



**University of  
Zurich**<sup>UZH</sup>

**Zurich Open Repository and  
Archive**

University of Zurich  
Main Library  
Strickhofstrasse 39  
CH-8057 Zurich  
[www.zora.uzh.ch](http://www.zora.uzh.ch)

---

Year: 2015

---

## **The phytotherapeutic fenugreek as trigger of toxic epidermal necrolysis**

Bentele-Jaberg, Nicoletta; Guenova, Emmanuella; Mehra, Tarun; Nägeli, Mirjam; Chang, Yung-Tsan; Cozzio, Antonio; French, Lars E; Hoetzenecker, Wolfram

**Abstract:** We describe the case of a 32-year-old woman who presented to the hospital with generalized painful exanthema, blisters and erosions 1 month after giving birth to a healthy girl. The patient's medical history was inconspicuous for comorbidities; however, it included the incidental intake of pain killers and a herbal preparation (fenugreek), which she took regularly over the last 4 weeks to improve lactation. Based on the clinical characteristics, we suspected toxic epidermal necrolysis (TEN), a severe cutaneous adverse drug reaction, which was confirmed by skin biopsy. The patient was treated with high-dose intravenous human immunoglobulins and was discharged 2 weeks after hospital admission in good condition. The allergological workup identified fenugreek as the most likely causative agent. Given the increased self-medication of freely available phytotherapeutics by patients in industrialized countries, herbal mixtures should be taken into consideration in the diagnostic workup of TEN.

DOI: <https://doi.org/10.1159/000433423>

Posted at the Zurich Open Repository and Archive, University of Zurich

ZORA URL: <https://doi.org/10.5167/uzh-115341>

Published Version

Originally published at:

Bentele-Jaberg, Nicoletta; Guenova, Emmanuella; Mehra, Tarun; Nägeli, Mirjam; Chang, Yung-Tsan; Cozzio, Antonio; French, Lars E; Hoetzenecker, Wolfram (2015). The phytotherapeutic fenugreek as trigger of toxic epidermal necrolysis. *Dermatology*, 231(2):99-102.

DOI: <https://doi.org/10.1159/000433423>

## The Phytotherapeutic Fenugreek as Trigger of Toxic Epidermal Necrolysis

Nicoletta Bentele-Jaberg<sup>a</sup> Emmanuella Guenova<sup>a</sup> Tarun Mehra<sup>b</sup> Mirjam Nägeli<sup>a</sup>  
Yung-Tsan Chang<sup>a</sup> Antonio Cozzio<sup>a</sup> Lars E. French<sup>a</sup> Wolfram Hoetzenecker<sup>a</sup>

<sup>a</sup>Department of Dermatology and <sup>b</sup>Medical Directorate, University Hospital of Zurich, Zurich, Switzerland

### Key Words

Toxic epidermal necrolysis ·  
Phytotherapeutics · Fenugreek

### Abstract

We describe the case of a 32-year-old woman who presented to the hospital with generalized painful exanthema, blisters and erosions 1 month after giving birth to a healthy girl. The patient's medical history was inconspicuous for comorbidities; however, it included the incidental intake of pain killers and a herbal preparation (fenugreek), which she took regularly over the last 4 weeks to improve lactation. Based on the clinical characteristics, we suspected toxic epidermal necrolysis (TEN), a severe cutaneous adverse drug reaction, which was confirmed by skin biopsy. The patient was treated with high-dose intravenous human immunoglobulins and was discharged 2 weeks after hospital admission in good condition. The allergological workup identified fenugreek as the most likely causative agent. Given the increased self-medication of freely available phytotherapeutics by patients in industrialized countries, herbal mixtures should be taken into consideration in the diagnostic workup of TEN.

© 2015 S. Karger AG, Basel

### Introduction

Toxic epidermal necrolysis (TEN) is a rare cutaneous adverse drug reaction, with a mortality of around 30% [1]. Prior drug intake is reported in over 95% of patients with TEN, and a strong association is observed in 80% of cases [2, 3]. Other, rarer causes include infections and immunizations. To date, more than 100 drugs have been associated with the development of TEN, the most frequent being allopurinol, antibiotics, nonsteroidal anti-inflammatory drugs and anticonvulsants [3]. Self-medication with phytotherapeutics has become increasingly popular, and due to their availability, their abusive use is increasing. We describe a patient with TEN most likely triggered by the regular use of the herb fenugreek.

### Case Report

A 32-year-old female presented to a regional hospital with fever, headache and beginning exanthema. She had given birth to her second child, without any complications, 1 month prior to admission. The patient's medical history included the irregular intake of metamizole, paracetamol (acetaminophen) and ibuprofen since giving birth. Additionally, she regularly took a herbal preparation made of pure fenugreek seeds to improve lactation. All medications except for fenugreek had been taken by the

patient during her previous pregnancy without the appearance of any adverse reactions. The patient was first diagnosed with a common cold and sent back home. Due to the deterioration of her general condition with spreading exanthema on the face and upper trunk, the patient was transferred to the University Hospital with the suspected diagnosis of severe cutaneous adverse drug reaction. On admission, she presented with multiple bullae and erosions with a positive Nikolsky sign and skin sloughing involving approximately 30–40% of her body surface including the mouth, lips and tongue (fig. 1). There was no involvement of the eyes, genital mucosa or other mucosal areas. Two biopsies were performed, and both confirmed the diagnosis of TEN with completely necrotic epidermis with mixed-cell inflammatory infiltrates in the histological sections. The severity-of-illness score (SCORTEN) was 2, with a predicted mortality of 3% [4, 5]. Treatment with intravenous high-dosed immunoglobulins (IVIg) at a total dose of 3 g/kg body weight was initiated and continued over the following 3 days together with supportive treatment at the intensive care unit. In the following days, the patient's condition markedly improved, and she was finally discharged 2 weeks later after full recovery. In order to identify the causative agent, an allergologic workup was performed 4 months after full recovery. Lymphocyte transformation tests (LTT) demonstrated a significant sensiti-

**Table 1.** Lymphocyte transformation test positive for fenugreek

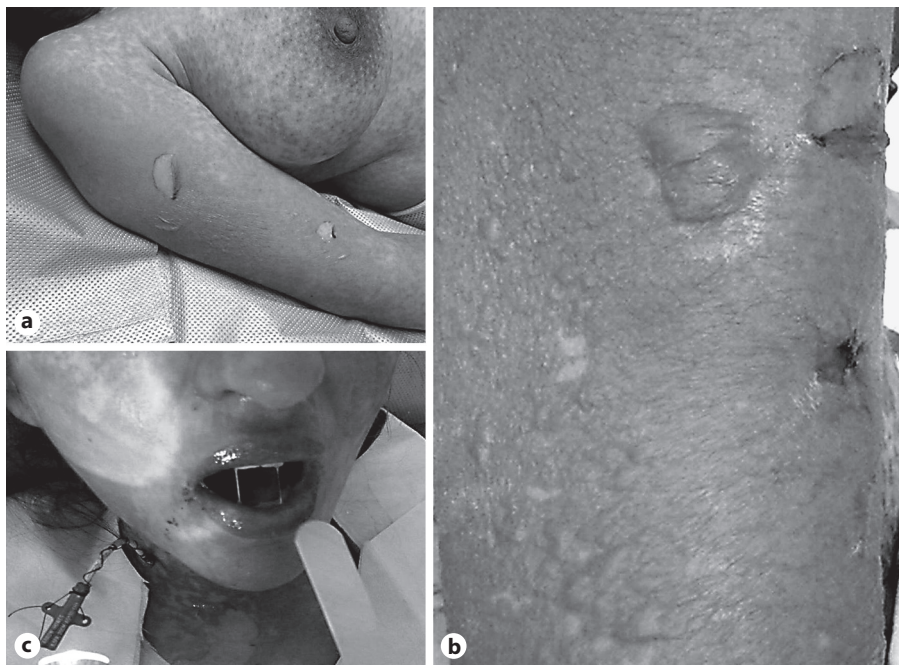
Compound	Concentration, µg	SI (autologous plasma)	SI (AB plasma)
Paracetamol	0.1	1.3	1
	1	1.2	1
	10	1	0.9
	100	0.9	0.8
	500	0.8	1.3
Ibuprofen	0.1	0.8	1.3
	1	1	1.3
	10	1.1	1.6
	100	0.8	0.8
Metamizole	0.1	0.6	0.8
	1	1	0.9
	10	1.5	1
	100	0.9	0.5
Fenugreek	100	86.9	1.3
	1,000	17.5	3.2
Tetanus (positive control)	1	125.9	108.9

SI = Stimulation index; AB plasma = human, antibody-free, plasma blood type AB.

zation for fenugreek without any proliferation of immune cells in the presence of metamizole, paracetamol and ibuprofen (table 1). However, it should be noted that the LTT are not a standardized procedure and merely demonstrate the proliferation of lymphocytes in the presence of various compounds. Skin patch tests were not performed because the rate of positive test reactions in Stevens-Johnson syndrome (SJS)/TEN is rather low with 24% [6]. Due to the risk of severe side effects after TEN, we did not apply oral provocation tests. Based on the LTT, fenugreek was identified as the most likely causative agent, despite the fact that infectious agents (e.g. certain viruses) cannot be ruled out completely as causative agents or cofactors of TEN. As drug hypersensitivity to metamizole, paracetamol and ibuprofen cannot be excluded without provocation testing, we advised against the intake of all three pain killers as well as of fenugreek in the future.

## Discussion

Today, SJS and TEN are regarded as being different manifestations in degrees of severity of one and the same rare, acute and life-threatening mucocutaneous disease, which is nearly always drug related [1]. In this context, TEN represents the severest form of this pathological entity. TEN is a consequence of extensive keratinocyte cell death that results in the separation of significant areas of skin at the dermal-epidermal junction, producing the appearance of scalded skin. This massive cell death results in mucous membrane detachment and contributes to the characteristic symptoms of TEN, which include high fever, skin pain, anxiety and asthenia [1]. In terms of pathogenesis, TEN is thought to be the consequence of an altered immune response to an antigenic drug-tissue complex, although the exact pathophysiologic mechanism(s) are still unclear. Today, three different concepts on how the antigenic drug-tissue complex is formed exist [7]: (a) covalent binding of a drug to a cellular peptide (hapten/prohapten concept), (b) noncovalent, direct interaction of a drug with a specific major histocompatibility complex (MHC) I allotype (p-i concept), and (c) presentation of an altered-self repertoire by direct drug-MHC I interaction (altered peptide concept). Whereas the well-known hapten model is less likely to be human leukocyte antigen (HLA) re-



**Fig. 1.** TEN triggered by fenugreek. **a** Detachment of large sheets of necrolytic epidermis (>30% body surface area), leading to extensive areas of denuded skin. **b** A few intact bullae are still present. **c** Hemorrhagic crusts with mucosal involvement.

**Table 2.** Severe cutaneous adverse reactions due to phytotherapeutics

Authors [Ref.]	Type of report	Phytotherapeutics	Severity of reaction	Survival
Mochitomi et al. [29]	case report	<i>Ophiopogon japonicus</i> tuber (in Chinese health drink)	SJS	yes
Wu and Deng [31]	case report	realgar (in oral herbal medicine and herbal ointment)	TEN	no
Shivamurthy et al. [30]	case report	ayurvedic drugs (not further specified)	TEN	yes
Monk [28]	case report	'golden health blood-purifying tablets' (contains extracts of red clover, burdock, queen's delight, poke root, prickly pear, ash, sassafras bark and <i>Passiflora</i> )	SJS	yes
Kumar Das et al. [27]	prospective cohort study	<i>Ocimum</i> , <i>Tribulus</i> , <i>Caesalpinia</i> , <i>Tinospora</i> , <i>Piper</i> , <i>Cichorium</i> and <i>Foeniculum</i>	TEN	34% survived
Wechwithan et al. [32]	pharmacovigilance study	<i>Andrographis</i> , green traditional medicine, <i>Derris scandens</i>	SJS	not reported

stricted, the other two concepts favor specific HLA phenotypes [8–10]. In line with the concepts of HLA-restricted drug presentation are reports on the genetic susceptibility, as evidenced by the identification of specific drug-related HLA alleles as major susceptibility genes for the development of SJS and TEN [11–13]. However, it should be noted that most HLA phenotypes associated with SJS/TEN are of relevance for people of Han-Chinese or South East Asian ancestry only. As a result of immune activation by the drug-tissue complex, an interplay of various cell types and cytokines (yet to be defined) is initiated that is accompanied by a strong expression of the cytolytic molecule FasL on keratinocytes as well as granulysin and annexin A1 secretion from cytotoxic T lymphocytes, natural killer cells, natural killer T cells and monocytes [14–19]. This leads to FasL- and granulysin-mediated apoptosis and/or annexin-dependent necroptosis of keratinocytes and subsequent epidermal necrosis and detachment. Of note, granulysin is expressed at high concentrations in the blister fluid of TEN patients, suggesting an important role of this protein in the pathogenesis of TEN [17].

To date, no specific therapies for TEN have shown efficacy in prospective, controlled clinical trials. Case reports and case series have reported the use of cyclosporine, cyclophosphamide, plasmapheresis, N-acetylcysteine, tumor necrosis factor- $\alpha$  antagonists (e.g. etanercept, infliximab), systemic corticosteroids and thalidomide [for a review, see 1]. In our case, we treated

the patient with high-dose IVIg (>2 g/kg bodyweight total). Even though the mechanism of action is still unclear, with confirmed diagnosis as well as for severe TEN, early administration of high-dose IVIg may be considered [1, 20]. Interestingly, it has been shown that IVIg do not reduce the levels of granulysin. This might be, at least, partly responsible for the lack of efficacy of IVIg in some patients [21, 22]. Alternatively, a recent study has shown excellent efficacy of cyclosporine in the treatment of TEN [23, 24].

Although TEN is mostly caused by prescribed drugs, we report the first case of TEN due to fenugreek. Fenugreek belongs to the family of Fabaceae and is used as a herb (dried or fresh leaves), spice (seeds) and vegetable (fresh leaves) in the Indian subcontinent, Argentina, Egypt, France, Spain and Turkey. Fenugreek is a popular phytotherapeutic and is thought to have beneficial effects in multiple sclerosis, diabetes, cancer and lactation although its mode of action is unknown, and controlled clinical trials are missing. Fenugreek seeds consist of approximately 50% fiber (fenugreekine), 20% gums, 20% proteins, besides moisture, lipids, starch and ash. Additionally, chemical analyses have identified alkaloids and various saponinins as part of fenugreek seeds. The antigenic parts of fenugreek are still unknown, but specific IgE binding with the fenugreek proteins in immunoblotting has been reported in 2 patients allergic to fenugreek and in mice sensitized to fenugreek [25, 26]. Not much is known about the adverse cutaneous side ef-

fects of fenugreek intake. A prospective observational study conducted in Bangladesh analyzed a total of 29 patients with TEN admitted to the intensive care unit [27]. In 10 patients (34%), the causative agent remains unidentified. However, those patients had treated themselves with several traditional herbal drugs to cure fever before the onset of TEN. Those herbal mixtures included *Ocimum*, *Tribulus*, *Caesalpinia*, *Tinospora*, *Piper*, *Cichorium* and *Foeniculum*. As *Caesalpinia* and fenugreek belong to the same plant family, namely Fabaceae, one can speculate that severe cutaneous adverse reactions were indeed triggered by herbal mixture in certain of those patients. The family of Fabaceae includes edible leguminous plants (e.g. beans, soya beans, lentils and peanuts). Because cross-reactivity between certain leguminous plants is known in allergic patients, one has to consider the possibility of food allergy to leguminous plants in the patient's allergological work-up. However, as she had eaten beans, soya beans, lentils and peanuts in the meantime without any complications, secondary food allergy to legumes could be ruled out. We performed a thorough literature search on phytotherapeutics as triggers of SJS and TEN. We identified 4 case reports and 1 cohort study including 10 patients [27–31]. In those reports, SJS and TEN were described to be caused by the intake of traditional medications (Chinese roots and drinks), herbal ointment containing realgar and ayurvedic drugs (table 2) [27–31]. In an additional study utilizing large pharmacovigilance data in Thailand from 2002



to 2013, the authors computed that 0.001% of all reported serious adverse drug reactions were due to Thai traditional medicine. Of those, green traditional medicine was associated with an increased odds ratio in terms of SJS [32]. Taken together, it is

important to consider herbal medication as a possible trigger of severe cutaneous adverse reactions like SJS and TEN as phytotherapeutics are becoming more popular in industrialized countries and are easily available.

## Disclosure Statement

No conflicts of interest declared.

## References

- French LE, Prins C: Erythema multiforme, Stevens-Johnson syndrome and toxic epidermal necrolysis; in Bologna JL, Jorrizo JL, Schaffer JV (eds): *Dermatology*, ed 3. New York, Elsevier, 2013, vol 3, pp 319–334.
- Garcia-Doval I, LeCleach L, Bocquet H, Otero XL, Roujeau JC: Toxic epidermal necrolysis and Stevens-Johnson syndrome: does early withdrawal of causative drugs decrease the risk of death? *Arch Dermatol* 2000;136:323–327.
- Roujeau JC, Kelly JP, Naldi L, Rzany B, Stern RS, Anderson T, Auquier A, Bastuji-Garin S, Correia O, Locati F, et al: Medication use and the risk of Stevens-Johnson syndrome or toxic epidermal necrolysis. *N Engl J Med* 1995;333:1600–1607.
- Bastuji-Garin S, Fouchard N, Bertocchi M, Roujeau JC, Revuz J, Wolkenstein P: SCORTEN: a severity-of-illness score for toxic epidermal necrolysis. *J Invest Dermatol* 2000;115:149–153.
- Trent JT, Kirsner RS, Romanelli P, Kerdel FA: Use of SCORTEN to accurately predict mortality in patients with toxic epidermal necrolysis in the United States. *Arch Dermatol* 2004;140:890–892.
- Barbaud A, Collet E, Milpied B, Assier H, Staudmont D, Avenel-Audran M, Grange A, Amarger S, Girardin P, Guinneeupain MT, Truchetet F, Lasek A, Waton J; Toxidermies group of the French Society of Dermatology: A multicentre study to determine the value and safety of drug patch tests for the three main classes of severe cutaneous adverse drug reactions. *Br J Dermatol* 2013;168:555–562.
- Abe R: Immunological response in Stevens-Johnson syndrome and toxic epidermal necrolysis. *J Dermatol* 2015;42:42–48.
- Yun J, Marcaida MJ, Eriksson KK, Jamin H, Fontana S, Pichler WJ, Yerly D: Oxypurinol directly and immediately activates the drug-specific T cells via the preferential use of HLA-B\*58:01. *J Immunol* 2014;192:2984–2993.
- Illing PT, Vivian JP, Dudek NL, Kostenko L, Chen Z, Bharadwaj M, Miles JJ, Kjer-Nielsen L, Gras S, Williamson NA, Burrows SR, Purcell AW, Rossjohn J, McCluskey J: Immune self-reactivity triggered by drug-modified HLA-peptide repertoire. *Nature* 2012;486:554–558.
- Ostrov DA, Grant BJ, Pompeu YA, Sidney J, Harndahl M, Southwood S, Oseroff C, Lu S, Jakoncic J, de Oliveira CA, Yang L, Mei H, Shi L, Shabanowitz J, English AM, Wriston A, Lucas A, Phillips E, Mallal S, Grey HM, Sette A, Hunt DF, Buus S, Peters B: Drug hypersensitivity caused by alteration of the MHC-presented self-peptide repertoire. *Proc Natl Acad Sci USA* 2012;109:9959–9964.
- Hung SI, Chung WH, Liou LB, Chu CC, Lin M, Huang HP, Lin YL, Lan JL, Yang LC, Hong HS, Chen MJ, Lai PC, Wu MS, Chu CY, Wang KH, Chen CH, Fann CS, Wu JY, Chen YT: HLA-B\*5801 allele as a genetic marker for severe cutaneous adverse reactions caused by allopurinol. *Proc Natl Acad Sci USA* 2005;102:4134–4139.
- Chung WH, Hung SI, Chen YT: Human leukocyte antigens and drug hypersensitivity. *Curr Opin Allergy Clin Immunol* 2007;7:317–323.
- Chung WH, Hung SI, Hong HS, Hsieh MS, Yang LC, Ho HC, Wu JY, Chen YT: Medical genetics: a marker for Stevens-Johnson syndrome. *Nature* 2004;428:486.
- Viard I, Wehrli P, Bullani R, Schneider P, Holler N, Salomon D, Hunziker T, Saurat JH, Tschopp J, French LE: Inhibition of toxic epidermal necrolysis by blockade of CD95 with human intravenous immunoglobulin. *Science* 1998;282:490–493.
- Wehrli P, Viard I, Bullani R, Tschopp J, French LE: Death receptors in cutaneous biology and disease. *J Invest Dermatol* 2000;115:141–148.
- Ito K, Hara H, Okada T, Shimojima H, Suzuki H: Toxic epidermal necrolysis treated with low-dose intravenous immunoglobulin: immunohistochemical study of Fas and Fas-ligand expression. *Clin Exp Dermatol* 2004;29:679–680.
- Chung WH, Hung SI, Yang JY, Su SC, Huang SP, Wei CY, Chin SW, Chiou CC, Chu SC, Ho HC, Yang CH, Lu CF, Wu JY, Liao YD, Chen YT: Granulysin is a key mediator for disseminated keratinocyte death in Stevens-Johnson syndrome and toxic epidermal necrolysis. *Nat Med* 2008;14:1343–1350.
- Saito N, Qiao H, Yanagi T, Shinkuma S, Nishimura K, Suto A, Fujita Y, Suzuki S, Nomura T, Nakamura H, Nagao K, Obuse C, Shimizu H, Abe R: An annexin A1-FPR1 interaction contributes to necroptosis of keratinocytes in severe cutaneous adverse drug reactions. *Sci Transl Med* 2014;6:245ra295.
- Viard-Leveugle I, Bullani RR, Meda P, Micheau O, Limat A, Saurat JH, Tschopp J, French LE: Intracellular localization of keratinocyte Fas ligand explains lack of cytolytic activity under physiological conditions. *J Biol Chem* 2003;278:16183–16188.
- Enk A, Fierlbeck G, French L, Hertl M, Messer G, Meurer M, Steinbrink K, Stingl G, Volz-Platzer B, Zillikens D: Use of high-dose immunoglobulins in dermatology. *J Dtsch Dermatol Ges* 2009;7:806–812.
- Lee HY, Lim YL, Thirumoorthy T, Pang SM: The role of intravenous immunoglobulin in toxic epidermal necrolysis: a retrospective analysis of 64 patients managed in a specialized centre. *Br J Dermatol* 2013;169:1304–1309.
- Huang YC, Li YC, Chen TJ: The efficacy of intravenous immunoglobulin for the treatment of toxic epidermal necrolysis: a systematic review and meta-analysis. *Br J Dermatol* 2012;167:424–432.
- Valeyrrie-Allanore L, Wolkenstein P, Brochard L, Ortonne N, Maitre B, Revuz J, Bagot M, Roujeau JC: Open trial of ciclosporin treatment for Stevens-Johnson syndrome and toxic epidermal necrolysis. *Br J Dermatol* 2010;163:847–853.
- Kirchhof MG, Miliszewski MA, Sikora S, Papp A, Dutz JP: Retrospective review of Stevens-Johnson syndrome/toxic epidermal necrolysis treatment comparing intravenous immunoglobulin with cyclosporine. *J Am Acad Dermatol* 2014;71:941–947.
- Patil SP, Niphadkar PV, Bapat MM: Allergy to fenugreek (*Trigonella foenum graecum*). *Ann Allergy Asthma Immunol* 1997;78:297–300.
- Vinje NE, Namork E, Lovik M: Cross-allergic reactions to legumes in lupin and fenugreek-sensitized mice. *Scand J Immunol* 2012;76:387–397.
- Kumar Das K, Khondokar S, Rahman A, Chakraborty A: Unidentified drugs in traditional medications causing toxic epidermal necrolysis: a developing country experience. *Int J Dermatol* 2014;53:510–515.
- Monk B: Severe cutaneous reactions to alternative remedies. *Br Med J (Clin Res Ed)* 1986;293:665–666.
- Mochitomi Y, Inoue A, Kawabata H, Ishida S, Kanzaki T: Stevens-Johnson syndrome caused by a health drink (Eberu) containing ophiopogon tuber. *J Dermatol* 1998;25:662–665.
- Shivamurthy RP, Kallappa R, Reddy SG, Rangappa DK: Stevens-Johnson syndrome due to unknown drugs. *Indian J Pharmacol* 2012;44:134–135.
- Wu ML, Deng JF: Toxic epidermal necrolysis after extensive dermal use of realgar-containing (arsenic sulfide) herbal ointment. *Clin Toxicol (Phila)* 2013;51:801–803.
- Wechwithan S, Suwankesawong W, Sornsriwichai V, McNeil EB, Jiraphongsa C, Chongsuvivatwong V: Signal detection for Thai traditional medicine: examination of national pharmacovigilance data using reporting odds ratio and reported population attributable risk. *Regul Toxicol Pharmacol* 2014;70:407–412.