



Spectrophotometric and visual evaluation of peri-implant soft tissue color

Scherrer, Daniela

Abstract: Aim: To spectrophotometrically and visually test whether the peri-implant mucosal color differs from the color of the natural gingiva. Material and methods: Forty single implants in the incisor and premolar region of 40 patients were assessed 3–7 years after implant placement. The differences of the color components lightness, chroma along red-green axis, chroma along yellow-blue axis, and the total color difference DE between peri-implant mucosa and natural gingiva were measured with a spectrophotometer. The color difference between peri-implant mucosa and natural gingiva was visually evaluated by clinicians and rated as “clinically visible” or “clinically invisible” from speaking distance. The dimensions of peri-implant mucosa and gingiva at the mid-buccal aspect were evaluated by using cone-beam CT. Spearman analysis was performed to detect correlations between different variables. Two-sided t-test, ANOVA, Mann–Whitney, and Kruskal–Wallis tests were applied to detect differences between the groups. Results: The spectrophotometrically assessed color difference DE between peri-implant mucosa and natural gingiva amounted to 7.0 3.9. The peri-implant mucosa presented a significant dark, greenish and bluish discoloration in comparison with gingiva at control teeth. Clinical investigation revealed that in 60% of sites the color difference between peri-implant mucosa and natural gingiva was clinically visible from speaking distance. The threshold value DE for the extraoral clinical distinction of mucosal color differences measured 7.5. When comparing the groups with visible and invisible color differences with respect to the three color components, a significant difference was found only for chroma along yellow-blue axis. In the group with visible color difference, mucosa presented a bluish discoloration. Correlation analysis indicated that with an increase in mucosal thickness, a trend for smaller DE was found. Conclusion: The spectrophotometrically assessed color of the peri-implant mucosa revealed more dark, green and blue components compared to the natural gingiva. At 60% of the implants, periimplant mucosal discoloration was visible from speaking distance. The sites with visible and those with invisible mucosal discolorations differed significantly only regarding the chroma along yellowblue axis.

Posted at the Zurich Open Repository and Archive, University of Zurich
ZORA URL: <https://doi.org/10.5167/uzh-126185>
Published Version

Originally published at:

Scherrer, Daniela. Spectrophotometric and visual evaluation of peri-implant soft tissue color. 2016, University of Zurich, Faculty of Medicine.

Universität Zürich
Zentrum für Zahnmedizin
Klinik für Kronen- und Brückenprothetik, Teilprothetik und zahnärztliche
Materialkunde (KBTM)
Direktor: Prof. Dr. med. dent. Christoph H. F. Hämmerle

Arbeit unter Leitung von PD Dr. med. dent. Goran I. Benic

Spectrophotometric and visual evaluation of peri-implant soft tissue color

INAUGURAL-DISSERTATION
zur Erlangung der Doktorwürde der Zahnmedizin
der Medizinischen Fakultät
der Universität Zürich

vorgelegt von
Daniela Scherrer

Genehmigt auf Antrag von Prof. Dr. med. dent. Christoph H. F. Hämmerle
Zürich 2016

Publikationshinweis

Spectrophotometric and visual evaluation of peri-implant soft tissue color

Publiziert am: 5. Februar 2016

Journal: *Clinical Oral Implants Research*, 00, 2016, 1-9

doi: 10.1111/clr.12781

<http://onlinelibrary.wiley.com/doi/10.1111/clr.12781/abstract;jsessionid=B4D6757BFE4B0C36F05F7194F65DF6A3.f01t01>

Goran I. Benic*
 Daniela Scherrer*
 Manuel Sancho-Puchades
 Daniel S. Thoma
 Christoph H. F. Hämmerle

Spectrophotometric and visual evaluation of peri-implant soft tissue color

Authors' affiliations:

Goran I. Benic, Manuel Sancho-Puchades, Daniel S. Thoma, Christoph H. F. Hämmerle, Clinic of Fixed and Removable Prosthodontics and Dental Material Science, Center of Dental Medicine, University of Zurich, Zurich, Switzerland
 Daniela Scherrer, Private Practice, Romanshorn, Switzerland

Corresponding author:

Dr. Goran I. Benic
 Clinic of Fixed and Removable Prosthodontics and Dental Material Science
 Center of Dental Medicine
 University of Zurich
 Plattenstrasse 11, CH-8032 Zurich
 Switzerland
 Tel.: +41 44 634 32 60
 Fax: +41 44 634 43 05
 e-mail: goran.benic@zzm.uzh.ch

Key words: color, dental, gingiva, implant, mucosa, peri-implant, soft tissue, spectrophotometry, spectrophotometer, thickness

Abstract

Aim: To spectrophotometrically and visually test whether the peri-implant mucosal color differs from the color of the natural gingiva.

Material and methods: Forty single implants in the incisor and premolar region of 40 patients were assessed 3–7 years after implant placement. The differences of the color components lightness, chroma along red-green axis, chroma along yellow-blue axis, and the total color difference ΔE between peri-implant mucosa and natural gingiva were measured with a spectrophotometer. The color difference between peri-implant mucosa and natural gingiva was visually evaluated by clinicians and rated as “clinically visible” or “clinically invisible” from speaking distance. The dimensions of peri-implant mucosa and gingiva at the mid-buccal aspect were evaluated by using cone-beam CT. Spearman analysis was performed to detect correlations between different variables. Two-sided *t*-test, ANOVA, Mann–Whitney, and Kruskal–Wallis tests were applied to detect differences between the groups.

Results: The spectrophotometrically assessed color difference ΔE between peri-implant mucosa and natural gingiva amounted to 7.0 ± 3.9 . The peri-implant mucosa presented a significant dark, greenish and bluish discoloration in comparison with gingiva at control teeth. Clinical investigation revealed that in 60% of sites the color difference between peri-implant mucosa and natural gingiva was clinically visible from speaking distance. The threshold value ΔE for the extraoral clinical distinction of mucosal color differences measured 7.5. When comparing the groups with visible and invisible color differences with respect to the three color components, a significant difference was found only for chroma along yellow-blue axis. In the group with visible color difference, mucosa presented a bluish discoloration. Correlation analysis indicated that with an increase in mucosal thickness, a trend for smaller ΔE was found.

Conclusion: The spectrophotometrically assessed color of the peri-implant mucosa revealed more dark, green and blue components compared to the natural gingiva. At 60% of the implants, peri-implant mucosal discoloration was visible from speaking distance. The sites with visible and those with invisible mucosal discolorations differed significantly only regarding the chroma along yellow-blue axis.

Natural and harmonic appearance of dental reconstructions and adjacent soft tissue is an essential element regarding the clinical outcome in esthetic sites (Belser et al. 2004; Benic et al. 2012b). Discoloration of peri-implant mucosa represents a clinical problem that, therefore, may compromise the esthetic success in implant dentistry.

Spectrophotometry is the most frequently used method to objectively assess color differences in implant dentistry (Benic et al. 2015). When compared to the ability of the human eye to distinguish colors in clinical

settings, spectrophotometry was found to detect smaller color differences and to achieve higher reproducibility (Johnston & Kao 1989; Gehrke et al. 2009; Paniz et al. 2014).

Several spectrophotometric investigations showed that the peri-implant mucosal color differs from the color of the natural gingiva (Park et al. 2007; Jung et al. 2008; Sailer et al. 2009; Bressan et al. 2011; Paniz et al. 2014). Previous studies sought at investigating the possibilities for improving the color match of the peri-implant mucosa to the natural gin-

*These authors contributed equally to the study.

Date:

Accepted 20 December 2015

To cite this article:

Benic GI, Scherrer D, Sancho-Puchades M, Thoma DS, Hämmerle CHF. Spectrophotometric and visual evaluation of peri-implant soft tissue color. *Clin. Oral Impl. Res.* 00, 2016, 1–9
 doi: 10.1111/clr.12781

giva. In particular, these trials evaluated the influence of the color of the reconstructive material and of the mucosal thickness (MT) on the degree of mucosal discoloration (Jung et al. 2007, 2008; Sailer et al. 2009; Bressan et al. 2011; Happe et al. 2013a,b; Buchi et al. 2014; Pecnik et al. 2015). Based on the findings of these studies, it can be concluded that the discoloration of peri-implant mucosa can clinically be addressed by improving the optical properties of the restorative material and by thickening of the covering mucosa.

As far as the clinical relevance of mucosal discoloration is concerned, the ability of the human eye to detect color differences plays a key role. For the intraoral evaluation of dental hard tissue, spectrophotometrically measured color difference ΔE values ranging from 2 to 4 were reported as the threshold of perceptibility by the naked eye (Johnston & Kao 1989; Douglas & Brewer 1998; Douglas et al. 2007; Yilmaz et al. 2009). A recent *in vitro* trial investigated the threshold value for the detection of color differences of the human gingiva (Sailer et al. 2014). Under standardized conditions on the computer monitor, the threshold value ΔE for the perceptibility of gingival colors amounted to 3.1. In this context, it has to be taken into account that natural color difference ΔE between gingiva at contralateral teeth was reported to measure 2.7 (Ishikawa et al. 1988).

Currently, there is scarce information on the threshold value for the distinction of mucosal color differences under clinical settings. In other words, the clinical relevance of the spectrophotometrically assessed mucosal color difference remains unknown. In a recent clinical trial, dental professionals rated the color match of the peri-implant mucosa to the natural gingiva on a scale ranging from perfect match to clinically unacceptable (Paniz et al. 2014). Subsequently, the color difference ΔE between the peri-implant mucosa and the gingiva was assessed by means of a spectrophotometer. The threshold value ΔE for the clinical distinction of mucosal color differences between perfect/good match and distinguishable difference amounted to 8.7 (Paniz et al. 2014). This value differs considerably from the threshold values calculated in the previously described studies.

The aim of this cross-sectional clinical study was to spectrophotometrically and visually test whether the peri-implant mucosal color differs from the color of the natural gingiva. In addition, the correlation between the degree of mucosal discoloration and the MT and between the mucosal discoloration and the type of abutment material was investigated.

Material and methods

This cross-sectional evaluation was performed at the Clinic of Fixed and Removable Prosthodontics and Dental Material Science, Center of Dental Medicine, University of Zurich, Zurich, Switzerland. The trial was approved by the local ethics committee (Kantonale Ethik-Kommission, Zurich, Switzerland), and written informed consent was obtained from all the patients.

Patient and implant selection

Three investigators experienced in reconstructive and implant dentistry performed the examinations. Prior to the study, the investigators attended a calibration session to standardize the criteria for the patient selection and the assessment techniques.

The patients previously treated with single implants at the Clinic of Fixed and Removable Prosthodontics and Material Science, Centre of Dental Medicine, University of Zurich, were recruited for this investigation.

The study implant had to fulfill the following inclusion criteria:

- Single-tooth implant in incisor, canine, or premolar region.
- Follow-up period of 3–7 years after implant placement.
- Presence of mesial and distal natural teeth.
- No metal reconstruction on two teeth mesially and distally to the implant site.
- Complete clinical records.
- No previous occurrence of complications that required any surgical treatment.
- No implant mobility, no persistent subjective complaints, no continuous peri-implant radiolucency.
- No peri-implant infection.

If two or more implant sites per patient fulfilled the inclusion criteria, one study site was randomly selected by casting a die. The contralateral vital tooth was selected as control site. In cases where the contralateral tooth was absent or non-vital, the control tooth was chosen adjacent to the implant site.

Spectrophotometric assessment

A reflectance spectrophotometer (Spectroshade™; Medical High Technologies, Niederhasli, Switzerland) was used for the color evaluation of the buccal mucosa. Prior to each measurement, the camera was calibrated by using a white and a green ceramic tile supplied by the manufacturer.

To objectively measure the discoloration of the peri-implant mucosa, spectrophotometric measurements of the buccal mucosa were

performed at study implant and at control tooth (Fig. 1). The spectrophotometer camera was positioned perpendicular to the mid-buccal mucosa, and three images were captured at each site. For spectrophotometric analysis, the image was displayed on a computer monitor and a circular area-of-interest with 1 mm diameter was selected. The center of the area-of-interest was located 1 mm apical to the mid-buccal mucosal/gingival margin (Sailer et al. 2009; Benic et al. 2013).

Spectral analysis rendered the CIE-Lab color coordinates (Commission Internationale d'Eclairage) L : lightness, a : chroma along red-green axis, and b : chroma along yellow-blue axis. The total color difference ΔE between the peri-implant mucosa and the natural gingiva was calculated according to the formula $\Delta E = [(L_{\text{impl}} - L_{\text{contr}})^2 + (a_{\text{impl}} - a_{\text{contr}})^2 + (b_{\text{impl}} - b_{\text{contr}})^2]^{1/2}$ (CIE 2004).

The ΔE value of 3.7 was considered as the threshold value for intraoral color distinction by the human eye (Johnston & Kao 1989).

Clinical assessment

The procedures used for periodontal assessment and periapical radiography will be described in a subsequent publication (three-dimensional evaluation of peri-implant bone and mucosa).

The clinicians visually evaluated the color match between the buccal marginal mucosa at the implant site and the gingiva at the control tooth from a distance of 40–50 cm. If needed, the lips were retracted to allow the full display of the marginal mucosa at the implant site and the control tooth. The clinicians rated the peri-implant mucosal discoloration as “clinically visible” or “clinically invisible”.

Cone-beam computed tomographic assessment

The procedures used for cone-beam computed tomography (CBCT) scanning and analysis will be described in a subsequent publication (three-dimensional evaluation of peri-implant bone and mucosa).

To allow depicting the soft tissues within CBCT, a thin layer of light-curing radio-opaque flowable composite was applied on the peri-implant mucosa and the gingiva of the control tooth (Benic et al. 2012a; Jung et al. 2015). CBCT imaging was performed with a 3DExam CBCT scanner (KaVo Dental, Biberich, Germany). The scans were made with following technical parameters: 120 kV, 5 mA, 19 mAs, voxel size of 0.125 mm and 360° rotation.

Bucco-oral sections perpendicular to the implant/tooth axis were used for CBCT analysis. The following parameters were assessed:

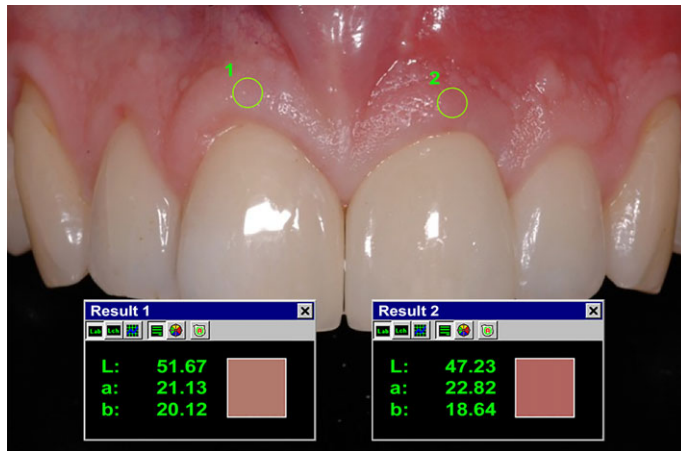

Fig. 1. Spectrophotometric color evaluation of the buccal mucosa at the control tooth 11 and the test implant 21.

- Mucosal thickness at the study implant (MT) 1 mm apical to the mucosal margin measured perpendicular to the implant axis (mm).
- Gingival thickness at the control tooth (GT) 1 mm apical to the gingival margin measured perpendicular to the tooth axis (mm).
- Distance from the mucosal margin to the most coronal aspect of the alveolar crest (MM-AC) measured parallel to the implant axis (mm).

Statistical analysis

Descriptive statistics was computed for all the variables (SPSS Statistics 21; IBM corporation, Somers, NY, USA). The data were described by using mean values, standard deviations, 95% confidence intervals (95% CI), medians, and ranges. The assumption of normality of the data was tested using Kolmogorov–Smirnov and Shapiro–Wilk tests. In case of normal distribution parametric methods (*t*-test and ANOVA) were applied. Nonparametric tests (Spearman correlation, Mann–Whitney, and Kruskal–Wallis tests) were used in case of non-normality of the data. More specifically, the one-sample *t*-test was applied to test ΔE values in comparison with the threshold ΔE of 3.7 for intraoral color distinction. Spearman analysis was performed to detect correlations between ΔE , ΔL , Δa , Δb , MT, GT, MM-AC, reconstructive materials, and results of the visual evaluation. Stratified analyses were computed by partitioning the sites according to the MT, the reconstructive material, and the result of the visual rating. Two-sided *t*-test and Mann–Whitney test were applied to detect

differences between the group with visually detectable color difference and the group with invisible color difference. Kruskal–Wallis test and ANOVA were performed for comparisons between the three groups with different MTs and between the three groups with different reconstructive materials. ROC analysis was employed to calculate a threshold ΔE value for the extraoral clinical distinction of mucosa color. Results of tests with *P*-value ≤ 0.05 were considered statistically significant, and these with *P*-value between 0.05 and 0.1 were interpreted as statistical trend.

Results

A total of 40 patients (18 women and 22 men) with 40 study implants were included in this study. The patients' mean age amounted to 36.6 years (range: 27–73 years). The follow-up period after implant placement ranged from 42 to 84 months (mean: 5.1 years).

Seven implants were inserted to replace maxillary premolars, 3 for maxillary canines, 24 for maxillary incisors, and 6 for mandibular premolars. With respect to implant type, there were 24 one-piece and 16 two-piece implants. Two implant placements were performed immediately after tooth extraction, 15 as type II procedure, 2 as type III procedure, and 21 as type IV procedure (Hämmerle et al. 2004). Guided bone regeneration was performed in 35 sites either as one- or as two-stage procedure. Two implants were loaded immediately after implant placement, 1 implant was early loaded, and 37 implants were conventionally loaded (Esposito et al. 2007).

Spectrophotometrically evaluated mucosal color difference

The overall color difference ΔE between the peri-implant mucosa and the natural gingiva amounted to 6.97 ± 3.90 (Table 1). This value was statistically different from the threshold value of 3.7 for color distinction ($P < 0.001$). In 31 of 40 sites (77.5%), ΔE measured > 3.7 .

ΔL amounted to -1.36 ± 4.53 , Δa to -2.78 ± 5.00 , and Δb to -1.63 ± 2.51 (Table 1). In other words, the buccal peri-implant mucosa revealed a dark, greenish and bluish discoloration in comparison with the gingiva at control teeth.

Visually evaluated mucosal color difference

In 16 of 40 sites (40%), the color difference between the peri-implant mucosa and the natural gingiva was clinically invisible from speaking distance, whereas in 24 of 40 sites (60%), the clinicians detected a visible color difference. A statistically significant correlation was detected between ΔE and results of the clinicians' visual evaluation of the color match (Spearman coeff.: 0.345; $P = 0.029$).

Total color difference ΔE amounted to 5.34 ± 3.24 in the group with invisible color difference and to 8.06 ± 3.99 in the group with perceivable color difference (Table 2, Fig. 2). The difference between the groups was statistically significant ($P = 0.029$).

When comparing the sites with visible and those with invisible color differences regarding the color components, significant difference was found only for Δb . Δb amounted to -0.38 ± 1.91 in the group with invisible color difference and to -2.46 ± 2.54 in the group with perceivable color difference ($P = 0.008$) (Table 2, Fig. 2). In other words, in the group with visible color difference, the mucosa presented a bluish discoloration (Fig. 2).

Ten of 16 (62.5%) sites with invisible color difference revealed $\Delta E > 3.7$. In the group with visible color difference, 21 of 24 (87.5%) of the sites were characterized by $\Delta E > 3.7$.

The threshold value ΔE for the clinical distinction of mucosal color differences was calculated and amounted to 7.54.

Mucosal thickness and mucosal color difference

Mean peri-implant MT measured 1.75 ± 0.41 mm (range: 0.90–2.70 mm) and mean GT at the control teeth amounted to 1.17 ± 0.22 mm (range: 0.80–1.70 mm). MT and GT were significantly correlated (Spearman coeff.: 0.426; $P = 0.006$). On average, MT was 0.58 ± 0.36 mm thicker in comparison with GT (95% CI: 0.47; 0.70 mm) (Table 3).

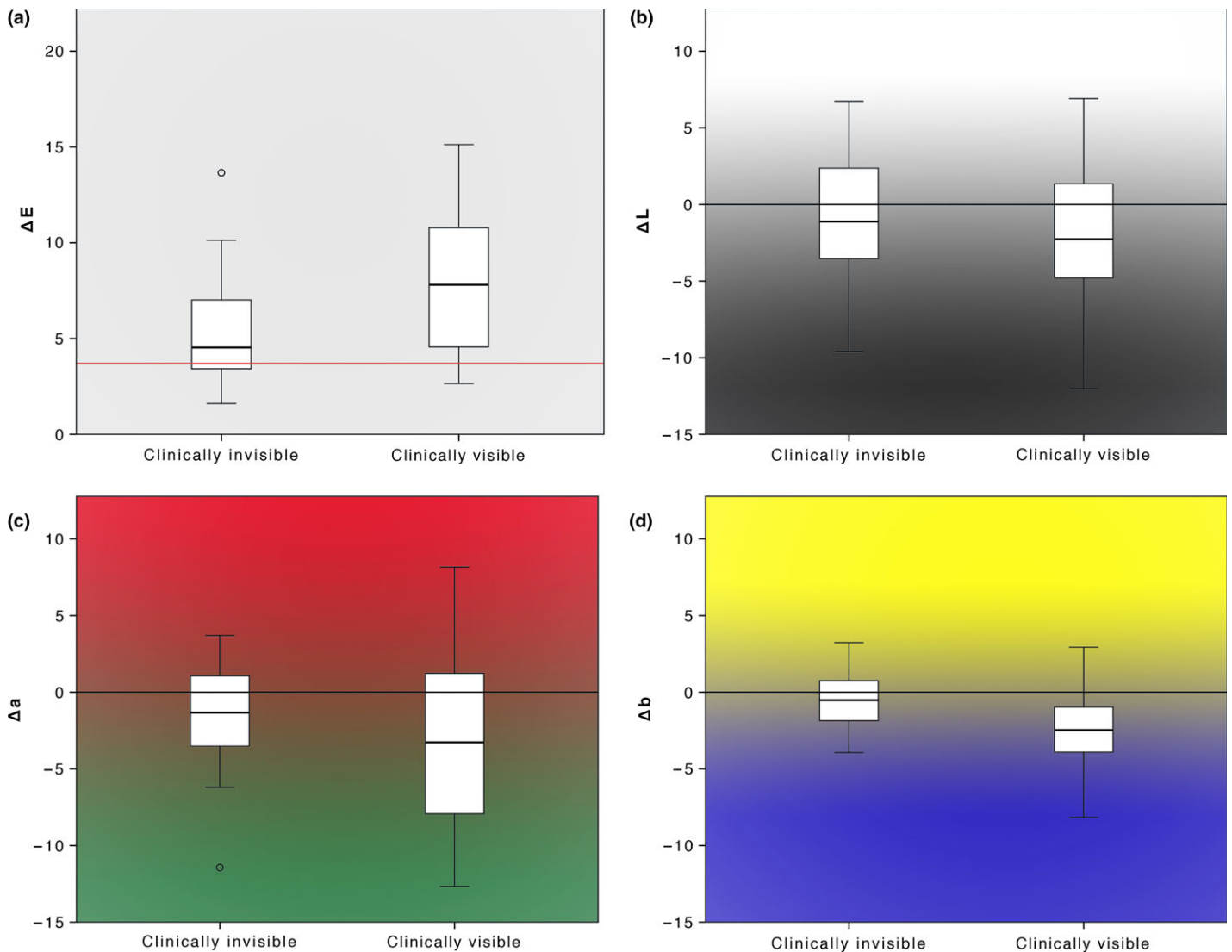


Fig. 2. Boxplots for (a) total color difference (ΔE), (b) difference of lightness (ΔL), (c) difference of chroma along red-green axis (Δa), and (d) difference of chroma along yellow-blue axis (Δb) between the peri-implant mucosa and the natural gingiva divided according to the results of the visual evaluation of color match. The line at the ΔE value of 3.7 represents the threshold value for intraoral color distinction.

A statistical trend was detected for the correlations between ΔE and MT (Spearman coeff.: -0.294 ; $P = 0.066$) and between ΔE and GT (Spearman coeff.: -0.283 ; $P = 0.077$), indicating that with an increase in soft tissue thickness a smaller ΔE was found.

Dividing the sites according to the MT rendered 6 of 40 (15%) cases with $MT < 1.5$ mm, 23 of 40 (57.5%) cases with $MT 1.5$ – 2 mm and 11 of 40 (27.5%) cases with $MT > 2$ mm. Total color difference ΔE reached 9.94 ± 4.50 in the group with $MT < 1.5$ mm (MT: 1.12 ± 0.17 mm). ΔE measured 6.93 ± 3.59 in the group with $MT 1.5$ – 2 mm (MT: 1.68 ± 0.16 mm) and 5.44 ± 3.61 in the group with $MT > 2$ mm (MT: 2.25 ± 0.23 mm) (Table 4, Fig. 3). There was a statistical trend of differences between the groups ($P = 0.064$).

The total color difference ΔE was above the threshold value 3.7 for intraoral color distinction in 100% of cases with $MT < 1.5$ mm, in 78.3% of cases with $MT 1.5$ – 2 mm, and in 63.6% of cases with $MT > 2$ mm. ΔE was significantly above 3.7 in the groups with $MT < 1.5$ mm ($P = 0.019$) and $MT 1.5$ – 2 mm ($P < 0.001$). In the group with $MT > 2$ mm, the difference between ΔE and 3.7 was not statistically significant ($P = 0.140$) (Fig. 3).

The highest color differences ΔL , Δa , and Δb were found in the sites with $MT < 1.5$ mm. In the group with $MT > 2$ mm, ΔL amounted to 0.01 ± 3.91 (95% CI: -2.62 ; 2.63), Δa to -2.82 ± 4.18 (95% CI: -5.62 ; -0.01), and Δb to -1.49 ± 1.29 (95% CI: -2.36 ; -0.63) (Table 4, Fig. 3).

The sites with visible and those with invisible mucosal discolorations did not dif-

fer regarding the MT ($P = 0.760$). MT measured 1.75 ± 0.43 mm in the group with invisible color difference and 1.75 ± 0.40 mm in the group with perceivable color difference.

Reconstructive material and mucosal color difference

Dividing the sites according to the reconstructive material under the mucosal region-of-interest (1 mm apical to the mid-buccal mucosal margin) rendered six sites with all-ceramic, nine sites with metal-ceramic (porcelain-fused-to-metal), and 23 with metal (titanium or gold) ($n = 38$). Two resin crowns were not included in this part of the analysis.

ΔE amounted to 4.84 ± 2.97 for all-ceramic, to 7.05 ± 5.04 for metal-ceramic, and to 7.25 ± 3.39 for metal. There were no statisti-

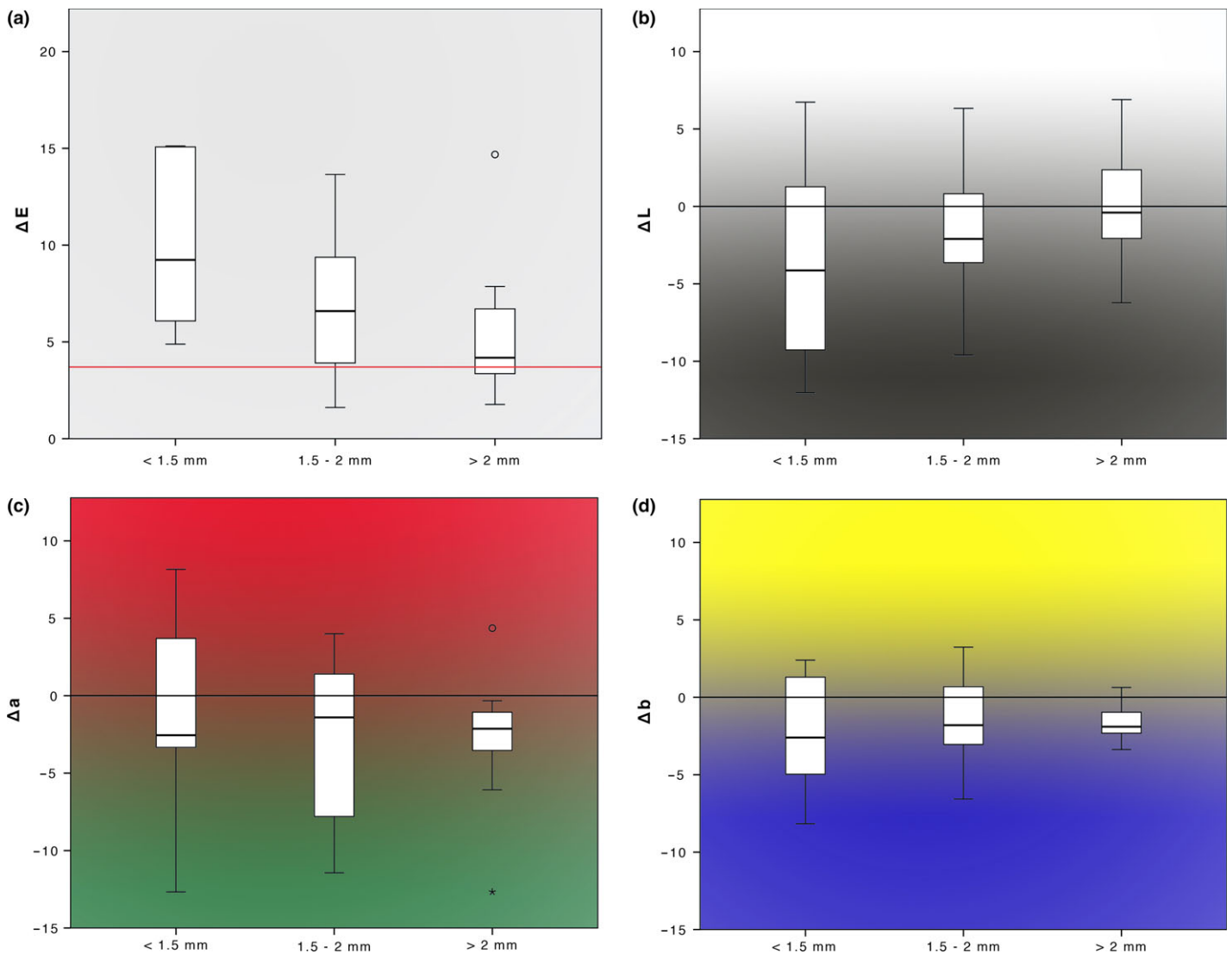


Fig. 3. Boxplots for (a) total color difference (ΔE), (b) difference of lightness (ΔL), (c) difference of chroma along red-green axis (Δa), and (d) difference of chroma along yellow-blue axis (Δb) between the peri-implant mucosa and the natural gingiva divided according to the mucosal thickness. The line at the ΔE value of 3.7 represents the threshold value for intraoral color distinction as perceived by human eye.

Table 1. Results of the spectrophotometric assessment of color differences

	Mean \pm SD	Range	95% CI (Mean)	Median	IQR	95% CI (Median)
ΔE	6.97 \pm 3.90	1.61 to 15.12	5.72; 8.22	6.04	5.69	4.56; 7.86
ΔL	-1.36 \pm 4.53	-12.03 to 6.90	-2.81; 0.09	-1.57	5.30	-3.19; -0.27
Δa	-2.78 \pm 5.00	-12.67 to 8.17	-4.38; -1.18	-2.10	8.40	-4.23; -0.33
Δb	-1.63 \pm 2.51	-8.17 to 3.23	-2.43; -0.83	-1.85	3.84	-2.44; -0.97

ΔE , total color difference; ΔL , difference of lightness; Δa , difference of chroma along red-green axis; Δb , difference of chroma along yellow-blue axis; SD, standard deviation; 95% CI (Mean), 95% confidence interval of the mean; IQR, interquartile range; 95% CI (Median), 95% confidence interval of the median.

cally significant differences in ΔE , ΔL , Δa , and Δb between the groups ($P > 0.05$) (Table 5).

Mucosal thickness measured 1.80 ± 0.28 mm in the all-ceramic group, 1.58 ± 0.40 mm in the metal-ceramic group, and 1.80 ± 0.42 mm in the metal group ($P > 0.05$).

Discussion

In the present study, the spectrophotometrically assessed color of the peri-implant mucosa differed significantly from the color of the natural gingiva. At 60% of the implants, peri-implant mucosal discoloration was visible from speaking distance. The sites

with perceptible and non-perceptible mucosal discolorations differed significantly only regarding the chroma along yellow-blue axis. The threshold value ΔE for the extraoral clinical distinction of mucosal color differences amounted to 7.5.

In this study, the total color difference ΔE between peri-implant mucosa and natural gingiva measured 7.0 ± 3.9 . The color coordinates L , a , and b were significantly lower at implant sites compared with control sites. In other words, the peri-implant mucosa color presented more dark, green and blue components in comparison with the gingiva at the control teeth. These data are within the range of mean values reported in previous clinical studies that spectrophotometrically assessed the color difference between peri-implant soft tissue and gingiva at control

Table 2. Results of the spectrophotometric assessment of color differences divided according to the results of the visual evaluation of color match

	Sample size	Color difference							P-value*
		Component	Mean ± SD	Range	95% CI (Mean)	Median	IQR	95% CI (Median)	
Clinically invisible	16	ΔE	5.34 ± 3.24	1.61 to 13.65	3.61; 7.06	4.53	3.86	3.48; 6.59	0.029 [†]
Clinically visible	24		8.06 ± 3.99	2.65 to 15.12	6.37; 9.74	7.81	6.42	4.79; 9.55	
Clinically invisible	16	ΔL	-0.47 ± 4.44	-9.60 to 6.73	-2.83; 1.90	-1.12	6.38	-3.47; 1.47	0.316
Clinically visible	24		-1.95 ± 4.59	-12.03 to 6.90	-3.89; -0.01	-2.27	6.48	-3.67; -0.20	
Clinically invisible	16	Δa	-1.78 ± 3.69	-11.43 to 3.70	-3.74; 0.19	-1.33	4.89	-3.17; 0.80	0.269
Clinically visible	24		-3.44 ± 5.69	-12.67 to 8.17	-5.84; -1.04	-3.27	9.33	-7.78; 0.57	
Clinically invisible	16	Δb	-0.38 ± 1.91	-3.93 to 3.23	-1.40; 0.65	-0.52	2.67	-1.80; 0.67	0.008 [†]
Clinically visible	24		-2.46 ± 2.54	-8.17 to 2.93	-3.54; -1.39	-2.47	3.00	-3.57; -1.03	

ΔE , total color difference; ΔL , difference of lightness; Δa , difference of chroma along red-green axis; Δb , difference of chroma along yellow-blue axis; SD, standard deviation; 95% CI (Mean), 95% confidence interval of the mean; IQR, interquartile range; 95% CI (Median), 95% confidence interval of the median.

*Results of t-test for the comparison between the groups with clinically invisible and visible color difference.

[†]Statistically significant.

Table 3. Results of soft tissue dimensions

	Mean ± SD	Range	95% CI (Mean)	Median	IQR	95% CI (Median)
MT (mm)	1.75 ± 0.41	0.90 to 2.70	1.62; 1.88	1.70	0.50	1.60; 1.90
GT (mm)	1.17 ± 0.22	0.80 to 1.70	1.09; 1.24	1.10	0.30	1.00; 1.20
Δ MT-GT (mm)	0.58 ± 0.36	-0.30 to 1.40	0.47; 0.70	0.65	0.40	0.50; 0.70
MM-AC (mm)	4.48 ± 1.24	1.60 to 8.90	4.08; 4.87	4.30	1.50	4.15; 4.70

MT, mucosal thickness; GT, gingival thickness; Δ MT-GT, difference between MT and GT; MM, mucosal margin; AC, alveolar crest; SD, standard deviation; 95% CI (Mean), 95% confidence interval of the mean; IQR, interquartile range; 95% CI (Median), 95% confidence interval of the median.

Table 4. Results of the spectrophotometric assessment of color differences divided according to the mucosal thickness

MT (mm)	Sample size	Color difference							P-value*
		Component	Mean ± SD	Range	95% CI (Mean)	Median	IQR	95% CI (Median)	
<1.5	6	ΔE	9.94 ± 4.50	4.88 to 15.12	5.22; 14.66	9.24	9.30	5.22; 15.10	0.064
1.5–2	23		6.93 ± 3.59	1.61 to 13.65	5.37; 8.48	6.59	5.78	4.24; 9.05	
>2	11		5.44 ± 3.61	1.77 to 14.68	3.02; 7.87	4.18	4.22	3.18; 7.41	
<1.5	6	ΔL	-3.59 ± 6.85	-12.03 to 6.73	-10.79; 3.60	-4.13	12.59	-10.65; 4.00	0.323
1.5–2	23		-1.43 ± 4.06	-9.60 to 6.33	-3.18; 0.33	-2.10	5.10	-3.53; -0.32	
>2	11		0.01 ± 3.91	-6.23 to 6.90	-2.62; 2.63	-0.40	5.87	-2.60; 3.27	
<1.5	6	Δa	-1.54 ± 7.09	-12.67 to 8.17	-8.98; 5.90	-2.55	10.48	-8.00; 5.93	0.908
1.5–2	23		-3.08 ± 4.95	-11.43 to 4.00	-5.22; -0.94	-1.40	10.49	-7.47; 1.07	
>2	11		-2.82 ± 4.18	-12.67 to 4.37	-5.62; -0.01	-2.13	10.50	-3.87; -0.87	
<1.5	6	Δb	-2.44 ± 4.01	-8.17 to 2.40	-6.65; 1.77	-2.60	7.34	-6.57; 1.85	0.848
1.5–2	23		-1.48 ± 2.55	-6.57 to 3.23	-2.59; -0.38	-1.80	4.27	-2.48; 0.03	
>2	11		-1.49 ± 1.29	-3.37 to 0.63	-2.36; -0.63	-1.90	1.60	-2.50; -0.90	

ΔE , total color difference; ΔL , difference of lightness; Δa , difference of chroma along red-green axis; Δb , difference of chroma along yellow-blue axis; SD, standard deviation; 95% CI (Mean), 95% confidence interval of the mean; IQR, interquartile range; 95% CI (Median), 95% confidence interval of the median.

*Results of Kruskal–Wallis test for the comparison between the groups with different mucosal thicknesses.

Table 5. Results of the spectrophotometric assessment of color differences divided according to the reconstructive material

	Sample size	Color difference							P-value*
		Component	Mean ± SD	Range	95% CI (Mean)	Median	IQR	95% CI (Median)	
All-ceramic	6	ΔE	4.84 ± 2.97	1.77 to 10.54	1.72; 7.96	4.12	2.91	2.84; 7.63	0.382
Metal–ceramic	9		7.05 ± 5.04	1.78 to 15.07	3.17; 10.92	4.79	9.68	2.99; 13.65	
Metal	23		7.25 ± 3.39	1.61 to 15.12	5.78; 8.72	7.44	5.41	5.66; 8.71	
All-ceramic	6	ΔL	-0.61 ± 3.05	-3.67 to 4.17	-3.80; 2.59	-1.00	5.76	-3.63; 2.82	0.157
Metal–ceramic	9		-4.00 ± 4.15	-12.03 to 1.53	-7.19; -0.81	-4.17	6.18	-6.77; -0.20	
Metal	23		-0.78 ± 4.62	-9.60 to 6.73	-2.78; 1.22	-1.43	6.73	-2.61; 1.27	
All-ceramic	6	Δa	-1.33 ± 4.49	-9.00 to 2.97	-6.04; 3.39	0.10	7.19	-6.43; 2.97	0.142
Metal–ceramic	9		-0.15 ± 5.69	-9.87 to 8.17	-4.54; 4.21	1.33	8.65	-7.47; 3.85	
Metal	23		-3.74 ± 4.38	-12.67 to 4.37	-5.63; -1.84	-3.20	7.45	-6.13; -1.08	
All-ceramic	6	Δb	-0.08 ± 2.21	-3.57 to 2.93	-2.24; 2.40	0.67	3.20	-2.37; 1.98	0.133
Metal–ceramic	9		-2.55 ± 2.39	-6.57 to 0.83	-4.39; -0.71	-1.80	3.77	-5.63; -1.03	
Metal	23		-1.79 ± 2.51	-8.17 to 3.23	-2.88; -0.71	-2.13	3.40	-2.52; -0.88	

ΔE , total color difference; ΔL , difference of lightness; Δa , difference of chroma along red-green axis; Δb , difference of chroma along yellow-blue axis; SD, standard deviation; 95% CI (Mean), 95% confidence interval of the mean; IQR, interquartile range; 95% CI (Median), 95% confidence interval of the median.

*Results of ANOVA for the comparison between the groups with different reconstructive materials.

teeth. These trials reported significant spectral differences with mean ΔE values ranging from 3.4 to 11, and lower L , a , and b values at implant sites in comparison with control teeth (Ishikawa-Nagai et al. 2007; Park et al. 2007; Jung et al. 2008; Sailer et al. 2009; Bressan et al. 2011; Paniz et al. 2014). The discrepancy between the data from different studies may be due to the differences in spectrophotometer, measurement protocol (e.g. location and surface of the region-of-interest), MT, and reconstructive material of the implant-supported restoration under investigation.

Under standardized laboratory conditions, the human eye is able to distinguish a color difference ΔE of 1 (Kuehni & Marcus 1979). For the intraoral evaluation of dental hard tissue, spectrophotometrically assessed color difference ΔE values in the range from 2 to 4 were reported as detection threshold (Johnston & Kao 1989; Douglas & Brewer 1998; Douglas et al. 2007; Yilmaz et al. 2009). In previous clinical investigations of the color of oral mucosa, the ΔE value of 3.7 (Johnston & Kao 1989) was generally considered as the limit of visibility (Jung et al. 2008; Sailer et al. 2009; Bressan et al. 2011; Benic et al. 2013; Buchi et al. 2014). A recent *in vitro* trial assessed the limit of gingival color detection by the human eye (Sailer et al. 2014). The colors of digital images of human gingiva were gradually modified and the images were randomly presented on a computer monitor. Dentists, dental technicians, and lay people assessed visible differences between the images. The overall threshold value ΔE amounted to 3.1. When considering the clinical relevance of mucosal discolorations, one has to take into account that color difference ΔE between natural gingiva at contralateral teeth was reported to measure 2.7 (Ishikawa et al. 1988).

In a recent clinical trial with 39 patients, the shade of the peri-implant mucosa was visually and spectrophotometrically compared with the shade of the gingiva at the adjacent tooth (Paniz et al. 2014). The visual inspection was performed by five dental professionals, which rated the peri-implant mucosa on a scale: grade 1 = perfect matching, grade 2 = good matching (distinguishable at intraoral examination), grade 3 = distinguishable at extraoral examination, but clinically acceptable, and grade 4 = clinically unacceptable. Eight sites were rated with median grade 1, 22 sites with median grade 2, and nine sites with median grade 3. The investigators found a significant correlation

between ΔE values and results of the visual inspection. The mean ΔE value amounted to 6.6 for the sites rated with grade 1, to 8.5 for the sites with grade 2, and to 15.5 for the sites rated with grade 3. The threshold value ΔE between perfect/good match (grades 1–2) and clinical visibility (grade 3) of the mucosal discoloration amounted to 8.7 (Paniz et al. 2014). These results are in accordance with the findings of the present investigation. In the current study, the mucosal discolorations were rated as “invisible” and “visible” from speaking distance. Therefore, both studies calculated the threshold for the visibility of mucosal discoloration at extraoral inspection. It is striking that the threshold values for the extraoral visibility of mucosal discolorations found in these two studies are significantly higher than the value generally considered as the limit of intraoral color distinction (Johnston & Kao 1989).

In the present investigation, 60% of the sites presented a mucosal discoloration that was visible from speaking distance. Interestingly, when comparing the sites with visible mucosal discoloration to those with invisible discoloration, a significant difference was found only regarding the chroma along yellow-blue axis. In the group with visible discoloration, peri-implant mucosa was significantly more bluish than the natural gingiva. On the other hand, in the group with non-perceptible discolorations, there were no differences in the blue color component between peri-implant mucosa and gingiva. It can, therefore, be hypothesized that the human eye is more sensible to the color differences in the blue direction compared to other directions of the color coordinate system. To our knowledge, this is the first study that compared the differences in the color components between the sites with visible and those with invisible peri-implant mucosal discoloration.

Various earlier spectrophotometric investigations found that the MT affected the degree of soft tissue discoloration caused by the color of the underlying reconstructive material or discolored tooth (Jung et al. 2007; Benic et al. 2013; Happe et al. 2013b; Pecnik et al. 2015). It was concluded that when MT exceeded 2 mm, the discoloration of mucosa caused by the underlying materials was below the ΔE threshold value of 3.7 (Jung et al. 2007; Pecnik et al. 2015). In accordance to these findings, in the present study, a statistical trend was found for the correlation between the MT and the spectrophotometrically assessed degree of mucosal discolorations. The peri-implant mucosa showed less discoloration in cases

with thicker soft tissue. However, there was no correlation between the MT and the results of the visual rating of color differences. Indeed, the sites with visible mucosal discolorations and those with invisible discolorations did not differ regarding the MT. In the previously mentioned clinical study that assessed extraoral visibility of mucosal discolorations, the sites with good color match presented more frequently a thick mucosal biotype compared to the sites with poor color match (Paniz et al. 2014).

One of the first clinical studies in this field compared metal–ceramic and all-ceramic implant-supported reconstructions with respect to the degree of peri-implant mucosal discoloration (Jung et al. 2008). It was concluded that all-ceramic reconstructions reveal better peri-implant mucosal color match to the natural gingiva. In other clinical studies, no difference in the mucosal discolorations was found between ceramic and metal abutments (Sailer et al. 2009; Bressan et al. 2011). In the present investigations, even though there was no statistical significance, a favorable trend in terms of less mucosal discolorations was observed for all-ceramic in comparison with metal–ceramic.

The main limitation of the present study is the fact that the visual rating of mucosal discoloration was performed only once for each site and that the patient cohort was examined by three clinicians. To reduce discrepancies in the assessment technique, a calibration meeting was held prior to the study start. For this purpose, digital photographs were visually assessed and the rating was discussed to aim for congruence. Nevertheless, the applied study design bears the risk of measurement inaccuracy due to the potentially low agreement of the visual rating. Ideally, multiple visual rating of each site is performed, permitting to control for inter- and intrarater agreement. As far as the clinical relevance of the findings from the present trial is concerned, it has to be taken into account that the perception of esthetic variations differ between lay people and dental professionals (Kokich et al. 1999; Gehrke et al. 2008; Sailer et al. 2014). Therefore, visual rating of the mucosa should have been performed by clinicians and by the patients.

Based on the findings of the present study, it can be deduced that visible mucosal discoloration can be expected at a large number of implants, with higher color discrepancies at sites with thin mucosa and those with metal abutments. According to the current knowledge, the mucosal discolorations can

clinically be reduced using two different approaches: improving the optical properties of the restorative material and surgically thickening the covering mucosa. This investigation provides relevant information regarding the perceptibility of mucosal color under clinical settings, and the differences between the sites with visible discolorations and those with invisible color differences. Further clinical investigations are needed to confirm the observations from the present trial. Future clinical research should investigate whether the human eye is more perceptible to the color differences of particular color components.

Conclusions

Within the limitations of the present study, it can be concluded that:

- Spectrophotometrically assessed color of the peri-implant mucosa revealed more dark, green and blue components in comparison with the natural gingiva.
- At 60% of the implants, peri-implant mucosal discoloration was visible from speaking distance.
- The sites with visible and those with invisible mucosal discolorations differed significantly only regarding the chroma along yellow-blue axis.
- The threshold value ΔE for the extraoral clinical distinction of mucosal color differences amounted to 7.5.
- Soft tissue thickness appeared a crucial factor with respect to the spectrophotometrically measured degree of peri-implant mucosal discoloration, with a trend for less pronounced discolorations in patients with thick mucosa. The sites

with visible and those with invisible mucosal discolorations did, however, not differ regarding the MT.

- Peri-implant MT was significantly correlated to the GT. On average, the peri-implant mucosa was 0.5–0.7 mm thicker than the natural gingiva.

Acknowledgements: The investigators gratefully acknowledge PhD Malgorzata Roos, Department of Biostatistics, University of Zurich, Switzerland, for assistance in analyzing the data. This study was supported by the Clinic of Fixed and Removable Prosthodontics and Dental Material Science, Center of Dental Medicine, University of Zurich, Switzerland, and by a research grant from the Swiss Dental Association (SSO).

References

- Belser, U., Buser, D. & Higginbottom, F. (2004) Consensus statements and recommended clinical procedures regarding esthetics in implant dentistry. *International Journal of Oral and Maxillofacial Implants* **19**(Suppl.): 73–74.
- Benic, G.I., Elmasry, M. & Hammerle, C.H. (2015) Novel digital imaging techniques to assess the outcome in oral rehabilitation with dental implants: a narrative review. *Clinical Oral Implants Research* **26** (Suppl. 11): 86–96.
- Benic, G.I., Mokti, M., Chen, C.J., Weber, H.P., Hammerle, C.H. & Gallucci, G.O. (2012a) Dimensions of buccal bone and mucosa at immediately placed implants after 7 years: a clinical and cone beam computed tomography study. *Clinical Oral Implants Research* **23**: 560–566.
- Benic, G.I., Wolleb, K., Hammerle, C.H. & Sailer, I. (2013) Effect of the color of intraradicular posts on the color of buccal gingiva: a clinical spectrophotometric evaluation. *International Journal of Periodontics and Restorative Dentistry* **33**: 733–741.
- Benic, G.I., Wolleb, K., Sancho-Puchades, M. & Hammerle, C.H. (2012b) Systematic review of parameters and methods for the professional assessment of aesthetics in dental implant research. *Journal of Clinical Periodontology* **39** (Suppl. 12): 160–192.
- Bressan, E., Paniz, G., Lops, D., Corazza, B., Romeo, E. & Favero, G. (2011) Influence of abutment material on the gingival color of implant-supported all-ceramic restorations: a prospective multicenter study. *Clinical Oral Implants Research* **22**: 631–637.
- Buchi, D.L., Sailer, I., Fehmer, V., Hammerle, C.H. & Thoma, D.S. (2014) All-ceramic single-tooth implant reconstructions using modified zirconia abutments: a prospective randomized controlled clinical trial of the effect of pink veneering ceramic on the esthetic outcomes. *International Journal of Periodontics and Restorative Dentistry* **34**: 29–37.
- CIE (2004) Commission internationale de l'éclairage (cie). Colorimetry, 3rd edn. Vienna, Austria: Central bureau of the cie. Publication CIE No. 15.3.
- Douglas, R.D. & Brewer, J.D. (1998) Acceptability of shade differences in metal ceramic crowns. *Journal of Prosthetic Dentistry* **79**: 254–260.
- Douglas, R.D., Steinhauer, T.J. & Wee, A.G. (2007) Intraoral determination of the tolerance of dentists for perceptibility and acceptability of shade mismatch. *Journal of Prosthetic Dentistry* **97**: 200–208.
- Esposito, M., Grusovin, M.G., Willings, M., Coulthard, P. & Worthington, H.V. (2007) Interventions for replacing missing teeth: different times for loading dental implants. *Cochrane Database Systematic Reviews* **18**: CD003878.
- Gehrke, P., Lobert, M. & Dhom, G. (2008) Reproducibility of the pink esthetic score – rating soft tissue esthetics around single-implant restorations with regard to dental observer specialization. *Journal of Esthetic Restorative Dentistry* **20**: 375–384; discussion 385.
- Gehrke, P., Riekeberg, U., Fackler, O. & Dhom, G. (2009) Comparison of in vivo visual, spectrophotometric and colorimetric shade determination of teeth and implant-supported crowns. *International Journal of Computerized Dentistry* **12**: 247–263.
- Hämmerle, C.H., Chen, S.T. & Wilson, T.G., Jr. (2004) Consensus statements and recommended clinical procedures regarding the placement of implants in extraction sockets. *International Journal of Oral and Maxillofacial Implants* **19** (Suppl.): 26–28.
- Happe, A., Schulte-Mattler, V., Strassert, C., Naumann, M., Stimmelmayer, M., Zoller, J.E. & Rothamel, D. (2013a) In vitro color changes of soft tissues caused by dyed fluorescent zirconia and nondyed, nonfluorescent zirconia in thin mucosa. *International Journal of Periodontics and Restorative Dentistry* **33**: e1–e8.
- Happe, A., Stimmelmayer, M., Schlee, M. & Rothamel, D. (2013b) Surgical management of peri-implant soft tissue color mismatch caused by shine-through effects of restorative materials: one-year follow-up. *International Journal of Periodontics and Restorative Dentistry* **33**: 81–88.
- Ishikawa, S., Nemoto, F., Furukawa, K. & Ishibashi, K. (1988) Colorimetric studies of the gingiva. Color variation of the gingiva in the upper anterior region. *Nihon Hotetsu Shika Gakkai Zasshi* **32**: 821–828.
- Ishikawa-Nagai, S., Da Silva, J.D., Weber, H.P. & Park, S.E. (2007) Optical phenomenon of peri-implant soft tissue. Part II. Preferred implant neck color to improve soft tissue esthetics. *Clinical Oral Implants Research* **18**: 575–580.
- Johnston, W.M. & Kao, E.C. (1989) Assessment of appearance match by visual observation and clinical colorimetry. *Journal of Dental Research* **68**: 819–822.
- Jung, R.E., Benic, G.I., Scherrer, D. & Hammerle, C.H. (2015) Cone beam computed tomography evaluation of regenerated buccal bone 5 years after simultaneous implant placement and guided bone regeneration procedures – a randomized, controlled clinical trial. *Clinical Oral Implants Research* **26**: 28–34.
- Jung, R.E., Holderegger, C., Sailer, I., Khraisat, A., Suter, A. & Hammerle, C.H. (2008) The effect of all-ceramic and porcelain-fused-to-metal restorations on marginal peri-implant soft tissue color: a randomized controlled clinical trial. *International Journal of Periodontics and Restorative Dentistry* **28**: 357–365.
- Jung, R.E., Sailer, I., Hammerle, C.H., Attin, T. & Schmidlin, P. (2007) In vitro color changes of soft tissues caused by restorative materials. *International Journal of Periodontics and Restorative Dentistry* **27**: 251–257.
- Kokich, V.O., Jr, Kiyak, H.A. & Shapiro, P.A. (1999) Comparing the perception of dentists and lay peo-

- ple to altered dental esthetics. *Journal of Esthetic Dentistry* **11**: 311–324.
- Kuehni, R.G. & Marcus, R.T. (1979) An experiment in visual scaling of small color differences. *Color Research & Application* **4**: 83–91.
- Paniz, G., Bressan, E., Stellini, E., Romeo, E. & Lops, D. (2014) Correlation between subjective and objective evaluation of peri-implant soft tissue color. *Clinical Oral Implants Research* **25**: 992–996.
- Park, S.E., Da Silva, J.D., Weber, H.P. & Ishikawa-Nagai, S. (2007) Optical phenomenon of peri-implant soft tissue. Part I. Spectrophotometric assessment of natural tooth gingiva and peri-implant mucosa. *Clinical Oral Implants Research* **18**: 569–574.
- Pecnik, C.M., Roos, M., Muff, D., Spolenak, R. & Sailer, I. (2015) In vitro color evaluation of esthetic coatings for metallic dental implants and implant prosthetic appliances. *Clinical Oral Implants Research* **26**: 563–571.
- Sailer, I., Fehmer, V., Ioannidis, A., Hammerle, C.H. & Thoma, D.S. (2014) Threshold value for the perception of color changes of human gingiva. *International Journal of Periodontics and Restorative Dentistry* **34**: 757–762.
- Sailer, I., Zembic, A., Jung, R.E., Siegenthaler, D., Holderegger, C. & Hammerle, C.H. (2009) Randomized controlled clinical trial of customized zirconia and titanium implant abutments for canine and posterior single-tooth implant reconstructions: preliminary results at 1 year of function. *Clinical Oral Implants Research* **20**: 219–225.
- Yilmaz, B., Ozcelik, T.B. & Wee, A.G. (2009) Effect of repeated firings on the color of opaque porcelain applied on different dental alloys. *Journal of Prosthetic Dentistry* **101**: 395–404.

Begleittext zur Publikation (equal contribution)

Von Daniela Scherrer

Zusammenfassung

Einleitung: Die natürliche und harmonische Erscheinung zahnärztlicher Rekonstruktionen und umliegender Weichgewebe ist ein wichtiger Erfolgsfaktor für zahnärztliche rekonstruktive Behandlungen im sichtbaren Mundbereich. Aus diesem Grund stellen pathologisch verursachte oder iatrogen induzierte Farb- und Formveränderungen der peri-implantären Mukosa ein klinisches Problem dar. Spektrophotometrie ist die meist genutzte Methode zur objektiven Farbbestimmung in der Zahnmedizin. Aus früheren spektrophotometrischen Studien ist bekannt, dass durch Veränderungen der optischen Eigenschaften der Rekonstruktionsmaterialien an Implantatversorgungen sowie durch Verdickung der Schleimhaut die Farbveränderung der peri-implantären Mukosa korrigiert werden können. Die klinische Relevanz des Farbunterschiedes ist letztlich abhängig davon, wie gross ein objektiver Farbunterschied sein kann ohne von Auge erkannt zu werden. In der Literatur sind die Grenzwerte für den Farbunterschied zwischen Zähnen besser dokumentiert als jene für den Farbunterschied zwischen Weichgeweben. Die wenigen Ergebnisse der bisherigen Studien liegen weit auseinander. Somit erscheint die klinische Relevanz spektrophotometrischer Farbbestimmungen der intraoralen Weichgewebe weitgehend unbekannt. Das Ziel der vorliegenden Studie war es, sowohl mittels eines Spektrophotometers als auch von Auge zu testen, ob ein Farbunterschied zwischen der peri-implantären Mukosa und der Gingiva an natürlichen Zähnen besteht.

Material und Methoden: Vierzig Einzelzahnimplantate in der Frontzahn- und Prämolarenregion wurden drei bis sieben Jahre nach der Implantation untersucht. Für jedes Implantat wurde der kontralaterale vitale Zahn als Referenz gewählt. Mit Hilfe eines Spektrophotometers wurde der bukkale Bereich der peri-implantären Mukosa am Studienimplantat und der Gingiva am entsprechenden Kontrollzahn erfasst. Die Farbmessung erfolgte 1 mm apikal des Mukosarandes am Studienimplantat bzw. des Gingivarandes am Kontrollzahn. Die erhaltenen Werte für die Farbkomponenten Helligkeit (L), Farbton entlang der Rot-Grün-Achse (a) und Farbton entlang der Gelb-Blau-Achse (b) wurden in einer Excel-Tabelle gesammelt. Der gesamte Farbunterschied (ΔE) zwischen dem peri-implantären Weichgewebe und der Gingiva am natürlichen Kontrollzahn wurde mit der Formel $\Delta E = [(L_{impl} - L_{contr})^2 + (a_{impl} - a_{contr})^2 + (b_{impl} -$

$b_{\text{contr}})^2]^{1/2}$ berechnet. Klinisch wurde der Farbunterschied zwischen peri-implantärer Mukosa und Gingiva am Kontrollzahn durch drei erfahrene Zahnärzte aus Sprechdistanz beurteilt. Der Farbunterschied wurde entweder als „klinisch sichtbar“ oder „klinisch unsichtbar“ bewertet. Anhand einer digitalen Volumetomografie (DVT) wurde die Dicke der peri-implantären Mukosa und der Gingiva an der umschriebenen Farbmessstelle ermittelt. Zusätzlich wurden sowohl die Höhe als auch die Dicke des Knochens an sämtlichen Studienimplantaten und Kontrollzähnen gemessen. Um die Weichgewebekontur in der DVT sichtbar zu machen, wurde vorgängig eine dünne Schicht des radioopaken Komposits auf die bukkale Schleimhaut des Implantates und des Kontrollzahnes angebracht und lichtgehärtet. Die DVT-Datensätze wurden mit einer CT-Visualisierungssoftware ausgemessen. Für die statistische Auswertung wurden die Fälle nach verschiedenen Kriterien gruppiert. Einerseits erfolgte eine Einteilung bezüglich der klinischen Bewertung in „klinisch sichtbar“ oder „klinisch unsichtbar“. Weiter wurden die Fälle nach der Dicke der peri-implantären Schleimhaut in 3 Gruppen (<0.5 mm; $0.5-1$ mm; >1 mm) unterteilt. Zudem wurden die Fälle nach dem Material, welches an der Farbmessstelle unterhalb der Schleimhaut liegt, in drei Gruppen unterteilt: Vollkeramik, Metallkeramik und Metall. Die statistische Auswertung wurde mit SPSS durchgeführt. In Abhängigkeit davon, ob Normalverteilung angenommen wurde, wurden entweder parametrische oder nicht-parametrische Verfahren angewendet. Für alle Variablen wurde die deskriptive Auswertung mit Mittelwert, Standardabweichung, 95%-Vertrauensintervall, Median und Range durchgeführt. Das nicht-parametrische Spearman-Verfahren wurde benutzt um Korrelationen zwischen verschiedenen Variablen zu erkennen. Zweiseitiger t-Test, ANOVA, Mann-Whitney- und Kruskal-Wallis-Tests wurden verwendet um Unterschiede zwischen den verschiedenen Gruppen festzustellen. Das Signifikanzniveau wurde auf 0.05 festgelegt.

Resultate: Der spektrophotometrisch ermittelte Farbunterschied ΔE zwischen peri-implantärer Mukosa und natürlicher Gingiva betrug 7.0 ± 3.9 . Die Auswertung der Farbkomponenten zeigte, dass die peri-implantäre Mukosa eine statistisch signifikant dunklere, grünlichere und bläulichere Verfärbung im Vergleich zum Zahnfleisch an den Kontrollzähnen präsentierte. Die klinische Untersuchung ergab in 60% (24/40) der Fälle einen sichtbaren Farbunterschied zwischen peri-implantärer Mukosa und natürlicher Gingiva. Der Grenzwert ΔE für die extraorale klinische Beurteilung von Schleimhautfarben betrug 7.5. Anders gesagt, wenn der objektive Farbunterschied grösser als 7.5 war, konnte die Farbabweichung von erfahrenen Zahnärzten klinisch

aus Sprechdistanz erkannt werden. Der Vergleich der Gruppe mit klinisch sichtbarem Farbunterschied und der Gruppe mit klinisch unsichtbarem Farbunterschied im Hinblick auf die drei Farbkomponenten L, a und b ergab nur einen statistisch signifikanten Unterschied für den Farbton entlang der Gelb-Blau-Achse. In der Gruppe mit extraoral erkennbarem Farbunterschied wies die peri-implantäre Mukosa eine bläuliche Verfärbung auf. Die Korrelationsanalyse zeigte, dass mit zunehmender Schleimhautdicke über dem Implantat oder Zahn tendenziell ein kleinerer Farbunterschied festzustellen war. Die Farbunterschiede zwischen den einzelnen Gruppen verschiedener Rekonstruktionsmaterialien waren statistisch nicht signifikant.

Schlussfolgerung: Die spektrophotometrische Analyse zeigte, dass die peri-implantäre Mukosa mehr dunkle, grüne und blaue Farbkomponenten enthielt im Vergleich zur Gingiva an natürlichen Zähnen. In 60% der Fälle war der Farbunterschied zwischen der peri-implantären Mukosa und der Gingiva an den Kontrollzähnen aus Sprechdistanz erkennbar. Die Implantate mit sichtbarer Schleimhautverfärbung und diejenigen mit nicht-sichtbarer Verfärbung unterschieden sich nur bezüglich des Farbtons entlang der Gelb-Blau-Achse.

Eigener Beitrag

Zu Beginn las ich mich mit Hilfe von wissenschaftlichen Artikeln aus PubMed in die Thematik ein. Die Fotoaufnahmen mit dem Spektrophotometer und die klinische Farbbeurteilung wurden von Dr. Manuel Sancho-Puchades, Dr. Goran I. Benic und PD Dr. Daniel S. Thoma durchgeführt. Ich führte die spektrale Analyse am Spektrophotometer selbständig durch und berechnete die Farbunterschiede wie oben beschrieben in Excel. Die DVT-Datensätze aller Studienteilnehmer importierte ich in eine 3D-Visualisierungssoftware. Damit nahm ich die Dimensionsmessungen an allen Implantaten und Kontrollzähnen vor. Alle Messungen der Farbunterschiede und der Hart- oder Weichgewebedimensionen in der DVT führte ich dreimal durch und übertrug jeweils den Mittelwert in SPSS. Mit demselben Programm nahm ich die statistische Analyse vor, wobei mir Frau Margrit Roos beratend zur Seite stand. Das Manuskript war von Anfang an zur Publikation vorgesehen, sodass ich es unter Anleitung von Dr. Goran I. Benic in englischer Sprache verfasste.

Nicht nur Verfärbungen, sondern auch Dimensionsdefizite des peri-implantären Weichgewebes beeinträchtigen den klinischen Erfolg von Implantatrekonstruktionen. Deshalb ist zur Beschreibung der Dimensionsunterschiede zwischen der Mukosa um

Implantatrekonstruktionen und der Gingiva um natürliche Zähne der gleichen Patientenkohorte ein zweites Manuskript vorgesehen. Das Ziel dieser Analyse ist es festzustellen, durch welche sekundären Parameter die apiko-koronale Position des peri-implantären Mukosasaumes beeinflusst wird. An Gipsmodellen bestimmte ich zusammen mit Dr. Goran I. Benic die ideale, apiko-koronale Position des marginalen Mukosasaumes bukkal am Implantat. Mit dieser Referenzposition ermittelte ich das Schleimhautdefizit bzw. den Schleimhautüberschuss am Studienimplantat, welches den primären Parameter darstellt. Die Messungen der sekundären Parameter erfolgten anhand von DVT und periapikalen Röntgenbildern. Die Publikation des zweiten Manuskriptes steht noch aus.