



---

Year: 2014

---

## **The most common complications after wisdom-tooth removal: Part 1: A retrospective study of 1,199 cases in the mandible**

Sigron, Guido R ; Pourmand, Pierre P ; Mache, Beatrice ; Stadlinger, Bernd ; Locher, Michael C

**Abstract:** The knowledge of potential complications after surgical removal of third molars and adequate risk assessment is indispensable in oral surgery. The present retrospective study analyzed the influence of different parameters, such as the patient's age and gender, retention type, and radiological projection (using orthopantomography) of wisdom teeth on the mandibular canal on postoperative complications after the removal of 1,199 wisdom teeth. Overall, 101 (8.4%) complications occurred: 50 cases of alveolar osteitis (4.2%), 12 temporary (1%) and 6 persistent (0.5%) sensation disorders, 15 abscesses (1.25%), 7 dehiscences (0.6%), 5 cases of post-operative bleeding (0.4%), 4 sequestra (0.32%), 1 fistula (0.08%) and 1 hematoma (0.08%). The risk for developing alveolar osteitis was 6% for patients who suffered from a previous pericoronar infection and was higher for female than male patients. Smoking showed no influence on alveolar osteitis. A significant correlation ( $p < 0.0001$ ) could be shown between the radiological projection of wisdom teeth on the mandibular canal and post-operative sensation disorders. The experience of the surgeon and pre-operative 3-dimensional imaging (cone-beam computed tomography, computed tomography) did not reduce this risk. No correlation was found for patient's age and gender. In conclusion, the surgical decision to remove wisdom teeth must be made with caution in cases of complete radiological projection of the wisdom tooth on the mandibular canal.

Posted at the Zurich Open Repository and Archive, University of Zurich

ZORA URL: <https://doi.org/10.5167/uzh-102777>

Journal Article

Published Version

Originally published at:

Sigron, Guido R; Pourmand, Pierre P; Mache, Beatrice; Stadlinger, Bernd; Locher, Michael C (2014). The most common complications after wisdom-tooth removal: Part 1: A retrospective study of 1,199 cases in the mandible. *Swiss Dental Journal*, 124(10):1042-1056.

Research · Science  
Forschung · Wissenschaft  
Recherche · Science

<b>Publisher</b> <b>Herausgeber</b> <b>Editeur</b>	<b>Editor-in-chief</b> <b>Chefredaktor</b> <b>Rédacteur en chef</b>	<b>Editors</b> <b>Redaktoren</b> <b>Rédacteurs</b>	<b>Assistant Editor</b> <b>Redaktions-Assistent</b> <b>Rédacteur assistant</b>
Schweizerische Zahnärzte- Gesellschaft SSO Société Suisse d'Odonto-Stomatologie CH-3000 Bern 7	Prof. Adrian Lussi Klinik für Zahnerhaltung, Präventiv- und Kinderzahnmedizin Freiburgstrasse 7 3010 Bern	Andreas Filippi, Basel Susanne Scherrer, Genève Patrick R. Schmidlin, Zürich	Simon Flury, Bern Klaus Neuhaus, Bern Brigitte Zimmerli, Bern

Articles published in this section have been reviewed by members of the Editorial Review Board.

Jede im Teil «Forschung und Wissenschaft» des SDJ eingereichte Arbeit wird von zahnärztlichen Fachpersonen begutachtet. Diese genaue Begutachtung macht es möglich, dass die Publikationen einen hohen wissenschaftlichen Standard aufweisen.

Ich bedanke mich bei den unten aufgeführten Kolleginnen und Kollegen für ihre wertvolle Mitarbeit, die sie in den vergangen zwei Jahren geleistet haben.

Adrian Lussi

M. Altenburger, Freiburg	K. W. Grätz, Zürich	H. T. Lübbbers, Zürich	P. R. Schmidlin, Zürich
N. Arweiler, Marburg	S. Hänni, Bern	H. -U. Luder, Männedorf	A. Sculean, Bern
T. Attin, Zürich	E. Hellwig, Freiburg	R. Männchen, Winterthur	R. Seemann, Bern
C. Besimo, Brunnen	I. Hitz Lindenmüller, Basel	C. Marinello, Basel	V. Suter, Bern
U. Blunck, Berlin	T. Imfeld, Zürich	G. Menghini, Zürich	U. Thüer, Meikirch
M. M. Bornstein, Lausanne	R. Jacobs, Leuven	A. Mombelli, Genève	J. Türp, Basel
D. Bosshardt, Bern	S. Janner, Bern	F. Müller, Genève	H. van Waes, Zürich
V. Chappuis, Bern	C. Katsaros, Bern	K. Neuhaus, Bern	T. von Arx, Bern
D. Dagassan-Berndt, Basel	J. Katsoulis, Bern	I. Nitschke, Zürich	C. Walter, Basel
S. Eick, Bern	N. Kellerhoff, Bern	C. Ramseier, Bern	T. Waltimo, Basel
T. Eliades, Zürich	S. Kiliaridis, Genf	S. Ruf, Giessen	R. Weiger, Basel
N. Enkling, Bern	K. Kislig, Bern	G. Salvi, Bern	M. Zehnder, Zürich
A. Filippi, Basel	A. Kruse, Zürich	M. Schätzle, Luzern	D. Zero, Indianapolis
S. Flury, Bern	K. Lädach, Bern	S. Scherrer, Genève	B. Zimmerli, Bern
A. Friedmann, Witten	J. T. Lambrecht, Basel	M. Schimmel, Bern	N. U. Zitzmann, Basel

GUIDO R. SIGRON  
PIÈRE P. POURMAND  
BEATRICE MACHE  
BERND STADLINGER  
MICHAEL C. LOCHER

Clinic for Dental and Orofacial  
Medicine and Maxillary Surgery,  
Polyclinic for Oral Surgery,  
Center for Dental Medicine,  
University of Zurich

#### CORRESPONDENCE

Dr. med. dent. Guido R. Sigron  
Klinik für Zahn-, Mund-  
und Kieferkrankheiten und  
Kieferchirurgie  
Poliklinik für Orale Chirurgie  
Universität Zürich  
Plattenstrasse 15  
8032 Zürich  
Tel. 044 634 32 90  
Fax 044 634 43 28  
E-mail: guido.sigron@  
zsm.uzh.ch

SWISS DENTAL JOURNAL SSO 124:  
1042–1046 (2014)  
Accepted for publication:  
13 November 2013

## The most common complications after wisdom-tooth removal

Part 1: A retrospective study of 1,199 cases in the mandible

#### KEYWORDS

Wisdom tooth,  
mandible,  
retention types,  
complication,  
nerve damage

#### SUMMARY

The knowledge of potential complications after surgical removal of third molars and adequate risk assessment is indispensable in oral surgery. The present retrospective study analyzed the influence of different parameters, such as the patient's age and gender, retention type, and radiological projection (using orthopantomography) of wisdom teeth on the mandibular canal on postoperative complications after the removal of 1,199 wisdom teeth. Overall, 101 (8.4%) complications occurred: 50 cases of alveolar osteitis (4.2%), 12 temporary (1%) and 6 persistent (0.5%) sensation disorders, 15 abscesses (1.25%), 7 dehiscences (0.6%), 5 cases of post-operative bleeding (0.4%), 4 sequestra (0.32%), 1 fistula (0.08%) and 1 hematoma (0.08%). The risk for developing alveolar osteitis

was 6% for patients who suffered from a previous pericoronar infection and was higher for female than male patients. Smoking showed no influence on alveolar osteitis. A significant correlation ( $p < 0.0001$ ) could be shown between the radiological projection of wisdom teeth on the mandibular canal and post-operative sensation disorders. The experience of the surgeon and pre-operative 3-dimensional imaging (cone-beam computed tomography, computed tomography) did not reduce this risk. No correlation was found for patient's age and gender. In conclusion, the surgical decision to remove wisdom teeth must be made with caution in cases of complete radiological projection of the wisdom tooth on the mandibular canal.

### Introduction

The removal of mandibular wisdom teeth – both erupted and retained – is one of the most common oral surgical procedures in the dental practice. Compared to a simple tooth extraction, however, the dentist must first perform more comprehensive pre-operative diagnostics using panoramic radiography and in some cases even cone-beam computer tomography (CBCT). The position of the wisdom tooth and the relationship to the mandibular canal must be known pre-operatively in order to assess

the risk of complications. With this knowledge, a risk-benefit analysis and optimal patient information can be conducted if surgery is indicated. A detailed overview of indications and contraindications for third-molar removal is given by JAQUIÉRY ET AL. (1994). In daily practice, the classification of the respective tooth by degree of difficulty into simple, advanced, and complex (SAC) has become established (SAILER & PAJAROLA 1996).

Regardless of the operative indication and degree of difficulty, the dentist should be familiar with the possible compli-

cations after wisdom-tooth removal and their frequency. However, most studies have only considered complications associated with surgical removals (OSBORN ET AL. 1985, BLACK 1997, ARRIGONI & LAMBRECHT 2004, VOEGELIN ET AL. 2008).

Thus, the aim of this study was to examine the type and frequency of complications after simple extractions and surgical removal of wisdom teeth. A total of 1,199 removed/extracted mandibular teeth were evaluated, including the influence of factors such as age, sex, retention type, and radiological projection (superimposition). The rate of complications was presented according to the SAC class of the removed/extracted tooth in order to determine whether a complex operation was associated with an increased risk. In addition, the possible relationship between the occurrence of temporary or permanently impaired sensation and the retention type as well as the radiological projection of the tooth on the mandibular canal was examined.

## Materials and Methods

In 2004, 1,199 mandibular third molars in 1,001 patients were extracted or surgically removed under local anesthesia at the Polyclinic for Oral Surgery at the University of Zürich. At that time, the sockets of all operatively removed teeth were left open and an iodine-vaseline drain was placed in them (SAILER & PAJAROLA 1994). The inclusion criteria were the Swiss Dental Society's fee schedule items 4201 (extraction of multi-rooted tooth, n=401), 4202 (extraction with separation, n=59), 4203 (extraction with flap operation, n=128), 4204 (extraction with flap operation and separation, n=57), 4206 (removal of a retained tooth, simple, n=383), 4207 (removal of a retained tooth, complex, n=171) for the removal of a mandibular third molar as well as the complete documentation including age, sex, radiographic findings using OPG or CT, surgery indication, surgical report, and follow-up progression.

On the OPG, all wisdom teeth were classified either as a retention type I–VII (SAILER & PAJAROLA 1994) or a normally erupted tooth based on the stage of root growth and the position. Further, the radiological projection of the wisdom tooth on the mandibular canal was examined and divided into 5 classes (none, at the superior border, half, complete, farther to caudal than inferior border). Existing complications were primarily divided into 8 main groups: alveolar osteitis (post-operative pain), impaired sensation, abscess, dehiscence, post-operative bleeding, sequestrum, fistula, and hematoma. Sensation disorders were further subdivided into type (anesthesia, hypesthesia, hyperesthesia, paresthesia), the nerve affected (N. alveolaris inferior, N. lingualis) and disorder progression (temporary, permanent).

The evaluation examined a possible relationship between sensation disorder and retention type as well as the radiological position of the tooth relative to the inferior alveolar nerve. Next, evaluation was performed according to ROOD & SHEHAB'S (1990) seven radiological signs of teeth with complete projection of the roots on the mandibular canal. ROOD & SHEHAB'S seven signs are: radiolucent root, curved root, constricted root, dark, split apex, interruption of the radiopaque superior line of the mandibular canal, change of direction of canal, constricted canal.

The data were entered into Microsoft Excel, subsequently graphically displayed using SPSS, and analyzed using single (Chi-square test) and multiple logistic regression analysis. The multiple logistic regression analysis was checked again, taking clustering into account, using STATA 10. The level of significance was set at  $p < 5\%$  (0.05).

## Results

Of 1,199 third molars, 569 (47.5%) were in the right mandible and 630 (52.5%) in the left. Overall, wisdom teeth were removed/extracted more frequently in men (54.5%) than in women (45.5%). The average age at the time of the operation was  $29 \pm 12$  years. Most of the teeth were removed prophylactically upon referral from a dentist or orthodontist in private practice. The rest were removed due to caries, impaired eruption (pericoronitis/abscess), cysts, and other reasons, e.g., as part of focal rehabilitation in tumor patients.

Table I shows the respective retention types I–VII relative to the degrees of difficulty (SAC) according to SAILER & PAJAROLA (1996). It was possible to classify 877 teeth. 210 teeth were not retained.

Radiological projection onto the mandibular canal was observed in 1,085 teeth. 387 (35.7%) teeth exhibited no such radiological projection, 355 (32.7%) were projected on the superior border, 179 (16.5%) were projected over half of the mandibular canal, and 120 (11%) did so completely. In 44 (4.1%) teeth, the root apices were farther to the caudal than the inferior border of the mandibular canal, and CTs were performed in 21 cases for definitive diagnosis. A total of 34 CTs were done.

A total of 101 (8.4%) complications arose in the 1,199 removed/extracted wisdom teeth. The most frequent complication was alveolar osteitis (n=50, 4.2%), followed by temporary (n=12, 1%) and permanent (n=6, 0.5%) sensation disorders, abscesses (n=15, 1.3%), dehiscence (n=7, 0.6%), post-operative bleeding (n=5, 0.4%) and other complications, such as formation of a sequestrum (n=4, 0.32%), fistula (n=1, 0.08%) or hematoma (n=1, 0.08%).

The risk of developing alveolar osteitis was relatively high (6%) in patients with pre-existing pericoronitis and was more common in women than men. No association between smoking and developing alveolar osteitis was found. The development of an abscess was most frequent in patients with pre-existing pain due to caries, pulpitis or apical periodontitis.

Temporary or permanent sensation disorders of the inferior alveolar nerve occurred more commonly (n=15, 1.25%) than

**Tab. I** Retention type distribution by degree of difficulty SAC (n=1,087)

<b>S(simple)</b>	<b>n</b>	<b>relF SD</b>
Type 0: tooth erupted along properly aligned axis	210	0.5
Type II: root growth 2/3 completed	83	0
Type III: retained tooth in normal position	515	2
<b>A(advanced)</b>	<b>n</b>	<b>relF SD</b>
Type I: tooth bud, crown formed	10	0
Type IV: tooth tipped to mesial	192	1
Type V: tooth tipped to distal	74	1.4
Type VI: tooth turned perpendicular to alveolar to alveolar process	1	0
<b>C(complex)</b>	<b>n</b>	<b>relF SD</b>
Type VII: highly aberrant tooth	2	0
S = simple, A = advanced, C = complex, relF SD = relative frequency of sensation disorder (in %)		

**Tab. II** Type and frequency of post-operative sensation disorder (n=1,199)

	NAI		NL	
	n (ri/le)	t/p	n (ri/le)	t/p
Anesthesia	0 (0/0)	0/0	2 (1/1)	0/2
Hypesthesia	12 (4/8)	8/4	0 (0/0)	0/0
Paresthesia	2 (1/1)	2/0	1 (0/1)	1/0
Hyperesthesia	1 (1/0)	1/0	0 (0/0)	0/0
Total	15 (6/9)	11/4	3 (1/2)	1/2

NAI = N. alveolaris inferior, NL = N. lingualis, t = temporary, p = permanent

those of the the lingual nerve (n=3, 0.25%). The left side was affected more frequently than the right, and in terms of the number of teeth removed and gender, more sensation disorders occurred in women (1.8%) than in men (1.2%). However, these differences were not statistically significant. Similarly, the patient's age and the retention type (I–VII) also had no influence on the development of a sensation disorder. Table II presents an overview of the affected nerves, type of damage and progression of the disorder (temporary or permanent).

The occurrence of sensation disorders was statistically significantly higher ( $p < 0.0001$ ) after removal of wisdom teeth whose OPG showed radiological projection on the inferior border of the mandibular canal. Figure 1 shows the relative frequency of sensation disorders in terms of the radiological projections of the root on the mandibular canal. The evaluation according to Rood's seven radiological signs showed no association of any criterion with the development of a sensation disorder. The radiolucent roots was by far the most common radiological finding, followed by the interruption of the radiopaque superior cortical line. Curved roots and changes of direction were less common.

In terms of progression, of the 18 (1.5%) sensation disorders of the inferior alveolar nerve or the lingual nerve, 12 (1%) were temporary and 6 (0.5%) were permanent. In 4 (0.35%) patients,

it was not possible to follow the progression after the first post-operative follow-up exam, since they did not attend further recall appointments. In these cases, the sensation disorder was presumed to be temporary.

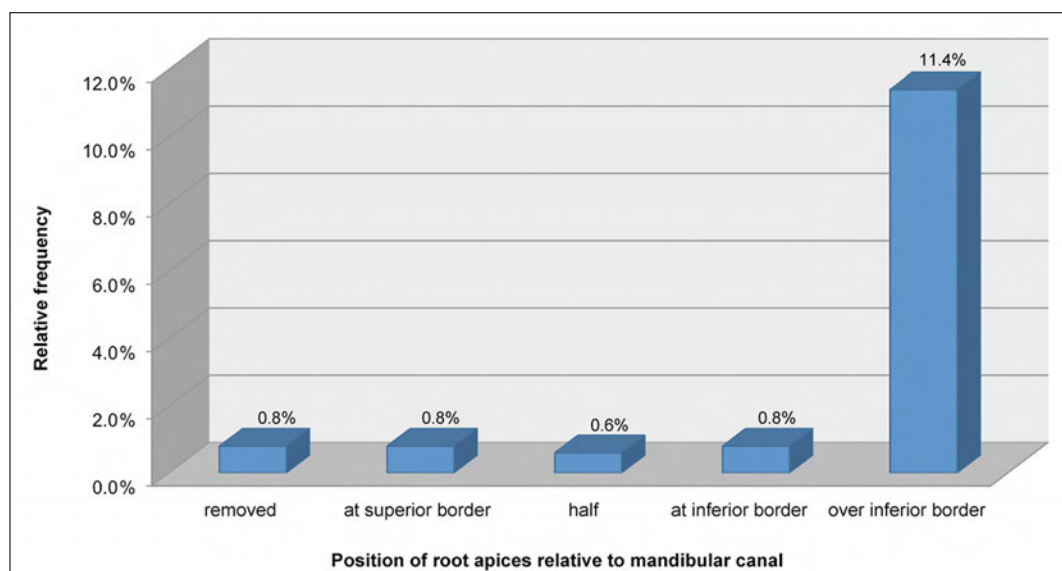
## Discussion

In this study, the overall complication rate after the removal of mandibular wisdom teeth was 8.4%, which agrees with the frequencies of 4.3% to 9.1% mentioned in the literature (CHIAPASCO ET AL. 1995, LOPES ET AL. 1995, BUI ET AL. 2003, BLONDEAU & DANIEL 2007).

The most frequent complication was alveolar osteitis (3.9%). In comparable studies, the alveolar osteitis rates were 2.6% (ARRIGONI & LAMPRECHT 2004), 2.7% (LOPES ET AL. 1995), 3.6% (BLONDEAU & DANIEL 2007) and 4.2% (VOEGELIN ET AL. 2008). In the present study, no relationship between smoking as a possible influencing factor and wound-healing disorders was observed. In contrast, ARRIGONI & LAMPRECHT (2004) reported an increased risk of infection in the fourth quadrant in patients who smoked.

The second most common complication (1.5%) was a post-operative temporary or permanent sensation disorder. In the literature, the frequency of this complication varies between 0.6% (OSBORN ET AL. 1985) and 14.1% (LOPES ET AL. 1995). Thus, the present results fall within the lower end of this range and are comparable with those of SAXER (1992), who evaluated the complication rate after removal of 1,342 mandibular third molars and found a 2.45% rate of sensation disorders. Table III shows the results of the present study compared with those of other authors.

The literature mentions various risk factors (age, local anesthetic, radiological signs, etc.) for sensation disorders, some of which are contentiously discussed. To date, there is no consensus on whether or not a correlation exists between a patient's age and developing a sensation disorder. In the present study, similar to BRANN ET AL. (1999) and REHMAN ET AL. (2002), no correlation between age and occurrence of a sensation disorder was found. However, other studies did observe such a relationship (GÜLICHER & GERLACH 2000, VALMASEDA-CASTELLÓN ET AL. 2001). CHIAPASCO ET AL. (1995) sought to determine the age after which the risk of complications from wisdom-tooth removal increases and found it to be 25 years. This was confirmed by



**Fig. 1** Relative frequency of a sensation disorder of the inferior alveolar nerve depending on root position/superimposition relative to the nerve.

**Tab. III** Frequency of sensation disorder compared to literature

	No. of cases	NAI		NL		NAI + NL	
	N	%	(t/p)	%	(t/p)	%	(t/p)
NEUMANN (2003)	1,320	0.23	(-/-)	0	(-/-)	0.23	(-/-)
OSBORN (1985)	1,6127	-	(-/-)	-	(-/-)	0.6	(-/-)
ARRIGONI (2004)	2,384	0.71	(0.71/0)	0.25	(0.21/0.04)	0.96	(0.92/0.04)
<b>Present study (2004)</b>	<b>1,199</b>	<b>1.25</b>	<b>(0.9/0.35)</b>	<b>0.25</b>	<b>(0.1/0.15)</b>	<b>1.5</b>	<b>(1/0.5)</b>
BLACK (1997)	3,848	1.2	(1.2/-)	0.9	(0.9/-)	2.1	(2.1/-)
SAXER (1992)	1,342	1.7	(1.7/-)	0.75	(0.75/-)	2.45	(2.45/-)
GÜLICHER (2000)	1,103	4.48	(3.57/0.91)	2.47	(2.1/0.37)	6.95	(5.67/1.28)
BATAINEH (2001)	741	3.9	(3.9/-)	2.6	(2.6/-)	6.5	(6.5/-)
JERJES (2006)	1,087	4.8	(4.1/0.7)	7.5	(6.5/1)	12.3	(10.6/1.7)
BRANN (1999)	718	-	(-/-)	-	(-/-)	13.4	(-/-)
LOPES (1995)	721	8.4	(8.4/-)	5.7	(5.7/-)	14.9	(14.1/1.2)

NAI = N. alveolaris inferior, NL = N. lingualis, t = temporary, p = permanent, - = no data

other authors (ARRIGONI & LAMBRECHT 2004, KUNKEL ET AL. 2006, BLONDEAU & DANIEL 2007, VOEGELIN ET AL. 2008). Based on these results, prophylactic removal of third molars should be performed between the ages of 17 and 24.

Besides the patient's age, meticulous radiological planning using OPG and, if necessary, CBCT is important for the successful removal of wisdom teeth. Using these imaging techniques, the position of the wisdom tooth – also in relation to the mandibular canal – must be analyzed. The significant correlation ( $p < 0.0001$ ) of the occurrence of post-operative sensation disorders with third molars radiologically shown to be superimposed on the inferior border of the mandibular canal emphasizes the importance of this analysis. The indication for CBCT is clearly given in this situation, since the spatial relationship between the tooth and the mandibular canal cannot be interpreted in two dimensions with any certainty (FLYGARE & OHMAN 2008) but is critical (KUNKEL ET AL. 2006). Routine CBCT or CT is not necessary, because in slightly displaced teeth, the therapeutic benefit is likewise slight (BETTER ET AL. 2004). In the present study, OPGs showed 164 wisdom teeth to be completely projected on the mandibular canal. A CT was done in just 31 cases, and 133 radiologically superimposed wisdom teeth were removed without first performing a CT. It should be mentioned that while conducting the study in 2004, CBCT was not yet available. Interestingly, only 2 cases (1.5%) in the group without CT had a sensation disorder, but 5 in the group with CT did so (16.1%). This confirms that despite CT or CBCT imaging and experienced operators, nerve damage cannot be completely prevented. Thus, given complete projection of the tooth on the mandibular canal, the indication for removal must be particularly strict.

To improve risk assessment, many authors have attempted to find radiological signs on the OPG which accompany increased risk of nerve damage (ROOD ET AL. 1990, BLAESER ET AL. 2003, RENTON ET AL. 2005). However, the present study could not confirm the seven radiological signs defined in the oft-cited and well-known study by ROOD & SHEHAB (1990) as an influencing

factor. Nevertheless, where these 7 criteria were absent after third-molar removal, the inferior alveolar nerve was rarely exposed (SEDAGHATFAR ET AL. 2005). It is noteworthy that when the mandibular canal is opened and the nerve exposed, sensation disorders occur only rarely (GÜLICHER & GERLACH 2000, TAY & GO 2004). In the current study, an exposed inferior alveolar nerve was explicitly described in only 6 of 15 cases of sensation disorder of the inferior alveolar nerve.

There is also some discussion about the influence of the local anesthetic and the anesthetization itself in sensation disorders. Currently, the literature shows that the use of articaine 4% and prilocaine as well as analog sedation or general anesthesia for wisdom-tooth removal markedly increases the risk of nerve damage (BRANN ET AL. 1999, GÜLICHER & GERLACH 2000, HILLERUP & JENSEN 2006, POGREL 2012). In the present study, two patients developed a temporary sensation disorder, although their wisdom teeth had exhibited no radiological projection on the inferior alveolar nerve. Hence, anesthesia cannot be ruled out as an influencing factor in these cases.

Other complications, such as abscesses and their sequelae or post-operative bleeding, were relatively infrequent. The risk of wound infection largely depends on pre-operative oral hygiene, the type of wound closure, and the patient's post-operative behavior. Open wound management including placing an iodine-vaseline drain results in markedly fewer infections than does closed wound management (SAILER & PAJAROLA 1996). However, due to the longer post-operative treatment period, the former procedure is no longer recommended. For this reason, today the Polyclinic for Oral Surgery uses half-open wound management and places a short iodine-vaseline drain (JACQUIÉRY ET AL. 1994). Pre-operative intraoral bacterial reduction by rinsing with chlorhexidine 0.12% for 2 minutes statistically significantly diminishes the risk of wound infection (HERMESCH ET AL. 1998, VEZEAU 2000, CASO ET AL. 2005), but perioral disinfection of the lips and facial skin provides no advantage (LOUKOTA 1991).

In the dental practice, the radiographs/CTs should first be carefully examined, then the wisdom teeth assigned to the ap-

appropriate SAC class. In surgically difficult situations, the operator should realistically assess his/her own surgical competence and, if necessary, refer the patient to an oral surgeon or oral maxillofacial surgeon.

## Résumé

En chirurgie orale, il est indispensable de connaître les éventuelles complications suivant l'extraction chirurgicale d'une troisième molaire et de pouvoir en évaluer les risques. La présente étude a permis d'évaluer l'influence de l'âge et du sexe du patient, du type de rétention et du chevauchement radiologique de la dent avec le canal mandibulaire sur les complications postopératoires de l'extraction de 1199 dents de sagesse. Au total, 101 (8,4%) complications ont été constatées: 50 alvéolites (4,2%), 12 troubles temporaires (1%) et 6 troubles perma-

nents de la sensibilité (0,5%), 15 abcès (1,25%), 7 déhiscences (0,6%), 5 hémorragies (0,4%), 4 séquestres (0,32%), 1 fistule (0,08%) et 1 hématome (0,08%). Les femmes ainsi que les personnes ayant souffert d'une périoronarite présentent un risque plus élevé de développer une alvéolite, alors que le tabagisme n'a montré aucune influence. Une corrélation significative ( $p < 0,0001$ ) a pu être établie entre une projection radiologique de la dent de sagesse au-delà de la partie inférieure du canal mandibulaire sur l'OPT et les troubles de la sensibilité. Aucune corrélation n'a été établie par rapport à l'âge et au sexe du patient. Par conséquent, lors d'une planification d'extraction d'une dent de sagesse présentant une projection radiologique sur l'OPT au-delà du canal mandibulaire inférieur, il est impératif de discuter avec le patient des risques plus élevés d'une lésion du nerf et des troubles de la sensibilité.

## References

- ARRIGONI J, LAMBRECHT J T: Komplikationen bei und nach operativer Weisheitszahnentfernung. *Schweiz Monatsschr Zahnmed* 114: 1271–1286 (2004)
- BATAINEH A B: Sensory nerve impairment following mandibular third molar surgery. *J Oral Maxillofac Surg* 59: 1012–1017 (2001)
- BETTER H, ABRAMOVITZ I, SHLOMI B, KAHN A, LEVY Y, SHAHAM A, CHAUSHU G: The presurgical workup before third molar surgery: how much is enough? *J Oral Maxillofac Surg* 62: 689–692 (2004)
- BLACK C G: Sensory impairment following lower third molar surgery: a prospective study in New Zealand. *N Z Dent J* 93: 68–71 (1997)
- BLAESER B F, AUGUST M A, DONOFF R B, KABAN L B, DODSON T B: Panoramic radiographic risk factors for inferior alveolar nerve injury after third molar extraction. *J Oral Maxillofac Surg* 61: 417–421 (2003)
- BLONDEAU F, DANIEL N G: Extraction of impacted mandibular third molars: postoperative complications and their risk factors. *J Can Dent Assoc* 73: 325 (2007)
- BRANN C R, BRICKLEY M R, SHEPHERD J P: Factors influencing nerve damage during lower third molar surgery. *Br Dent J* 186: 514–516 (1999)
- BUI C H, SELDIN E B, DODSON T B: Types, frequencies, and risk factors for complications after third molar extraction. *J Oral Maxillofac Surg* 61: 1379–1389 (2003)
- CASO A, HUNG L K, BEIRNE O R: Prevention of alveolar osteitis with chlorhexidine: a meta-analytic review. *Oral Surg Oral Med Oral Pathol Oral Radiol Endod* 99: 155–159 (2005)
- CHIAPASCO M, CRESCENTINI M, ROMANONI G: Germectomy or delayed removal of mandibular impacted third molars: the relationship between age and incidence of complications. *J Oral Maxillofac Surg* 53: 418–422; discussion 422–413 (1995)
- FLYGARE L, OHMAN A: Preoperative imaging procedures for lower wisdom teeth removal. *Clin Oral Investig* 12: 291–302 (2008)
- GÜLICHER D, GERLACH K L: Inzidenz, Risikofaktoren und Verlauf von Sensibilitätsstörungen nach operativer Weisheitszahnentfernung. *Mund Kiefer Gesichtschir* 4: 99–104 (2000)
- HERMESCH C B, HILTON T J, BIESBROCK A R, BAKER R A, CAIN-HAMLIN J, MCCLANAHAN S F, GERLACH R W: Perioperative use of 0.12% chlorhexidine gluconate for the prevention of alveolar osteitis: efficacy and risk factor analysis. *Oral Surg Oral Med Oral Pathol Oral Radiol Endod* 85: 381–387 (1998)
- HILLERUP S, JENSEN R: Nerve injury caused by mandibular block analgesia. *Int J Oral Maxillofac Surg* 35: 437–443 (2006)
- JAQUIÉRY C, PAJAROLA G F, SAILER H F, LAMBRECHT J T: Die Entfernung unterer retinierter Weisheitszähne (I). *Schweiz Monatsschr Zahnmed* 104: 1510–1519 (1994)
- JERJES W, SWINSON B, MOLES D R, EL-MAAYTAH M, BANU B, UPILE T, KUMAR M, AL KHAWALDE M, VOURVACHIS M, HADI H, KUMAR S, HOPPER C: Permanent sensory nerve impairment following third molar surgery: a prospective study. *Oral Surg Oral Med Oral Pathol Oral Radiol Endod* 102: e1–7 (2006)
- KUNKEL M, BECKER J, BOEHME P, ENGEL P, GOZ G, HAESSLER D, HEIDEMANN D, HELLWIG E, KOPP I, KREUSSER B, LAUER H C, LUCKEY H, REINHARD E, SCHOPF P, SINGER R, TERHEYDEN H, TURP J C, WEBER M, WEINGART D, WERKMEISTER R, WAGNER W: Operative Entfernung von Weisheitszähnen. *Mund Kiefer Gesichtschir* 10: 205–211 (2006)
- KUNKEL M, MORBACH T, KLEIS W, WAGNER W: Third molar complications requiring hospitalization. *Oral Surg Oral Med Oral Pathol Oral Radiol Endod* 102: 300–306 (2006)
- LOPES V, MUMENYA R, FEINMANN C, HARRIS M: Third molar surgery: an audit of the indications for surgery, post-operative complaints and patient satisfaction. *Br J Oral Maxillofac Surg* 33: 33–35 (1995)
- LOUKOTA R A: The effect of pre-operative perioral skin preparation with aqueous povidone-iodine on the incidence of infection after third molar removal. *Br J Oral Maxillofac Surg* 29: 336–337 (1991)
- NEUMAN F: Der Einfluss des chirurgischen Vorgehens zum Schutz des Nervus lingualis bei der Entfernung unterer Weisheitszähne: eine prospektive Studie. *Med Diss, Greifswald* (2003)
- OSBORN T P, FREDERICKSON G JR., SMALL I A, TORGERTSON T S: A prospective study of complications related to mandibular third molar surgery. *J Oral Maxillofac Surg* 43: 767–769 (1985)
- POGREL M A: Permanent nerve damage from inferior alveolar nerve blocks: a current update. *J Calif Dent Assoc* 40: 795–797 (2012)
- REHMAN K, WEBSTER K, DOVER M S: Links between anaesthetic modality and nerve damage during lower third molar surgery. *Br Dent J* 193: 43–45 (2002)
- RENTON T, HANKINS M, SPROATE C, MCGURK M: A randomised controlled clinical trial to compare the incidence of injury to the inferior alveolar nerve as a result of coronectomy and removal of mandibular third molars. *Br J Oral Maxillofac Surg* 43: 7–12 (2005)
- ROOD J P, SHEHAB B A: The radiological prediction of inferior alveolar nerve injury during third molar surgery. *Br J Oral Maxillofac Surg* 28: 20–25 (1990)
- SAILER H F, PAJAROLA G F: Retinierte Zähne. In: Rateitschak K H, Wolf H F (Herausgeber): *Farbatlanten der Zahnmedizin* 11, *Orale Chirurgie*. Thieme, Stuttgart, pp. 71–140 (1996)
- SAXER J: Die operative Entfernung des unteren Weisheitszahnes unter spezieller Berücksichtigung iatrogenen Läsionen des Nervus alveolaris inferior und des Nervus lingualis. *Med Diss, Zürich* (1992)
- SEDAGHATFAR M, AUGUST M A, DODSON T B: Panoramic radiographic findings as predictors of inferior alveolar nerve exposure following third molar extraction. *J Oral Maxillofac Surg* 63: 3–7 (2005)
- TAY A B, GO W S: Effect of exposed inferior alveolar neurovascular bundle during surgical removal of impacted lower third molars. *J Oral Maxillofac Surg* 62: 592–600 (2004)
- VALMASEDA-CASTELLON E, BERINI-AYTES L, GAY-ESCOODA C: Inferior alveolar nerve damage after lower third molar surgical extraction: a prospective study of 1117 surgical extractions. *Oral Surg Oral Med Oral Pathol Oral Radiol Endod* 92: 377–383 (2001)
- VEZEAU P J: Dental extraction wound management: medicating postextraction sockets. *J Oral Maxillofac Surg* 58: 531–537 (2000)
- VOEGELIN T C, SUTER V G, BORNSTEIN M M: Komplikationen während und nach chirurgischer Entfernung unterer Weisheitszähne. Einfluss von Patientenprofil und Anatomie. *Schweiz Monatsschr Zahnmed* 118: 192–198 (2008)