



**University of
Zurich**^{UZH}

**Zurich Open Repository and
Archive**

University of Zurich
Main Library
Strickhofstrasse 39
CH-8057 Zurich
www.zora.uzh.ch

Year: 2014

Standards of care and novel approaches in the management of glioblastoma multiforme

Hottinger, Andreas F; Stupp, Roger; Homicsko, Krisztian

Abstract: Glioblastoma multiforme (GBM) is the most common malignant primary brain tumor in adults. Standard therapeutic approaches provide modest improvement in the progression-free and overall survival, necessitating the investigation of novel therapies. We review the standard treatment options for GBM and evaluate the results obtained in clinical trials for promising novel approaches, including the inhibition of angiogenesis, targeted approaches against molecular pathways, immunotherapies, and local treatment with low voltage electric fields.

DOI: <https://doi.org/10.5732/cjc.013.10207>

Posted at the Zurich Open Repository and Archive, University of Zurich

ZORA URL: <https://doi.org/10.5167/uzh-107891>

Journal Article

Published Version

Originally published at:

Hottinger, Andreas F; Stupp, Roger; Homicsko, Krisztian (2014). Standards of care and novel approaches in the management of glioblastoma multiforme. *Chinese Journal of Cancer*, 33(1):32-39.

DOI: <https://doi.org/10.5732/cjc.013.10207>

Review

Standards of care and novel approaches in the management of glioblastoma multiforme

Andreas F. Hottinger^{1,3}, Roger Stupp² and Krisztian Hombicsko³

Abstract

Glioblastoma multiforme (GBM) is the most common malignant primary brain tumor in adults. Standard therapeutic approaches provide modest improvement in the progression-free and overall survival, necessitating the investigation of novel therapies. We review the standard treatment options for GBM and evaluate the results obtained in clinical trials for promising novel approaches, including the inhibition of angiogenesis, targeted approaches against molecular pathways, immunotherapies, and local treatment with low voltage electric fields.

Key words Glioblastoma multiforme, treatment, targeted agents, angiogenesis, electric fields, immunotherapy

With a yearly incidence of 3/100,000–4/100,000, glioblastoma multiforme (GBM) is the most common malignant primary brain tumor in adults. Despite modern treatments with the current standard of care, the outcome of GBM patients remains poor with a median life expectancy of 15–17 months^[1]. Fewer than 16% of patients survive more than 3 years^[2]. Novel therapeutic approaches are needed to improve the outcome of these patients. An improved understanding of molecular biology and cancer genomics has led to the identification of a number of mutated genes and abnormalities in signaling pathways. The key role of the microenvironment, especially of tumor angiogenesis, has also been elucidated and may provide avenues for future therapeutic options. This review focuses on the current standards of care and highlights novel therapeutic approaches for the treatment of GBM.

Current Standard Treatment Options for GBM

GBMs are highly invasive tumors that are surrounded by peritumoral edema and inflammation. Due to their highly aggressive nature, the tumor margins of GBMs are unclear, and GBMs are therefore usually not amenable to complete resection. Nevertheless, surgical resection remains the first step in the management

of GBM to the extent that it is safely feasible. Tumor resection allows for pathologic confirmation of the diagnosis and relieves compressed brain structures (**Figure 1**). As of 2005, the addition of chemotherapy to radiation has become the first-line treatment for GBM. Temozolomide (TMZ, Temodal, Temodar[®], MSD, Merck & Co, Whitehouse Station, NJ, USA), an alkylating cytotoxic agent, is administered orally on a daily basis at a dose of 75 mg/m² throughout radiotherapy. Four weeks later, magnetic resonance imaging (MRI) is repeated, and TMZ is then given at a dose of 150–200 mg/m² daily for 5 days every 28 days for maintenance. MRIs are performed after every 2–3 cycles of TMZ treatment to ensure continuous stability or response of the tumor to treatment (**Figure 2**). In comparison to radiotherapy alone, in a large, randomized phase III trial, TMZ treatment along with radiotherapy resulted in an improved median overall survival (OS) from 12.1 to 14.6 months and an increase in the 2-year survival rate from 10% to 27%^[1,3], and this finding has since been confirmed by additional reports. In an unplanned analysis of a representative subgroup of patients, it was shown that the addition of TMZ mainly benefited patients with a methylated O-6-methylguanine-DNA methyltransferase (*MGMT*) gene promoter^[4]. *MGMT* is a DNA repair protein that reverses the damage induced by alkylating chemotherapy agents. Methylation of the gene promoter results in decreased expression of this enzyme and thus renders tumor cells more susceptible to alkylating agents.

As elderly patients with GBM are considered to have a particularly poor prognosis, many clinical trials have been restricted to patients less than 65–70 years of age. The benefit of radiotherapy in elderly patients was confirmed in a randomized trial comparing radiotherapy to best supportive care alone. The median OS increased from 3.9 to 6.9 months with radiotherapy and resulted in a better quality of life^[5]. For elderly patients, hypofractionated radiotherapy administered over 15 days (34 Gy in 3.4 Gy fractions^[6] or 40 Gy in 15 daily fractions

Authors' Affiliations: ¹Department of Clinical Neuroscience, ²Department of Oncology, Lausanne University Hospital, Lausanne 1011, Switzerland; ³Department of Oncology, Zurich University Hospital, Zurich CH-8091, Switzerland.

Corresponding Author: Andreas F. Hottinger, Department of Clinical Neurosciences, Lausanne University Hospital, Rue du Bugnon 46, Lausanne 1011, Switzerland. Tel: +41-21-3146541; Fax: +41-21-3140737; Email: andreas.hottinger@gmail.com.

doi: 10.5732/cjc.013.10207

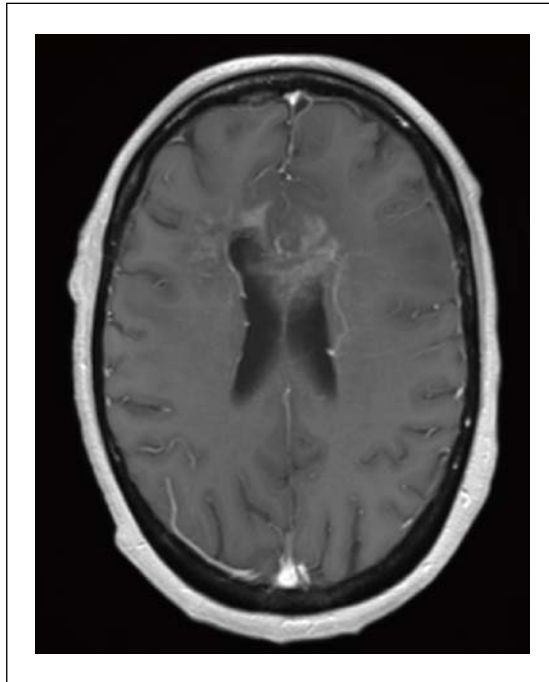


Figure 1. T1 post gadolinium sequence of magnetic resonance imaging (MRI) of a 46-year-old patient with a butterfly glioblastoma multiforme (GBM) invading the corpus callosum.

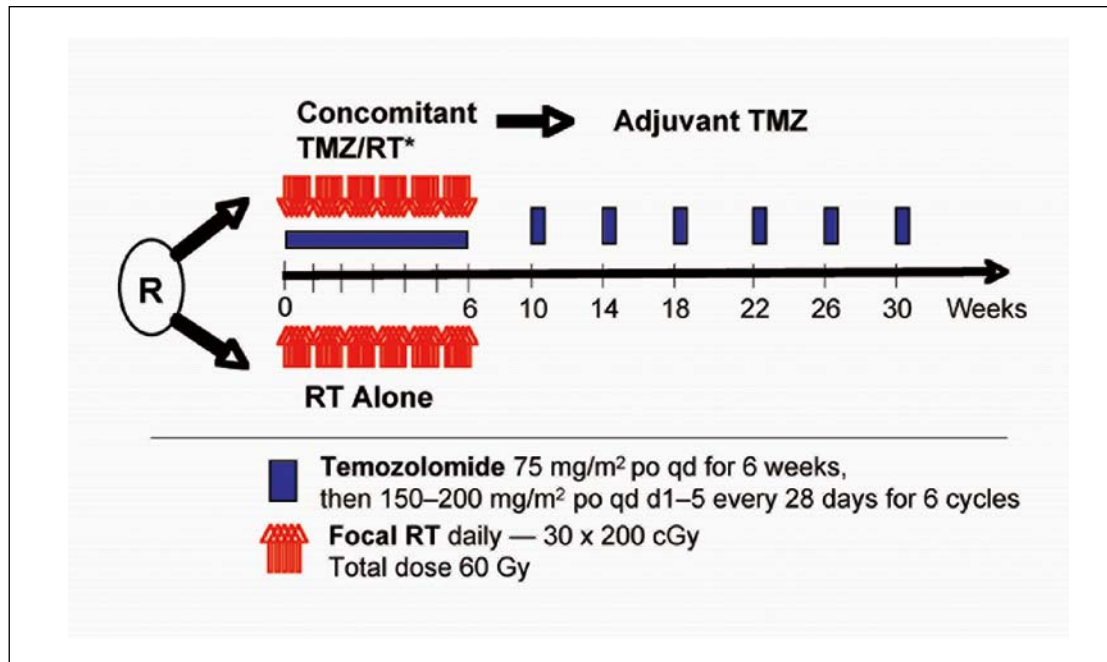


Figure 2. The standard treatment regimen for GBM that combines radiotherapy (RT) with temozolomide (TMZ). *Prophylaxis against *Pneumocystis Jirovecii* was required for patients undergoing TMZ treatment during the concomitant phase.

of 2.6 Gy^[7]) was shown to result in equivalent outcome to standard radiotherapy (30 fractions of 2 Gy)^[7]. Two recent phase III studies with the objective of avoiding radiation-induced toxicity and allowing for an easy and better tolerated oral treatment for more vulnerable

elderly patients compared radiotherapy with TMZ chemotherapy alone. These 2 trials showed that in elderly patients, there was no significant difference in the outcome of patients undergoing standard radiotherapy, hypofractionated radiotherapy, or TMZ alone. However,

patients with methylated *MGMT* benefited significantly when treated with TMZ alone rather than radiotherapy, whereas patients with an unmethylated *MGMT* gene promoter treated with TMZ alone fared worse^[6,8]. The National Cancer Institute of Canada (NCIC) and European Organisation for Research and Treatment of Cancer (EORTC) are currently conducting a phase III trial to evaluate a short course of radiotherapy alone administered over 3 weeks versus the combination of the same course of radiotherapy with TMZ in patients over 65 years of age that are not candidates to undergo the standard chemoradiotherapy with TMZ (clinicaltrials.gov: NCT00482677).

Novel Targeted Therapies for Glioblastoma

Antiangiogenesis

Vascular epithelial growth factor-A (VEGF-A) is a major regulator of angiogenesis and can be detected in high amounts in GBM^[9]. It plays a critical role in endothelial cell proliferation in GBM^[9]. Vascular epithelial growth factor receptor-2 (VEGFR-2) is overexpressed by 3- to 5-fold in tumor endothelial cells compared to that in normal endothelial tissue^[10]. Overproduction of VEGF may explain, in part, dysfunction of the blood-brain barrier as well as edema and hemorrhagic areas in GBM^[11].

Therapies targeting VEGF have been widely tested in clinical trials in GBM patients (**Table 1**). Cediranib (Recentin™, AstraZeneca, Wilmington, DE, USA) is a small-molecule tyrosine kinase inhibitor that targets VEGFR. In a randomized, 3-arm phase III trial of recurrent GBM, lomustine alone showed a similar progression-free survival (PFS) rate to cediranib alone [hazard ratio (HR) = 1.05; 95% confidence interval (CI), 0.74 to 1.50; *P* = 0.90] or to dual treatment with cediranib and lomustine (HR = 0.76; 95% CI, 0.53 to 1.08; *P* = 0.16)^[12]. Moreover, cediranib was associated with increased tumor infiltration in a phase II trial in recurrent GBM^[13]. Aflibercept (Zaltrap, Sanofi and Regeneron Pharmaceuticals, Tarrytown, NY, USA), a

recombinant fusion protein, is able to bind to and sequester VEGF-A, VEGF-B, and placental growth factor (PGF). In a phase II study, the objective response rate (ORR) of recurrent GBM patients to aflibercept was reported at 24%, whereas the 6-month PFS rate was only 7.7%, suggesting minimal antitumor activity of the compound^[14].

Bevacizumab (Bev; Avastin®, Roche Basel, Switzerland) is a humanized monoclonal antibody directed against VEGF. Several trials aimed at studying the effects of Bev, either alone or in combination with chemotherapeutic agents, have been performed. Two studies led to the conditional approval of Bev by the US Food & Drug Administration (FDA). In a phase II study of 35 patients, in combination with the topoisomerase I inhibitor irinotecan, Bev showed a 6-month PFS rate of 46% and a median OS of 42 weeks, and 11% of the patients were alive after 4 years^[15,16]. In a randomized phase II trial that included 167 patients with recurrent glioblastoma, the irinotecan-Bev arm showed a 6-month PFS rate of 50.3% and a median OS of 8.9 months; in the Bev only arm, the results were similar, with a 6-month PFS rate of 42.6% and a median OS of 9.3 months^[17]. In contrast to the United States, the European Medicines Agency (EMA) rejected the approval of Bev based on the lack of controlled data. The results of the Avaglio and Radiation Therapy Oncology Group (RTOG) 0825 trials were presented at the 2013 Annual Meeting of the American Society of Clinical Oncology (ASCO)^[15,18]. Both phase III studies evaluated the addition of Bev to standard radiotherapy and TMZ compared with standard chemoradiotherapy alone in patients with newly diagnosed GBM. Both the Avaglio and RTOG trials, which enrolled 921 and 637 GBM patients, respectively, showed an increase in PFS from 6.2 to 10.6 months (*P* ≤ 0.001) and from 7.3 to 10.7 months (considered non-significant as it did not meet the prespecified difference), respectively. In contrast, median OS was not significantly different (16.8 vs. 16.7 months in the Avaglio trial and 15.7 vs. 16.1 months in the RTOG trial, *P* > 0.05). Interestingly, although the Avaglio trial suggested more favorable quality of life outcomes in patients treated with Bev, the RTOG 0825 trial suggested that patients under Bev treatment

Table 1. MicroRNAs (miRNAs) associated with epithelial-mesenchymal transition (EMT)

Agent	Class	Target	Clinical trials	Comments
Bevacizumab	Anti-VEGF antibody	VEGF	Phase II, recurrent; phase II & III, initial	Approved by the US FDA and Swissmedic for recurrent GBM
Cediranib (Recentin)	Small-molecule	VEGFR, PDGFR, FGFR1, c-KIT	Phase I & II, initial; phase III, recurrent	No effect in a multicentric phase III study
Vatalanib (PTK787)	Small-molecule	VEGFR, c-KIT, PDGFR	Phase I & II, initial and recurrent	Minimal efficacy
Aflibercept	Protein, 97 kDa	VEGF Trap	Phase I & II, initial and recurrent	Minimal efficacy
Cilengitide	Peptide	Alphav integrin inhibitor, antiangiogenesis	Phase II & III	Phase III trial in newly diagnosed GBM showed no efficacy

VEGF, vascular epithelial growth factor; VEGFR, vascular epithelial growth factor receptor; PDGFR, platelet-derived growth factor receptor; FGFR1, fibroblast growth factor receptor 1; FDA, Food & Drug Administration; GBM, glioblastoma multiforme.

showed a significantly worse neurocognitive outcome.

In summary, VEGF- or VEGFR-targeted treatments have failed to demonstrate a benefit in OS in patients with GBM. The discrepancy between improved PFS and unchanged OS that was observed in most trials targeting VEGF inhibition has raised some questions. It has been postulated that antiangiogenic agents can transiently “normalize” the abnormal structure and function of tumor vasculature, improving its efficiency to deliver blood and oxygen and reducing intratumoral fluid pressure (IFP) and peritumoral edema. This aspect is certainly important to reduce edema-induced neurologic deficits and allows for the reduction or replacement of steroid treatments. It has also been postulated that this might improve drug delivery to the tumor. To date, however, combination treatments with chemotherapeutic and antiangiogenic agents have not resulted in improved survival in comparison to treatment with single antiangiogenic agents^[17,19-21]. Experiments in animal models have suggested that Bev may affect tumor cell invasion. In a xenograft model using the GBM U87MG cell line, Bev treatment resulted in an increased invasiveness of tumor cells^[22]. Initially, it was suggested that this increased invasiveness was observed frequently^[23]; however, this has not been confirmed in a large review analyzing patterns of progression following treatment with Bev^[24].

Inhibition of integrins

Integrins are heterodimeric transmembrane cell surface receptors that play a major role in the interaction between the cell and its surrounding stroma. They regulate some key processes such as cell adhesion, differentiation, proliferation, survival, control of inflammation, and modulation of signaling pathways including platelet-derived growth factor (PDGF), epidermal growth factor (EGF), and VEGF. The members of the integrin family alphaVbeta3 and alphaVbeta5 are overexpressed in both the tumor cells and the vasculature of GBM. Cilengitide (Merck KGaA, Darmstadt,

Germany) is a selective inhibitor of these integrins and has been extensively evaluated in GBM. Patients with *MGMT* gene promoter methylation appeared to derive the greatest benefit. Several phase II studies have suggested a more favorable outcome in patients treated with higher doses of cilengitide in recurrent GBM as well as a favorable comparison with historical controls with newly diagnosed GBM (especially those with methylated *MGMT*)^[25-27]. Based on these findings, a large phase III trial was initiated by Merck in collaboration with the EORTC in patients with newly diagnosed GBM and *MGMT* promoter methylation. No activity for cilengitide could be demonstrated in this trial, and further development of the compound was discontinued.

Inhibition of growth factor receptors and intracellular signaling pathways

Amplification and overexpression of epidermal growth factor receptor (EGFR) are observed in approximately 50% of GBM cases^[28]. Several compounds directed against EGFR function have been evaluated (**Table 2**). For instance, gefitinib (Iressa; AstraZeneca, Wilmington, DE, USA) induced a partial response in 12.7% of recurrent GBM cases in a phase II study^[29]. However, the 6-month PFS rate was merely 13%, and the median OS was 10 months, which is identical to the expected outcome in GBM patients undergoing non-efficient therapies^[29,30]. When associated with radiotherapy, TMZ, or other agents, erlotinib (Tarceva, Genentech and OSI pharmaceuticals, Long Island, NY, USA), another EGFR inhibitor, also failed to show any positive effect on PFS and OS in patients with recurrent or newly diagnosed GBM^[31]. Despite adequate distribution into tumor tissue, lapatinib (Tyverb, GlaxoSmithKline, Brentford, United Kingdom), a dual HER2 and EGFR inhibitor, failed to show any efficacy in a phase II trial^[32]. The chimeric monoclonal antibody cetuximab, which inhibits EGFR, also showed minimal efficacy, even when patients were stratified according to the amplification of EGFR

Table 2. Selected targeted agents evaluated in GBM patients

Agent	Class	Target	Clinical trials	Comments
Erlotinib (Tarceva)	Small-molecule	EGFR	Phase II, initial and recurrent	Minimal efficacy
Gefitinib (Iressa)	Small-molecule	EGFR	Phase II, recurrent	Minimal efficacy
Lapatinib (Tyverb)	Small-molecule	EGFR, ErbB2	Phase II, recurrent	No efficacy
Cetuximab	Chimeric antibody	EGFR	Phase I & II, initial and recurrent	Minimal efficacy
Imatinib (Gleevec)	Small-molecule	PDGFR, c-KIT, BCR-ABL	Phase I & II, recurrent	Minimal efficacy
Enzastaurin	Small-molecule	PKC, PI3K/AKT pathway inhibitor	Phase I, II & III, initial and recurrent	Limited efficacy. Phase III trial in recurrent GBM discontinued early as Enzastraurin was found inferior to lomustin
Temsirolimus (Torisel)	Small-molecule	mTOR inhibitor	Phase I & II, initial and recurrent	Limited efficacy as single agent

EGFR, epidermal growth factor receptor; PKC, protein kinase C; PI3K/AKT, phosphatidylinositide 3-kinase/protein kinase B; mTOR, mammalian target of rapamycin. Other abbreviations as in Table 1.

and when combined with irinotecan and Bev^[33,34].

In the proneural subtype of GBM, platelet-derived growth factor receptor (PDGFR) is often activated and overexpressed^[35]. Activation of the PDGF pathway stimulates GBM growth and angiogenesis^[36]. Imatinib (Glivec; Novartis, Basel Switzerland) is a kinase inhibitor of PDGFR, c-KIT, and the oncogene fusion protein BCR-ABL. In a phase II study in recurrent GBM that stratified patients by their PDGFR expression, a 6-month PFS rate of merely 3% was reported^[37]. Several other multicenter trials also failed to show efficacy of imatinib alone or in combination with hydroxyurea^[38,39].

As illustrated above, to date, agents targeting a single specific pathway have failed to demonstrate consistent improvement in the outcome of patients with GBM. This might be due to several reasons. First, the selected agents are not sufficient to induce significant inhibition. Second, although efficient, the agents are not able to reach their target in at a sufficient concentration. The blood-brain barrier, intratumoral pressure, and other factors may hinder the therapeutic agents to efficiently target and inhibit their pathways in GBM, or the size of the molecule (e.g., monoclonal antibodies) may impede crossing of the blood-brain barrier. Third, the inhibition obtained by these agents is counterbalanced by the activation of other parallel pathways that signal downstream of the inhibition. For these reasons, a number of compounds that directly target downstream effectors have been evaluated. For instance, mammalian target of rapamycin (mTOR) transduces signals from phosphatidylinositol 3-kinase/protein kinase B (PI3K/AKT) as well as the Ras pathway. mTOR expression is increased by overexpression of growth factors or phosphatase and tensin homolog deleted on chromosome ten (PTEN)^[28].

Several selective inhibitors of mTOR have been evaluated without clear efficacy. In a phase II study, temsirolimus (Rapamune; Wyeth, now Pfizer, New York, NY, USA) showed little to no activity as a single agent^[40] or when combined with erlotinib^[41]. The combination of temsirolimus with Bev also did not produce any significant effects as none of the 10 patients in the study showed a radiological response, resulting in the premature termination of the study^[42]. The combination of temsirolimus and sorafenib also did not associate with improved outcome^[43].

Protein kinase C (PKC), when activated, contributes to the propagation of some growth factors, including EGF and PDGF. Enzastaurin (Eli Lilly, Indiana, ID, USA) is a specific PKC inhibitor. Initial, unpublished reports suggested significant activity of enzastaurin in recurrent GBM, with a radiological response rate of 22% and a promising PFS. However, a subsequent randomized phase II/III study failed to confirm this efficacy^[44]. Similarly, the anti-estrogen drug tamoxifen, which also targets PKC, has been evaluated in GBM without significant activity^[45,46].

Epigenetic modifications of genes also play a key role in the malignant transformation of glioma cells. Acetylation and deacetylation (HDACs) of histones is a fundamental mechanism of gene regulation. It has long been suggested that valproic acid, which has been shown to inhibit HDACs at high concentrations, may improve survival in patients with GBM. A retrospective subgroup analysis of patients included in the seminal EORTC/NCIC 26981-

22981 trial that underwent valproic acid treatment at inclusion showed a significantly better outcome than patients that did not undergo any antiepileptic treatment (HR = 0.67, 95% CI = 0.49–0.93) or those treated with an enzyme-inducing antiepileptic agent (HR = 0.69, 95% CI = 0.53–0.90), although these patients showed more hematologic adverse events^[47]. These findings could not be confirmed in the phase III Cilengitide trial (Prof. Roger Stupp, personal communication).

Immunotherapy for the treatment of GBM

Modulating the immune system has been considered a promising modality for cancer treatment in various malignancies. Recent data demonstrate that treatment with the monoclonal antibody ipilimumab results in the modulation of T lymphocytes and restores immune response against melanoma cells^[48]. The sipuleucel-T vaccine was also approved by the US FDA for treatment of prostate cancer^[49]. A number of approaches are also under investigation for GBM, including the use of autologous stimulated lymphocytes, immunotherapy with cytokines and dendritic cells, and tumor- or peptide-based vaccines. One such vaccine is rindopepimut, a peptide-based vaccine against a 13 amino-acid sequence of the tumor-specific antigen EGFRvIII. This mutant variant of *EGFR* is constitutively activated and expressed in approximately 30% of GBM patients. Two phase II trials have evaluated rindopepimut in patients with newly diagnosed GBM. Patients who had completed radiotherapy and concomitant TMZ were enrolled to undergo maintenance TMZ treatment along with a rindopepimut vaccination. In these studies, the median PFS was 14.2 months (95% CI: 9.9 to 17.6 months) and 15.2 months (95% CI: 11.0 to 18.5 months), whereas the median OS was 23.6 and 26 months, respectively^[50,51]. These data are encouraging, but as patients were only enrolled after completion of the radiotherapy, cross trial comparisons with the landmark trial by Stupp *et al.*^[1] cannot be made. A multicenter, randomized, double-blinded study is currently ongoing to confirm the validity of this approach (NCT01480479).

Alternating electric fields

Alternating electric fields (AEF) have been shown to have a wide range of effects on living tissues. At very low frequencies (<1 kHz), AEF can induce membrane depolarization and stimulate excitable tissues. Low intensity-intermediate frequency AEF (100–300 kHz) has been shown to arrest the proliferation and differentiation of cells, resulting in a variety of cancer cell lines both *in vitro* and *in vivo*^[52]. After exposure to AEF, abnormal mitotic configurations that closely resemble morphologic abnormalities were observed with agents that interfere with microtubule polymerization, such as paclitaxel^[53]. It has been postulated that non-homogeneous electric fields generate unidirectional forces that disrupt the normal polymerization-depolymerization process of tubulin during mitosis^[52].

Two clinical trials have evaluated the potential effects of AEF in patients with recurrent GBM using the NovoTTF-100A device (Novocure Ltd, Haifa, Israel). This battery-operated device generates AEF with a frequency of 200 kHz and an intensity of 1–2 V/cm. In the first trial^[52], 10 patients were enrolled and were required to wear

the device continuously for a minimum of 18 h/day until disease progression (or up to 18 months). The device was well tolerated, as the major adverse events were limited to dermatitis beneath the electrodes. The time-to-progression (TTP) was 6.1 months; the 6-month PFS rate was 50%, and the median OS was 62.2 weeks, which compared favorably with historical controls that showed a TTP of 9.5 weeks, a 6-month PFS rate of 15.3%, and a median OS of 29.3 weeks^[52].

Based on these results, a multicenter phase III trial was initiated to compare the safety and efficacy of NovoTTF-100A with physician's choice chemotherapy in 238 patients with recurrent GBM. In that study, the majority of patients had undergone at least 1 prior therapy for recurrence. There was no significant difference in OS between the groups (6.0 vs. 6.6 months, $P = 0.23$), suggesting that this treatment was not inferior to chemotherapy in heavily pretreated patients with recurrent GBM or that neither standard best physician's choice chemotherapy nor the TTF device has a substantial antitumor effect in this population. The definite confirmation of efficacy of NovoTTF-100A will be obtained by an ongoing multicenter phase III trial that randomizes over 800 patients with newly diagnosed GBM to undergo standard radiotherapy with concomitant and adjuvant TMZ versus standard radiotherapy plus NovoTTF and adjuvant TMZ treatment. Preliminary studies indicated that AEF acted synergistically with chemotherapeutic agents on human glioma cell line U-118. In a pilot study of 10 newly diagnosed GBM patients treated with NovoTTF at

the initiation of adjuvant TMZ, a median PFS of 36.2 months and a median OS of 39 months were observed^[54]. In comparison, patients of the pivotal EORTC trial ($n = 81$) who initiated maintenance TMZ showed a median PFS of 17.51 months (95% CI: 12.75 to 19.88 months) and a median OS of 26.94 months (95% CI: 22.60 months to not reached) (Dr. Thierry Gorlia, personal communication).

Conclusions

The prognosis of GBM remains poor despite aggressive management including neurosurgical resection, radiation, and chemotherapy. A number of challenges remain to achieve better tumor control and patient survival. GBMs present a complex heterogeneity at the genomic and differentiation levels. It is therefore not surprising that targeted therapies have so far failed to deliver a clear clinical benefit. This might be the result of multiple driver mutations in different tumor cell populations within the same tumor. Therefore, combinations of multiple inhibitors have been proposed along with the identification of key driver mutations that are specific to each patient. A specific molecular profiling could therefore result in specific selection of targeted agents for every patient. To date, this approach is however still limited by the lack of effective therapies.

Received: 2013-11-15; accepted: 2013-12-10.

References

- [1] Stupp R, Mason WP, van den Bent MJ, et al. Radiotherapy plus concomitant and adjuvant temozolomide for glioblastoma. *N Engl J Med*, 2005,352:987–996.
- [2] Stupp R, Hegi ME, Mason WP, et al. Effects of radiotherapy with concomitant and adjuvant temozolomide versus radiotherapy alone on survival in glioblastoma in a randomised phase III study: 5-year analysis of the EORTC-NCIC trial. *Lancet Oncol*, 2009,10:459–466.
- [3] Mirimanoff R, Stupp R. Long-term survival in glioblastoma possible? Updated results of the EORTC/NCIC phase III randomized trial on radiotherapy (RT) and concomitant and adjuvant temozolomide (TMZ) versus RT alone. *Int J Radiat Oncol Biol Phys*, 2007,69:S2.
- [4] Hegi ME, Diserens AC, Gorlia T, et al. MGMT gene silencing and benefit from temozolomide in glioblastoma. *N Engl J Med*, 2005,352:997–1003.
- [5] Keime-Guibert F, Chinot O, Taillandier L, et al. Radiotherapy for glioblastoma in the elderly. *N Engl J Med*, 2007,356:1527–1535.
- [6] Malmstrom A, Gronberg BH, Marosi C, et al. Temozolomide versus standard 6-week radiotherapy versus hypofractionated radiotherapy in patients older than 60 years with glioblastoma: the Nordic randomised, phase 3 trial. *Lancet Oncol*, 2012,13:916–926.
- [7] Roa W, Brasher PM, Bauman G, et al. Abbreviated course of radiation therapy in older patients with glioblastoma multiforme: a prospective randomized clinical trial. *J Clin Oncol*, 2004,22:1583–1588.
- [8] Wick W, Platten M, Meisner C, et al. Temozolomide chemotherapy alone versus radiotherapy alone for malignant astrocytoma in the elderly: the NOA-08 randomised, phase 3 trial. *Lancet Oncol*, 2012,13:707–715.
- [9] Huang H, Held-Feindt J, Buhl R, et al. Expression of VEGF and its receptors in different brain tumors. *Neurol Res*, 2005,27:371–377.
- [10] Shibuya M. Differential roles of vascular endothelial growth factor receptor-1 and receptor-2 in angiogenesis. *J Biochem Mol Biol*, 2006,39:469–478.
- [11] Bergers G, Benjamin LE. Tumorigenesis and the angiogenic switch. *Nat Rev Cancer*, 2003,3:401–410.
- [12] Batchelor TT, Mulholland P, Neyns B, et al. Phase III randomized trial comparing the efficacy of cediranib as monotherapy, and in combination with lomustine, versus lomustine alone in patients with recurrent glioblastoma. *J Clin Oncol*, 2013,31:3212–3218.
- [13] Gerstner ER, Chen PJ, Wen PY, et al. Infiltrative patterns of glioblastoma spread detected via diffusion MRI after treatment with cediranib. *Neuro Oncol*, 2010,12:466–472.
- [14] de Groot JF, Lamborn KR, Chang SM, et al. Phase II study of aflibercept in recurrent malignant glioma: a North American Brain Tumor Consortium study. *J Clin Oncol*, 2011,29:2689–2695.
- [15] Vredenburgh JJ, Desjardins A, Herndon JE 2nd, et al. Bevacizumab plus irinotecan in recurrent glioblastoma multiforme. *J Clin Oncol*, 2007,25:4722–4729.
- [16] Vredenburgh JJ, Desjardins A, Herndon JE 2nd, et al. Phase II trial of bevacizumab and irinotecan in recurrent malignant glioma. *Clin Cancer Res*, 2007,13:1253–1259.
- [17] Friedman HS, Prados MD, Wen PY, et al. Bevacizumab alone and

- in combination with irinotecan in recurrent glioblastoma. *J Clin Oncol*, 2009,27:4733–4740.
- [18] Raizer JJ, Grimm S, Chamberlain MC, et al. A phase 2 trial of single-agent bevacizumab given in an every-3-week schedule for patients with recurrent high-grade gliomas. *Cancer*, 2010,116:5297–5305.
- [19] Kreisl TN, Kim L, Moore K, et al. Phase II trial of single-agent bevacizumab followed by bevacizumab plus irinotecan at tumor progression in recurrent glioblastoma. *J Clin Oncol*, 2009,27:740–745.
- [20] Sathornsumetee S, Desjardins A, Vredenburgh JJ, et al. Phase II trial of bevacizumab and erlotinib in patients with recurrent malignant glioma. *Neuro Oncol*, 2010,12:1300–1310.
- [21] Lai A, Tran A, Nghiemphu PL, et al. Phase II study of bevacizumab plus temozolomide during and after radiation therapy for patients with newly diagnosed glioblastoma multiforme. *J Clin Oncol*, 2011,29:142–148.
- [22] de Groot JF, Fuller G, Kumar AJ, et al. Tumor invasion after treatment of glioblastoma with bevacizumab: radiographic and pathologic correlation in humans and mice. *Neuro Oncol*, 2010,12:233–242.
- [23] Verhoeff JJ, van Tellingen O, Claes A, et al. Concerns about anti-angiogenic treatment in patients with glioblastoma multiforme. *BMC Cancer*, 2009,9:444.
- [24] Wick A, Dörner N, Schafer N, et al. Bevacizumab does not increase the risk of remote relapse in malignant glioma. *Ann Neurol*, 2011,69:586–592.
- [25] Reardon DA, Fink KL, Mikkelsen T, et al. Randomized phase II study of cilengitide, an integrin-targeting arginine-glycine-aspartic acid peptide, in recurrent glioblastoma multiforme. *J Clin Oncol*, 2008,26:5610–5617.
- [26] Stupp R, Hegi ME, Neyns B, et al. Phase I/IIa study of cilengitide and temozolomide with concomitant radiotherapy followed by cilengitide and temozolomide maintenance therapy in patients with newly diagnosed glioblastoma. *J Clin Oncol*, 2010,28:2712–2718.
- [27] Gilbert MR, Kuhn J, Lamborn KR, et al. Cilengitide in patients with recurrent glioblastoma: the results of NABTC 03–02, a phase II trial with measures of treatment delivery. *J Neurooncol*, 2012,106:147–153.
- [28] Rao SK, Edwards J, Joshi AD, et al. A survey of glioblastoma genomic amplifications and deletions. *J Neurooncol*, 2010,96:169–179.
- [29] Rich JN, Reardon DA, Peery T, et al. Phase II trial of gefitinib in recurrent glioblastoma. *J Clin Oncol*, 2004,22:133–142.
- [30] Wong ET, Hess KR, Gleason MJ, et al. Outcomes and prognostic factors in recurrent glioma patients enrolled onto phase II clinical trials. *J Clin Oncol*, 1999,17:2572–2578.
- [31] Raizer JJ, Abrey LE, Lassman AB, et al. A phase II trial of erlotinib in patients with recurrent malignant gliomas and nonprogressive glioblastoma multiforme postirradiation therapy. *Neuro Oncol*, 2010,12:95–103.
- [32] Thiessen B, Stewart C, Tsao M, et al. A phase I/II trial of GW572016 (lapatinib) in recurrent glioblastoma multiforme: clinical outcomes, pharmacokinetics and molecular correlation. *Cancer Chemother Pharmacol*, 2010,65:353–361.
- [33] Hasselbalch B, Lassen U, Hansen S, et al. Cetuximab, bevacizumab, and irinotecan for patients with primary glioblastoma and progression after radiation therapy and temozolomide: a phase II trial. *Neuro Oncol*, 2010,12:508–516.
- [34] Neyns B, Sadones J, Joosens E, et al. Stratified phase II trial of cetuximab in patients with recurrent high-grade glioma. *Ann Oncol*, 2009,20:1596–1603.
- [35] Verhaak RG, Hoadley KA, Purdom E, et al. Integrated genomic analysis identifies clinically relevant subtypes of glioblastoma characterized by abnormalities in PDGFRA, IDH1, EGFR, and NF1. *Cancer Cell*, 2010,17:98–110.
- [36] Lokker NA, Sullivan CM, Hollenbach SJ, et al. Platelet-derived growth factor (PDGF) autocrine signaling regulates survival and mitogenic pathways in glioblastoma cells: evidence that the novel PDGF-C and PDGF-D ligands may play a role in the development of brain tumors. *Cancer Res*, 2002,62:3729–3735.
- [37] Wen PY, Yung WK, Lamborn KR, et al. Phase I/II study of imatinib mesylate for recurrent malignant gliomas: North American Brain Tumor Consortium Study 99–08. *Clin Cancer Res*, 2006,12:4899–4907.
- [38] Reardon DA, Egorin MJ, Quinn JA, et al. Phase II study of imatinib mesylate plus hydroxyurea in adults with recurrent glioblastoma multiforme. *J Clin Oncol*, 2005,23:9359–9368.
- [39] Reardon DA, Dresemann G, Taillibert S, et al. Multicentre phase II studies evaluating imatinib plus hydroxyurea in patients with progressive glioblastoma. *Br J Cancer*, 2009,101:1995–2004.
- [40] Akhavan D, Cloughesy TF, Mischel PS. mTOR signaling in glioblastoma: lessons learned from bench to bedside. *Neuro Oncol*, 2010,12:882–889.
- [41] Reardon DA, Desjardins A, Vredenburgh JJ, et al. Phase 2 trial of erlotinib plus sirolimus in adults with recurrent glioblastoma. *J Neurooncol*, 2010,96:219–230.
- [42] Lassen U, Sorensen M, Gaziel TB, et al. Phase II study of bevacizumab and temsirolimus combination therapy for recurrent glioblastoma multiforme. *Anticancer Res*, 2013,33:1657–1660.
- [43] Lee EQ, Kuhn J, Lamborn KR, et al. Phase I/II study of sorafenib in combination with temsirolimus for recurrent glioblastoma or gliosarcoma: North American Brain Tumor Consortium study 05–02. *Neuro Oncol*, 2012,14:1511–1518.
- [44] Kreisl TN, Kim L, Moore K, et al. A phase I trial of enzastaurin in patients with recurrent gliomas. *Clin Cancer Res*, 2009,15:3617–3623.
- [45] Brandes AA, Ermani M, Turazzi S, et al. Procarbazine and high-dose tamoxifen as a second-line regimen in recurrent high-grade gliomas: a phase II study. *J Clin Oncol*, 1999,17: 645–650.
- [46] Spence AM, Peterson RA, Scharnhorst JD, et al. Phase II study of concurrent continuous temozolomide (TMZ) and tamoxifen (TMX) for recurrent malignant astrocytic gliomas. *J Neurooncol*, 2004,70: 91–95.
- [47] Weller M, Gorlia T, Cairncross JG, et al. Prolonged survival with valproic acid use in the EORTC/NCIC temozolomide trial for glioblastoma. *Neurology*, 2011,77:1156–1164.
- [48] Hodi FS, O'Day SJ, McDermott DF, et al. Improved survival with ipilimumab in patients with metastatic melanoma. *N Engl J Med*,

- 2010,363:711–723.
- [49] Kantoff PW, Higano CS, Shore ND, et al. Sipuleucel-T immunotherapy for castration-resistant prostate cancer. *N Engl J Med*, 2010,363:411–422.
- [50] Sampson JH, Heimberger AB, Archer GE, et al. Immunologic escape after prolonged progression-free survival with epidermal growth factor receptor variant III peptide vaccination in patients with newly diagnosed glioblastoma. *J Clin Oncol*, 2010,28:4722–4729.
- [51] Sampson JH, Aidape KD, Archer GE, et al. Greater chemotherapy-induced lymphopenia enhances tumor-specific immune responses that eliminate EGFRvIII-expressing tumor cells in patients with glioblastoma. *Neuro Oncol*, 2011,13:324–333.
- [52] Kirson ED, Dbaly V, Tovarys F, et al. Alternating electric fields arrest cell proliferation in animal tumor models and human brain tumors. *Proc Natl Acad Sci U S A*, 2007,104:10152–10157.
- [53] Jordan MA, Toso RJ, Thrower D, et al. Mechanism of mitotic block and inhibition of cell proliferation by taxol at low concentrations. *Proc Natl Acad Sci U S A*, 1993,90:9552–9556.
- [54] Kirson ED, Schneiderman RS, Dbaly V, et al. Chemotherapeutic treatment efficacy and sensitivity are increased by adjuvant alternating electric fields (TTFields). *BMC Med Phys*, 2009,9:1.