



Year: 2015

Transforming growth factor- pathway activity in glioblastoma

Frei, K ; Gramatzki, D ; Tritschler, I ; Schroeder, J J ; Espinoza, L ; Rushing, E J ; Weller, M

Abstract: Transforming growth factor (TGF)- is a central molecule maintaining the malignant phenotype of glioblastoma. Anti-TGF- strategies are currently being explored in early clinical trials. Yet, there is little contemporary data on the differential expression of TGF- isoforms at the mRNA and protein level or TGF- /Smad pathway activity in glioblastomas in vivo. Here we studied 64 newly diagnosed and 16 recurrent glioblastomas for the expression of TGF- 1-3, platelet-derived growth factor (PDGF)-B, and plasminogen activator inhibitor (PAI)-1 mRNA by RT-PCR and for the levels of TGF- 1-3 protein, phosphorylated Smad2 (pSmad2), pSmad1/5/8 and PAI-1 by immunohistochemistry. Among the TGF- isoforms, TGF- 1 mRNA was the most, whereas TGF- 3 mRNA was the least abundant. TGF- 1-3 mRNA expression was strongly correlated, as was the expression of TGF- 1-3 mRNA, and of the TGF- 1-3 target genes, PDGF-B and PAI-1. TGF- 2 and TGF- 3 protein levels correlated well, whereas the comparison of the other TGF- isoforms did not. Positive correlation was also observed between TGF- 1 and pSmad1/5/8 and between pSmad2 and pSmad1/5/8. Survival analyses indicated that a group of patients with high expression levels of TGF- 2 mRNA or pSmad1/5/8 protein have inferior outcome. We thus provide potential biomarkers for patient stratification in clinical trials of anti-TGF- therapies in glioblastoma.

DOI: <https://doi.org/10.18632/oncotarget.3467>

Posted at the Zurich Open Repository and Archive, University of Zurich

ZORA URL: <https://doi.org/10.5167/uzh-110458>

Journal Article

Published Version



The following work is licensed under a Creative Commons: Attribution 3.0 Unported (CC BY 3.0) License.

Originally published at:

Frei, K; Gramatzki, D; Tritschler, I; Schroeder, J J; Espinoza, L; Rushing, E J; Weller, M (2015). Transforming growth factor- pathway activity in glioblastoma. *OncoTarget*, 6(8):5963-5977.

DOI: <https://doi.org/10.18632/oncotarget.3467>

Neurodegeneration in the Elderly – when the blood type matters

An overview of the McLeod Syndrome with focus on hematological features

B.M Frey¹, C. Gassner¹, H.H. Jung²

¹) Blood Transfusion Service SRK, 8952 Schlieren-Zurich, Switzerland

²) Department of Neurology, University Hospital Zurich, Zurich, Switzerland

Corresponding author: Beat M. Frey, Blood Transfusion Service SRK, Rütistrasse 19,
8952 Schlieren-Zurich, Switzerland

Tel: 0041 (0)58 272 52 52

Email: bm.frey@zhbsd.ch

www.zhbsd.ch

Summary

Multisystem deterioration occurs mainly in older individuals and may be related to physiological tissue degeneration. However, genetic predisposition may be unmasked by inappropriate functional and structural system deficiencies. McLeod Syndrome (MLS) is a rare, multisystem disease which is X-chromosomal inherited and belongs to the Neuroacanthocytosis Syndromes (NAS). The main clinical manifestations contain progressive neuro-psychiatric and cognitive deterioration, choreatic movement disorder, as well as myopathy, sensorymotor axonal neuropathy and cardiomyopathy. In addition, MLS patients have red blood cell abnormalities including immune-hematological, morphological and functional impairments of red blood cells. In large deletions, contiguous gene syndrome may arise, including Duchenne muscular dystrophy, cellular immunodeficiency or retinitis pigmentosa. Hematological abnormalities such as blood group abnormalities in Kell- and XK blood group system, formation of anti-public red blood cell alloantibodies, acanthocytosis and elevated creatinine phosphokinase may precede clinical disease manifestation for decades and provide tools for early diagnosis. Patients with unexplained neuro-muscular deterioration and/or neuro-psychological pathologies accompanied with hematological abnormalities should be investigated for MLS.

McLeod Syndrom (MLS) is part of the Neuroacanthocytosis Syndromes (NAS)

NAS are defined as progressive neurodegenerative diseases affecting mainly basal ganglia including nucleus caudatus and putamen in association with red blood cell acanthocytosis. Additional hematological abnormalities e.g. morphological, functional and serological aberrations of red blood cells (RBC) are part of disease defining clinical features.¹⁻³. Four different diseases with overlapping clinical manifestations account for the NA syndromes: Chorea-acanthocytosis (ChAc) and the McLeod syndrome (MLS) constitute the core NAS and are caused by mutations of the *VPS13A* gene on chromosome 9q21 and the *XK* gene on *Xp21.1*, respectively. The more rare diseases such as Huntington-like2 disease (HDL2) and the pantothenate kinase 2 disease (PKAN) complete the group of NAS. Affected genes and proteins, mechanism of inheritance and clinical as well as laboratory phenotypes are summarized in table 1.

Usually, the MLS is diagnosed in patients with progressive neuro-psychiatric deficiencies and having excluded other pathologies such as Huntington's disease, Tourette's syndrome and familial hemolytic anemia. The clinical picture reflects a neuro-hematological disorder⁴ where the subtle hematological findings may precede the neurological deficiencies for decades and remain unrecognized until neuro-psychiatric alterations prompt invasive assessment. The patients suffer on premature dementia, intellectual and cognitive impairment, depression, personality changes, social retraction and in some cases they may suffer of movement disorders such as choreatic movement disorder and dystonia as well as generalized epileptic seizures^{1,2,5-12}. In all MLS patients examined up to date creatinine phosphokinase (CPK) is elevated, without signs of acute myocardial and muscular cell necrosis or renal insufficiency. The diagnostic key feature is the prototypic McLeod blood group phenotype comprising weakened or absent Kell blood group antigens and negativity for the Kx antigen on the red blood cell membrane. This blood group abnormality is

highly specific for MLS and separates the disease from other NAS. In many patients with MLS the blood group peculiarity goes along with acanthocytosis of variable degree and compensated hemolytic anemia. However, several individuals have been described with exclusive McLeod RBC phenotype without other hematological, neuro-psychiatric and neuro-muscular symptoms^{13,14}. Mostly, these cases are recognized when being blood group phenotyped for KEL antigens while serving as blood donors. Infact, the first case discovered with the prototypic RBC phenotype was the healthy blood donor Mr. McLeod, who engaged into blood donation as a dentist student and was diagnosed with “a new phenotype (McLeod) in the Kell blood group system”¹⁵ because of weakened expression of several Kell antigens as compared to his parents.

Peculiarity of blood group antigens on McLeod erythrocytes

The MLS is the only NAS with distinct blood group abnormality affecting the KEL (ISBT 06) as well as the XK (ISBT 019) blood group system. The Kell glycoprotein (CD238) is a type II single-pass transmembrane red blood cell protein containing 732 aminoacids and functions as an endopeptidase which cleaves big-endothelin3 into the active endothelin3, that acts as a potent vasoconstrictor^{16,17}. It expresses at least 35 recognized blood group antigens, including 5 antithetical pairs exerting clinical relevance¹⁸. From these, the K/k pair (Kell/Cellano) is the most important one¹⁹. The single aminoacid exchange of methionine replacing threonine at position 193 (Met193Thr) eliminates a N-glycosylation site of the Kell protein constituting the K (KEL1) and k (KEL2) epitopes, respectively. Alloantibodies against K and k may cause severe hemolytic transfusion reactions as well as live-threatening morbus hemolyticus neonatorum^{19,20}.

The XK protein, encoded by the *XK* gene at Xp21.1 is a 444 aminoacid multipass red blood cell membrane peptide, forming a heterodimer with the Kell glycoprotein and expresses the single blood group antigen Kx^{21,22}. The antigen Kx is located at the fifth extracellular loop of the XK peptide in close proximity to the disulfide bond XK^{Cys347}-Kell^{Cys72}, covalently linking and stabilizing the Kell-XK heterodimer²². In most ethnicities, the frequency of the Kx antigen is >99% and may therefore be considered as “the public Kx phenotype”¹⁹. Individuals with the McLeod phenotype, characteristically lack the Kx antigen, which is due to a complete absence or a drastically shortened XK protein and may rise anti-public red blood cell antibodies such as anti-Kx and anti-Km upon immunizing events, such as transfusion. These alloantibodies will react with most of the homologous blood donations and may therefore generate substantial problems in the supplementation with correctly matched, e.g. Kx negative blood^{4,13,23}. In Kx negative individuals, the observed weakened agglutination of Kell antigens serves as surrogate for the McLeod phenotype and needs to be distinguished from a modified Kell antigen expression in Kmod and Knull phenotypes. These, equally rare variants of *KEL* alleles lead to modified Kell protein expression^{24,25} without molecular, phenotypic and clinical signs of MLS. The red blood cells of Kmod and Knull phenotypes express the Kx antigen^{24,26,27} and will therefore not develop anti-public antibodies in the Kx blood group system.

Genetic defects at Xp21.1 lead to the absence or truncation of the XK protein causing both, the reduced or complete absence of the Kell antigen in the erythrocyte membrane, as well as the absence of the Kx blood group antigen (Kx-)⁵. At least 29 different mutations at Xp21.1 are recognized as molecular mechanism for the Kx-phenotype^{5,18}. These are missense and stop mutations anywhere in the three exons of the coding sequence as well as splice site and insertion/deletion mutations leading to erroneous translation and transcription of the gene, respectively⁵. In cases of large

deletional defects, neighbour genes of *XK* may also be affected and give rise to the “contiguous gene syndrome”²⁸, of which the clinical phenotype is dominated by the co-affected gene(s)²⁹. Most important are deletions affecting *DMD*, a gene located telomeric to *XK*, leading to Duchenne muscular dystrophy²⁸ or deletions affecting the centromeric *CYBB* gene, leading to X-linked granulomatous disease (*X-CGD*)^{30,31}. Figure 1 gives an overview on some of the molecular defects at Xp21.1 and there consequences for the *XK* protein.

Distinct morphology of McLeod erythrocytes

Patients suffering on *MLS* or *ChAc* usually present with various degree of acanthocytosis in circulating blood, which may be visualized by light microscopy of a blood smear. The abnormally shaped RBCs (acanthocytes) are characterized by few irregular membrane protrusions³². They are different from echinocytes which show many, more regular and shorter membrane bulges. However, although the morphological variants are distinct, these RBC abnormalities are interchangeable and in most cases acanthocytes are accompanied by echinocytes³³. Since the lipid composition of altered RBC is normal, the acanthocytic shape change results from impaired interaction of the membrane multiprotein complexes (MMPC) with the cytoskeleton of red blood cell³³. The major RBC anion exchanger protein, band 3 (B3), one of the most abundant membrane protein, is organized either as a tetrameric B3-ankyrin complex, a dimeric B3-protein 4.1R complex (also called “junctional complex”) and as a free B3 protein^{34,35}. The B3 multimeric entities are attached to various other transmembrane proteins such as glycophorin A and C, Rh protein/Rh associated glycoprotein (RhAG), Kell, *XK* and Duffy proteins as well as CD47 and Landstein-Wiener (LW) glycoproteins and thereby constitute the MMPC. The MMPC interact with the RBC cytoskeleton by recruiting linker proteins such as protein 4.2/ankyrin (ankyrin

complex) and protein 4.1R/adducin (4.1R complex)³⁶⁻³⁸. The MMPC-cytoskeleton network controls the RBC discocytic shape and determines RBC deformability, rheological, adhesive and functional properties^{37,39,40}. Deficiencies in one or several proteins of MMPC impairing the MMPC-cytoskeleton interaction were found to cause inherited RBC membranopathies such as hereditary elliptocytosis, ovalocytosis, stomatocytosis and spherocytosis^{37,41-49}. Moreover, the cytoplasmic part of B3 as well as of other attached membrane proteins control a variety of metabolic pathways in RBC by binding to aldolases, kinases, oxidases and phosphatases⁵⁰⁻⁵⁸.

However, not only deficiencies or dysfunction of RBC membrane proteins may lead to acanthocytosis. Also, hereditary disorders of lipid metabolism such as apolipoprotein A and vitamin E deficiency^{59,60} as well as a number of acquired conditions such as acute and chronic anemia, hepatitis, alcoholic liver cirrhosis, hypopituitarism, hypothyroidism, malabsorption syndromes and malnutrition may be associated with acanthocytic shape change of RBC⁶¹.

Acanthocytic RBCs are a typical finding in NAS especially in patients with MLS and ChAc. However, the finding is neither specific nor sensitive enough for clinical diagnosis^{13,14}. Moreover, the in vitro diagnosis of acanthocytes is technically demanding and prone of false positive testing⁶². Therefore, Storch et al. suggested a modified technique to assess peripheral blood smears for acanthocytes. According to Storch et al., quantification of acanthocytes needs to be done using wet smear of diluted blood sample and by applying dark field microscopy⁶². Due to technical demanding procedure and the low disease specificity of acanthocytes, this test has lost its diagnostic power. Nevertheless, functional impairment of transmembrane ion transport^{58,63-65}, impaired formation of endovesicles by acanthocytes in NAS⁶⁶ and the findings by DeFranceschi et al who described 14 kinases constituting a mutual phospho-tyrosine sub-network in acanthocytes of NAS⁵¹ suggest common pathways

for acanthocyte formation and neurodegeneration in NAS. Therefore, acanthocytes of MLS may provide an easy accessible substrate to be investigated for patho-mechanism of disease and may paste new avenues of treatment options for patients suffering on NAS.

MLS is a multisystem disorder

Although the genetic alteration in MLS was precisely located at Xp21.1⁶⁷ the genotype-phenotype correlation is weak and most mutation carriers are discovered while being assessed for a wide spectrum of subtle to severe central nervous system or neuromuscular affection occurring together with pathological changes of red blood cells (acanthocytosis, coombs-negative, hemolytic anemia)^{1-3,68}. The molecular characterization of underlying genetic defects in NAS allow unambiguous distinction between the four different entities of NAS (Table 1). Molecular defect identification has therefore become the key tool for diagnosis^{1,69}. In MLS, the disorder is caused by the affection of the XK protein, which is expressed ubiquitously in body tissues⁷⁰ and most likely functions as a membrane transporter^{71,72} with so far not precisely defined substrate. In the RBC membrane the XK protein is co-expressed with the Kell protein and forms a heterodimer^{22,27,70,73}. In contrast, non-hematopoietic cells express the XK protein independently of the Kell protein which may not even be present⁷⁰. Therefore, XK may act as a universal gatekeeper by direct or indirect control of substrate exchange between different subcellular compartments^{70,72}. Several groups have shown, that in the absence of XK or other RBC membrane proteins, the RBC shape and transmembrane ion transport may be severely altered. Active ion transport channels including the Ca²⁺ dependent K⁺ transport (Gardos channel) as well as the transporters of Mg²⁺, Cl⁻, SO₄⁻ and other ions are negatively affected^{58,63,65,66,74}. Especially, the proper function of Gardos channel is pivotal for the integrity and

function of RBCs⁷⁵⁻⁷⁸. Gardos channels are ubiquitously expressed in body tissue⁷⁹ and their functionality may depend on intact XK protein. In line with this assumption, disruption of XK may therefore lead to multisystem deficiencies by impairment of Gardos functionality which could explain the chief affected cardiac and neuronal tissues in MLS⁷⁹⁻⁸³ (see Table 1).

Molecular MLS Assessment

As detailed earlier, the NAS are monoallelic deficiency syndromes, perfectly suited for molecular defect analysis. The genetic defects of MLS always involve *XK*, the gene encoding the XK protein and its Kx antigen, which is located at Xp21.1. The genetic lesions may be point mutations leading to amino acid exchanges and stop codons, splice site mutations and small insertional and deletional aberrations (indels), as well as large X-chromosomal deletions involving up to approximately 5 Mio bp, as reported as of yet. A listing of all currently known *XK*-null alleles, e.g. *XK* N01* to *XK* N29*, may be retrieved from the homepage of the ISBT terminology committee¹⁸. The mode of inheritance of MLS is X-chromosomal recessive, implying carrier status with no, or abrogated clinical disease manifestation in mothers, sisters and daughters of affected males. To exclude a disease caused by a molecular defect at Xp21.1, we designed a systematic approach to investigate the regions, telomeric and centromeric to *XK* for the unique identification of contiguous gene defects. In brief, the X-chromosome is investigated in between *OTC* (Ornithine Carbamoyltransferase at Xp11.4, OMIM* 300461) and *DMD* (Duchenne Muscular Dystrophy, Dystrophin 1 at Xp21.2, OMIM* 300377), by 36 equally distanced positional PCRs also co-amplifying sequences of the Human Growth Hormone 1 (*GH1* at 17q23.3, OMIM* 139250), which serve as positive amplification controls. The X-chromosomal distance investigated by this approach covers more than 8.8 Mio basepairs (bp) in total and includes *XK*, 0.7

Mio bps from its centromeric end (McLeod Syndrome associated XK at *Xp21.1*, *OMIM* 314850*), as well as *CYBB* (Cytochrome b(-245) subunit associated with X-CGD at *Xp11.4*, *OMIM* 300481*) and *RPGR* (Retinitis Pigmentosa GTPase Regulator at *Xp11.4*, *OMIM* 312610*). In case of large X-chromosomal deletions, certain positional PCRs will fail to amplify. The indicated gap is then narrowed down by additional positional PCRs until the breakpoint of the deletion may be bridged by one single PCR. Consequently, this case specific PCR product is then sequenced and allows for the exact definition of the breakpoint position, and may itself already be used as highly accurate diagnostic tool for the detection of a carrier status in mothers, sisters and daughters of affected males. In case, no large X-chromosomal deletion is observed, all three XK exons, also including some sequences of the promoter and at least 50 bp of each flanking intron will be sequenced to reveal point mutations within the gene, potentially causative of an XK inactivating effect. The effect of such point mutations may be clearly evident, e.g. when nonsense mutations lead to the creation of stop codons in the predicted XK peptide, or be less informative and of questionable meaning, e.g. when exchanged amino acids share in between no, and up to similar physiochemical properties, then called “radical” and “conservative missense mutations”, respectively. Using this approach we were able to describe five intragenic *XK* mutants, with only one of them already known and listed as *XK* N.20* by the ISBT terminology committee¹⁸, the others, with as yet undescribed nonsense (n= 1), frame shift (n= 1) and radical missense mutation (n= 1) and two large X-chromosomal deletions, respectively. All carriers had different MLS phenotypes including neuropsychiatric disorder associated with hereditary sudden death syndrome, severe choreatic movement disorder and X-linked CGD, in one case (manuscript in preparation).

Clinically guided MLS diagnosis

Most of the MLS mutations described so far were discovered in patients being investigated for neuro-psychiatric or choreatic movement disorders or in cases with immune deficiency syndromes⁵. Normally, the patients suffer of unspecific neuro-psychiatric symptoms for years without having assigned clear diagnosis. Sometimes, MLS is diagnosed in asymptomatic mutation carriers, most often when routinely phenotyped for KEL antigens while serving as blood donors¹³⁻¹⁵. These blood donors may develop clinical MLS later on and available data indicate a high penetrance of the disorder with a possible onset in the sixth and seventh decade⁸⁴. However, in patients with unexplained neuro-psychiatric problems or choreatic movement disorders with onset in the third or fourth decade it might be important to exclude MLS as the underlying disease causing condition. The findings may have important implications for the usually male patient as well as for his family members. Although the disease progression cannot be stopped, early supportive measures such as seizure protection, psychiatric treatment as well as prevention of mutilating involuntary movements may provide desired palliation of disease associated disabilities. Importantly, early recognition of orofacial dystonia may be pivotal to prevent feeding impairment and secondary wasting disease⁸⁵. Also, the recognition of private blood type (Kx-) is crucial when it comes to transfusion support. By timely searching for Kx- blood donors from international donor registries or alternatively, by use of cryopreserved autologous blood units the formation of anti-public antibodies can be prevented²³. Finally, cardiac complications such as fatal arrhythmia may be prevented by implantation of a cardiac pacemaker⁸⁶.

For genetic counselling of MLS patient's family members, it is important to identify the exact genetic defect which can then be followed for segregation in the relatives of the patient. Finally, in X-linked CGD patients, the exclusion of mutations at Xp21.1 is

pivotal in planning and exertion of CGD treatment which often includes stem cell transplantation and transfusion support^{87,88}.

We established an algorithm to comprehensively assess patient's samples for suspected McLeod mutations (Figure 2). Firstly, the patient's RBCs are examined for expression of the Kx antigen as well as several antithetical Kell antigens (e.g. K, k, Kp^b) by conventional serology techniques. It is important to emphasize that IgG coating of patient's RBCs needs to be excluded by negative direct antiglobuline test in order to validate serological antigen determination. Also, genetic investigation for inherited Kell antigens by commercial genotyping kits helps to confirm serological findings. In case the Kx antigen is absent and the inherited Kell antigens show weakened or missing expression, the McLeod red cell phenotype is proven. In such cases, the blood smear is assessed for the presence of acanthocytes and the extracted genomic DNA will be searched for disease causing mutations (see above). Identified mutations will then be used to design a molecular protocol to follow the segregation the of disease specific mutation in consanguineous family members. In order to complete an individual McLeod assessment, we further recommend to perform an expression study of the KEL protein by flowcytometry as described earlier¹³. Flowcytometric investigation of KEL protein expression by using commercially available anti-Kell antibodies (e.g. BRIC18, BRIC68, BRIC203, provided by IBGRL, Bristol/UK) allows for a quantification of the circulating McLeod RBCs admixed to normal RBCs. Double RBC populations with normal and depressed KEL protein expression is a typical finding in female McLeod carriers^{4,7}. All individuals with confirmed McLeod RBC phenotype need to be assessed for the presence of red blood cell alloantibodies, since anti-public alloantibodies may have substantial consequences for transfusion support of MLS patients.

Conclusion

MLS is a rare multisystem disease which affects mainly male adults. Neuro-psychiatric, neuromuscular, cardiac and hematologic affection dominate the clinical picture and may vary substantially in individual patients. Early diagnosis in patients with suggestive clinical symptoms is crucial for guiding the patient's management in order to prevent cardiac and hematologic sequelae and to palliate clinical and social consequences of disease. Diagnostic cornerstones are red blood cell phenotyping in the XK- and KEL system, appropriate molecular analysis of underlying genetic defect and quantification of circulating acanthocytes. The molecular mutation analysis also provides insights into multi gene defects (contiguous gene syndrome) which is most important in cases with juvenile X-linked granulomatous disease, retinitis pigmentosa and Duchenne muscular dystrophy.

Legends

Table 1:

Genetic and somatic deficiencies in NA syndromes. Various genetic defects with distinct inheritance and overlapping clinical manifestation constitute the NA syndromes. Adapted from Jung et al²

ChAc: Choreoacanthocytosis, MLS: McLeod Syndrome, HDL2: Huntingon-like2 Syndrome, PKAN: Pantothenatekinase 2 Disease

Figure 1:

The XK gene with its three exons and the corresponding red blood cell multipass membrane protein XK are shown. All three exons may be affected by stop and missense mutations leading to shortened or missing protein at the red cell surface. Also splice site mutation as well as partial and complete gene deletion mutations may cause absence of XK protein. Whole XK gene deletions extending to telomeric and centromeric coding regions may lead to the contiguous gene syndrome.

X: Marks premature termination of XK protein assembly due to stop codon

Figure 2:

Figure 2 delineates the systematic analysis of patient samples suspected for the presence of a McLeod mutation. The assessment always starts with the serological evaluation for KEL and Kx antigen expression, which are expected to be either negative or weakened. The antigen expression pattern needs to be validated by negative direct antiglobuline test. In case of positive DAT, the antigens might be determined false positive. Kx antigen expression pattern will then guide further evaluation performed. If Kx is negative, an assumed molecular defect directly encoded by the XK gene itself, or alternatively a large deletion affecting the expanded XK locus at Xp21.1 is checked for. Respective X-chromosomal mutations may then establish the diagnosis of McLeod syndrome and also explain the secondary weekend Kell antigen expression. If Kx reacts positive, the MLS is excluded and other reasons for weakened KEL expression might be checked for (K_{mod} , K_{Null} , $Kp^{\text{a}+}$). In MLS, further diagnostic steps may be taken, e.g. detailed FACS analysis of weakened Kell antigen expression, or a microscopic investigation for the presence of acanthocytes.

DAT: Direct Antiglobuline Test

FACS: Fluorescence Activated Cell Sorting

References

1. Danek A, Jung HH, Melone MA, et al. Neuroacanthocytosis: new developments in a neglected group of dementing disorders. *J Neurol Sci* 2005;**229-230**: 171-86.
2. Jung HH, Danek A, Walker RH. Neuroacanthocytosis syndromes. *Orphanet J Rare Dis* 2011;**6**: 68.
3. Hardie RJ, Pullon HW, Harding AE, et al. Neuroacanthocytosis. A clinical, haematological and pathological study of 19 cases. *Brain* 1991;**114 (Pt 1A)**: 13-49.
4. Jung HH, Danek A, Frey BM. McLeod syndrome: a neurohaematological disorder. *Vox Sang* 2007;**93**: 112-21.
5. Jung H, Danek A, Walker RH, et al. McLeod Neuroacanthocytosis Syndrome. *GeneReviews* 2012; <http://www.ncbi.nlm.nih.gov/books/NBK1354/>
6. Walker RH, Jung HH, Tison F, et al. Phenotypic variation among brothers with the McLeod neuroacanthocytosis syndrome. *Mov Disord* 2007;**22**: 244-8.
7. Miranda M, Castiglioni C, Frey BM, et al. Phenotypic variability of a distinct deletion in McLeod syndrome. *Mov Disord* 2007;**22**: 1358-61.
8. Danek A, Bader B, Walker RH. Antisocial behaviour and neuroacanthocytosis. *Int J Clin Pract* 2007;**61**: 1419; author reply
9. Walker RH, Danek A, Dobson-Stone C, et al. Developments in neuroacanthocytosis: expanding the spectrum of choreatic syndromes. *Mov Disord* 2006;**21**: 1794-805.
10. Balhara YP, Varghese ST, Kayal M. Neuroacanthocytosis: presenting with depression. *J Neuropsychiatry Clin Neurosci* 2006;**18**: 426.
11. Zeman A, Daniels G, Tilley L, et al. McLeod syndrome: life-long neuropsychiatric disorder due to a novel mutation of the XK gene. *Psychiatr Genet* 2005;**15**: 291-3.
12. Jung HH, Haker H. Schizophrenia as a manifestation of X-linked McLeod-Neuroacanthocytosis syndrome. *J Clin Psychiatry* 2004;**65**: 722-3.
13. Jung HH, Hergersberg M, Vogt M, et al. McLeod phenotype associated with a XK missense mutation without hematologic, neuromuscular, or cerebral involvement. *Transfusion* 2003;**43**: 928-38.
14. Walker RH, Danek A, Uttner I, et al. McLeod phenotype without the McLeod syndrome. *Transfusion* 2007;**47**: 299-305.
15. Allen FH, Jr., Krabbe SM, Corcoran PA. A new phenotype (McLeod) in the Kell blood-group system. *Vox Sang* 1961;**6**: 555-60.
16. Claperon A, Rose C, Gane P, et al. The Kell protein of the common K2 phenotype is a catalytically active metalloprotease, whereas the rare Kell K1 antigen is inactive. Identification of novel substrates for the Kell protein. *J Biol Chem* 2005;**280**: 21272-83.
17. Lee S, Lin M, Mele A, et al. Proteolytic processing of big endothelin-3 by the kell blood group protein. *Blood* 1999;**94**: 1440-50.
18. Storry JR, Castilho L, Daniels G, et al. International Society of Blood Transfusion Working Party on red cell immunogenetics and blood group terminology: Cancun report (2012). *Vox Sang* 2014;**107**: 90-6.
19. Read. *Facts book* 2013.
20. Vaughan JI, Manning M, Warwick RM, et al. Inhibition of erythroid progenitor cells by anti-Kell antibodies in fetal alloimmune anemia. *N Engl J Med* 1998;**338**: 798-803.

21. Redman CM, Russo D, Lee S. Kell, Kx and the McLeod syndrome. *Baillieres Best Pract Res Clin Haematol* 1999;**12**: 621-35.
22. Redman CM, Marsh WL. The Kell blood group system and the McLeod phenotype. *Semin Hematol* 1993;**30**: 209-18.
23. Bansal I, Jeon HR, Hui SR, et al. Transfusion support for a patient with McLeod phenotype without chronic granulomatous disease and with antibodies to Kx and Km. *Vox Sang* 2008;**94**: 216-20.
24. Moulds JM, Persa R, Rierson D, et al. Three novel alleles in the Kell blood group system resulting in the Knull phenotype and the first in a Native American. *Transfusion* 2013;**53**: 2867-71.
25. Meyer S, Vollmert C, Trost N, et al. High-throughput Kell, Kidd, and Duffy matrix-assisted laser desorption/ionization, time-of-flight mass spectrometry-based blood group genotyping of 4000 donors shows close to full concordance with serotyping and detects new alleles. *Transfusion* 2014.
26. Lee S, Russo DC, Reid ME, Redman CM. Mutations that diminish expression of Kell surface protein and lead to the Kmod RBC phenotype. *Transfusion* 2003;**43**: 1121-5.
27. Redman CM, Marsh WL, Scarborough A, et al. Biochemical studies on McLeod phenotype red cells and isolation of Kx antigen. *Br J Haematol* 1988;**68**: 131-6.
28. Francke U, Ochs HD, de Martinville B, et al. Minor Xp21 chromosome deletion in a male associated with expression of Duchenne muscular dystrophy, chronic granulomatous disease, retinitis pigmentosa, and McLeod syndrome. *Am J Hum Genet* 1985;**37**: 250-67.
29. Watkins CE, Litchfield J, Song E, et al. Chronic granulomatous disease, the McLeod phenotype and the contiguous gene deletion syndrome-a review. *Clin Mol Allergy* 2011;**9**: 13.
30. Frey D, Machler M, Seger R, et al. Gene deletion in a patient with chronic granulomatous disease and McLeod syndrome: fine mapping of the Xk gene locus. *Blood* 1988;**71**: 252-5.
31. Henderson LM, Meech RW. Evidence that the product of the human X-linked CGD gene, gp91-phox, is a voltage-gated H(+) pathway. *J Gen Physiol* 1999;**114**: 771-86.
32. Galey WR, Evan AP, Van Nice PS, et al. Morphology and physiology of the McLeod erythrocyte. I. Scanning electron microscopy and electrolyte and water transport properties. *Vox Sang* 1978;**34**: 152-61.
33. Wong P. A basis of the acanthocytosis in inherited and acquired disorders. *Med Hypotheses* 2004;**62**: 966-9.
34. Kodippili GC, Spector J, Sullivan C, et al. Imaging of the diffusion of single band 3 molecules on normal and mutant erythrocytes. *Blood* 2009;**113**: 6237-45.
35. Kodippili GC, Spector J, Hale J, et al. Analysis of the mobilities of band 3 populations associated with ankyrin protein and junctional complexes in intact murine erythrocytes. *J Biol Chem* 2012;**287**: 4129-38.
36. Salomao M, Zhang X, Yang Y, et al. Protein 4.1R-dependent multiprotein complex: new insights into the structural organization of the red blood cell membrane. *Proc Natl Acad Sci U S A* 2008;**105**: 8026-31.
37. Mohandas N, Gallagher PG. Red cell membrane: past, present, and future. *Blood* 2008;**112**: 3939-48.
38. Anong WA, Franco T, Chu H, et al. Adducin forms a bridge between the erythrocyte membrane and its cytoskeleton and regulates membrane cohesion. *Blood* 2009;**114**: 1904-12.
39. Stewart GW, Wilmore SMS, Ohono S, Terada N. Questions of cell shape. In: Walker RH, Saiki S, Danek A, eds. *Neuroacanthocytosis Syndromes II*. Berlin Heidelberg: Springer, 2008:115-32.

40. Bosman GJCGM, DeFranceschi L. Neuroacanthocytosis-related changes in erythrocyte membrane organisation and function. In: Walker RH, Saiki S, Danek A, eds. *Neuroacanthocytosis Syndromes II*. Berlin Heidelberg: Springer, 2008:133-42.
41. Perrotta S, Gallagher PG, Mohandas N. Hereditary spherocytosis. *Lancet* 2008;**372**: 1411-26.
42. Pekrun A, Eber SW, Kuhlmeier A, Schroter W. Combined ankyrin and spectrin deficiency in hereditary spherocytosis. *Ann Hematol* 1993;**67**: 89-93.
43. Wandersee NJ, Olson SC, Holzhauer SL, et al. Increased erythrocyte adhesion in mice and humans with hereditary spherocytosis and hereditary elliptocytosis. *Blood* 2004;**103**: 710-6.
44. Savvides P, Shalev O, John KM, Lux SE. Combined spectrin and ankyrin deficiency is common in autosomal dominant hereditary spherocytosis. *Blood* 1993;**82**: 2953-60.
45. Lane PA, Shew RL, Iarocci TA, et al. Unique alpha-spectrin mutant in a kindred with common hereditary elliptocytosis. *J Clin Invest* 1987;**79**: 989-96.
46. Coetzer TL, Lawler J, Liu SC, et al. Partial ankyrin and spectrin deficiency in severe, atypical hereditary spherocytosis. *N Engl J Med* 1988;**318**: 230-4.
47. Coetzer TL, Palek J. Partial spectrin deficiency in hereditary pyropoikilocytosis. *Blood* 1986;**67**: 919-24.
48. Albuissou J, Murthy SE, Bandell M, et al. Dehydrated hereditary stomatocytosis linked to gain-of-function mutations in mechanically activated PIEZO1 ion channels. *Nat Commun* 2013;**4**: 1884.
49. Delaunay J, Stewart G, Iolascon A. Hereditary dehydrated and overhydrated stomatocytosis: recent advances. *Curr Opin Hematol* 1999;**6**: 110-4.
50. De Franceschi L, Bosman GJ, Mohandas N. Abnormal red cell features associated with hereditary neurodegenerative disorders: the neuroacanthocytosis syndromes. *Curr Opin Hematol* 2014;**21**: 201-9.
51. De Franceschi L, Scardoni G, Tomelleri C, et al. Computational identification of phospho-tyrosine sub-networks related to acanthocyte generation in neuroacanthocytosis. *PLoS One* 2012;**7**: e31015.
52. Matte A, Bertoldi M, Mohandas N, et al. Membrane association of peroxiredoxin-2 in red cells is mediated by the N-terminal cytoplasmic domain of band 3. *Free Radic Biol Med* 2012;**55**: 27-35.
53. Puchulu-Campanella E, Chu H, Anstee DJ, et al. Identification of the components of a glycolytic enzyme metabolon on the human red blood cell membrane. *J Biol Chem* 2012;**288**: 848-58.
54. Slavova-Azmanova NS, Kucera N, Satiaputra J, et al. Gain-of-function Lyn induces anemia: appropriate Lyn activity is essential for normal erythropoiesis and Epo receptor signaling. *Blood* 2013;**122**: 262-71.
55. De Franceschi L, Tomelleri C, Matte A, et al. Erythrocyte membrane changes of chorea-acanthocytosis are the result of altered Lyn kinase activity. *Blood* 2011;**118**: 5652-63.
56. Perrotta S, Borriello A, Scaloni A, et al. The N-terminal 11 amino acids of human erythrocyte band 3 are critical for aldolase binding and protein phosphorylation: implications for band 3 function. *Blood* 2005;**106**: 4359-66.
57. Pantaleo A, Ferru E, Giribaldi G, et al. Oxidized and poorly glycosylated band 3 is selectively phosphorylated by Syk kinase to form large membrane clusters in normal and G6PD-deficient red blood cells. *Biochem J* 2009;**418**: 359-67.
58. Olivieri O, De Franceschi L, Bordin L, et al. Increased membrane protein phosphorylation and anion transport activity in chorea-acanthocytosis. *Haematologica* 1997;**82**: 648-53.

59. Bassen FA, Kornzweig AL. Malformation of the erythrocytes in a case of atypical retinitis pigmentosa. *Blood* 1950;**5**: 381-87.
60. Hentati F, El-Euch G, Bouhlal Y, Amouri R. Ataxia with vitamin E deficiency and abetalipoproteinemia. *Handb Clin Neurol* 2011;**103**: 295-305.
61. <http://emedicine.medscape.com/article/954356-differential>. 2014.
62. Storch A, Kornhass M, Schwarz J. Testing for acanthocytosis A prospective reader-blinded study in movement disorder patients. *J Neurol* 2005;**252**: 84-90.
63. Rivera A, Kam SY, Ho M, et al. Ablation of the Kell/Xk complex alters erythrocyte divalent cation homeostasis. *Blood Cells Mol Dis* 2013;**50**: 80-5.
64. Foller M, Hermann A, Gu S, et al. Chorein-sensitive polymerization of cortical actin and suicidal cell death in chorea-acanthocytosis. *FASEB J* 2012;**26**: 1526-34.
65. Romero JR, Markovic A, Schorer G, et al. Alterations in Magnesium and Potassium but not Sodium transporters characterize McLeod Syndrome erythrocytes. *3rd Joint Symposium on Neuroacanthocytosis and Neurodegeneration with Brain Iron Accumulation, 2014, Stresa/Italy 2014*.
66. Siegl C, Hamming P, Jank H, et al. Alterations of red cell membrane properties in neuroacanthocytosis. *PLoS One* 2013;**8**: e76715.
67. Bertelson CJ, Pogo AO, Chaudhuri A, et al. Localization of the McLeod locus (XK) within Xp21 by deletion analysis. *Am J Hum Genet* 1988;**42**: 703-11.
68. Danek A, Rubio JP, Rampoldi L, et al. McLeod neuroacanthocytosis: genotype and phenotype. *Ann Neurol* 2001;**50**: 755-64.
69. Danek A, Walker RH. Neuroacanthocytosis. *Curr Opin Neurol* 2005;**18**: 386-92.
70. Lee S, Sha Q, Wu X, et al. Expression profiles of mouse Kell, XK, and XPLAC mRNA. *J Histochem Cytochem* 2007;**55**: 365-74.
71. Ho M, Chelly J, Carter N, et al. Isolation of the gene for McLeod syndrome that encodes a novel membrane transport protein. *Cell* 1994;**77**: 869-80.
72. Subcellular locations from UniProtKB/Swiss-Prot, 2014.
73. Russo D, Redman C, Lee S. Association of XK and Kell blood group proteins. *J Biol Chem* 1998;**273**: 13950-6.
74. De Franceschi L, Olivieri O, Miraglia del Giudice E, et al. Membrane cation and anion transport activities in erythrocytes of hereditary spherocytosis: effects of different membrane protein defects. *Am J Hematol* 1997;**55**: 121-8.
75. De Franceschi L, Rivera A, Fleming MD, et al. Evidence for a protective role of the Gardos channel against hemolysis in murine spherocytosis. *Blood* 2005;**106**: 1454-9.
76. Hoffman JF, Joiner W, Nehrke K, et al. The hSK4 (KCNN4) isoform is the Ca²⁺-activated K⁺ channel (Gardos channel) in human red blood cells. *Proc Natl Acad Sci U S A* 2003;**100**: 7366-71.
77. Kucherenko YV, Wagner-Britz L, Bernhardt I, Lang F. Effect of chloride channel inhibitors on cytosolic Ca²⁺ levels and Ca²⁺-activated K⁺ (Gardos) channel activity in human red blood cells. *J Membr Biol* 2013;**246**: 315-26.
78. Ataga KI, Smith WR, De Castro LM, et al. Efficacy and safety of the Gardos channel blocker, senicapoc (ICA-17043), in patients with sickle cell anemia. *Blood* 2008;**111**: 3991-7.
79. Tissue-specific pattern of gene expression of KCNN4, 2014.
80. Lipskaia L, Chemaly ER, Hadri L, et al. Sarcoplasmic reticulum Ca(2+) ATPase as a therapeutic target for heart failure. *Expert Opin Biol Ther* 2010;**10**: 29-41.
81. Striessnig J, Koschak A, Sinnegger-Brauns MJ, et al. Role of voltage-gated L-type Ca²⁺ channel isoforms for brain function. *Biochem Soc Trans* 2006;**34**: 903-9.

82. Lam J, Coleman N, Garing AL, Wulff H. The therapeutic potential of small-conductance KCa₂ channels in neurodegenerative and psychiatric diseases. *Expert Opin Ther Targets* 2013;**17**: 1203-20.
83. Kuiper EF, Nelemans A, Luiten P, et al. K(Ca)₂ and k(ca)₃ channels in learning and memory processes, and neurodegeneration. *Front Pharmacol* 2012;**3**: 107.
84. Tani Y, Takahashi J, Tanaka M, Shibata H. McLeod Syndrome: A perspective from Japanese Blood Centers. In: Walker RW, Saiki S, Danek A, eds. *Neuroacanthocytosis Syndromes II*. Berlin Heidelberg: Springer, 2008:143-50.
85. Gantenbein AR, Damon-Perriere N, Bohlender JE, et al. Feeding dystonia in McLeod syndrome. *Mov Disord* 2011;**26**: 2123-6.
86. Oechslin E, Kaup D, Jenni R, Jung HH. Cardiac abnormalities in McLeod syndrome. *Int J Cardiol* 2009;**132**: 130-2.
87. Siderow A, Ries J, Grossrieder B, et al. Association of X-linked chronic granulomatous disease with the rare McLeod phenotype - A case report. *Transfusion Medicine and Hemotherapy* 2009;**36**: P1.16.
88. Honig M, Flegel WA, Schwarz K, et al. Successful hematopoietic stem-cell transplantation in a patient with chronic granulomatous disease and McLeod phenotype sensitized to Kx and K antigens. *Bone Marrow Transplant* 2009;**45**: 209-11.

Figure 1

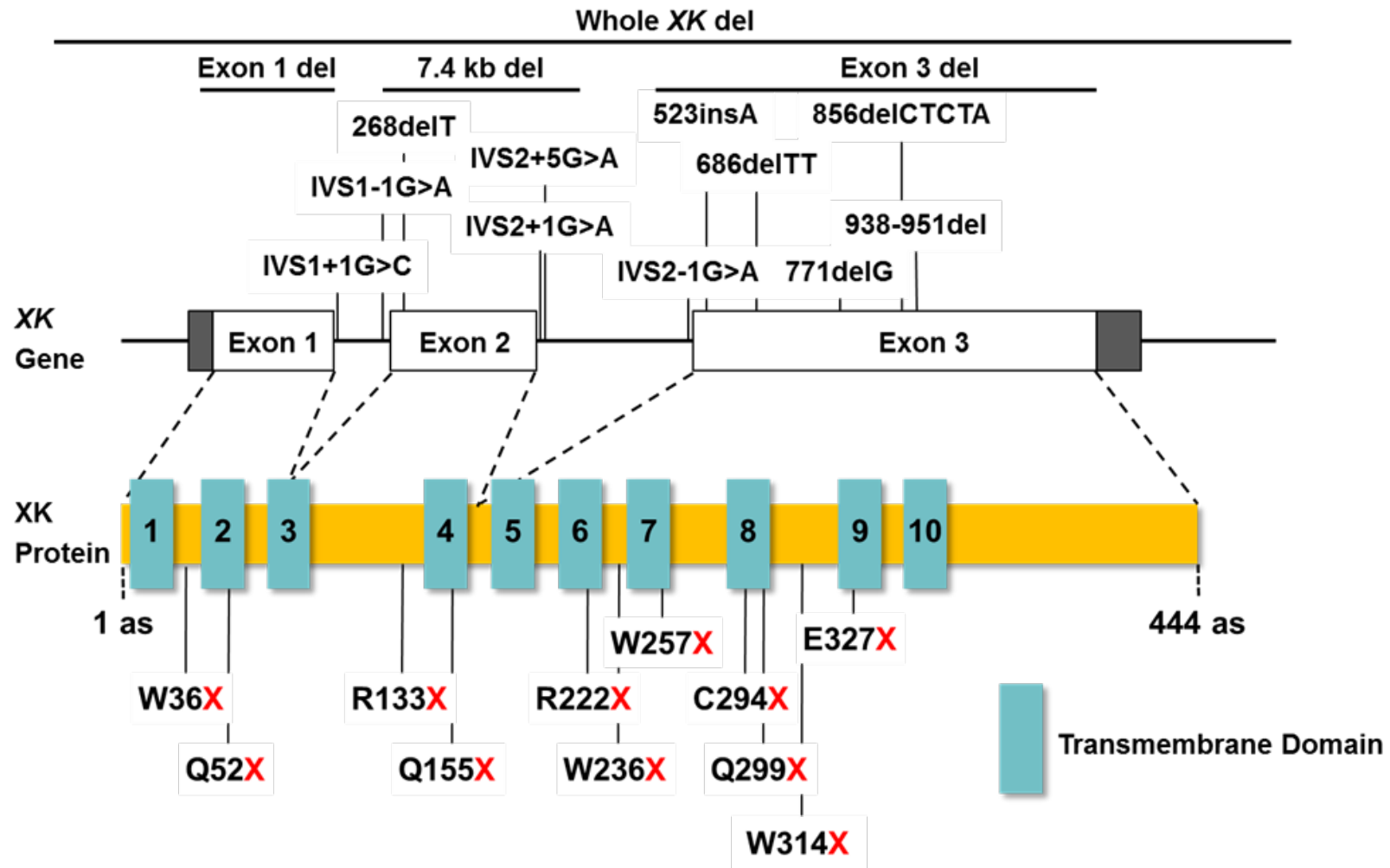
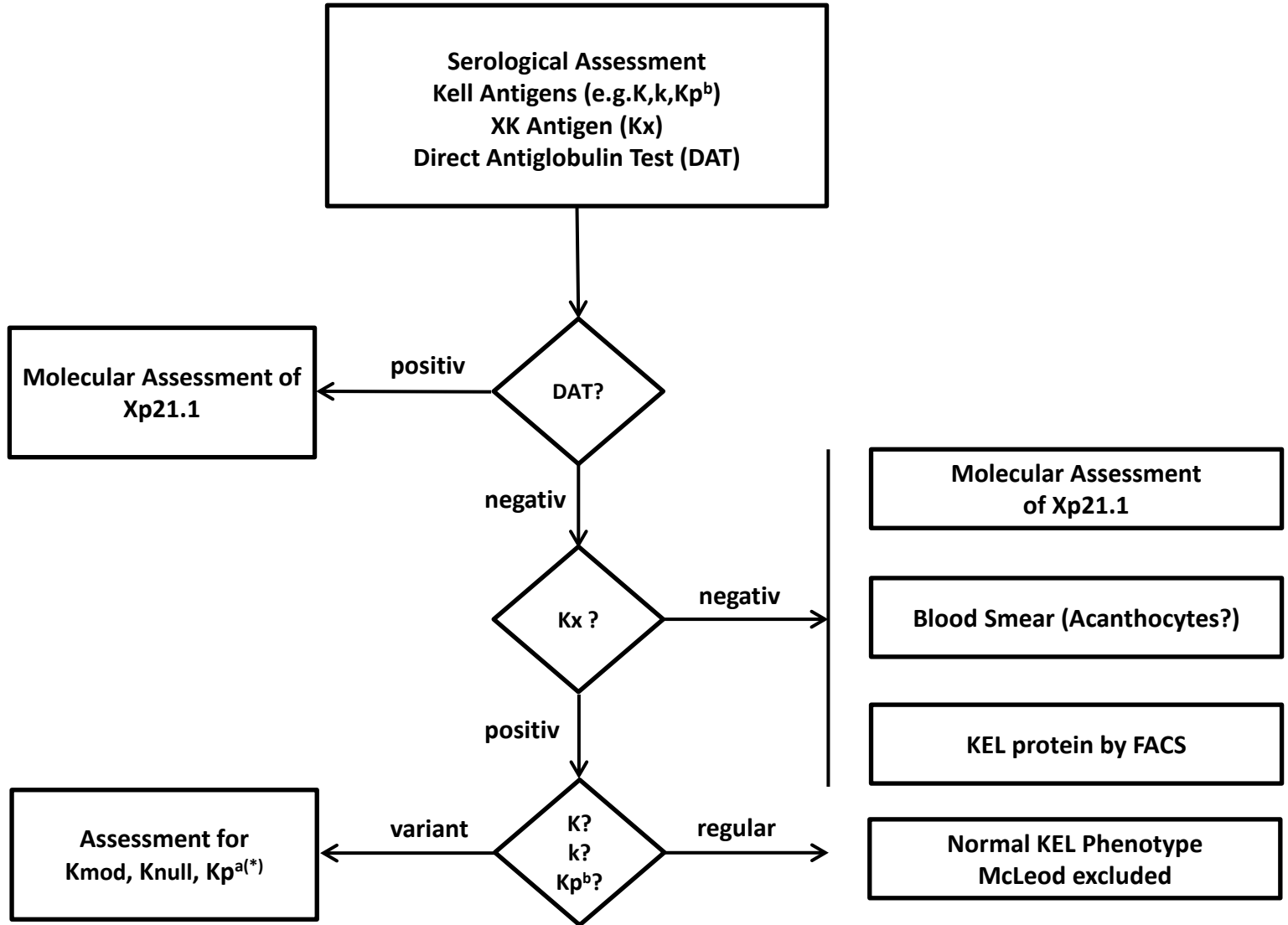


Figure 2



(*) Kp^a may explain weak expression of KEL antigens

Table 1

Disorder Phenotype	ChAc	MLS	HDL2	PKAN
Gene/ Chromosome	<i>VPS13A</i> /9q21	<i>XK</i> /Xp21.1	<i>JPH3</i> /16q24.3	<i>PANK2</i> /20p13
Protein	Chorein	XK protein	Junctophilin-3	Pantothenate kinase 2
Inheritance	autosomal/recessive	X-linked/recessive	autosomal/dominant	autosomal/recessive
Hemolytic anemia	none	yes (not always)	none	none
Acanthocytes	+++	++	+/-	+/-
Serum CK	increased	increased	normal	normal
Neuroimaging abnormalities	striatal	striatal	striatal/ cortical	striatal "Eye of the tiger"
Age of onset	20 - 30	25 - 60	20 - 40	< 16
Chorea	+++	+++	+++	+++
Other movement Disorders	dystonia lip biting parkinsonism	vocalization	dystonia, parkinsonism	dystonia parkinsonism spasticity
Seizures	yes	yes	none	none
Neuromuscular defects	areflexia atrophy	areflexia atrophy	none	none
Cardiac affection	none	arrhythmias cardiomyopathia sudden cardiac death	none	none