



**University of
Zurich**^{UZH}

**Zurich Open Repository and
Archive**

University of Zurich
University Library
Strickhofstrasse 39
CH-8057 Zurich
www.zora.uzh.ch

Year: 2015

Beauty and the biologic: artistic documentation of scientific breakthrough in psoriasis

Maul, Julia-Tatjana ; Carraro, Sabina ; Stierlin, Johanna ; Geiges, Michael L ; Navarini, Alexander A

DOI: <https://doi.org/10.1159/000439583>

Posted at the Zurich Open Repository and Archive, University of Zurich

ZORA URL: <https://doi.org/10.5167/uzh-121199>

Journal Article

Published Version



The following work is licensed under a Creative Commons: Attribution-NonCommercial 4.0 International (CC BY-NC 4.0) License.

Originally published at:

Maul, Julia-Tatjana; Carraro, Sabina; Stierlin, Johanna; Geiges, Michael L; Navarini, Alexander A (2015). Beauty and the biologic: artistic documentation of scientific breakthrough in psoriasis. *Case Reports in Dermatology*, 7(3):249-252.

DOI: <https://doi.org/10.1159/000439583>

Beauty and the Biologic: Artistic Documentation of Scientific Breakthrough in Psoriasis

Julia-Tatjana Maul^a Sabina Carraro^b Johanna Stierlin^b
Michael L. Geiges^{a, b} Alexander A. Navarini^a

^aDepartment of Dermatology and ^bMuseum of Wax Moulages, University Hospital Zurich, Zurich, Switzerland

Key Words

Psoriasis · Biologics · Wax moulage

Abstract

The making of wax moulages was an exclusive and sought-after art that was primarily used for teaching, but also to document clinical and laboratory research during the first half of the 20th century. Applying the technique of moulage-making to document a case of psoriasis improvement for posterity, a moulage of the trunk of a patient with psoriasis vulgaris was taken prior to treatment with biologics – adalimumab, a TNF- α antagonist – and again 3 month after adalimumab was first given. Our modern moulage shows in the most realistic way the science-driven improvement of psoriasis achievable nowadays with biologics. However, the real clinical picture of the disease is shrouded by showing only one detail of the patient – by accident the one with the best clinical improvement. All available techniques to document skin disease have advantages and limitations and nothing beats seeing live patients.

© 2015 The Author(s)
Published by S. Karger AG, Basel

Introduction

Dermatologists have witnessed the many new successes in psoriasis treatment that are documented by improvement of the Psoriasis Area and Severity Index (PASI). It measures four aspects of disease activity, namely reduction of erythema, scaling and infiltration as well as area involved. All components of PASI can be documented by photography, except for

infiltration, which until today has to be felt by touching the actual lesions. This information is lost on photography, which precludes retrospective PASI scoring based on pictures.

Moulage-making was an exclusive and sought-after art that was primarily used for teaching, but also to document clinical and laboratory research during the first half of the 20th century [1, 2]. The largest collections of moulages remaining today are in Paris, Zürich (www.moulagen.ch), Vienna, Bonn and Athens. Moulages were essentially utilized as life-size casts of actual patients' skin lesions to demonstrate dermatoses to medical students [3]. When photography became popular in the 19th century, moulages were eventually replaced by color slides that were quicker and cheaper to generate.

However, conventional photography has several drawbacks. It greatly depends on the type and direction of illumination, including flash, contains shadows, visual artefacts arising from perspective and distance from the subject, as well as distortion of colors. Digital photography has added chromatic aberration at the picture edges, blooming (indicating local overexposure) and, most prominently, the usual curse when trying to publish a picture: JPEG compression artefacts.

Moulages, instead, are based on an actual cast of the dermatosis in question and can therefore more accurately reproduce the dimensions of skin lesions. The most prominent difference is their life size and three-dimensionality. Also, in contrast to photography, some non-essential elements such as overgrowth of hair can be omitted. However, moulages have important limitations, too – each example is expensive and unique, can reproduce only a limited area of the body and requires careful conservation.

Methods

We applied the technique of making wax moulages to document a case of psoriasis improvement for posterity. In most places this technique was kept a secret and got lost over time. The Museum of Wax Moulages in Zurich and the Deutsches Hygienemuseum in Dresden are the only institutions that succeeded in preserving the original technique, including the recipes for the wax mixtures [4]. In Zurich, the moulageuse Elsbeth Stoiber passed on her technique to Michael Geiges in 1998 [5]. Sabina Carraro and Johanna Stierlin are using this same technique to form duplicates or new moulages. Up to present, the Museum of Wax Moulages is the only place where moulages are being fabricated again. As an exception, Navena Widulin from the Berlin Museum of Medical History at the Charité was introduced to the Zurich technique by Michael Geiges in 2004, which resulted in a small collection of forensic wax moulages exhibited on several occasions.

The moulage is cast using a silicone negative formed directly from the patient's back using a mixture of bleached bees wax, calcium carbonate and dammar resin. The wax replica is colored using oil-based paint (cobalt blue, carmine dark, bitumen and gamboge), traditionally next to the patient who acts as a model. The coloring is very time-consuming. In our case, because of the outpatient setting, numerous differently illuminated photographic pictures served as templates.

Case Description

A 57-year-old architect presented with moderate-to-severe plaque-type psoriasis that had first appeared in 2008. Topical therapy with steroid, calcipotriol and salicylic acid, followed by phototherapy with narrow-band UVB and methotrexate therapy, were unable to

reach PASI50. Therefore, at a PASI of 12.7, therapy with adalimumab was initiated and the most prominent plaques on the lower back documented by wax moulage. Three months later, the lower back was almost completely clear of lesions. The wax cast demonstrated the improvement of infiltration from an average elevation from the skin surface of >1 mm to 0 mm (fig. 1) [6]. However, the patient had not reached the clinical threshold of PASI50 overall, as his PASI was still at 10.4 (table 1).

Discussion

Our modern moulage shows both the science-driven improvement of psoriasis achievable nowadays with biologics, but also how exquisitely dependent on the choice of location the art of moulage really was with its restricted area of reproduction. This effect – namely that the rest of the patient remains unseen – is easily forgotten when admiring the surviving moulages in the museum. Taken together, all available techniques to document skin diseases have advantages and limitations – and for learning dermatology, nothing beats seeing actual live patients.

Statement of Ethics

The authors have no ethical conflicts to disclose.

Disclosure Statement

The authors declare no conflict of interest.

References

- 1 Bray FN, Simmons BJ, Falto-Aizpurua LA, Griffith RD, Nouri K: Moulage: the decaying art of dermatology. *JAMA Dermatol* 2015;151:480.
- 2 Geiges ML: Traces of Marion B. Sulzberger in the Museum of Wax Moulages in Zurich and their importance for the history of dermatology. *J Am Acad Dermatol* 2009;60:980–984.
- 3 Miescher G: Dermatologische Klinik; in *Zürcher Spitalgeschichte*, vol II. Zürich, Regierungsrat des Kantons Zürich, 1951, pp 345–351.
- 4 Lang J, Mühlenberend S, Roessiger S: Körper in Wachs. Moulagen in Forschung und Restaurierung. *Sammlungsschwerpunkte*, vol. 3. Dresden, Sandstein-Verlag, 2010.
- 5 Geiges M: The Museum of Wax Moulages in Zurich – current relevance for dermatology, history of medicine and the general public (in German). *J Dtsch Dermatol Ges* 2007;5:953–957.
- 6 Paulsen E, Korsholm L, Brandrup F: A double-blind, placebo-controlled study of a commercial *Aloe vera* gel in the treatment of slight to moderate psoriasis vulgaris. *J Eur Acad Dermatol Venereol* 2005;19:326–331.

M.L. Geiges and A.A. Navarini contributed equally to this work.

Table 1. PASI and local PASI improvement during treatment with biologics

		Scores
<i>Week 0</i>		
Erythema	overall 3/4, local 3/4	PASI 12.7
Scaling	overall 3/4, local 2/4	local PASI 7
Infiltration	overall 3/4, local 2/4	PGA 3/4
Body surface area	overall 20%, local 5%	
<i>Week 12</i>		
Erythema	overall 3/4, local 0/4	PASI 10.4
Scaling	overall 3/4, local 0/4	local PASI 0
Infiltration	overall 3/4, local 0/4	PGA 0/3
Body surface area	overall 15%, local 0%	

PGA = Physician Global Assessment.

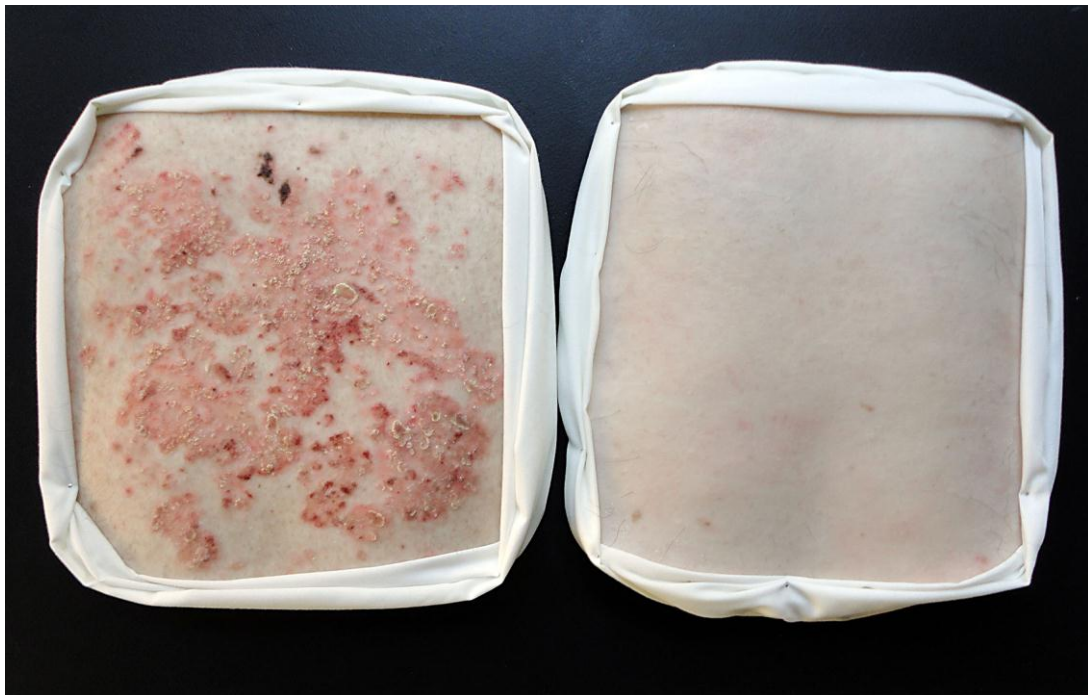


Fig. 1. Wax moulage of a psoriasis patient treated with biologics. A moulage of the trunk was taken in a psoriasis vulgaris patient prior to treatment with biologics – adalimumab, a TNF- α antagonist (August 12, 2014) and 3 months after adalimumab was first given (November 10, 2014). Wax moulages made by Johanna Stierlin and Sabina Carraro, Museum of Wax Moulages, Zurich.