



---

Year: 2018

---

## Ultrasound-guided pericardiocentesis: a novel parasternal approach

Osman, Adi ; Wan Chuan, Tan ; Ab Rahman, Jamalludin ; Via, Gabriele ; Tavazzi, Guido

**Abstract:** **OBJECTIVE:** The aim of this study was to evaluate a novel pericardiocentesis technique using an in-plane parasternal medial-to-lateral approach with the use of a high-frequency probe in patients with cardiac tamponade. **BACKGROUND:** Echocardiography is pivotal in the diagnosis of pericardial effusion and tamponade physiology. Ultrasound guidance for pericardiocentesis is currently considered the standard of care. Several approaches have been described recently, which differ mainly on the site of puncture (subxiphoid, apical, or parasternal). Although they share the use of low-frequency probes, there is absence of complete control of needle trajectory and real-time needle visualization. An in-plane and real-time technique has only been described anecdotally. **METHODS AND RESULTS:** A retrospective analysis of 11 patients (63% men, mean age:  $37.7 \pm 21.2$  years) presenting with cardiac tamponade admitted to the tertiary-care emergency department and treated with parasternal medial-to-lateral in-plane pericardiocentesis was carried out. The underlying causes of cardiac tamponade were different among the population. All the pericardiocentesis were successfully performed in the emergency department, without complications, relieving the hemodynamic instability. The mean time taken to perform the eight-step procedure was  $309 \pm 76.4$  s, with no procedure-related complications. **CONCLUSION:** The parasternal medial-to-lateral in-plane pericardiocentesis is a new technique theoretically free of complications and it enables real-time monitoring of needle trajectory. For the first time, a pericardiocentesis approach with a medial-to-lateral needle trajectory and real-time, in-plane, needle visualization was performed in a tamponade patient population. This is an open-access article distributed under the terms of the Creative Commons Attribution-Non Commercial-No Derivatives License 4.0 (CCBY-NC-ND), where it is permissible to download and share the work provided it is properly cited. The work cannot be changed in any way or used commercially without permission from the journal. <http://creativecommons.org/licenses/by-nc-nd/4.0/>.

DOI: <https://doi.org/10.1097/MEJ.0000000000000471>

Posted at the Zurich Open Repository and Archive, University of Zurich

ZORA URL: <https://doi.org/10.5167/uzh-145455>

Journal Article

Published Version

Originally published at:

Osman, Adi; Wan Chuan, Tan; Ab Rahman, Jamalludin; Via, Gabriele; Tavazzi, Guido (2018). Ultrasound-guided pericardiocentesis: a novel parasternal approach. *European Journal of Emergency Medicine*, 25(5):322-327.

DOI: <https://doi.org/10.1097/MEJ.0000000000000471>

# Ultrasound-guided pericardiocentesis: a novel parasternal approach

Adi Osman<sup>a,\*</sup>, Tan Wan Chuan<sup>a,\*</sup>, Jamalludin Ab Rahman<sup>b</sup>, Gabriele Via<sup>c</sup> and Guido Tavazzi<sup>d,e</sup>

**Objective** The aim of this study was to evaluate a novel pericardiocentesis technique using an in-plane parasternal medial-to-lateral approach with the use of a high-frequency probe in patients with cardiac tamponade.

**Background** Echocardiography is pivotal in the diagnosis of pericardial effusion and tamponade physiology. Ultrasound guidance for pericardiocentesis is currently considered the standard of care. Several approaches have been described recently, which differ mainly on the site of puncture (subxiphoid, apical, or parasternal). Although they share the use of low-frequency probes, there is absence of complete control of needle trajectory and real-time needle visualization. An in-plane and real-time technique has only been described anecdotally.

**Methods and results** A retrospective analysis of 11 patients (63% men, mean age:  $37.7 \pm 21.2$  years) presenting with cardiac tamponade admitted to the tertiary-care emergency department and treated with parasternal medial-to-lateral in-plane pericardiocentesis was carried out. The underlying causes of cardiac tamponade were different among the population. All the pericardiocentesis were successfully performed in the emergency department, without complications, relieving the hemodynamic instability. The mean time taken to perform the eight-step procedure was  $309 \pm 76.4$  s, with no procedure-related complications.

## Introduction

Cardiac tamponade represents a life-threatening complication of pericardial effusion where prompt recognition and treatment are essential for a favorable outcome [1].

The physiological intrapericardial pressure ranges from  $-5$  to  $+5$  mmHg, along with intrathoracic pressure, during the respiratory cycle. The normal pressure–volume curve of pericardium is a J-shaped curve with an initial shallow portion, which allows the pericardium to stretch slightly in response to volume or postural changes, and a steep part

**Conclusion** The parasternal medial-to-lateral in-plane pericardiocentesis is a new technique theoretically free of complications and it enables real-time monitoring of needle trajectory. For the first time, a pericardiocentesis approach with a medial-to-lateral needle trajectory and real-time, in-plane, needle visualization was performed in a tamponade patient population. *European Journal of Emergency Medicine* 00:000–000 Copyright © 2017 The Author(s). Published by Wolters Kluwer Health, Inc.

*European Journal of Emergency Medicine* 2017, 00:000–000

**Keywords:** cardiac tamponade, focused cardiac ultrasound, pericardiocentesis, point of care ultrasound, procedural guidance, ultrasound-guided pericardiocentesis

<sup>a</sup>Emergency and Trauma Department, Raja Permaisuri Bainun Hospital, Jalan Raja Ashman (Jalan Hospital), Ipoh, Perak, <sup>b</sup>Department of Community Medicine, Faculty of Medicine, International Islamic University, Kuantan, Pahang, Malaysia, <sup>c</sup>Cardiac Anesthesia & Intensive Care – Cardiocentro Ticino, Lugano, Switzerland, <sup>d</sup>Emergency Department, Anaesthesia and Intensive Care Unit, Fondazione IRCCS Policlinico S. Matteo and <sup>e</sup>Department of Clinical, Surgical, Diagnostic and Paediatric Sciences, Anaesthesia, Intensive Care and Pain Therapy Unit, University of Pavia, Pavia, Italy

Correspondence to Adi Osman, MD, Hospital Raja Permaisuri Bainun, 30450 Ipoh, Perak, Malaysia  
Tel: +60 125 390 911; fax: +60 52 425 033; e-mail: osman.adi@gmail.com

\*Adi Osman and Tan Wan Chuan contributed equally to the writing of this article.

Received 29 November 2016 Accepted 18 April 2017

indicating increases in pressure. This means that sudden accumulation of limited quantity of fluid, faster than it can be absorbed, may lead to a significant increase in pericardial pressure and eventually to cardiac tamponade. In contrast, a slow but constant pericardial distension may result in accumulation of considerable amount of fluid, such as 1–2 l, with only a modest increase in pericardial pressure and no hemodynamic consequences [2].

For the same reason, the clinical presentation of pericardial effusion varies accordingly with the speed of accumulation and etiology, with symptoms related to the causative disease (decompensated heart failure or infective process) [3].

Although cardiac tamponade is essentially a clinical diagnosis, on the basis of elevated systemic venous pressure, tachycardia, dyspnea, and paradoxical arterial pulse, which is frequently accompanied by hypotension,

Supplemental digital content is available for this article. Direct URL citations appear in the printed text and are provided in the HTML and PDF versions of this article on the journal's website ([www.euro-emergencymed.com](http://www.euro-emergencymed.com)).

This is an open-access article distributed under the terms of the Creative Commons Attribution-Non Commercial-No Derivatives License 4.0 (CCBY-NC-ND), where it is permissible to download and share the work provided it is properly cited. The work cannot be changed in any way or used commercially without permission from the journal.

echocardiography is still the standard of care to confirm the presence and hemodynamic consequences of the tamponade [4].

Echocardiography-guided pericardiocentesis is the current technique of choice, which has the highest rate of procedural success and the lowest rate of major complications compared with blind or surgical methods [5].

Several methods have been described to date (parasternal, apical, or subxiphoid), but the best approach for draining pericardial effusion is controversial as the procedure selection often depends on the patient's characteristics and local hospital expertise [5]. The common techniques use low-frequency probes guiding the needle insertion to where the largest fluid collection is observed and how the needle trajectory avoids vital structures [5–11].

The parasternal in-plane and real-time technique has only been described anecdotally [12,13].

We hypothesized that a novel in-plane parasternal medial-to-lateral approach using a high-frequency probe would provide additional benefits in terms of feasibility and safety with a real-time procedure monitoring and avoiding liver, internal thoracic vessels, and lung [11]. Here, we have described our preliminary experience using this novel approach in the emergency and critical care setting of tamponade and the technical details.

## Patients and methods

### Patient population

All patients (11; 63% were men and the mean age was  $37.6 \pm 21.2$  years) who were admitted to the emergency department (ED) of a tertiary-care centre (Hospital Raja Permaisuri Bainun, Ipoh, Malaysia) from January 2013 to July 2015 and treated for cardiac tamponade by emergency pericardiocentesis with parasternal medial-to-lateral approach were retrospectively enrolled.

The National Institute of Health Malaysia approved the publication and informed consent was obtained from all the patients or their next of kin. Demographic and clinical data were collected at the time of ED admission on the basis of the patients' records. Demographic and cardiac ultrasound data were reviewed for the purpose of data analysis. Patients' characteristics are summarized in Table 1.

### Cardiac ultrasound

Pericardial effusion was initially evaluated with a focused cardiac ultrasound [14] protocol for shock assessment as part of our standard ED practice. The diagnosis of cardiac tamponade was made on the basis of clinical and echocardiographic findings according to the European Association of Cardiovascular Imaging criteria [15]. Two emergency physicians (O.A. and T.W.C), Focused Cardiac Ultrasound certified [14], performed the procedure. A GE Logiq E

ultrasound machine with a cardiac phased array probe (1.7–4.0 MHz) and a linear probe were used. Maximum pericardial layer separation was measured to quantify the effusion [15].

After cardiac ultrasound examination, the parasternal view was obtained with a linear probe (4.0–12 MHz) and the parasternal cardiac notch was visualized and the distance from the skin to the pericardium and effusion diameter was measured. An effusion of more than 1 cm in the parasternal window was considered suitable for the in-plane pericardiocentesis technique.

The pericardiocentesis procedure was performed following eight steps:

#### **Step 1: patient and ultrasound positioning**

An ultrasound machine was positioned to the left of the patient, who was kept supine throughout the procedure, and the operator on the right, allowing a direct view of the ultrasound screen after optimal ultrasound setting adjustment (Fig. 1).

#### **Step 2: patient and ultrasound preparation**

The skin overlying the left chest was prepped and draped in a sterile manner, and the ultrasound transducer was covered with a sterile sheath.

#### **Step 3: thoracic ultrasound and reference points visualization**

Left thoracic ultrasound examination, using the high-frequency linear probe to identify the sternum bone (Fig. 2), internal thoracic vessel, lung sliding, pericardial effusion, and myocardial border (right ventricle), was performed and the best needle insertion area (measuring the maximal parietal-to-visceral pericardial distance) was identified (Fig. 3, Video 1, Supplemental digital content 1, <http://links.lww.com/EJEM/A165>).

#### **Step 4: ultrasound setting optimization**

Depth of the sector on the screen and focus position was adjusted so that only the pericardial effusion and the right ventricle were visible.

#### **Step 5: needle insertion**

An in-plane medial-to-lateral approach with a 45° angle was used to visualize the needle trajectory and its entrance into the pericardial space (Fig. 4, Video 1, Supplemental digital content 1, <http://links.lww.com/EJEM/A165>).

#### **Step 6: microbubble test confirmation and hemodynamic stabilization**

Using the same parasternal view with a high-frequency linear probe, a normal saline–air microbubble was systematically injected through the needle while its position was monitored by ultrasonography, creating a 'rocket flare' appearance. (Fig. 5, Video 1, Supplemental digital content 1, <http://links.lww.com/EJEM/A165>). The first

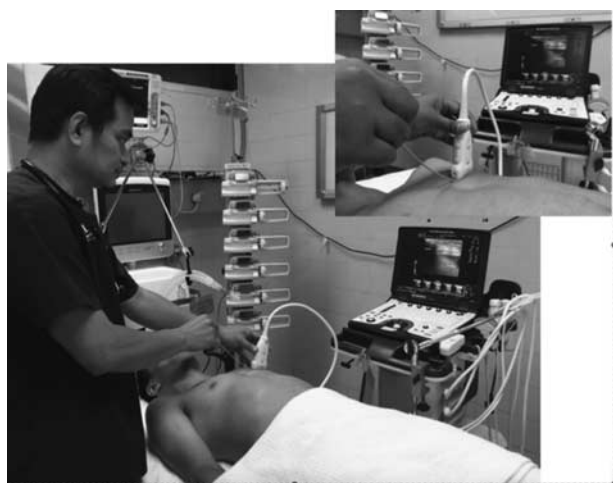**Table 1 Patients' demographics, findings, and hemodynamic data before pericardiocentesis and after pericardiocentesis**

Patients	Age (years)	Mean BP pre (mmHg)	Mean BP post (mmHg)	HR pre (mmHg)	HR post (mmHg)	Fluid during procedure (ml)	Total fluid during hospital stay (ml)	Skin to pericardium distance (cm)	Time to needle in (min:s)	Time to cath in (min:s)	Maximum effusion diameter (mm)
1	21	49	105	140	101	300	520	1.5	01:10	03:10	24
2	51	70	80	91	60	1490	1980	1.2	01:20	03:50	20
3	25	50	67	100	72	1080	2550	2.0	02:30	03:00	17
4	71	54	98	120	98	490	2100	1.6	02:40	05:10	20
5	69	53	92	100	71	600	900	1.3	00:50	03:00	26
6	54	52	94	156	100	330	600	2.0	02:30	03:20	24
7	5	52	77	170	120	110	200	1.0	02:00	03:40	12
8	37	63	77	155	112	300	1030	1.3	00:40	03:30	20
9	30	53	77	153	100	580	1000	1.8	02:10	05:00	16
10	19	57	90	95	78	900	1050	1.6	01:50	04:00	14
11	32	44	104	102	82	750	1200	1.2	01:30	03:00	20
Minimum	5	44	67	91	60	110	200	1.0	00:40	03:00	12
Maximum	71	70	105	170	120	1490	2550	2.0	02:40	05:10	26
Mean	32	53 <sup>a</sup>	90 <sup>a</sup>	120	98	580	1030	1.5	01:50	03:30	20
SD	20	6.72 <sup>b</sup>	11 <sup>b</sup>	28	17.9	385	690	0.3	00:39	00:43	4

BP, blood pressure; Cath, catheter; HR, heart rate; IQR, interquartile, range; Post, postprocedure (pericardiocentesis); Pre, preprocedure (pericardiocentesis).

<sup>a</sup>Median.

<sup>b</sup>IQR.

**Fig. 1**


Ultrasound and patient position. The needle entry was inserted from medial-to-lateral on the patient's left chest (small picture).

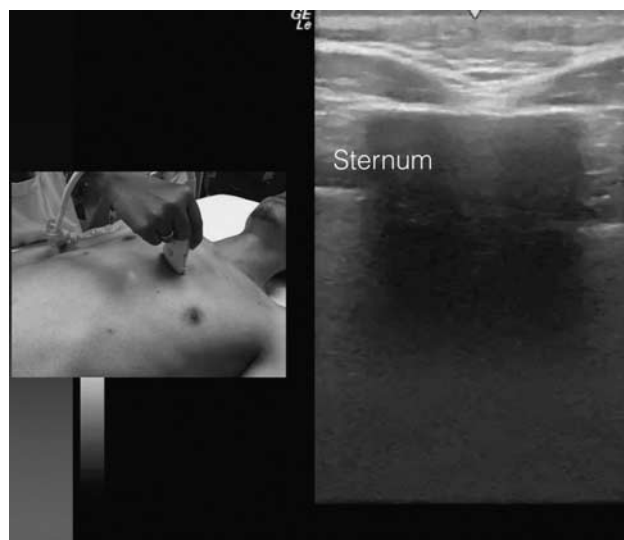amount of fluid was drained with a syringe connected to the catheter by a three-way stopcock until hemodynamic stabilization occurred.

#### Step 7: wire and catheter position

A guide wire was placed under real-time visualization and a standard Seldinger technique was used to dilate the subcutaneous space after the needle removal. Then, a single lumen catheter was placed into the pericardial space (Video 2, Supplemental digital content 2, <http://links.lww.com/EJEM/A166>).

#### Step 8: pericardial drainage and monitoring

After pericardial drainage, the catheter was left in place and ultrasound was repeated every 24 h, or as dictated by

**Fig. 2**

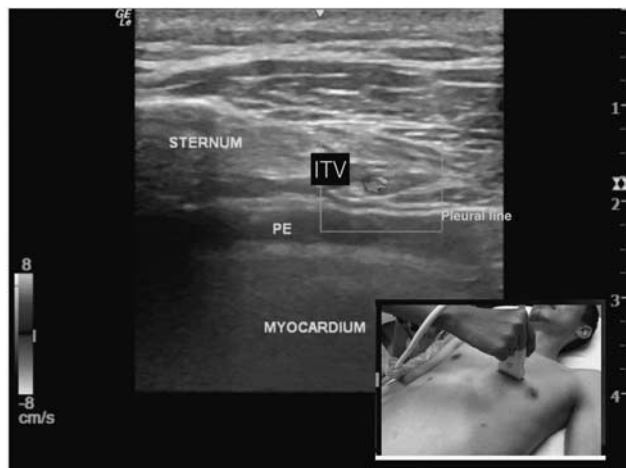

A high-frequency linear transducer was used to profile the transverse view of sternum bone.

clinical conditions, to ensure the absence of effusion and other postprocedural complications. Skin to pericardium distance, maximum effusion diameter, time to needle in, time to catheter in, and the first and total amount of fluid drained were recorded.

#### Statistical analysis

A descriptive statistical analysis was carried out with IBM SPSS Statistics for Windows, version 23 (IBM Corp., Armonk, New York, USA). Numerical measures were checked for normality. Measures with normal distribution were described using mean and SD, and those not normally distributed were described using median and

Fig. 3



The transducer was then moved laterally to identify the internal thoracic artery vessel (ITV) interrogated with color Doppler and pleural line (with lung sliding), which is just lateral to the sternum. PE, pericardial effusion.

interquartile range (IQR). Categorical measures were reported as numbers and percentages. Differences in blood pressures before and after the procedure were tested using the Wilcoxon-signed rank test and differences in the heart rate were tested using a paired *t*-test. Significance was considered at *P* less than 0.05.

**Results**

All pericardiocentesis were performed successfully in the emergency room without complications, relieving the hemodynamic instability. Patients’ demographics and clinical features are summarized in Table 1.

Four patients had pericardial effusion related to malignancy; two out of 11 as a complication of myocardial

infarction, one was a victim of traumatic injury, and the other patient’s effusion was related to inflammatory diseases or complication of uremic status.

The in-hospital 30-days mortality was 18%. One died because of septic shock secondary to pneumonia and another died because of septic shock with multiorgan failure. Seven (63%) patients required inotropes or vasopressors, which were reduced and subsequently discontinued after the procedure. The mean time to perform the eight-step procedure was 309 ± 76.4 s.

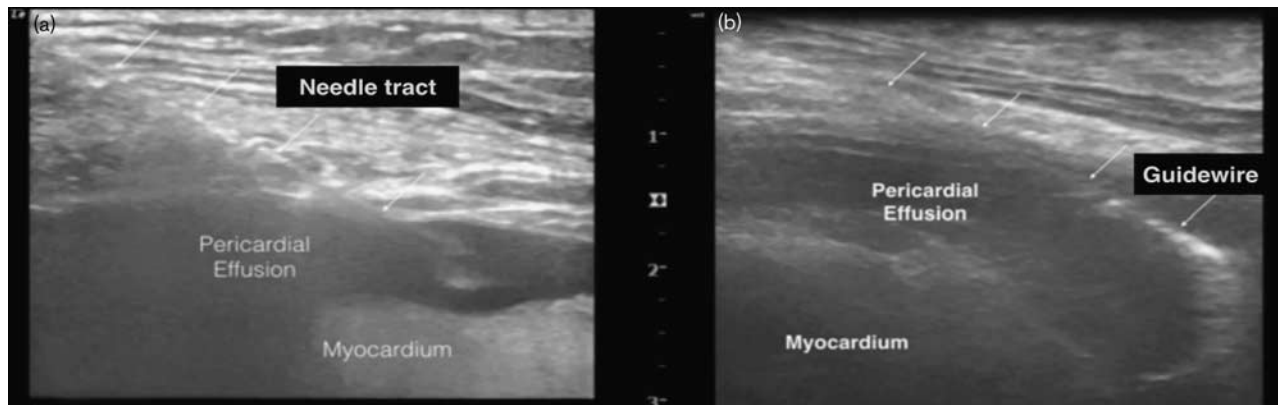
Patients’ mean blood pressures before and after the procedure were 53 mmHg (median; IQR: 4) and 90 mmHg (median; IQR: 19), respectively ( $Z = -2.803$ ,  $P = 0.005$ ). Patients’ heart rates before and after the procedure were 120 bpm (median IQR: 54) and 98 bpm (median; IQR: 25), respectively ( $t = 8.643$ ,  $P < 0.001$ ). The maximum effusion diameter was 20 mm [median; IQR: 6, Q1 (first quartiles): 17, Q3 (third quartiles): 22] and the skin to parietal pericardium distance was 15 mm (median; IQR: 4, Q1: 12, Q3: 17). Fluid removed during the procedure and the total amount of fluid drained during hospital stay were 580 ml (median; IQR: 510) and 1030 ml (median; IQR: 840), respectively.

**Discussion**

We report our preliminary experience on a novel ultrasound-guided pericardiocentesis technique with a medial-to-lateral approach, performed in the emergency context of tamponade, which led to the 100% success rate of the procedure without complications.

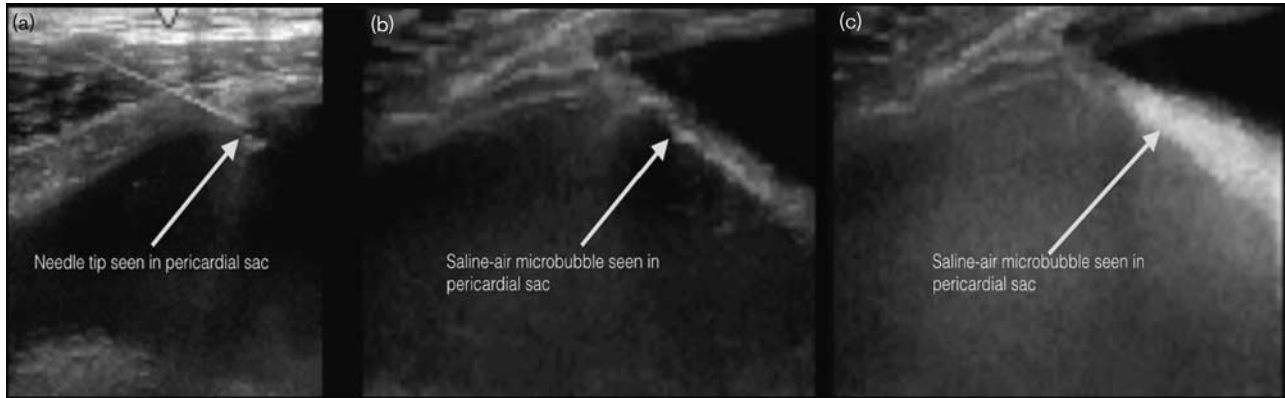
The main advantages of this medial-to-lateral approach are as follows: (i) safety, as all the surrounding structures are visualized and thus avoided, including the lungs and thoracic vessels; (ii) The high-frequency probe enables a

Fig. 4



The needle tip was directed to penetrate the skin, intercostal muscle, and pericardial tissue under real-time ultrasound guidance (a) and a curved guide wire was advanced into the pericardial cavity (b).

Fig. 5



A parasternal sonographic image of the needle tip seen in the pericardial sac (a). A saline-air microbubble was then flushed through the needle, showing a 'rocket flare' appearance, which confirmed the needle tip placement in the pericardial space (a, c).

more detailed visualization of the needle and the wire during their insertion; and (iii) fast procedural time.

Echocardiography-guided pericardiocentesis was developed in the 1970s and it has been adopted as the gold standard because of a significant reduction in complications in comparison with the blind technique, including liver, myocardium, arteries, and lungs perforation [6].

The standard technique involves identifying the location and distribution of pericardial fluid and insertion of the needle at the point where the largest amount of fluid is closest to the skin using the 'bubble test' to verify the correct position of the needle. This technique accounts for the low incidence of minor and major complications (3.5 and 1.2%, respectively) [5]. A number of alternative but similar techniques, including the probe-mounted needle, have been proposed, with similar complication rates [16].

The technique described above differ on the site of the puncture (subxiphoid, apical, or parasternal) [6–8], whereas they shared the use of low-frequency probes and absence of real-time needle visualization and complete control of needle trajectory. This might increase the risk of puncture to other vital organs.

The apical approach was transpleural, with the possibility of pneumothorax or spread of infection to the pleura and lung. The subxiphoid approach had a higher risk of injury to the liver, heart, and inferior vena cava. Vayre *et al.* [8] chose the subxiphoid approach for most of his case series and reported a complication rate of 21% (0.9% major and 20.1% minor). Akyuz *et al.* [9] reported the use of the subcostal (85%) and apical approach (15%) under echocardiographic guidance, and reported a complication rate of 1.3% for all minor and major complications.

The parasternal approach relies on the identification of the cardiac notch, where the pericardium is exposed,

enabling direct and safe access to pericardium. The cardiac notch can be identified sonographically by the absence of lung tissue overlying the pericardial sac. A parasternal, in-plane, and real-time technique has only been described anecdotally [12,13], but never with a medial-to-lateral approach.

Several observational studies showed that the left chest approach was superior to the traditional subxiphoid approach [5,10,13,17].

Traditional echo-guided pericardiocentesis without a probe-mounted needle did not enable continuous visualization of the needle in 56–75% of cases [16,18–20].

Our preliminary experience suggested that real-time visualization of the needle and the catheter by the left parasternal approach, avoiding the lung and other organs, and the preprocedural ultrasonography mapping of the thoracic vessels [11] make the procedure theoretically free of any complications.

Furthermore, our preliminary experience showed good timeliness and feasibility of this technique as shown by our average time to needle (Table 1).

No studies have been published to date addressing complete control of needle trajectory and real-time needle visualization in ultrasound-guided pericardiocentesis without an additional probe-mounted needle.

There are a few main limitations of this technique. It requires two probes as the initial assessment of pericardial effusion has to be performed with a cardiac probe while the procedure is performed using a linear high-frequency probe. It cannot be performed if the pericardial effusion is only posterior, but these kinds of effusions are usually more solid following cardiac surgery and the percutaneous approach is not efficient. In case of severe subcutaneous emphysema, the parasternal approach is unfeasible.

The preliminary description, although effective and promising, requires further validation in a larger population.

### Conclusion

The in-plane parasternal medial-to-lateral approach using a high-frequency probe offers potential advantages in terms of feasibility and safety as it abolishes the risk of liver injury, enables real-time visualization of the needle trajectory, and avoids the internal thoracic vessels, lung, and heart perforation.

### Acknowledgements

The authors would like to thank the Society of Critical Care and Emergency Sonography (SUCCES) Malaysia, Ipoh Emergency Medicine Society and Clinical Research Centre (CRC) HRPB, Ipoh, for their support and assistance.

Adi Osman and Tan Wan Chuan were involved in the initial conception, data acquisition, and drafting of the manuscript. Gabriele Via and Guido Tavazzi contributed toward the statistical analysis and data interpretation of the study, drafting, and revising of the manuscript. Jamalludin Ab Rahman was involved in biostatistics interpretation and advice.

### Conflicts of interest

There are no conflicts of interest.

### References

- 1 Tsang TS, Oh JK, Seward JB. Diagnosis and management of cardiac tamponade in the era of echocardiography. *Clin Cardiol* 1999; **22**:446–452.
- 2 Imazio M, Adler Y. Management of pericardial effusion. *Eur Heart J* 2013; **34**:1186–1197.
- 3 Gibbs CR, Watson RD, Singh SP, Lip GY. Management of pericardial effusion by drainage: a survey of 10 years' experience in a city centre general hospital serving a multiracial population. *Postgrad Med J* 2000; **76**:809–813.
- 4 Tsang TS, Oh JK, Seward JB, Tajik AJ. Diagnostic value of echocardiography in cardiac tamponade. *Herz* 2000; **25**:734–740.
- 5 Tsang TS, Enriquez-Sarano M, Freeman WK, Barnes ME, Sinak LJ, Gersh BJ, et al. Consecutive 1127 therapeutic echocardiographically guided pericardiocenteses: clinical profile, practice patterns, and outcomes spanning 21 years. *Mayo Clin Proc* 2002; **77**:429–436.
- 6 Tsang TS, Freeman WK, Sinak LJ, Seward JB. Echocardiographically guided pericardiocentesis: evolution and state-of-the-art technique. *Mayo Clin Proc* 1998; **73**:647–652.
- 7 Callahan JA, Seward JB. Pericardiocentesis guided by two-dimensional echocardiography. *Echocardiography* 1997; **14**:497–504.
- 8 Vayre F, Lardoux H, Pezzano M, Bourdarias JP, Dubourg O. Subxiphoid pericardiocentesis guided by contrast two-dimensional echocardiography in cardiac tamponade: experience of 110 consecutive patients. *Eur J Echocardiogr* 2000; **1**:66–71.
- 9 Akyuz S, Zengin A, Arugaslan E, Yazici S, Onuk T, Ceylan US, et al. Echo-guided pericardiocentesis in patients with clinically significant pericardial effusion. Outcomes over a 10-year period. *Herz* 2015; **40** (Suppl 2): 153–159.
- 10 Hanaki Y, Kamiya H, Todoroki H, Yasui K, Ohsugi S, Ohno M, et al. New two-dimensional, echocardiographically directed pericardiocentesis in cardiac tamponade. *Crit Care Med* 1990; **18**:750–753.
- 11 Blanco P, Volpicelli G. Looking a bit superficial to the pleura. *Crit Ultrasound J* 2014; **6**:13.
- 12 Nagdev A, Mantuani D. A novel in-plane technique for ultrasound-guided pericardiocentesis. *Am J Emerg Med* 2013; **31**:1424.e5–1424.e9.
- 13 Law MA, Borasino S, Kalra Y, Alten JA. Novel, long-axis in-plane ultrasound-guided pericardiocentesis for postoperative pericardial effusion drainage. *Pediatr Cardiol* 2016; **37**:1328–1333.
- 14 Via G, Hussain A, Wells M, Reardon R, ElBarbary M, Noble VE, et al. International evidence-based recommendations for focused cardiac ultrasound. *J Am Soc Echocardiogr* 2014; **27**:683.e1–683.e33.
- 15 Klein AL, Abbara S, Agler DA, Appleton CP, Asher CR, Hoit B, et al. American Society of Echocardiography clinical recommendations for multimodality cardiovascular imaging of patients with pericardial disease: endorsed by the Society for Cardiovascular Magnetic Resonance and Society of Cardiovascular Computed Tomography. *J Am Soc Echocardiogr* 2013; **26**:965–1012.e15.
- 16 Maggolini S, Bozzano A, Russo P, Vitale G, Osculati G, Cantu E, et al. Echocardiography-guided pericardiocentesis with probe-mounted needle: report of 53 cases. *J Am Soc Echocardiogr* 2001; **14**:821–824.
- 17 Cho BC, Kang SM, Kim DH, Ko YG, Choi D, Ha JW, et al. Clinical and echocardiographic characteristics of pericardial effusion in patients who underwent echocardiographically guided pericardiocentesis: Yonsei Cardiovascular Center experience, 1993-2003. *Yonsei Med J* 2004; **45**:462–468.
- 18 Callahan JA, Seward JB, Tajik AJ, Holmes DR Jr, Smith HC, Reeder GS, et al. Pericardiocentesis assisted by two-dimensional echocardiography. *J Thorac Cardiovasc Surg* 1983; **85**:877–879.
- 19 Chandraratna PA, Reid CL, Nimalasuriya A, Kawanishi D, Rahimtoola SH. Application of 2-dimensional contrast studies during pericardiocentesis. *Am J Cardiol* 1983; **52**:1120–1122.
- 20 Maggolini S, Gentile G, Farina A, De Carlini CC, Lenatti L, Meles E, et al. Safety, efficacy, and complications of pericardiocentesis by real-time echo-monitored procedure. *Am J Cardiol* 2016; **117**:1369–1374.