



**University of
Zurich**^{UZH}

**Zurich Open Repository and
Archive**

University of Zurich
Main Library
Strickhofstrasse 39
CH-8057 Zurich
www.zora.uzh.ch

Year: 1981

**Some thoughts about cross-sectional views of two-dimensional
echocardiography**

Krayenbühl, H P ; Jenni, R

DOI: <https://doi.org/10.1093/oxfordjournals.eurheartj.a061177>

Posted at the Zurich Open Repository and Archive, University of Zurich

ZORA URL: <https://doi.org/10.5167/uzh-154851>

Journal Article

Published Version

Originally published at:

Krayenbühl, H P; Jenni, R (1981). Some thoughts about cross-sectional views of two-dimensional echocardiography. *European Heart Journal*, 2(2):163-166.

DOI: <https://doi.org/10.1093/oxfordjournals.eurheartj.a061177>

Some thoughts about cross-sectional views of two-dimensional echocardiography

H. P. KRAYENBUHL AND R. JENNI

Medical Policlinic, University Hospital, Ramistrasse 100, 8091 Zürich, Switzerland

Two-dimensional echocardiography (2D-echo) has left its infancy and childhood and enters now into adult life. This powerful technique has found a wide application and a top place in our armamentarium of non-invasive means for the diagnosis of cardiac disease. Thus it was time that a uniform nomenclature and a standardization of the various cross-sectional images was offered to the cardiological community. The American Society of Echocardiography^[1] has recently published such recommendations and Meltzer *et al.* [2] in this journal have given a comprehensive analysis concerning the relationship of 2D-echo views to other imaging techniques.

Cross-sectional images through the heart and the great vessels are defined as 'views' which are determined by the transducer location and the specific orientation of the 2D-echo plane, i.e. the imaging plane transecting the heart. Among the immense number of views possible, both reports have stressed the usefulness of eight principal standards. These are the parasternal long and short axis views, the apical four-chamber and long axis views, the subcostal four-chamber and short axis views, and the suprasternal long and short axis views. The careful description of the image display and, more especially, the limitation to a reasonable number of standard views are welcome and fortunate because they are not only beneficial for those who are starting to learn and practice 2D-echo but facilitate greatly mutual understanding among researchers and the work of reviewers and editors of scientific journals. We now have a uniform scientific language in 2D-echo and it is only to be hoped that it will be used.

Whereas the qualitative evaluation of 2D-echocardiograms according to the above-mentioned

views is an established procedure, the quantitative assessment with respect to left ventricular volume estimation is less clearly defined. In left ventricular volume measurements from biplane RAO and LAO cine-angiograms, the left ventricular shape is described by an ellipsoidal model. When the long ventricular axis is defined in the RAO angiographic silhouette and the short ellipsoidal axes are determined by applying the area-length technique to both the RAO and the orthogonal LAO silhouette, left ventricular volumes are obtained which compare favorably with true volumes of casts. Thus, it appears logical to apply the same calculations based on an ellipsoidal model to 2D-echocardiograms for volumetric assessment. Unfortunately, and this is clearly outlined by Meltzer *et al.*[2], echocardiographic cross-sectional images are not strictly comparable with angiographic silhouettes since the latter integrate all information received along a circumference perpendicular to the plane of imaging whereas 2D-echocardiograms are tomographic sections through the heart which permit the assessment of the boundaries of the left ventricle in that given plane but, of course, do not contain information from overlying levels and hence do not necessarily indicate the largest possible dimensions of the ventricular ellipsoid. If, however, a 2D left ventricular tomographic section can be obtained which encompasses the maximal dimensions comprised in an angiographic silhouette of an X-ray projection perpendicular to the echocardiographic view the 2D-echocardiographic images can be treated in the same way as angiographic silhouettes for the calculation of left ventricular volumes. For practical purposes then, a left ventricular 2D long axis view containing information which approximates that obtained from the angiographic RAO silhouette and a 2D view orthogonal to the long axis view are required. This orthogonal view must be obtained solely by the 90° rotation of the transducer *without* any tilting or change in location. Which is now the long axis view providing

Received for publication 14 November 1980.

Requests for reprints to: Prof. H. P. Krayenbuhl, Chief of Cardiology, Medical Policlinic, University Hospital, Ramistrasse 100, 8091 Zürich, Switzerland.

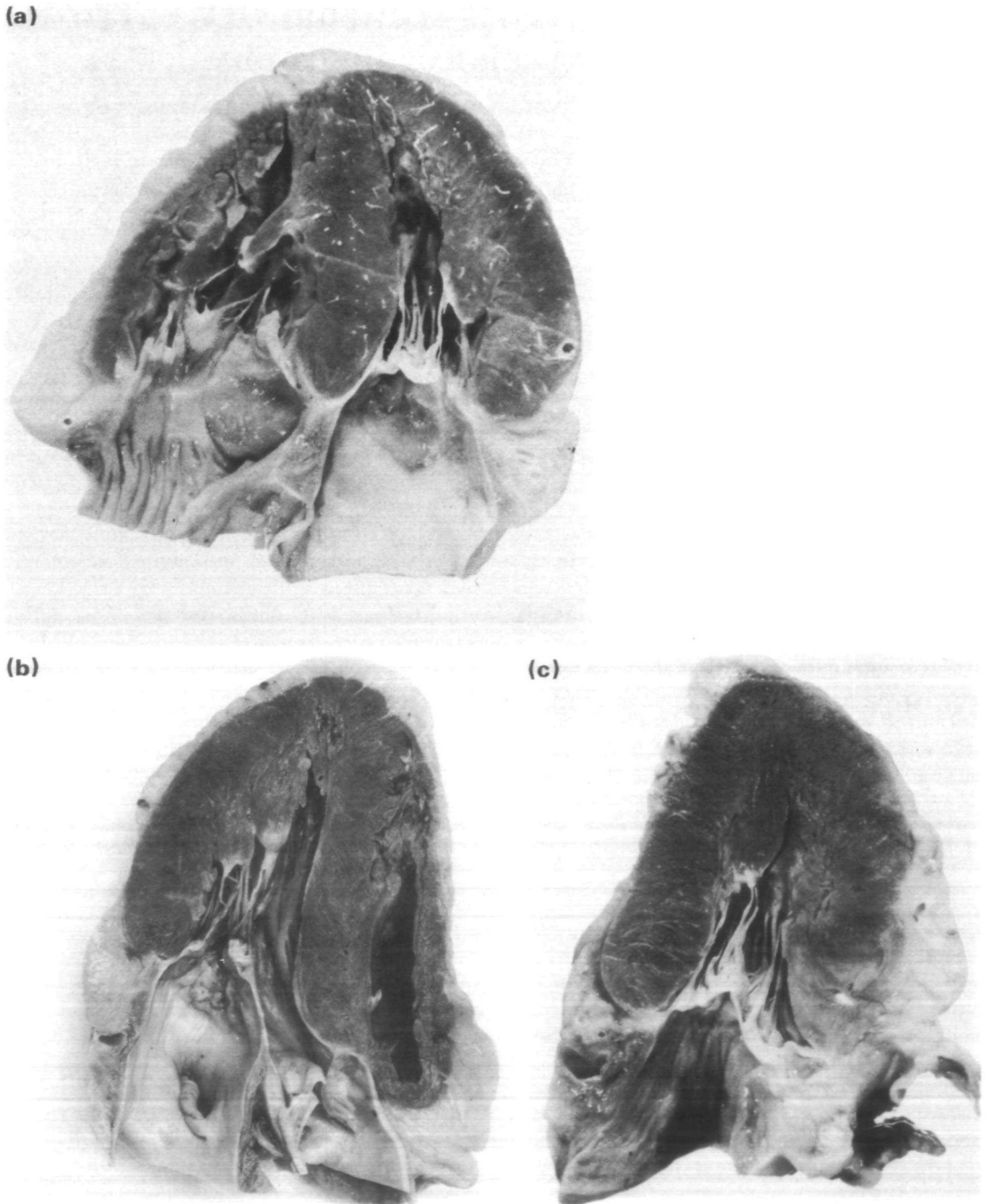


Figure 1 (a) Section through a necropsy heart according to the apical four-chamber view. The left ventricle (LV) is to the upper right, the right ventricle (RV) to the upper left, the left atrium (LA) to the bottom right and the right atrium to the bottom left. (b) Section according to the apical long axis view. This section is not strictly orthogonal to that shown in (a). The angular difference to the truly orthogonal view shown in (c) is about 15°. To the right are portions of the RV and the anterior interventricular septum, to the left is the posterior part of the LV. The aorta (AO) is to the bottom right and the LA to the bottom left. (c) Section through the heart orthogonal to that shown in (a). The echocardiographic image corresponding to this anatomical section is the newly termed 'RAO equivalent' view. To the right is the anterior wall and to the left the inferior wall of the LV. The AO is to the bottom right and the LA to the bottom left.

dimensions similar to the angiographic RAO projection? Schiller *et al.*^[3] have termed the apical long axis view—the echo plane of which transects the left atrium and the left ventricle—the 'RAO equivalent' view. In this apical two-chamber view, the left ventricular outflow tract is, however, *not* visualized and thus it is not surprising that the left ventricular volume is underestimated. Thus the term 'RAO equivalent' view for the apical two-chamber view should be abandoned. Is the apical long axis view as described by Meltzer *et al.* in fig. 6 adequate for volumetric measurements? We do not believe it because the anatomical sections in necropsy hearts of Tajik *et al.*^[4] and of ourselves have shown that the apical long axis view which transects the anterior part of the septum and the posterior left ventricular wall (fig. 6 of Meltzer *et al.*) is *not orthogonal* to the true apical four-chamber view (Fig. 1) which for biplane volumetric measurements serves to define the short ellipsoidal axis *orthogonal* to that in the long axis view. The apical long axis view which contains information similar to the angiographic RAO silhouette and which is truly orthogonal to the apical four-chamber view is parallel to the septum and results in visualization (display) of the anterior wall to the right, of the inferior wall to the left and of the aorta to the bottom right and of the left atrium to the bottom left (Fig. 1). It is this particular view which deserves the term 'RAO equivalent' view. Using this 2D cross-sectional view in combination with the orthogonal apical four-chamber view for the determination of left ventricular end-diastolic and end-systolic volume we have found in 42 patients with and without regional contraction disorders excellent correlations ($r=0.98$ and 0.97) with the corresponding values obtained from biplane RAO and LAO cine-angiograms^[5]. There was no systematic error for the determination of end-systolic volume whereas 2D-echo underestimated slightly end-diastolic volume (error 8%). The correlations obtained in the patients with localized wall motion abnormalities were similar to those in the whole group. It is noteworthy that Silverman *et al.*^[6] using the same cross-sectional views have obtained a similar good agreement between echo and angio volumes in pediatric patients. Thus it would appear that we have at our disposal standardizable cross-sectional images which can be used for the calculation of left ventricular volumes. Since these views are able to visualize practically all segments of the left ventricular wall it should be advantageous to use them for the assessment of localized

wall motion abnormalities. With modern light-pen and micro-processor systems it will be easy to establish in normals and in patients with coronary artery disease the extent and velocity of regional axis and hemiaxis shortening. The feasibility of the instantaneous measurement of regional axes opens the path for a more meaningful determination of left ventricular afterload than by simple blood pressure measurements alone. Instantaneous left ventricular dimensions from 2D-echos, left ventricular wall thickness from single beam echos selected from appropriate 12D views such as, for example, the parasternal long axis view, and peak systolic pressures by non-invasive cuff measurements might be combined to calculate peak systolic wall stress which, as is known from invasive studies, is an excellent measure of left ventricular afterload. It is obvious that such a non-invasive quantitation of afterload would be extremely useful in judging the efficacy of afterload reduction therapy as well as in evaluating changes in ejection performance in pre/postoperative comparisons of patients with mitral and aortic regurgitation.

In summary, it can be said that with the standardization of the cross-sectional views the stage is set for a logical, easily understandable, and uniform use of 2D-echocardiography. Accurate volumetric measurements can now be obtained from appropriate tomographic planes. Quantitation of regional wall motion disorders and the determination of left ventricular afterload are applications which are in the realm of 2D-echocardiography.

References

- [1] Henry WL, De Maria A, Gramiak R, *et al.* Report of the American Society of Echocardiography Committee on nomenclature and standards in two-dimensional echocardiography. *Circulation* 1980; 62: 212-7.
- [2] Meltzer RS, Meltzer C, Roelandt J. Sector scanning views in echocardiology: a systematic approach. *Eur Heart J* 1980; 1: 379-94.
- [3] Schiller NB, Acquatella H, Ports TA, *et al.* Left ventricular volume from paired biplane two-dimensional echocardiography. *Circulation* 1979; 60: 547-55.
- [4] Tajik AJ, Seward JB, Hagler DJ, Mair DD, Lie JT. Two-dimensional real-time ultrasonic imaging of the heart and great vessels. *Mayo Clin Proc* 1978; 53: 271-303.
- [5] Jenni R, Vieli A, Hess O, Anliker M, Krayenbuehl HP. Determination of left ventricular volume from apical orthogonal 2D-echocardiograms (in preparation).

[6] Silverman NH, Ports TA, Snider AR, *et al.* Determination of left ventricular volume in children:

echocardiographic and angiographic comparisons. *Circulation* 1980; 62: 548-57.