



**University of
Zurich**^{UZH}

**Zurich Open Repository and
Archive**

University of Zurich
University Library
Strickhofstrasse 39
CH-8057 Zurich
www.zora.uzh.ch

Year: 2007

**Preventative ibandronate treatment has the most beneficial effect on the
microstructure of bone in experimental tumor osteolysis**

Kurth, Andreas A ; Kim, Soo-Zin ; Shea, Marie ; Bauss, Frieder ; Hayes, Wilson C ; Müller, Ralph

DOI: <https://doi.org/10.1007/s00774-006-0732-x>

Posted at the Zurich Open Repository and Archive, University of Zurich

ZORA URL: <https://doi.org/10.5167/uzh-156110>

Journal Article

Published Version

Originally published at:

Kurth, Andreas A; Kim, Soo-Zin; Shea, Marie; Bauss, Frieder; Hayes, Wilson C; Müller, Ralph (2007). Preventative ibandronate treatment has the most beneficial effect on the microstructure of bone in experimental tumor osteolysis. *Journal of Bone and Mineral Metabolism*, 25(2):86-92.

DOI: <https://doi.org/10.1007/s00774-006-0732-x>

Andreas A. Kurth · Soo-Zin Kim · Marie Shea
Frieder Bauss · Wilson C. Hayes · Ralph Müller

Preventative ibandronate treatment has the most beneficial effect on the microstructure of bone in experimental tumor osteolysis

Received: February 20, 2006 / Accepted: October 31, 2006

Abstract We investigated the effect of ibandronate on three-dimensional (3-D) microstructure and bone mass in experimentally induced tumor osteolysis. Walker carcinoma cells were implanted into the left femur of female rats that received 26-day ibandronate pretreatment followed by continued therapy or ibandronate posttreatment only. A tumor-only group received isotonic saline. At endpoint, excised femurs were scanned using microcomputed tomography (μ CT) to assess bone volume density, bone mineral content, trabecular number/thickness, and separation for cortical plus trabecular bone or trabecular bone alone. Compared with the nonimplanted right femur, bone volume and surface density and trabecular number and thickness were reduced in the distal left femur following tumor cell implantation. μ CT analysis revealed greater cortical and trabecular bone mineral content in the preventative and interventional (pre-post tumor) ibandronate group, and the interventional (post-tumor) ibandronate group, versus the tumor-only group. Bone volume density was significantly higher in pre-post and post-tumor groups compared to the tumor-only group. After preventative and interventional ibandronate, bone volume density and trabecular thickness were 13% and 60% greater, respectively,

than in the post-tumor treatment group. 3-D μ CT images confirmed microstructural changes. We conclude that combined interventional and preventative ibandronate preserves bone strength and integrity more than intervention alone.

Key words bisphosphonate · preclinical · computer tomography · skeletal integrity

Introduction

Skeletal metastases are the most frequent complication of malignant tumors and are associated with severe pain and pathological fractures. Although treatment for metastatic bone lesions does not alter life expectancy, preventing fractures can improve the quality of life of the cancer patient. Bisphosphonates are one class of therapeutic agents currently being used or under investigation for various diseases related to pathologically increased bone resorption, such as Paget's disease, postmenopausal osteoporosis, and tumor-induced hypercalcemia and osteolysis [1]. Over recent years, bisphosphonates have also become an established treatment for bone metastases, and are currently the only available treatment option for bone complications associated with malignancies. Bisphosphonates are able to reduce the number of skeletal complications by inhibiting osteoclast-mediated bone destruction. Numerous experimental and clinical studies have shown that interventional treatment can reduce the occurrence of pathological fractures, bone pain, hypercalcemia, and the need for radiotherapy and surgery [2].

Preclinical studies and initial clinical experience show that preventative administration of bisphosphonates seems very promising and more beneficial for the patient than palliative administration alone [3–9]. Investigations into the use of bisphosphonates are now directed to understand the effects of a preventative treatment on tumor osteolysis [10]. A recent investigation on bone quality in tumor osteolysis showed that tumor growth in bone resulted in a

A.A. Kurth · S.-Z. Kim
Department of Orthopaedic Surgery, University Hospital
Frankfurt/Main, Frankfurt/Main, Germany

M. Shea
Orthopaedic Biomechanics Laboratory, Department of
Orthopaedics & Rehabilitation, Oregon Health and Science
University, Portland, OR, USA

F. Bauss
Roche Diagnostics GmbH, Pharma Research, Penzberg, Germany

W.C. Hayes
Orthopaedic Biomechanics Laboratory, Beth Israel Deaconess
Medical Center and Harvard Medical School, Boston, MA, USA

R. Müller (✉)
Institute for Biomedical Engineering, Swiss Federal Institute of
Technology (ETH) and University of Zürich, Moussonstrasse 18,
8044 Zürich, Switzerland
Tel./Fax +41-44-632-4592; Fax +41-44-632-1214
e-mail: ralph.mueller@ethz.ch

decrease in bone mass and the loss of biomechanical competence of bone, but they are not correlated [11]. In addition, new imaging techniques for determining the alteration of the three-dimensional (3-D) structure of trabecular bone, a factor known to influence its mechanical behavior, have been introduced [12].

We utilized this new technology in a previous study and demonstrated that microcomputed tomography (μ CT) can provide 3-D parameters of bone mass and trabecular structure in an animal model for tumor-induced bone loss [13]. We found significant differences in 3-D morphometric parameters between the tumor-bearing bones and contralateral controls.

In the current experimental study, we investigated the effect of a preventative administration of ibandronate on the 3-D microstructure of bone in a rat model for tumor-induced osteolysis. Building on previously published experiments [11,13–15], this study aimed to investigate whether interventional treatment with ibandronate affects the tumor-induced destruction of the 3-D structure of trabecular bone, and whether preventative treatment combined with interventional treatment preserves the 3-D structure of trabecular bone in tumor osteolysis better than interventional treatment alone.

Materials and methods

Animal model and treatment protocol

We used a previously described animal model to evaluate densitometric and biomechanical properties in tumor osteolysis [11,13–15]. The widely used Walker Carcinoma 256 malignant breast cancer cells (W256) were cultured in 0.6% agarose gel solution. After anesthesia by an intraperitoneal injection of ketamine hydrochloride (75 mg/kg) and xylazine (5 mg/kg), equivalent volumes of tumor cells in agarose gel containing approximately 2×10^6 cells were surgically implanted into the medullary canal of the left femur via a drill hole in the intercondylar notch (see [15] for additional details). Forty-five female Sprague–Dawley rats aged 4 months were randomly assigned to three study groups. All animals were maintained in accordance with federal regulations, and the study was conducted with the approval of the Institutional Animal Care and Use Committee (Harvard Medical School). In the first group (tumor-only), Walker 256 tumor cells were implanted into the left femur without treatment. The second group (pre-post) first underwent a daily pretreatment with ibandronate (Roche Diagnostics, Mannheim, Germany; 25 μ g/kg subcutaneously) for 26 days; then, tumor cells were implanted and the daily treatment was continued until death. The third group (post) received daily ibandronate treatment only after tumor cell implantation. There were no complications from the surgical procedure. Twenty-eight days after surgery, all animals were killed and both femora from each rat were harvested and cleaned of soft tissue for image analysis. Before microtomographic scanning, all femora were radiographed in an anteroposterior plane using a

Faxitron machine (Hewlett-Packard, McMinnville, OR, USA).

Structural analysis using microcomputed tomography (μ CT)

As in our recent study [13], we employed a desktop μ CT imaging system (μ CT 20; Scanco Medical, Bassersdorf, Switzerland; 30 μ m, nominal resolution) to assess 3-D densitometric and architectural parameters in small animal whole bones. The μ CT system has a micro-X-ray source (10 μ m focal spot, 25 keV) directed toward the sample. The quantitative modification of the X-ray beam by apatite crystals contained in the bone sample is analyzed by a plane detector (CCD array; 1024 elements). The process is piloted by an Alpha workstation (HP, Palo Alto, CA, USA) and an OpenVMS system in cluster configuration to perform the 3-D analysis. For each specimen, a total of 200 microtomographic slices were taken, each 30 μ m thick, starting from a reproducible anatomical landmark right behind the boundary of the condyles, thereby covering a 6-mm region of the distal femur. From the obtained two-dimensional slices, 3-D reconstruction of bone was automatically performed using the triangulation algorithm. Architectural indices were calculated in the spherical volume of interest according to standard definitions used in histomorphometry [11]. Bone volume density (bone volume/tissue volume), bone surface density (bone surface/bone volume), trabecular thickness, trabecular separation, and trabecular number were determined directly from the 3-D images. Bone mineral content, calculated using the measured bone volume and assuming a constant tissue density, was measured in a metaphyseal region consisting of both cortical and trabecular bone, and a sphere consisting of trabecular bone only. In a previous study, calculations of bone mineral content using this method were shown to correlate closely to dual-energy X-ray absorptiometry (DXA)-based methods [16], and in a separate study, the bone volume densities of metastatic cancer bone and normal bone were found to be similar [17]. A total of 90 specimens (left and right femora) were scanned. All 90 specimens were analyzed using both visual assessment and quantitative morphometry.

Statistical analysis

A Wilk–Shapiro test for normality was conducted on all parameters. All data were expressed as the mean \pm standard deviation. Analysis of variance (ANOVA) with Student–Newman–Keuls post hoc analysis, or a paired *t* test was performed to determine if the measurements differed significantly (statistical significance level, $P < 0.05$).

Results

This model of tumor induction in bone has been characterized previously [11,13–15]. As with previous studies,

Table 1. Architectural parameters of the distal left (implanted) and right (nonimplanted) femur (no ibandronate treatment)

Group (<i>n</i>)	Bone volume density (%)	Bone surface density (mm ² /mm ³)	Trabecular number (1/mm)	Trabecular thickness (mm)	Trabecular separation (mm)
Left femur (15)	33.78 (11.30)	6.66 (1.72)	2.79 (1.03)	0.09 (0.01)	0.33 (0.21)
Right femur (15)	48.24 (5.95)	8.41 (0.64)	3.69 (0.51)	0.10 (0.02)	0.18 (0.05)
Group differences (%)	-30*	-21*	-24*	-10*	83*

Data are means (SD)

* $P < 0.001$ (paired *t* test)

Table 2. Bone mineral content for full and trabecular regions in the left operated femur measured using micro-computed tomography (μ CT)

Group ^a (<i>n</i>)	Full bone mineral content	Trabecular bone mineral content
Pre-post (15)	0.17 (0.02)	0.07 (0.01)
Post (15)	0.16 (0.02)	0.06 (0.01)
Tumor only (15)	0.10 (0.02)	0.02 (0.01)
Group differences (%)		
Pre-post vs. tumor only	74*	174*
Pre-post vs. post	11*	21*
Post vs. tumor only	57*	127*

Data are mean in grams (SD)

^aGroup title indicates treatments received: pre-post, ibandronate administered both before and after tumor cell implantation; post, ibandronate administered after tumor implantation but not before; tumor only, tumor implantation with no ibandronate treatment (see Materials and methods for further details)

* $P < 0.05$ (ANOVA with Student–Newman–Keuls post hoc comparisons)

radiographs confirmed that all femora implanted with tumor cells contained osteolytic lesions [11,15]. In addition, there was macroscopic evidence of soft tissue tumors surrounding affected bones.

Compared with the nonimplanted right femur, bone volume density, bone surface density, trabecular number, and trabecular thickness were significantly reduced in the distal left femur following the implantation of tumor cells ($P < 0.001$). Trabecular separation was significantly increased in the left femur (Table 1).

The μ CT analysis revealed greater values for cortical and trabecular bone mineral content in the preventative and interventional (pre-post tumor) ibandronate treatment group, and the interventional (post-tumor) ibandronate treatment group, than in the tumor-only group (Table 2). Morphometric analysis of trabecular volume revealed architectural changes in accordance with the quantitative changes seen in bone density (Figs. 1–4).

Changes in architectural parameters of the left femur following treatment with ibandronate are summarized in Table 3. Bone volume density was significantly higher in the pre-post and post-tumor groups compared to the tumor-only group, showing an increase of 133% and 106%, respectively ($P < 0.05$) (Table 3). These results are most likely caused by a significant increase in trabecular thickness (up by 211% and 95% versus the tumor-only group, respectively; $P < 0.05$) (Table 3). In addition, trabecular separation significantly decreased in the pre-post (-74%)

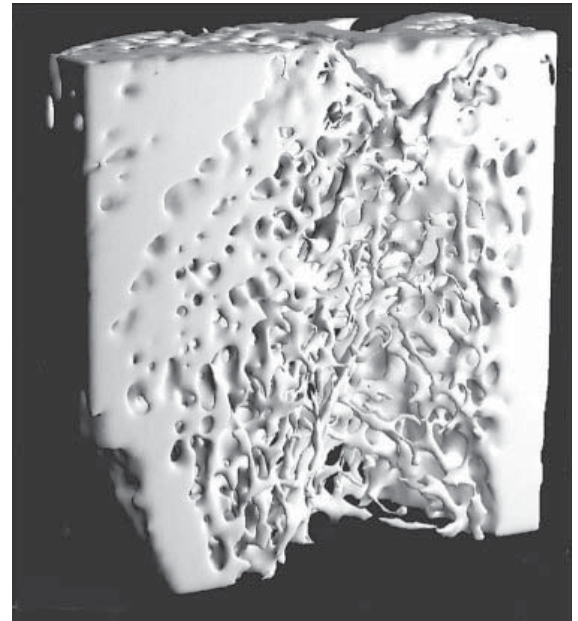
**Fig. 1.** Three-dimensional (3-D) reconstruction of microcomputed tomography (μ CT) slices for a control bone with no tumor and placebo treatment (a 6-mm region is shown)**Fig. 2.** 3-D reconstruction of μ CT slices for a tumor-bearing bone with placebo treatment (a 6-mm region is shown)



Fig. 3. 3-D reconstruction of μ CT slices for a tumor-bearing bone with interventional ibandronate treatment (a 6-mm region is shown)




Fig. 4. 3-D reconstruction of μ CT slices for a tumor-bearing bone with preventative and interventional ibandronate treatment (a 6-mm region is shown)

Table 3. Architectural parameters of the distal left (operated) femur measured using microcomputed tomography (μ CT)

Group ^a (n)	Bone volume density (%)	Bone surface density (mm^2/mm^3)	Trabecular number (1/mm)	Trabecular thickness (mm)	Trabecular separation (mm)
Pre-post (15)	78.58 (4.52)	5.83 (0.85)	2.80 (0.52)	0.28 (0.07)	0.09 (0.02)
Post (15)	69.52 (7.32)	7.49 (0.61)	3.77 (0.37)	0.18 (0.04)	0.09 (0.02)
Tumor only (15)	33.78 (11.30)	6.66 (1.72)	2.79 (1.03)	0.09 (0.01)	0.33 (0.21)
Group differences (%)					
Pre-post vs. tumor only	133*	-12	0	211*	-74*
Pre-post vs. post	13*	-22*	-26*	60*	-3
Post vs. tumor only	106*	12	35*	95*	-73*

Data are mean (SD)

^aGroup title indicates treatments received: pre-post, ibandronate administered both before and after tumor cell implantation; post, ibandronate administered after tumor implantation but not before; tumor only, tumor implantation with no ibandronate treatment (see Materials and methods for further details)

* $P < 0.05$ (ANOVA with Student–Newman–Keuls post hoc comparisons)

and post-tumor (-73%) treatment groups ($P < 0.05$ versus tumor only) (Table 3).

Values recorded in the pre-post ibandronate treatment group were 13% greater for bone volume density and 60% greater for trabecular thickness than in the post-tumor treatment group ($P < 0.05$) (Table 3). Bone surface density and trabecular number were not affected by ibandronate treatment (see Table 3).

Discussion

The aim of the present study was to investigate the effect of a bisphosphonate, ibandronate, on bone density and 3-D bone structure in a rat model of tumor-induced osteolysis. Previously, we presented biomechanical and

mineralization data with this model and treatment regimen, including DXA-based measurements, and also demonstrated no effects on serum calcium with the ibandronate doses used [11]. Other studies have also demonstrated that ibandronate does not induce either hypomineralization or hypermineralization, even at doses exceeding any therapeutically intended dose by multiples [11,18,19].

From clinical experience, it is known that bone metastases frequently occur in the metaphyseal regions of long bones and the vertebral bodies of the spine. In those areas, the turnover rate of trabecular bone is much greater than that of cortical bone; consequently, dramatic changes in tumor osteolysis occur in trabecular bone much later than in cortical bone. This also is the region of bone where the effect of an interventional treatment with bisphosphonates is more pronounced [20,21]. In recent years, 3-D analysis of bone has become possible using μ CT technology. This

tool rapidly evaluates the internal morphology and structure of trabecular and cortical bone, and has been widely used in osteoporosis research and to examine the effects of pharmacological intervention on bone [12,22–27]. In particular, μ CT imaging allows the noninvasive examination of the quantity, orientation, and connection of trabecular bone elements separately from cortical bone by focusing on a selected volume of interest containing trabecular bone only.

The results of the present study confirm that ibandronate administered either as a daily interventional treatment starting after the onset of tumor growth in bone, or as both a preventative and interventional treatment, preserves bone mass and 3-D structure compared with an untreated tumor-only control group. However, we found a greater beneficial effect on density, mineral content, and trabecular thickness in the preventative and interventional ibandronate group than the intervention-only group. In a previous study, we found that preventative and interventional treatment increased failure load by 9% versus interventional treatment alone in this model, although this was not statistically significant [11]. These data may suggest a potential for preventative ibandronate treatment to reduce the risk of fractures for patients. The similar number of trabeculae in the treatment groups indicates that ibandronate affected mostly existing trabeculae (i.e., increasing their width) rather than inducing formation of new trabeculae. These results are corroborated by two recent *in vivo* studies of bisphosphonate action on trabecular microarchitecture: a macaque study of preventative ibandronate for ovariectomy-induced bone loss in the lumbar spine [16], and a human trial of risedronate for preserving iliac bone architecture in postmenopausal women with osteoporosis [28]. In both studies, trabecular number was preserved and trabecular thickness was increased in treatment groups compared with controls or baseline values.

Several studies in different experimental models have shown that preventative bisphosphonate treatment reduces the development of bone metastases. Preventative etidronate treatment reduced osteolysis and prolonged survival in a rat model of bone metastasis using bladder carcinoma cells [29]. In other studies using parathyroid hormone-related protein-producing Walker 256 carcinosarcoma cells inoculated intraosseously into rats, pretreatment with clodronate or pamidronate was osteoprotective, with the extent of the effect correlating with duration and intensity of treatment [7–9,30]. Preventative treatment with pamidronate was also shown to increase trabecular volume, although an increase in skeletal tumor burden was observed, with no effects on nonosseous metastases [6]. However, other studies of human breast carcinoma cells injected into nude mice have shown a reduced tumor burden following pretreatment with ibandronate [31] or risedronate [32]. In addition, in a similar rat model, risedronate pretreatment decreased the incidence of bone metastases with no effect on visceral metastases [4]. Previous studies performed in our laboratory showed that combined preventative and interventional treatment with ibandronate most effectively preserved bone mass and strength, although all

ibandronate treatment schedules resulted in significant improvements compared with untreated tumor-bearing controls [11,14]. Supporting these results, a recent study of experimentally induced multiple tumor osteolysis in rats found that initiation of ibandronate therapy 3 days before tumor cell inoculation substantially reduced the development of osteolytic lesions compared with postoperative ibandronate administration [33].

Our study did not investigate the mechanism of action for the observed benefits of preventative ibandronate treatment. Bisphosphonates have several potential inhibitory effects on bone metastases. In particular, these agents have a well-documented inhibitory effect on osteoclast function. Studies have shown that bisphosphonates induce apoptosis in murine osteoclasts both *in vivo* and *in vitro*, and a greater effect is seen with more potent agents [34,35]. In addition, bisphosphonates may promote the secretion of an osteoclast inhibitory factor by osteoblasts [36]. Bisphosphonates also induce apoptosis in macrophages [37,38] and human myeloma cell lines [39] *in vitro*. Other biological effects include inhibiting the adhesion of breast or prostate carcinoma cells to bone matrices [40,41], inhibiting matrix metalloproteinases *in vitro* and *in vivo*, and decreasing the invasive properties of malignant melanoma and fibrosarcoma cell lines [31,42].

In a previous study from our laboratory, we assessed the effects of preventative and interventional ibandronate treatment on nonimplanted femora [11]. As is well established, ibandronate increased various bone parameters (such as bone mineral density) in femora without tumors; however, the effects were less than those observed in tumor-implanted femora. Although this confirms that ibandronate has additional effects on tumor-containing bone, it is unclear whether this is a result of timing of treatment or total dose administered. Regardless of mechanism, the present study further demonstrates that combined preventative and interventional ibandronate treatment is most beneficial in our model, and this finding has direct relevance to clinical dosing.

Conclusions

In our animal model investigating the structural consequences of tumor destruction in trabecular bone, both ibandronate treatment schedules resulted in significantly greater bone mass and improved structural parameters compared with no treatment. Combined preventative and continued treatment provided the best protection against tumor-mediated bone destruction and preserved the integrity of bone, even in the presence of a malignant tumor. Our experimentally obtained results for bone structure are in concordance with accumulating clinical evidence suggesting that preventative treatment with bisphosphonates can reduce the occurrence of skeletal complications in cancer patients and thus may prolong survival [43,44]. These animal experiments and the current clinical experience with bisphosphonates suggest that further investigations

that focus on preventative treatment are likely to be very promising.

Acknowledgments We thank Dan Michaeli, M.S., and John Hipp, Ph.D., for their input. This work was supported in part by a grant of the German National Science Foundation (Deutsche Forschungsgemeinschaft) and the G. Wallrabenstein Found (AAK). The Maurice E. Müller Professorship at the Harvard Medical School partly provided the financial support for the μ CT system. Gardiner-Caldwell US provided editorial assistance.

References

- Fleisch H (2000) Bisphosphonates in Bone Disease. Academic Press, San Diego
- Diel IJ, Solomayer EF, Bastert G (2000) Bisphosphonates and the prevention of metastasis: first evidences from preclinical and clinical studies. *Cancer (Phila)* 88:3080–3088
- Guaitani A, Polentarutti N, Filipeschi S, Marmonti L, Corti F, Italia C, Coccioli G, Donelli MG, Mantovani A, Garattini S (1984) Effects of disodium etidronate in murine tumor models. *Eur J Cancer Clin Oncol* 20:685–693
- Hall DG, Stoica G (1994) Effect of the bisphosphonate risedronate on bone metastases in a rat mammary adenocarcinoma model system. *J Bone Miner Res* 9:221–230
- Jung A, Bornand J, Mermillod B, Edouard C, Meunier PJ (1984) Inhibition by diphosphonates of bone resorption induced by the Walker tumor of the rat. *Cancer Res* 44:3007–3011
- Kostenuik PJ, Orr FW, Suyama K, Singh G (1993) Increased growth rate and tumor burden of spontaneously metastatic Walker 256 cancer cells in the skeleton of bisphosphonate-treated rats. *Cancer Res* 53:5452–5457
- Krempien B, Diel IJ, Jöckle-Kretz B, Buchele R, Andre L (1984) The Walker carcinosarcoma 256 as an experimental model of bone metastasis. Influence of skeletal metabolism on the development of bone metastases. *Verh Dtsch Ges Pathol* 68:211–216
- Krempien B, Manegold C (1993) Prophylactic treatment of skeletal metastases, tumor-induced osteolysis, and hypercalcemia in rats with the bisphosphonate Cl2MBP. *Cancer (Phila)* 72:91–98
- Krempien B, Wingen F, Eichmann T, Müller M, Schmahl D (1988) Protective effects of a prophylactic treatment with the bisphosphonate 3-amino-1-hydroxypropane-1,1-bisphosphonic acid on the development of tumor osteopathies in the rat: experimental studies with the Walker carcinosarcoma 256. *Oncology* 45:41–46
- Diel IJ (2000) Antitumour effects of bisphosphonates: first evidence and possible mechanisms. *Drugs* 59:391–399
- Kurth AA, Kim SZ, Sedlmeyer I, Bauss F, Shea M (2002) Ibandronate treatment decreases the effects of tumor-associated lesions on bone density and strength in the rat. *Bone (NY)* 30:300–306
- Müller R, Hildebrand T, Ruegsegger P (1994) Non-invasive bone biopsy: a new method to analyse and display the 3-dimensional structure of trabecular bone. *Phys Med Biol* 39:145–164
- Kurth AA, Müller R (2001) The effect of an osteolytic tumor on the 3-dimensional trabecular bone morphology in an animal model. *Skeletal Radiol* 30:94–98
- Kurth AHA, Kim S-Z, Sedlmeyer I, Hovy L, Bauss F (2000) Treatment with ibandronate preserves bone in experimental tumour-induced bone loss. *J Bone Joint Surg* 82B:126–130
- Kurth AA, Wang CO, Hayes WC, Shea M (2001) The evaluation of a rat model for the analysis of densitometric and biomechanical properties of tumor-induced osteolysis. *J Orthop Res* 19:200–205
- Müller R, Hannan M, Smith SY, Bauss F (2004) Intermittent ibandronate preserves bone quality and bone strength in the lumbar spine after 16 months of treatment in the ovariectomized cynomolgus monkey. *J Bone Miner Res* 19:1787–1796
- Nazarian A, von Stechow D, Rho JY, Grynpas M, Zurakowski D, Müller R, Snyder BD (2005) Structure dominates tissue properties in metastatic cancer. *Cancer Treat Rev* 31(suppl 1): S53–S54 (abstract 103)
- Lalla S, Hothorn LA, Haag N, Bader R, Bauss F (1998) Lifelong administration of high doses of ibandronate increases bone mass and maintains bone quality of lumbar vertebrae in rats. *Osteoporos Int* 8:97–103
- Bauss F, Russell RG (2004) Ibandronate in osteoporosis: pre-clinical data and rationale for intermittent dosing. *Osteoporos Int* 15:423–433
- Pataki A, Müller K, Green JR, Ma YF, Li QN, Jee WS (1997) Effects of short-term treatment with the bisphosphonates zoledronate and pamidronate on rat bone: a comparative histomorphometric study on the cancellous bone formed before, during, and after treatment. *Anat Rec* 249:458–468
- Peyruchaud O, Winding B, Pécheur I, Serre CM, Delmas P, Clezardin P (2001) Early detection of bone metastases in a murine model using fluorescent human breast cancer cells: application of to the use of the bisphosphonate zoledronic acid in the treatment of osteolytic lesions. *J Bone Miner Res* 16:2027–2034
- Laib A, Kumer JL, Majumdar S, Lane NE (2001) The temporal changes of trabecular architecture in ovariectomized rats assessed by microCT. *Osteoporosis Int* 12:936–941
- Lane NE, Kumer JL, Majumdar S, Khan M, Lotz J, Stevens RE, Klein R, Phelps KV (2002) The effects of synthetic conjugated estrogens A (cenestin) on trabecular bone structure and strength in the ovariectomized rat model. *Osteoporosis Int* 13:816–823
- Rüegsegger P, Koller B, Müller R (1996) A microtomographic system for nondestructive evaluation of bone architecture. *Calcif Tissue Int* 58:24–29
- Hildebrand T, Laib A, Müller R, Dequeker J, Ruegsegger P (1999) Direct 3-D morphometric analysis of human cancellous bone: microstructural data from spine, femur, iliac crest, and calcaneus. *J Bone Miner Res* 14:1167–1174
- Borah B, Dufresne TE, Chmielewski PA, Gross GJ, Prenger MC, Phipps RJ (2002) Risedronate preserves trabecular architecture and increases bone strength in vertebra of ovariectomized minipigs as measured by 3-dimensional microcomputed tomography. *J Bone Miner Res* 17:1139–1147
- Jiang Y, Zhao JJ, Mitlak BH, Wang O, Genant HK, Eriksen EF (2003) Recombinant human parathyroid hormone (1-34) [teriparatide] improves both cortical and cancellous bone structure. *J Bone Miner Res* 18:1932–1941
- Borah B, Dufresne TE, Chmielewski PA, Johnson TD, Chines A, Manhart MD (2004) Risedronate preserves bone architecture in postmenopausal women with osteoporosis as measured by three-dimensional microcomputed tomography. *Bone (NY)* 34:736–746
- Nemoto R, Uchida K, Tsutsumi M, Koiso K, Satou S, Satou T (1987) A model of localized osteolysis induced by the MBT-2 tumor mice and its responsiveness to etidronate disodium. *J Cancer Res Clin Oncol* 113:539–543
- Wingen F, Eichmann T, Manegold C, Krempien B (1986) Effects of new bisphosphonic acids on tumor-induced bone destruction in the rat. *J Cancer Res Clin Oncol* 111:35–41
- Yoneda T, Sasaki A, Dunstan C, Williams PJ, Bauss F, De Clerck YA, Mundy GR (1997) Inhibition of osteolytic bone metastasis of breast cancer by combined treatment with the bisphosphonate ibandronate and tissue inhibitor of the matrix metalloproteinase-2. *J Clin Invest* 99:2509–2517
- Sasaki A, Boyce BF, Story B, Wright KR, Chapman M, Boyce R, Mundy GR (1995) Bisphosphonate risedronate reduces metastatic human breast cancer burden in bone in nude mice. *Cancer Res* 55:3551–3557
- Neudert M, Fischer C, Krempien B, Bauss F, Seibel MJ (2003) Site-specific human breast cancer (MDA-MB-231) metastases in nude rats: model characterisation and in vivo effects of ibandronate on tumour growth. *Int J Cancer* 107:468–477
- Hughes DE, Wright KR, Uy HL, Sasaki A, Yoneda T, Roodman GD, Mundy GR, Boyce BF (1995) Bisphosphonates promote apoptosis in murine osteoclasts in vitro and in vivo. *J Bone Miner Res* 10:1478–1487
- Hiraga T, Williams PJ, Mundy GR, Yoneda T (2001) The bisphosphonate ibandronate promotes apoptosis in MDA-MB-231 human breast cancer cells in bone metastases. *Cancer Res* 61:4418–4424

36. Vitte C, Fleisch H, Guenther HL (1996) Bisphosphonates induce osteoblasts to secrete an inhibitor of osteoclast-mediated resorption. *Eur J Cancer Clin Oncol* 137:2324–2333
37. Rogers MJ, Chilton KM, Coxon FP, Lawry J, Smith MO, Suri S, Russell RG (1996) Bisphosphonates induce apoptosis in mouse macrophage-like cells in vitro by a nitric oxide independent mechanism. *J Bone Miner Res* 11:1482–1491
38. Selander KS, Monkkonen J, Karhukorpi EK, Harkonen P, Hannuniemi R, Vaananen HK (1996) Characteristics of clodronate-induced apoptosis in osteoclasts and macrophages. *Mol Pharmacol* 50:1127–1138
39. Shipman CM, Rogers MJ, Apperley JF, Russell RG, Croucher PI (1997) Bisphosphonates induce apoptosis in human myeloma cell lines: a novel anti-tumour activity. *Br J Haematol* 98:665–672
40. van der Pluijm G, Vloedgraven H, van Beek E, van der Wee-Pals L, Lowik C, Papapoulos S (1996) Bisphosphonates inhibit the adhesion of breast cancer cells to bone matrices in vitro. *J Clin Invest* 98:698–705
41. Boissier S, Magonetto S, Frappart L, Cuzin B, Ebetino FH, Delmas PD, Clezardin P (2003) Bisphosphonates inhibit prostate and breast cancer cell adhesion to unmineralized and mineralized bone extracellular matrices. *Cancer Res* 57:3890–3894
42. Teronen O, Heikkila P, Konttinen YT, Laitinen M, Salo T, Hanemaaijer R, Teronen A, Maisi P, Sorsa T (1999) MMP inhibition and down regulation by bisphosphonates. *Ann NY Acad Sci* 878:453–465
43. Diel IJ, Solomayer EF, Costa SD, Gollan C, Goerna R, Wallwiener D, Kaufmann M, Bastert G (1998) Reduction in new metastases in breast cancer with adjuvant clodronate treatment. *N Engl J Med* 339:357–363
44. Powles T, Paterson S, Kanis JA (2002) Randomized placebo-controlled trial of clodronate in patients with primary operable breast cancer. *J Clin Oncol* 20:3219–3224