



**University of  
Zurich**<sup>UZH</sup>

**Zurich Open Repository and  
Archive**

University of Zurich  
University Library  
Strickhofstrasse 39  
CH-8057 Zurich  
[www.zora.uzh.ch](http://www.zora.uzh.ch)

---

Year: 2007

---

## **CT changes after trochleoplasty for symptomatic trochlear dysplasia**

Fucentese, S F ; Schöttle, P B ; Pfirrmann, C W A ; Romero, J

DOI: <https://doi.org/10.1007/s00167-006-0140-8>

Posted at the Zurich Open Repository and Archive, University of Zurich

ZORA URL: <https://doi.org/10.5167/uzh-156416>

Journal Article

Published Version

Originally published at:

Fucentese, S F; Schöttle, P B; Pfirrmann, C W A; Romero, J (2007). CT changes after trochleoplasty for symptomatic trochlear dysplasia. *Knee Surgery, Sports Traumatology, Arthroscopy*, 15(2):168-174.

DOI: <https://doi.org/10.1007/s00167-006-0140-8>

## CT changes after trochleoplasty for symptomatic trochlear dysplasia

S. F. Fucentese · P. B. Schöttle · C. W. A. Pfirrmann · J. Romero

Received: 22 July 2005 / Accepted: 17 March 2006 / Published online: 20 June 2006  
© Springer-Verlag 2006

**Abstract** Trochlear dysplasia is an important risk factor for patellar instability. Because of a decreased trochlear depth in combination with a low lateral femoral condyle, the patella cannot engage properly in the trochlea. Trochleoplasty is a surgical procedure, which strives to correct such bony abnormalities. The aim of this study was to describe morphological features of trochlear dysplasia and the corrective changes after trochleoplasty on CT scan. The study group consists of 17 knees with trochlear dysplasia having undergone trochleoplasty for recurrent patellofemoral dislocation at a mean age of 22.4 years. The evaluation consisted in pre- and postoperative measurements on the proximal and distal trochlea on transverse CT scans in order to determine the morphological features. We measured the transverse position and depth of the trochlear groove, the transverse position of the patella, the ratio between the posterior patellar edge and the trochlear groove, the lateral patellar inclination angle, the sulcus angle, and the lateral trochlear slope. The trochlear groove lateralised a mean of 6.1 mm in the proximal aspect and 2.5 mm in the distal aspect of the trochlea, while the patella medialised a mean of 5 mm. Preoperatively the patella was lateral in relation to the trochlear groove in 13 cases, neutral in two cases, and medial in two cases. Postoperatively it was lateral in four cases, in neutral position in seven cases, and

medialised in six cases, referenced to the trochlear groove. The trochlear depth increased from 0 to 5.9 mm postoperatively in the proximal aspect of the trochlea, and from 5.5 to 8.3 mm postoperatively in the distal trochlea. The lateral patellar inclination angle decreased from a mean of 21.9° to a mean of 7.8°. The sulcus angle decreased from a mean of 172.1° to a mean of 133° in the proximal trochlea and from a mean of 141.9° to a mean of 121.7° in the distal trochlea. The lateral trochlear slope changed from 2.8° to 22.7° in the proximal and from 14.9° to 26.9° in the distal part of the trochlea. In the CT scan patients with trochlear dysplasia demonstrated a poor depth, or even a flat or convex trochlea with a greater sulcus and lateral trochlear slope angle, a lateralised patella to the trochlear groove with poor congruency, and a greater lateral patellar inclination angle. Trochleoplasty can correct the pathological features of trochlear dysplasia by surgically creating more normal anatomy. The goal of this surgical procedure is to steepen and lateralise the trochlear groove for a better engagement of the patella.

**Keywords** Patella instability · Trochlear dysplasia · Trochleoplasty · Trochlea morphology

### Introduction

Trochlear dysplasia is commonly associated with recurrent patellar dislocation with atraumatic onset [6, 9, 11, 12, 25, 32]. A positive crossing sign, a decreased trochlear depth, and an anterior translation on a straight lateral X-ray [11] are radiological signs of trochlear dysplasia. These signs confirm the patho-

S. F. Fucentese (✉) · P. B. Schöttle · J. Romero  
Orthopaedic Department, University Hospital Balgrist  
Zurich, Forchstrasse 340, 8008 Zurich, Switzerland  
e-mail: sandro.fucentese@balgrist.ch

C. W. A. Pfirrmann  
Radiological Department, University Hospital Balgrist  
Zurich, Forchstrasse 340, 8008 Zurich, Switzerland

anatomy of a flat trochlea and low lateral femoral condyle. In patients with symptomatic trochlear dysplasia, patellofemoral subluxation or dislocation occurs in the first 30° of flexion [1, 3, 26, 36, 37], because patella can not engage properly [13, 27]. Extraarticular procedures such as proximal or distal realignment of the extensor mechanism, or reconstruction of the medial patellofemoral ligament do not correct the intra-articular anomaly and have limited success in cases of severe trochlear dysplasia. Several authors have described a method remodelling the trochlea for better engagement of the patella [2, 5, 11, 25].

With the technique described by Bereiter [5], the cartilage is peeled off and the subchondral trochlea is remodelled to a depth and lateral position within a normal range [14].

Aim of this study was to compare the transverse positioning of the trochlea and the patella, the relation between the posterior patellar edge and the trochlear groove, the trochlear depth, the lateral patellar inclination angle, the sulcus angle, and the lateral trochlear slope in the proximal and the distal aspect of the trochlea, on CT scans before and after trochleoplasty.

## Materials and methods

### Patients

The study group consisted in 17 knees of 14 patients (3 bilateral), who had undergone trochleoplasty. The average age at surgery was 22.4 years (range, 17–40 years). The mean follow-up was 3 years (range 2–4 years).

Indications for trochleoplasty were two or more dislocations or one dislocation and a persistent sense of instability. In the clinical examination, the patients

presented a positive apprehension sign [32]. All patients had radiological signs of trochlear dysplasia (positive crossing sign, decreased trochlear depth, positive translation) [11].

### Surgical technique

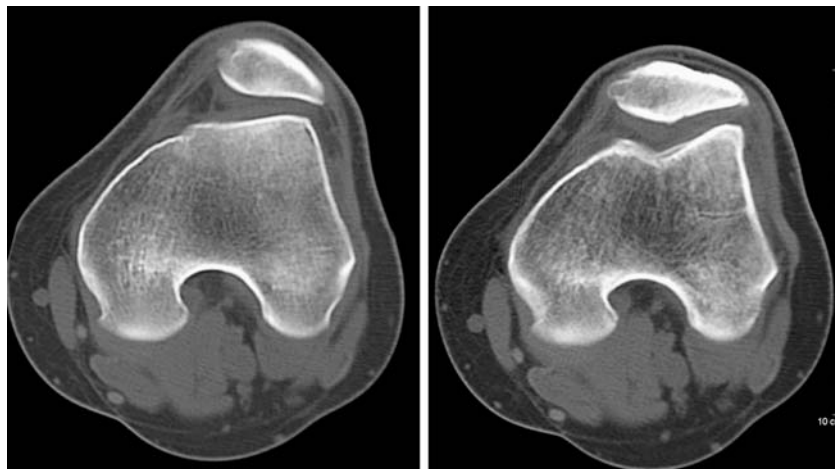
Through a parapatellar lateral incision, retracting the patella medially exposes the trochlea. The cartilage is separated along with 2 mm of bone from the condyles using a curved osteotome. Then the subchondral groove is deepened and lateralised. The cartilage bony fragment is now pressed into the newly formed bony groove and fixed with two absorbable transosseous sutures (Vicryl-Tape, Ethicon, Norderstedt, Germany). The insertion of the vastus medialis obliquus muscle at the patella is tightened with one absorbable suture (Vicryl 2-0, Ethicon, Norderstedt, Germany), while the lateral retinaculum is left open [5, 32].

### Measurement

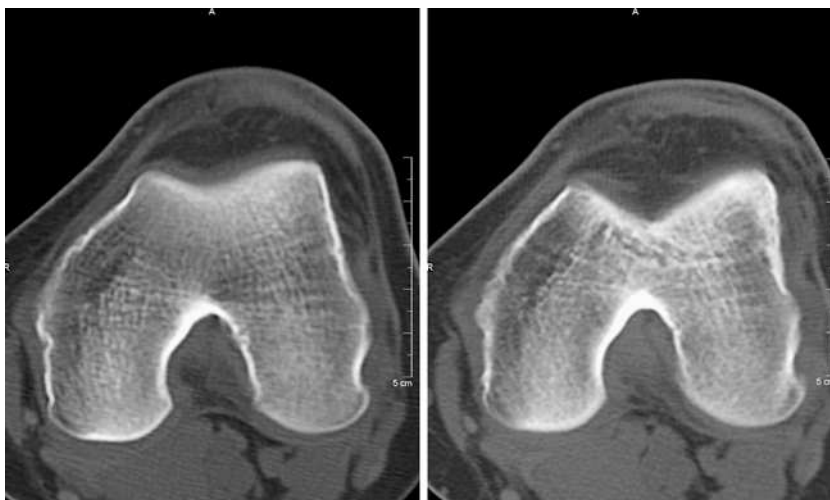
Radiographs used for measurements were pre- and postoperative CT scans in 0° knee extension with a relaxed quadriceps muscle. Continuous slices of 3 mm thickness were acquired using a Somatom plus 4 Scanner (Somatom Plus 4; Siemens Medical Solutions). Measurements were performed on the transverse CT images using bony landmarks. For a more exact evaluation of the trochlea, two axial images were used: a proximal one, when the trochlea is initially completely covered with cartilage [9] (Fig. 1) and a distal one, before the trochlear groove curves into the femoral notch [19] (Fig. 2).

The images with the widest diameter of patella were used for measurements of the patellar positioning, the lateral patellar inclination angle, and the relation

**Fig. 1** Pre- and postoperative axial view of the proximal trochlea at the same level (small differences between the slides are caused by the fact that patient positioning in the CT is different pre- and postoperatively). In the postoperative picture (*right*) the newly modelled groove with better femoropatellar geometry is shown. Note that very often patella alta in trochlear dysplasia normalises the position



**Fig. 2** Pre- and postoperative axial view of the distal trochlea



between the posterior patellar edge and the trochlear groove.

All measurements were performed using a PACS Workstation (ID Station, Image Devices, Idstein Germany). The principal two authors (SFF, PBS) evaluated the CT scans.

According to previous studies [23, 24, 33], the baseline (BL) is a constructed tangential to the subchondral osseous contours of the most posterior aspect of the medial and lateral femoral condyle (Fig. 3). Perpendicular to the baseline (BL), a medial (M) and a

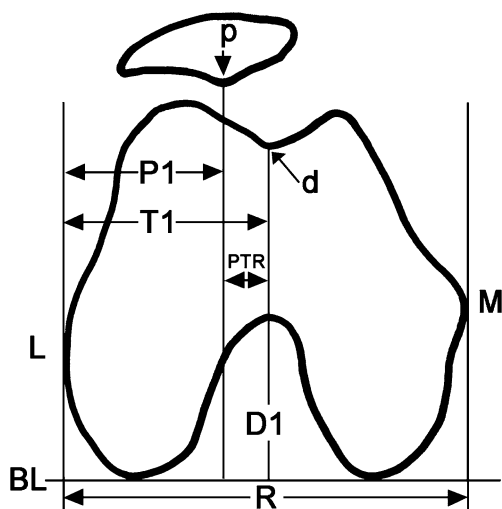
lateral (L) tangent are constructed. The reference distance (R) is the distance between (M) and (L) on the baseline (BL). The distance (R) was the reference distance for all measurements with exception of the depth measurement.

The reference distance for trochlear depth was the lateral femoral condyle height (D), perpendicular to the baseline (BL) (Fig. 4).

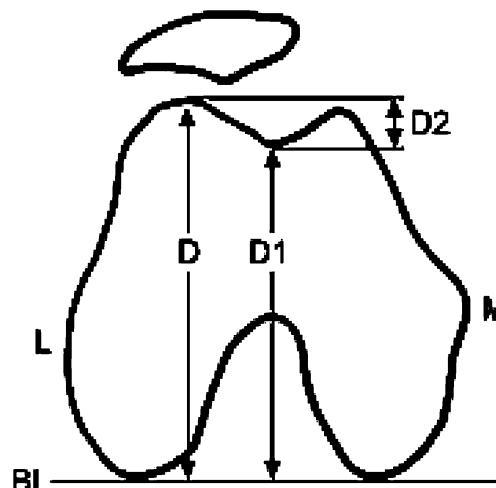
The absolute values were calculated in millimetres and in percentage related to the corresponding reference.

1. Transverse shifting of the trochlea (T1, Fig. 3).

The deepest point of the bony trochlea or, in cases with a convex trochlea the most prominent point of the bony trochlea was marked (d) and a perpendicular



**Fig. 3** Schematic transverse slice with the baseline (BL), medial (M) and lateral (L) epicondylar tangent perpendicular to (BL). Distance between (M) and (L) is the reference distance (R) for the transverse distances (TI) and (PI). (TI): shortest distance between the lateral epicondylar tangent (L) and a perpendicular line (D1) from the deepest or in a convex case highest point of the trochlea (d) to the (BL) for definition of the position of the trochlea. (PI): distance between the perpendicular taken from the posterior patellar edge (p) and (L) for definition of the position of the patella



**Fig. 4** Trochlear depth (D2): distance between the maximum lateral condylar height (D) and the height of the trochlea sulcus (D1)

(D1) to the reference distance (R) was drawn. (T1) was the distance between (D1) and (L).

The distance (T1) was measured pre- and postoperatively in millimetres. The absolute shifting of the trochlea was calculated as the difference between the pre- and postoperative (T1) value and evaluated in percent in relation to (R) [(T1/R) pre- and postoperatively]. Less than 50% was defined as lateral.

## 2. Transverse shifting of the patella (P1, Fig. 3).

The bony posterior patellar edge (p) was marked and a perpendicular (P) to the reference distance (R) was drawn. (P1) was the distance between (P) and (L). The distance (P1) was measured pre- and postoperatively in millimetres. The absolute shifting was calculated as the difference between the pre- and postoperative (P1) value and converted to a percentage referenced to the distance (R) [(P1/R) pre- and postoperatively]. Less than 50% was defined as lateral.

## 3. Posterior patellar edge-trochlear groove ratio (PTR, Fig. 3).


The ratio of the posterior patellar edge and the trochlear groove was calculated by the quotient between (P1/T1). If (P1) divided by (T1) was < 0.95, the patella was defined as lateral, if the quotient was between 0.95 and 1.05, the relation was defined neutral and if the quotient was > 1.05, the patella was defined as medial.

## 4. Trochlear depth (D2, Fig. 4).

The trochlear depth was evaluated in millimetres as difference between the lateral condylar height (D), and (D1, see above) on a perpendicular to the reference line (R).

## 5. Lateral patellar inclination angle (LPIA, Fig. 5).

The lateral patellar inclination angle was evaluated prolonging the major axis of the patella laterally to intersect the baseline (BL) [4].



**Fig. 5** Lateral patellar inclination angle (LPIA): intersection of major axis of the patella prolonged laterally and the baseline (BL)

## 6. Sulcus angle (Fig. 6).

The sulcus angle is defined by the intersection of the lines connecting the highest point of the femoral condyles to the deepest point of the trochlear groove [4, 33].

## 7. Lateral trochlear slope (LTS, Fig. 7).

The lateral trochlear slope was calculated by means of the baseline (BL) with a line tangential to the subchondral bone of the lateral trochlear facet [9, 34, 35].

## Results


### 1a. Transverse shifting of the proximal trochlea.

The distance (T1) decreased from a mean of 37.6 mm (range 32–45) preoperatively to a mean of 31.5 mm (range 25–40) postoperatively with a mean lateralisation of 6.1 mm (range 0–15). We found a lateralisation of the proximal trochlea in 16 knees, and none in one knee.

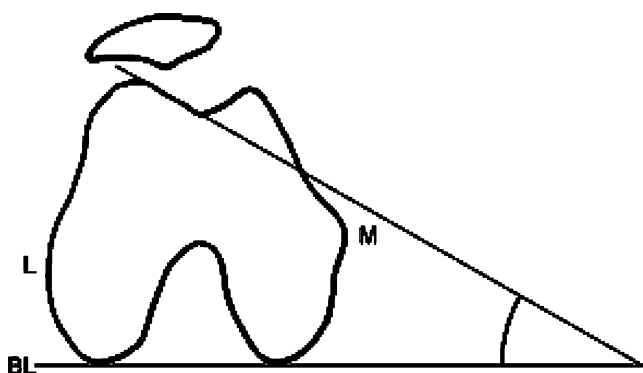
The relation (T1/R) decreased a mean of 8% (range 1–19%) from a mean of 48% (range 33–56%) to a mean of 40% (range 31–46%).

### 1b. Transverse shifting of the distal trochlea.

The distance (T1) decreased an average of 2.5 mm (range –3 to 8), from a mean of 35.4 mm (range 31–40) preoperatively to a mean of 32.9 mm (range 32–45) postoperatively. We found a lateralisation of the distal trochlea in 14 knees, while in 3 knees the distal trochlea was medialised.



**Fig. 6** Sulcus angle: intersection from the highest point of the condyles to the deepest respectively highest point of the trochlear groove



**Fig. 7** Lateral trochlear slope (*LTS*): angle between the tangent of the lateral surface of the trochlea and the baseline (*BL*). (*L*) lateral, (*M*) medial

The relation (*T1/R*) decreased a mean lateralisation of 4% (range 1–6%) from a mean of 46% (range 41–51%) to a mean of 42% (range 38–49%).

## 2. Transverse patellar shifting.

The distance (*P1*) increased a mean of 5 mm (range –5 to 18) from a mean of 27.1 mm (range 14–39) preoperatively to a mean of 32.1 mm (range 15–38) postoperatively.

The relation (*P1/R*) increased a mean of 7% (range –5 to 33%) from a mean of 34% (range 22–50%) preoperatively to a mean of 41% (range 29–50%) postoperatively. We found a medialisation of the patella in 13 knees. In one case the patella did not change position, and in three cases the patella was lateralised.

## 3. Posterior patellar edge-trochlear groove relation (*PTR*).

Preoperatively, the posterior patellar edge was lateral to the deepest point of the trochlear groove in 13 knees. In two knees the relation was neutral and in another two knees the patella was medial as referenced to the trochlear groove. The average was 0.73 (range 0.41–1.09). Postoperatively the posterior patellar edge remained lateral referenced to the trochlear groove in four cases, was neutral in seven cases, and medial in six cases. The average was 1.03 (range 0.87–1.32).

### 4a. Trochlear depth (*D2*) in the proximal trochlea.

In the proximal trochlea the trochlear depth increased in all cases with a mean increase of 5.9 mm (range 1–10) from a mean of 0 mm (range –5 to 4), including a flat or convex trochlea in eight knees, preoperatively to a mean of 5.9 mm (range 1–11) postoperatively. The lateral femoral condyle height (*D*) decreased from a mean of 60.1 mm (range 55–65) preoperatively to a mean of 59.7 mm (range 54–64).

### 4b. Trochlear depth (*D2*) in the distal trochlea.

In the distal trochlea the trochlear depth increased in all but three cases, from a mean of 5.5 mm (range 2–10) preoperatively to a mean of 8.3 mm (range 5–13) postoperatively with a mean increase of 2.8 mm (range 0–9). The lateral femoral condyle height (*D*) decreased from a mean of 60.9 mm (range 55–67) preoperatively to a mean of 60.4 mm (range 57–64).

## 5. Lateral patellar inclination angle (*LPIA*).

The mean *LPIA* decreased a mean of 14.1° (range 3–34) from a mean of 21.9° (range 5–35) preoperatively to a mean of 7.8° (range 1–20) postoperatively.

### 6a. Sulcus angle in the proximal trochlea.

In the proximal trochlea the sulcus angle decreased in all cases a mean of 39.1° (range 10–80) from a mean of 172.1° (range 150–190) preoperatively to a mean of 133° (range 110–150) postoperatively.

### 6b. Sulcus angle in the distal trochlea.

In the distal trochlea the sulcus angle decreased in all cases a mean of 20.2° (range 3–56) from a mean of 141.9° (range 118–164) preoperatively to a mean of 121.7° (range 110–135) postoperatively.

### 7a. Lateral trochlear slope in the proximal trochlea.

In the proximal trochlea the lateral trochlear slope increased in all cases a mean of 19.6° (range 3–49) from a mean of 2.8° (range –15 to 16) preoperatively to a mean of 22.7° (range 12–35) postoperatively.

### 7b. Lateral trochlear slope in the distal trochlea.

In the distal trochlea the lateral trochlear slope increased in all cases a mean of 12° (range 1–29) from a mean of 14.9° (range 0–29) preoperatively to a mean of 26.9° (range 15–37) postoperatively.

## Discussion

Patellar instability is a multifactorial disease, influenced by active, passive, and static factors, such as quadriceps force, ligamentous structure, and joint geometry, respectively. Trochlear dysplasia is an important static factor for recurrent patellar instability [11]. In trochlear dysplasia the groove is not deep enough, flat, or elevated. The patella cannot engage properly and maltracking and dislocation can occur.

Goal of trochleoplasty is to create an anatomically modelled trochlear groove to improve patellofemoral

tracking and prevent subluxation or dislocation. In clinical studies, no redislocation or subluxation occurred [5, 32], but exact evaluation of the morphological changes after trochleoplasty is missing. Until today radiographic outcome after trochleoplasty was determined on plain radiographs only [32, 39]. As it was shown that minimal rotation aberrations cause misdiagnosis of trochlear dysplasia on plain radiographs [21], it was the aim of this study to describe the trochlear morphology and the patellofemoral relation before and after trochleoplasty on CT images.

One main observation was the lateralisation of the newly modelled trochlea in the proximal part. This morphological change seems to achieve a more anatomic position, since Eckhoff has demonstrated that the trochlear groove physiologically lays lateral of the midplane [14]. Respecting the clinical fact that the patella is pulled towards lateral in the late extension, this morphological change improves the patellofemoral engagement near extension [32].

As another feature of a dysplastic trochlea is its insufficient trochlear depth [11, 22] an important goal of the trochleoplasty is to increase the depth, which was achieved in all cases.

Regarding the pre- and postoperative data, the main morphological changes were seen in the proximal trochlear aspect, where the trochlea seemed to have the more pronounced abnormality, while nearly no changes were seen in the distal trochlea.

These morphological facts correspond with the clinical findings where the lateral subluxation of the patella occurs during the early knee flexion, when the patella normally enters the proximal part of the trochlea [7, 8, 28, 29]. So the deepening and lateralisation must be focused on the proximal part of the trochlea. We think that the distal aspect should be slightly remodelled for a more harmonic patellofemoral kinematics in deeper knee flexion.

To study the geometry of the trochlear groove we used the sulcus angle [6, 10, 18, 23, 30, 33]. The value ranged between 110° to 150° in the proximal part and between 110° and 135° in the distal part, confirming the studies of Martinez and Reikeras [23, 30, 34] who proved a decreasing sulcus angle from proximal to distal. Interestingly, our population demonstrated an almost normal value for the distal part of the trochlea. Postoperative measurements showed a normal shape in almost all cases.

However, in two cases we found the lateral trochlear slope too steep, resulting in an overcorrected decreased sulcus angle. To avoid overcorrection, preoperative planning is necessary.

Regarding congruency between patella and trochlea, our results showed a decrease of the lateral patellar inclination angle (tilt) and a medialisation of the patella (shift), resulting in an improved patella tracking, proven by the decreased patellar edge-trochlear groove ratio [38].

It is known that lateral release and VMO insertion influence the patellar tilt as well. In patients with an underlying trochlear dysplasia, trochleoplasty not only treats the causing pathology, but also improves the patellofemoral joint congruency without additional proximal soft tissue realignment procedure or transfer of the tuberosity, which have had limited success in patients with trochlear dysplasia [1, 15–17, 20, 31].

Overall, in trochlear dysplastic patients, trochleoplasty changes the trochlear morphology towards normal values, especially in the proximal part. Specifically, the patellofemoral congruency is improved and patellofemoral engagement seems to be restored even in early flexion degrees.

## References

1. Aglietti P, Buzzi R, De Biase P, Giron F (1994) Surgical treatment of recurrent dislocation of the patella. *Clin Orthop* 8–17
2. Albee FH (1915) The bone graft wedge in the treatment of habitual dislocation of patella. *Med Rec* 88:257–259
3. Amis AA, Firer P, Mountney J, Senavongse W, Thomas NP (2003) Anatomy and biomechanics of the medial patellofemoral ligament. *Knee* 10:215–220
4. Beaconsfield T, Pintore E, Maffulli N, Petri GJ (1994) Radiological measurements in patellofemoral disorders: a review. *Clin Orthop* 308:18–28
5. Bereiter H, Gautier E (1994) [The trochleoplasty as a surgical therapy of recurrent dislocation of the patella in dysplastic trochlea of the femur]. *Arthroskopie* 7:281–286
6. Brattstrom H (1965) Shape of the intercondylar groove normally and in recurrent dislocation of the patella. *Acta Orthop Scand Suppl* 68:1–144
7. Brossmann J, Muhle C, Bull CC, Schroder C, Melchert UH, Zieplies J, Spielmann RP, Heller M (1994) Evaluation of patellar tracking in patients with suspected patellar malalignment: cine MR imaging vs arthroscopy. *AJR Am J Roentgenol* 162:361–367
8. Brossmann J, Muhle C, Schroder C, Melchert UH, Bull CC, Spielmann RP, Heller M (1993) Patellar tracking patterns during active and passive knee extension: evaluation with motion-triggered cine MR imaging. *Radiology* 187:205–212
9. Carrillon Y, Abidi H, Dejour D, Fantino O, Moyen B, Tran-Minh VA (2000) Patellar instability: assessment on MR images by measuring the lateral trochlear inclination-initial experience. *Radiology* 216:582–585
10. Davies AP, Costa ML, Shepstone L, Glasgow MM, Donell S (2000) The sulcus angle and malalignment of the extensor mechanism of the knee. *J Bone Joint Surg Br* 82:1162–1166
11. Dejour H, Walch G, Nove-Josserand L, Guier C (1994) Factors of patellar instability: an anatomic radiographic study. *Knee Surg Sports Traumatol Arthrosc* 2:19–26

12. Diks MJ, Wymenga AB, Anderson PG (2003) Patients with lateral tracking patella have better pain relief following CT-guided tuberosity transfer than patients with unstable patella. *Knee Surg Sports Traumatol Arthrosc* 11:384–388
13. Drew D (1908) Dislocation of patella. *Proc R Soc Med* 1:11
14. Eckhoff DG, Bach JM, Spitzer VM, Reinig KD, Bagur MM, Baldini TH, Rubinstein D, Humphries S (2003) Three-dimensional morphology and kinematics of the distal part of the femur viewed in virtual reality. Part II. *J Bone Joint Surg Am* 85-A Suppl 4:97–104
15. Fithian DC, Paxton EW, Cohen AB (2004) Indications in the treatment of patellar instability. *J Knee Surg* 17:47–56
16. Fithian DC, Paxton EW, Stone ML, Silva P, Davis DK, Elias DA, White LM (2004) Epidemiology and natural history of acute patellar dislocation. *Am J Sports Med* 32:1114–1121
17. Fulkerson JP (2002) Diagnosis and treatment of patients with patellofemoral pain. *Am J Sports Med* 30:447–456
18. Galland O, Walch G, Dejour H, Carret JP (1990) An anatomical and radiological study of the femoropatellar articulation. *Surg Radiol Anat* 12:119–125
19. Goutallier D, Bernageau J, Lecudonnec B (1978) [The measurement of the tibial tuberosity. Patella groove distanced technique and results]. *Rev Chir Orthop* 64:423–428
20. Harilainen A, Sandelin J (1993) Prospective long-term results of operative treatment in primary dislocation of the patella. *Knee Surg Sports Traumatol Arthrosc* 1:100–103
21. Koeter S, Bongers EM, de Rooij J, van Kampen A (2006) Minimal rotation aberrations cause radiographic misdiagnosis of trochlear dysplasia. *Knee Surg Sports Traumatol Arthrosc* 1–5
22. Malghem J, Maldague B (1989) Depth insufficiency of the proximal trochlear groove on lateral radiographs of the knee: relation to patellar dislocation. *Radiology* 170:507–510
23. Martinez S, Korobkin M, Fondren FB, Hedlund LW, Goldner JL (1983) Computed tomography of the normal patellofemoral joint. *Invest Radiol* 18:249–253
24. Martinez S, Korobkin M, Fondren FB, Hedlund LW, Goldner JL (1983) Diagnosis of patellofemoral malalignment by computed tomography. *J Comput Assist Tomogr* 7:1050–1053
25. Masse Y (1978) [Trochleoplasty. Restoration of the intercondylar groove in subluxations and dislocations of the patella]. *Rev Chir Orthop* 64:3–17
26. Nomura E, Horiuchi Y, Kihara M (2000) Medial patellofemoral ligament restraint in lateral patellar translation and reconstruction. *Knee* 7:121–127
27. Pollard B (1891) Old dislocation of patella reduced by intra articular operation. *Lancet* 1:988
28. Powers CM, Shellock FG, Pfaff M (1998) Quantification of patellar tracking using kinematic MRI. *J Magn Reson Imaging* 8:724–732
29. Powers CM, Ward SR, Fredericson M, Guillet M, Shellock FG (2003) Patellofemoral kinematics during weight-bearing and non-weight-bearing knee extension in persons with lateral subluxation of the patella: a preliminary study. *J Orthop Sports Phys Ther* 33:677–685
30. Reikeras O (1992) Patellofemoral characteristics in patients with increased femoral anteversion. *Skeletal Radiol* 21:311–313
31. Schneider T, Menke W, Fink B, Ruther W, Schulitz KP (1997) Recurrent dislocation of the patella and the Goldthwait operation. *Arch Orthop Trauma Surg* 116:46–49
32. Schottle PB, Fucntese SF, Pfirrmann C, Bereiter H, Romero J (2005) Trochleoplasty for patellar instability due to trochlear dysplasia. *Acta Orthop* 76:693–698
33. Schutzer SF, Ramsby GR, Fulkerson JP (1986) Computed tomographic classification of patellofemoral pain patients. *Orthop Clin North Am* 17:235–248
34. Shih YF, Bull AM, Amis AA (2004) The cartilaginous and osseous geometry of the femoral trochlear groove. *Knee Surg Sports Traumatol Arthrosc* 12:300–306
35. Shih YF, Bull AM, McGregor AH, Humphries K, Amis AA (2003) A technique for the measurement of patellar tracking during weight-bearing activities using ultrasound. *Proc Inst Mech Eng [H]* 217:449–457
36. Smirk C, Morris H (2003) The anatomy and reconstruction of the medial patellofemoral ligament. *Knee* 10:221–227
37. Steensen RN, Dopirak RM, McDonald WG 3rd (2004) The anatomy and isometry of the medial patellofemoral ligament: implications for reconstruction. *Am J Sports Med* 32:1509–1513
38. Tuneu J, Walch G (1987) Le scanner dans la pathologie femoro-patellaire. In: *La pathologie femoro-patellaire*:35–41
39. Verdonk R, Jansegers E, Stuyts B (2005) Trochleoplasty in dysplastic knee trochlea. *Knee Surg Sports Traumatol Arthrosc* 13:529–533