



**University of
Zurich**^{UZH}

**Zurich Open Repository and
Archive**

University of Zurich
University Library
Strickhofstrasse 39
CH-8057 Zurich
www.zora.uzh.ch

Year: 2007

Retrospective analysis and clinical evaluation of mandible reconstruction with free fibula flap

Wedler, V ; Farshad, M ; Sen, M ; Koehler, C ; Hanschin, A ; Graetz, K ; Kuenzi, W

DOI: <https://doi.org/10.1007/s00238-006-0081-y>

Posted at the Zurich Open Repository and Archive, University of Zurich

ZORA URL: <https://doi.org/10.5167/uzh-156666>

Journal Article

Published Version

Originally published at:

Wedler, V; Farshad, M; Sen, M; Koehler, C; Hanschin, A; Graetz, K; Kuenzi, W (2007). Retrospective analysis and clinical evaluation of mandible reconstruction with free fibula flap. *European Journal of Plastic Surgery*, 29(6):285-291.

DOI: <https://doi.org/10.1007/s00238-006-0081-y>

Retrospective analysis and clinical evaluation of mandible reconstruction with a free fibula flap

V. Wedler · M. Farshad · M. Sen · C. Koehler ·
A. Hanschin · K. Graetz · W. Kuenzi

Received: 11 July 2006 / Accepted: 20 July 2006 / Published online: 7 December 2006
© Springer-Verlag 2006

Abstract The objective of this investigation was to evaluate the indications for and the functional and cosmetic results of mandible reconstruction using free vascularized fibular flaps. It was also designed to assess the patients' quality of life, daily activities, and self-esteem, with special emphasis on patient satisfaction. We conducted a retrospective chart review of all patients who underwent osseous or

osteocutaneous free flap reconstruction of the mandible over a 10-year period (1992–2002). Those in whom a vascularized fibular flap was used were included in the study and invited for a follow-up comprehensive physical examination and x-ray evaluation. A questionnaire was also administered to evaluate patient satisfaction. Twenty-six patients were included in the study. Fourteen patients died after an average of 2 years and 9 months postoperatively due to their prognosis despite surgical intervention and adjuvant therapy. Of the remaining 12 patients, 6 appeared for the follow-up evaluation, 2 were unavailable for follow-up, and 4 denied participating. Of these 6 patients, all experienced a decrease in pain and were satisfied with their results. At the time of the latest follow-up, they experienced some difficulties swallowing, and in 3 patients, their articulation was impaired. All 6 patients would undergo the procedure again. Reconstruction of the mandible using a vascularized fibular graft produces satisfactory functional and cosmetic results. In benign lesions, the procedure is highly indicated. However, in the case of malignancy, most patients do not survive their primary tumor. Given the patients limited life expectancy, the improvement in their quality of life as a result of the improved appearance and function of the reconstructed mandible needs to be weighed against the potential morbidity of the operative intervention on an individual basis.

V. Wedler (✉) · M. Farshad · C. Koehler · W. Kuenzi
Department for Plastic-, Hand- and Reconstructive Surgery,
University Hospital of Zurich,
Rämistrasse 100,
8094 Zurich, Switzerland
e-mail: volker.wedler@usz.ch

M. Farshad
e-mail: mazda@farshad.ch

C. Koehler
e-mail: christian.koehler@usz.ch

W. Kuenzi
e-mail: walther.kuenzi@usz.ch

M. Sen
Department of Orthopaedic Surgery,
University of California San Francisco,
San Francisco, CA, USA
e-mail: senm@orthosurg.ucsf.edu

A. Hanschin
Department of Surgery, Research Division,
University Hospital of Zurich,
Rämistrasse 100,
8091 Zurich, Switzerland
e-mail: alexander.handschin@usz.ch

K. Graetz
Department of Cranio-Maxillofacial Surgery,
University Hospital of Zurich,
Rämistrasse 100,
8091 Zurich, Switzerland
e-mail: klaus.graetz@usz.ch

Keywords Free fibula · Mandible reconstruction · Flap · Evaluation · Reconstruction

Introduction

The reconstruction of discontinuity defects of the mandible due to benign or malignant lesions is a very challenging

procedure for the reconstructive surgeon. Many different approaches have been used to try to reconstruct these defects [6, 13, 14, 16, 18, 20, 21]. They include the use of alloplastic materials, nonvascularized bone grafts, and vascularized bone transfers. The most common method of mandible reconstruction used today is the vascularized osseous or osteocutaneous free-tissue transfer with the help of microsurgical techniques [17, 19].

Many reconstructive options exist due to the development of new techniques and the variety of flap donor sites [4, 6, 18, 24]. However, the most common donor site remains to be the fibula [4, 6, 14, 23]. In this study, we reviewed our experience with the reconstruction of the mandible using a free vascularized fibula flap. Our objective was to evaluate the indications, as well as the functional and cosmetic results of mandibles that were reconstructed using this technique. The study was also designed to find out if such a procedure has any influence on mortality and if any changes in the surgical procedure are indicated. We also evaluated the impact of this operation on the patients' quality of life, daily activities, and self-esteem, with special emphasis on patient satisfaction.

Patients and methods

We conducted a retrospective chart review of all patients who underwent osseous or osteocutaneous free flap reconstruction of the mandible over a 10-year period (1992–2002). Twenty-six patients in whom a vascularized fibula was used as the donor graft were included in the study. Data were collected on patient demographics, primary diagnosis, previous surgery or radiotherapy, complications, time to union, and the need for additional surgery.

Surgical technique

Prior to surgery, leg angiography was performed to evaluate the peroneal circulation. The standard lateral approach was used and dissection was performed with a tourniquet inflated to 380 mmHg. If a skin paddle was planned, it was centered mainly over the lateral aspect of the fibula, in the distal third of the lower leg. The anterior margin was reflected, and the posterolateral intermuscular septum was exposed to visualize the septocutaneous branches. The

posterior incision was then made down to the soleus. The bone was exposed above and below and divided with a Gigli saw. The vascular pedicle was identified proximal and distal. Harvest of the flap was modified by including an appropriate cuff of the soleus muscle in only two patients. The osteotomies were performed after the flap was divided and transferred. A mandibular reconstruction plate was molded and fixed in position prior to mandibular resection. In two cases, titanium miniplates were used for graft stabilization to the mandible. Next, the graft was fitted into the gap and anastomosed to the recipient site vessels. Return of circulation to the graft was demonstrated by periosteal bone bleeding and skin-island monitoring. The donor site was closed in all cases primarily, and the lower leg was immobilized with a posterior splint for a week. Antibiotics (7 days) were given perioperatively in all cases.

Long-term follow-up

Patients were then asked to participate in a follow-up evaluation consisting of a physical examination looking at both functional and aesthetic outcome and a questionnaire to evaluate patient satisfaction. Patient responses were quantified using a visual analogue scale (VAS) (Fig. 1). All patients who presented for the follow-up evaluation had a mandible x-ray and photographs taken.

Results

Of the 26 total patients, 17 were male and 9 were female. The average age at the time of surgery was 54 years (range, 20–84 years). Indications for mandible reconstruction included infiltration or radiation-induced osteonecrosis of the bone due to squamous cell cancer (SCC) (21 patients), destruction of the bone by osteomyelitis (2 patients), sarcoma (2 patients), and bone loss secondary to trauma (1 patient).

The left lateral part of the mandible was reconstructed in 13 patients, the right lateral part in 11 patients, and the frontal part in 2 patients (Table 1). The recipient artery was the superior thyroid artery in 15 patients, the facial artery in 10 patients, and the lingual artery in 1 patient. For the arterial anastomosis, the superior thyroid artery was used in 15 patients (end–end anastomosis), facial artery in 10 patients

Fig. 1 Quantification with a visual scale

Would you do the intervention again?

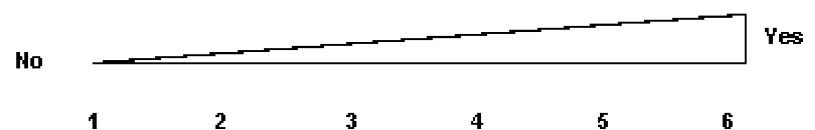


Table 1 Characteristics of patients and intervention

No.	Gender	Age at time of surgery	Follow-up (day)	Diagnosis	Radiation	Donor-site/Reco-site	Flap with mermis	Implant	Deceased
1	f	51	2075	SCC	Pre-OP	l/r	no	yes	no
2	f	53	1309	SCC	Pre-OP	r/l	yes	yes	yes
3	m	57	320	SCC	no	r/r	yes	no	yes
4	m	42	3748	OM	no	r/l	no	no	no
5	m	61	1414	SCC	Pre-OP	r/l	yes	yes	no
6	m	55	221	SCC	no	r/r	yes	no	yes
7	f	55	1778	SCC	Pre-OP	l/l	yes	yes	no
8	f	48	14	SCC	Pre-OP	l/l	yes	no	no
9	f	55	1584	SCC	Post-OP	r/r	yes	yes	no
10	m	59	795	SCC	Pre-OP + Post-OP	r/front	yes	no	yes
11	m	57	2972	SCC	Pre-OP	r/r	no	no	yes
12	m	57	2483	SCC	Pre-OP	l/l	no	yes	yes
13	m	20	159	Sarcoma	Pre-OP	r/l	no	no	no
14	f	60	345	SCC	Pre-OP	r/l	yes	no	yes
15	m	56	285	SCC	Pre-OP	r/r	yes	yes	yes
16	m	39	422	Trauma	no	r/front	no	no	yes
17	m	66	1554	Sarcoma	Post-OP	r/l	yes	no	yes
18	m	39	1523	SCC	Pre-OP	r/l	yes	yes	no
19	m	56	2358	SCC	Pre-OP	r/r	yes	yes	no
20	f	60	250	SCC	Pre-OP	r/r	no	no	yes
21	m	60	10	OM	no	r/l	yes	no	no
22	f	55	1087	SCC	Pre-OP	l/r	yes	yes	yes
23	m	57	2362	SCC	Pre-OP	r/r	yes	yes	no
24	m	84	282	SCC	no	r/l	yes	no	yes
25	f	47	1546	SCC	Pre-OP	r/l	yes	no	no
26	m	69	40	SCC	Pre-OP	r/r	no	no	yes

Pre-OP preoperative, *Post-OP* postoperative

(end–end anastomosis), and the lingual artery in 1 patient (end–end anastomosis). The recipient vein was the external jugular in 10 patients (end–side anastomosis), the internal jugular in 8 patients (end–side anastomosis), the facial vein in 4 patients (end–end anastomosis), and the superior thyroid vein in 4 patients (end–end anastomosis) (Table 2). There were no intraoperative complications such as thrombosis, and in no case was revision of the anastomosis necessary. Early postoperative complications included delayed wound healing in one patient—this was treated with conservative management.

Of the 26 patients, 14 were deceased at an average of 2 years and 9 months postoperatively (range, 40 days–8 years) due to complications related to their primary disease, despite surgery and adjuvant therapy. Of the remaining 12 patients, 6 appeared for the follow-up physical examination and questionnaire at an average of 6 years postoperatively (range, 4–10 years). Two patients had emigrated and were no longer available for follow-up, and 4 patients refused to participate.

Of the six examined patients, taste and touch sensation of the tongue was mostly preserved (Table 3), but the range

of motion of the tongue and hence their articulation was impaired in three patients. The sensory innervation of either the left or the right mental nerve was affected in all patients. The mimic musculature was hindered in only one patient (Table 3).

Using a VAS, patient satisfaction was determined to be very high (average 5.3; range, 5–6). Furthermore, all six patients described a decrease in pain following the procedure. However, the intervention produced difficulties

Table 2 Recipient vessel

Classification of recipient vessel	
Recipient artery	
Superior thyroid	15
Facial	10
Lingual	1
Recipient vein	
Internal jugular	8
External jugular	10
Facial	4
Superior thyroid	4

Table 3 Physical examination at latest follow-up

	Patient no.					
	1	4	9	18	19	23
Mouth opening (upper to lower incisor—range in cm)	3	3.5	3	8	5	6
Tongue-status (after mandibular reconstruction)						
Taste	good	good	left side	good	good	good
Touch	good	good	left side	good	right side	good
Movement range deficit	good	good	to left	good	to all sites	to all sites
Sensory deficit						
Area of mental nerve	left and right	left	right	left	right	right and left
Area of mandibular nerve	left and right	no	right	no	right	no
Motor deficit (facial nerve)	no	R. buccalis	no	no	no	no
Scar complications	no	no	no	no	Contractures	Contractures
Need for a reoperation	yes	yes	yes	no	no	no

in swallowing both solids and liquids in all patients. Patients also described a slight decrease in self-esteem from 4.8 to 4.2 on the VAS. However, all six patients said that they would undergo the procedure again (Table 4).

Documentation of a 47-year old man with SCC is described in Figs. 2 and 3.

Discussion

The reconstruction of mandible defects caused by malignancy, odontogenic tumors, and osteomyelitis is among the

most challenging procedures faced by a maxillofacial and plastic surgeon. A variety of different techniques for the treatment of mandibular discontinuity have been described in the literature over the past 30 years [3]. Although the free microvascular tissue transfer technique was established in the late 1960s, the field of mandibular reconstruction was dominated by the use of alloplastic materials and non-vascularized bone grafts until the 1980s [8, 9, 12, 16, 20].

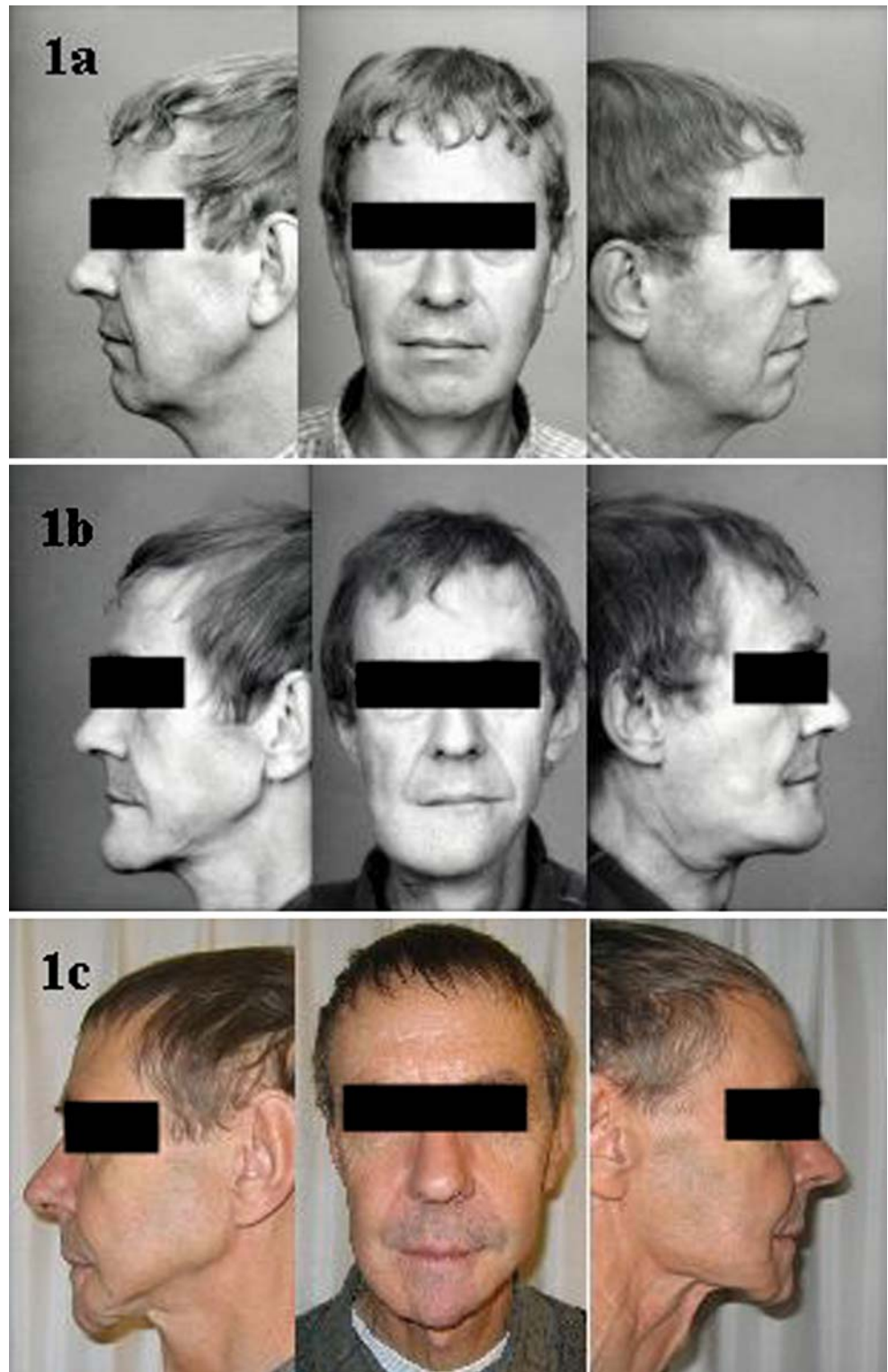
In 1985 Klotch and Prein recommended the use of alloplast and AO plate fixation for reconstruction of the mandible. In their series, they had an 86.7% success rate. They concluded that all patients requiring mandibular resection could be treated using this technique, provided there was adequate soft-tissue coverage. This was essential to prevent plate extrusion and fistula formation and was achieved using the pedicled pectoralis major myocutaneous flap [8, 9]. Hellem and Olofsson [5] and Vuillemin et al. [22] preferred a titanium-coated hollow screw and reconstruction plate system (THORP) for fixation of the mandible. In 1987 Holmes and Hagler [7] described the use of porous hydroxylapatite as a bone graft substitute in mandibular reconstruction. That same year, Nagamine et al. [12] described a method of reconstruction using an aluminium-oxide prosthesis.

In the early 1970s, McCullough, Ostrup, and Fredrickson [10, 13] described the technique of mandible reconstruction using free vascularized rib transplants. Taylor et al. [20] first described the vascularized fibular bone graft in 1975, and the 1980s was dominated by the use of autologous bone graft from a variety of different donor sites including the iliac crest, sternum, radius, and ribs [13, 15, 16, 18]. However, it was not until 1989 that Hidalgo described the first mandible reconstruction using a free vascularized fibula. In his series of 13 patients, there was a 100% success rate of osseous survival [6]. In 1983 Chen and Yan [1] incorporated a skin paddle with the free fibula as a composite graft for soft-tissue coverage. That same year,

Table 4 Outcome of function and patients satisfaction

	Average	Lowest rate	Highest rate
Satisfaction immediately after intervention	4.8	3	6
Satisfaction today	5.3	5	6
Amelioration of life quality true the intervention	4.3	3	6
Intensity of pain			
Preoperative	2.7	1	5
Today	1.0	1	1
Difficulties with swallowing solids			
Preoperative	1.5	1	1
Today	3.3	1	6
Difficulties with swallowing fluids			
Preoperative	1.5	1	1
Today	3.3	1	6
Mouth opening deficit	2.5		
Inability to work after the intervention (day)	107.0		
Self-estimation			
Preoperative	4.8	3	6
Today	4.2	2	5
“Would you do the intervention again?”	6.0	6	6

Fig. 2 Photographic documentation before (a), 6 month after operation (b), and 6 years post-operative (c)



Yoshimura et al. [24] expanded the indications for an osteocutaneous fibular graft with a skin island based on perforator vessels for postoperative monitoring of the free fibula bone graft. In 1989 Wei et al. [23] published their successful results of an anatomical study and a clinical

application of the vascularized free osteoseptocutaneous fibula flap. In their technique, the blood supply to the skin paddle was based solely on a septal perforator.

These developments over the past 20 years have led to a wide variation among the treatment methods used for

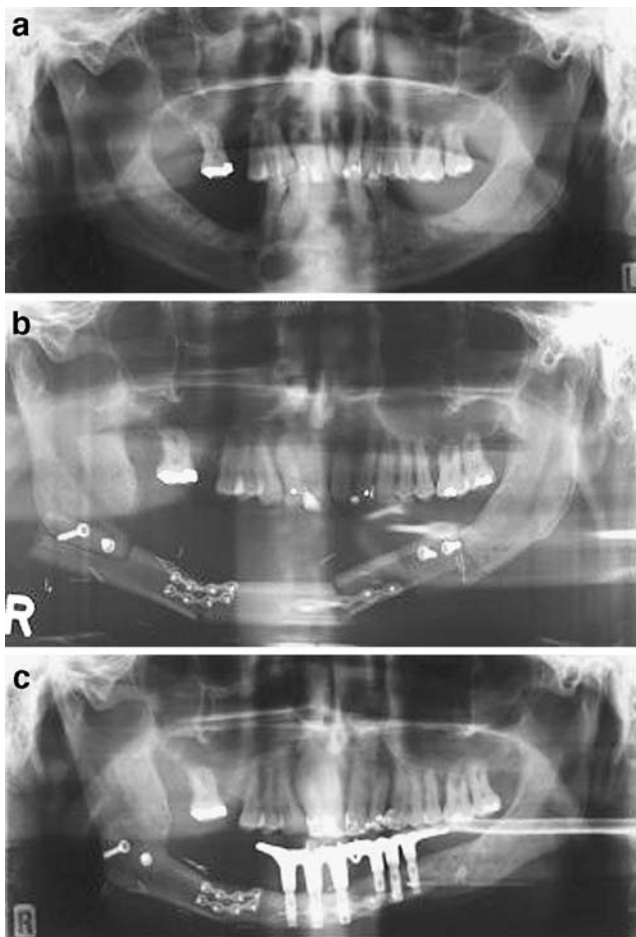


Fig. 3 **a** Preoperative mandible status. **b** Status 6 month postoperative. **c** Status 6 years postoperative

reconstruction of mandible defects. This has led to discord among surgeons regarding the type of reconstruction that is best suited for this problem, taking into account variation in training, infrastructure, and treatment strategies among different surgeons in different countries. More recently, Cordeiro et al. [2] established guidelines pertaining to the indications and timing of mandible reconstruction. A majority of patients who undergo composite resection are candidates for reconstruction, even in the presence of comorbid disease or advanced staging of the tumor. Today it is uncommon to reconstruct a mandibular defect using a nonvascularized bone graft or allograft alone. We agree with Peled et al. [14] that the limitations of nonvascularized bone grafts and alloplastic materials mitigated against satisfactory functional results in the past.

The most common donor sites for osteocutaneous free flaps are the iliac crest, scapula, radius, and fibula. When deciding on the donor tissue, one must take into consideration the size and shape of the graft, the bone quality, the amount of soft tissue needed, the eventual use of osseointegrated dental implants, and the stability of the tissue for alimentation and mastication. In addition, the

surgeon must follow oncological principles for replacement of the resected tissue with donor tissue that is functionally and aesthetically similar [11]. This includes not only the bone and skin but potentially also the tongue, floor of the mouth, lips, cheeks, mental, and submental regions. The fibula is well suited for this type of reconstruction because it provides the greatest bone length, can be contoured using multiple osteotomies for reconstruction of the shape of the arch, is very suitable for accepting dental implants, and can be harvested with a skin flap for reconstruction of mucosa, skin, or tongue defects [4].

Several other reconstructive options exist depending on the extent of the defect. Takushima et al. [19] developed an algorithm for mandibular reconstruction in which the bony defect is defined as either “lateral” or “anterior,” and the soft-tissue defect is classified as “none,” “skin or mucosal,” or “through-and-through.” For proper flap selection, the bony defect should be considered first, followed by the soft-tissue defect. When the bony defect is “lateral” and the soft tissue is “none,” the ilium is the best choice. When the bony defect is “lateral” and a small “skin or mucosal” soft-tissue defect exists, the fibula represents the optimal choice. When the bony defect is “lateral” and an extensive “skin or mucosal” or “through-and-through” soft-tissue defect exists, the scapula should be selected. When the bony defect is “anterior,” the fibula should always be selected. When the “anterior” bone defect is associated with an “extensive” or “through-and-through” soft-tissue defect, the fibula should be used in combination with other soft-tissue flaps. A forearm flap, anterior thigh flap, or rectus abdominis musculocutaneous flap is suitable, depending on the size of the soft-tissue defect [19].

Our data correlate well with that of Cordeiro et al. The mean age of their patients was 50 years [2] compared with our mean age of 54 years (range, 20–84 years). Seventeen out of the 26 patients in our series were male. The increased incidence of these procedures in male patients has also been reported by other authors [21]. This might be the result of differences in alcohol and nicotine consumption between males and females, as most of these procedures are performed for malignancy [2, 14, 17, 21]. In 21 out of our 26 patients, the indication for mandible reconstruction was infiltration or radiation-induced osteonecrosis of the bone secondary to SCC. This comparable to the results of Urken et al. [21] in which 142 of 201 patients had a diagnosis of SCC.

Of the six patients who were available for a follow-up examination, taste and touch of the tongue were mostly preserved (Table 2), but articulation was impaired in 50% of the patients. The sensory innervation of either the left or the right mental nerve was affected in all patients. The mimic musculature was hindered in only one patient (Table 2).

Cordeiro et al. [2] reported that about half of their patients returned to an unrestricted diet. In contrast, all the patients in our study returned to an unrestricted diet, although some had difficulty swallowing. However, it should be considered that we were able to assess long-term functional and aesthetic outcome in only 6 of our 26 patients. Cordeiro et al. [2] also reported that the aesthetic outcome of their patient group was judged as excellent in 32% of patients, good in 27%, fair in 27%, and poor in 14%. In our study, the patients were asked to quantify their change in self-esteem as a result of the operation. The change in self-esteem before and after the procedure has shown to be a very accurate measurement of subjective aesthetic outcome [2, 14]. Using the VAS, we reported a slight decrease in self-esteem from 4.8 to 4.2. As the mimic musculature was hindered slightly in only one patient, it should not cause a bias in using self-esteem as a quantification of aesthetic outcome.

Our results support the guidelines established in the literature with regard to the indications and technique of mandibular reconstruction. For patients who survive their primary tumor, acceptable functional, and aesthetic results can be expected. The risks and benefits of this procedure and its impact on the patients' quality of life should be individualized after informed discussion between patient and the reconstructive surgeon.

References

- Chen ZW, Yan W (1983) The study and clinical application of the osteocutaneous flap of fibula. *Microsurgery* 4:11–16
- Cordeiro P, Disa J, Hidalgo D, Hu QY (1999) Reconstruction of the mandible with osseous free flaps: a 10-year experience with 150 consecutive patients. *Plast Reconstr Surg* 104:1314–1320
- De Fries HO (1971) Reconstruction of the mandible: use of combined homologous mandible and autologous bone. *Arch Otolaryngol* 93:426–432
- Guerra MM, Gias LNRodriguez Campo FJ, Diaz Gonzalez FJ (2001) Vascularized free fibular flap for mandibular reconstruction: a report of 26 cases. *J Oral Maxillofac Surg* 59:140–144
- Hellem S, Olofsson J (1988) Titanium-coated hollow screw and reconstruction plate system (THORP) in mandibular reconstruction. *J Craniomaxillofac Surg* 16:173–183
- Hidalgo DA (1989) Fibula free flap: a new method of mandible reconstruction. *Plast Reconstr Surg* 84:71–79
- Holmes RE, Hagler HK (1987) Porous hydroxylapatite as a bone graft substitute in mandibular contour augmentation: a histometric study. *J Oral Maxillofac Surg* 45:421–429
- Klotch DW, Billger JR (1985) Plate fixation for open mandibular fractures. *Laryngoscope* 95:1374–1377
- Klotch DW, Prein J (1987) Mandibular reconstruction using AO plates. *Am J Surg* 154:384–388
- McCullough DW, Fredrickson JM (1972) Composite neovascularized rib grafts for mandibular reconstruction. *Surg Forum* 23:492–494
- Moscoco JF, Keller J, Genden E, Weinberg H, Biller HF, Buchbinder D, Urken MF (1994) Vascularized bone flaps in oromandibular reconstruction. A comparative anatomic study of bone stock from various donor sites to assess suitability for endosseous dental implants. *Arch Otolaryngol Head Neck Surg* 120:36–43
- Nagamine T, Yakata H, Nakajima T (1987) Secondary reconstruction of the mandible with an aluminum oxide prosthesis. *J Oral Maxillofac Surg* 45:173–176
- Ostrup LT, Fredrickson JM (1975) Reconstruction of mandibular defects after radiation, using a free, living bone graft transferred by microvascular anastomose. An experimental study. *Plast Reconstr Surg* 55:563–572
- Peled M, El-Naaj IA, Lipin Y, Ardekian L (2005) The use of free fibular flap for functional mandibular reconstruction. *J Oral Maxillofac Surg* 63:220–224
- Robertson GA (1986) A comparison between sternum and rib in osteomyocutaneous reconstruction of major mandibular defects. *Ann Plast Surg* 17:421–433
- Serafin D, Villareal RA, Georgiade NG (1977) Rib-containing free flap to reconstruct mandibular defects. *Br J Plast Surg* 30:263–266
- Shindo M et al. (2000) The fibula osteocutaneous flap in head and neck reconstruction: a critical evaluation of donor site morbidity. *Arch Otolaryngol Head Neck Surg* 126:1467–1472
- Soutar DS, Scheker LR, Tanner NSB, McGregor IA (1983) The radial forearm flap: a versatile method for intraoral reconstruction. *Br J Plast Surg* 36:1–8
- Takushima A, Harii K, Asato H, Momosawa A, Okazaki M, Nakatsuka T (2005) Choice of osseous and osteocutaneous flaps for mandibular reconstruction. *Int J Clin Oncol* 10:234–242
- Taylor GI, Miller GD, Ham FJ (1975) The free vascularized bone graft. A clinical extension of microvascular techniques. *Plast Reconstr Surg* 55:533–544
- Urken ML et al. (1998) Oromandibular reconstruction using microvascular composite flaps: report of 210 cases. *Arch Otolaryngol Head Neck Surg* 124:46–55
- Vuillemain T, Raveh J, Sutter T (1988) Mandibular reconstruction with the titanium hollow screw reconstruction plate (THORP) system: evaluation of 62 cases. *Plast Reconstr Surg* 82(5):804–814
- Wei FC, Chen HC, Chuang CC, Noordhoff FC (1986) Fibular osteoseptocutaneous flap: anatomic study and clinical application. *Plast Reconstr Surg* 78:191–200
- Yoshimura M, Shimamura K, Iwai Y, Yamauchi S, Ueno T (1983) Free vascularized fibular transplant. A new method for monitoring circulation of the grafted fibula. *J Bone Joint Surg Am* 65:1295–1301