



**University of  
Zurich**<sup>UZH</sup>

**Zurich Open Repository and  
Archive**

University of Zurich  
Main Library  
Strickhofstrasse 39  
CH-8057 Zurich  
[www.zora.uzh.ch](http://www.zora.uzh.ch)

---

Year: 2018

---

## **A rare complication of electric cardioversion in an elderly patient “Electrical Takotsubo”**

Di Valentino, M ; Mocetti, Marco ; Previsdomini, Marco ; Biasco, Luigi

DOI: <https://doi.org/10.4414/cvm.2018.00548>

Posted at the Zurich Open Repository and Archive, University of Zurich

ZORA URL: <https://doi.org/10.5167/uzh-158740>

Journal Article

Published Version



The following work is licensed under a Creative Commons: Attribution-NonCommercial-NoDerivatives 4.0 International (CC BY-NC-ND 4.0) License.

Originally published at:

Di Valentino, M; Mocetti, Marco; Previsdomini, Marco; Biasco, Luigi (2018). A rare complication of electric cardioversion in an elderly patient “Electrical Takotsubo”. *Cardiovascular Medicine*, 21(03):78-81.

DOI: <https://doi.org/10.4414/cvm.2018.00548>

## A rare complication of electric cardioversion in an elderly patient

## "Electrical Takotsubo"

Marcello Di Valentino<sup>a</sup>, Marco Moccetti<sup>b</sup>, Marco Previsdomini<sup>c</sup>, Luigi Biasco<sup>b</sup>, Andrea Menafoglio<sup>a</sup><sup>a</sup> Division of Cardiology Ospedale San Giovanni, Bellinzona, Switzerland; <sup>b</sup> Fondazione Cardiocentro Ticino, Lugano, Switzerland;<sup>c</sup> Intensive Care Unit, Ospedale San Giovanni, Bellinzona, Switzerland

An 84-year-old woman known to have arterial hypertension was sent to our division because of new onset symptomatic typical atrial flutter with a heart rate of about 130 bpm (fig. 1).

Transthoracic echocardiography (TTE) revealed mild left ventricular hypertrophy with normal systolic function. We decided to schedule the patient for electric cardioversion and we started oral anticoagulation (rivaroxaban 20 mg). After the first electric shock, there was a sinus arrest lasting 15 seconds, without ventricular escape rhythm (fig. 2).

The first ECG after restoration of sinus rhythm showed diffuse ST-segment elevation (fig. 3).

TTE revealed extensive left ventricular apical akinesia with moderate systolic dysfunction. High-sensitive troponin I was elevated (797 ng/l; reference range <40 ng/l). Urgent coronary angiography showed normal coronary arteries (fig. 4, panel A, A1 and B), and ventriculography revealed apical ballooning (fig. 4, panel C and D).

Next day, junctional rhythm with a very prolonged QTc interval was noticed on the ECG (fig. 5).

We implanted a dual chamber pacemaker programmed in AAI/DDD 70–130 bpm modality. After one week, the repolarisation had completely normalised and TTE revealed full recovery of the left ventricular systolic function without any segmental abnormalities. Takotsubo syndrome following electric cardioversion was diagnosed.

Takotsubo syndrome is an acute and usually reversible heart failure syndrome characterised by transient systolic and diastolic left ventricular dysfunction in the absence of obstructive coronary artery disease [1,2]. Several causes have been described [2], but only a few cases after electric cardioversion, as in our patient, have been reported [3–4].

It is likely that the stress induced by electric cardioversion followed by prolonged asystole caused the clinical picture.

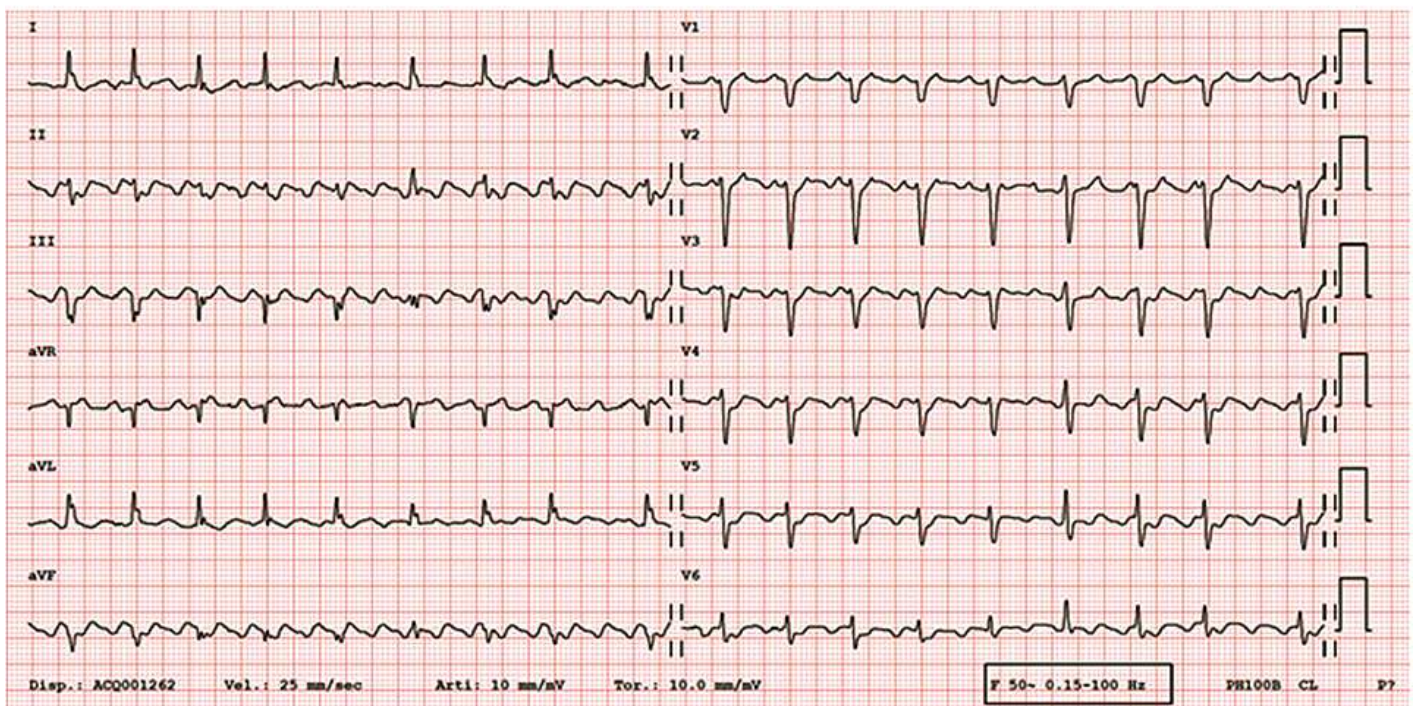


Figure 1: ECG showing typical atrial flutter with ventricular rate at about 130 bpm.



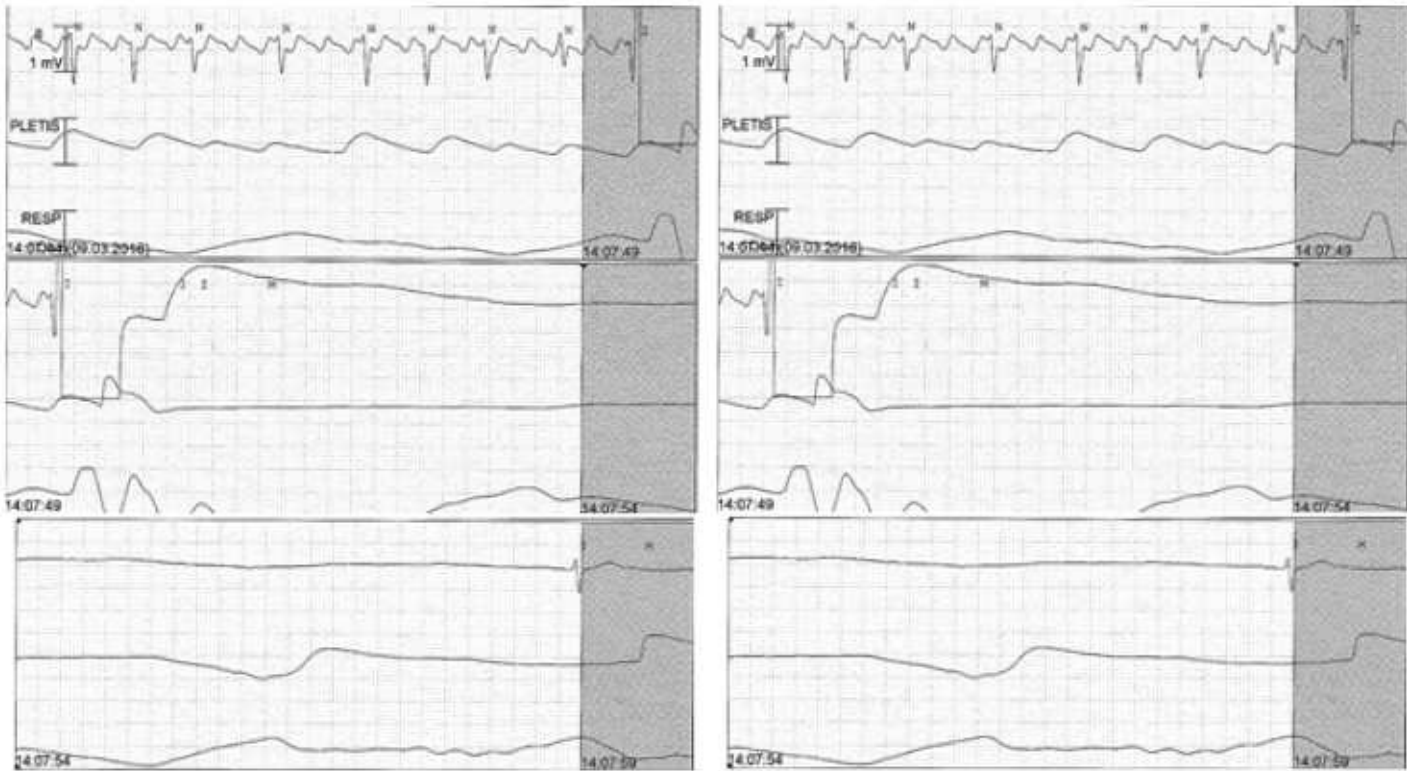


Figure 2: ECG monitoring showing sinus arrest (15 seconds) after electric cardioversion.

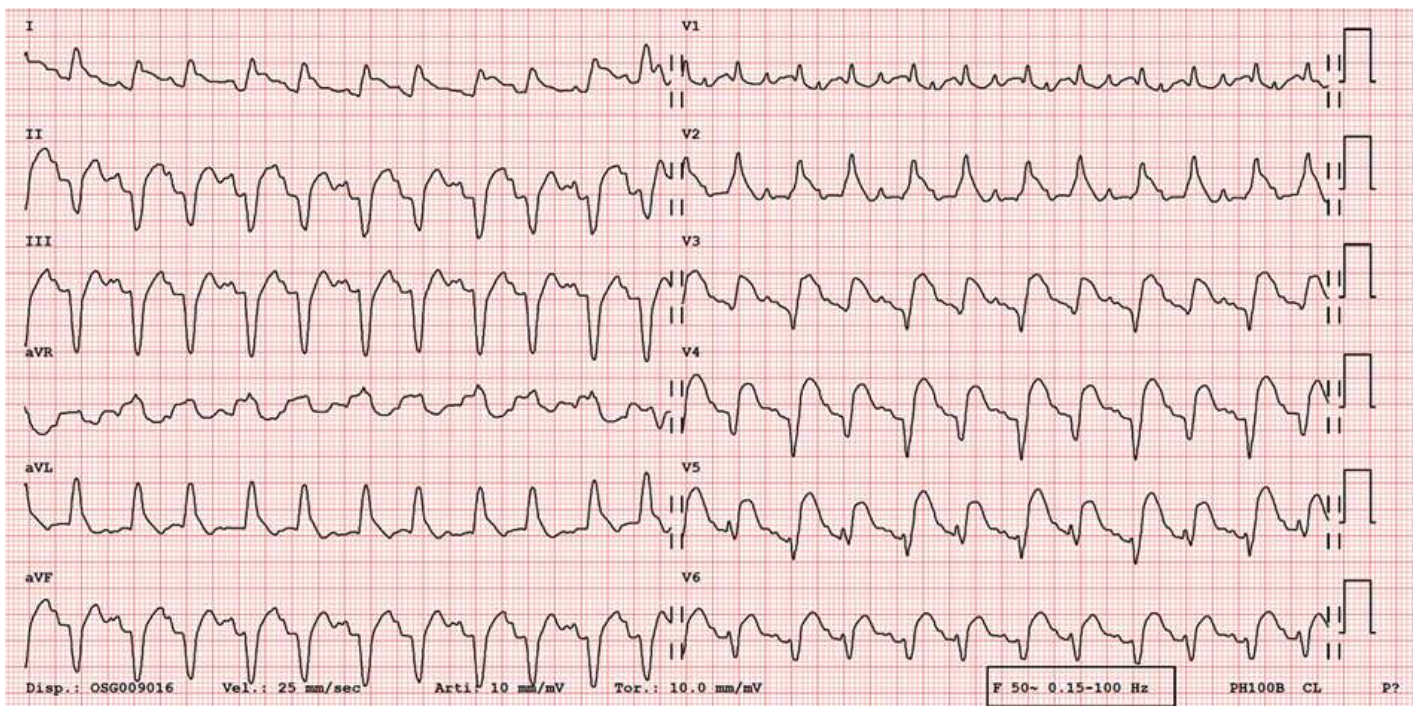


Figure 3: ECG showing sinus rhythm (140 bpm) with diffuse ST-segment elevation.



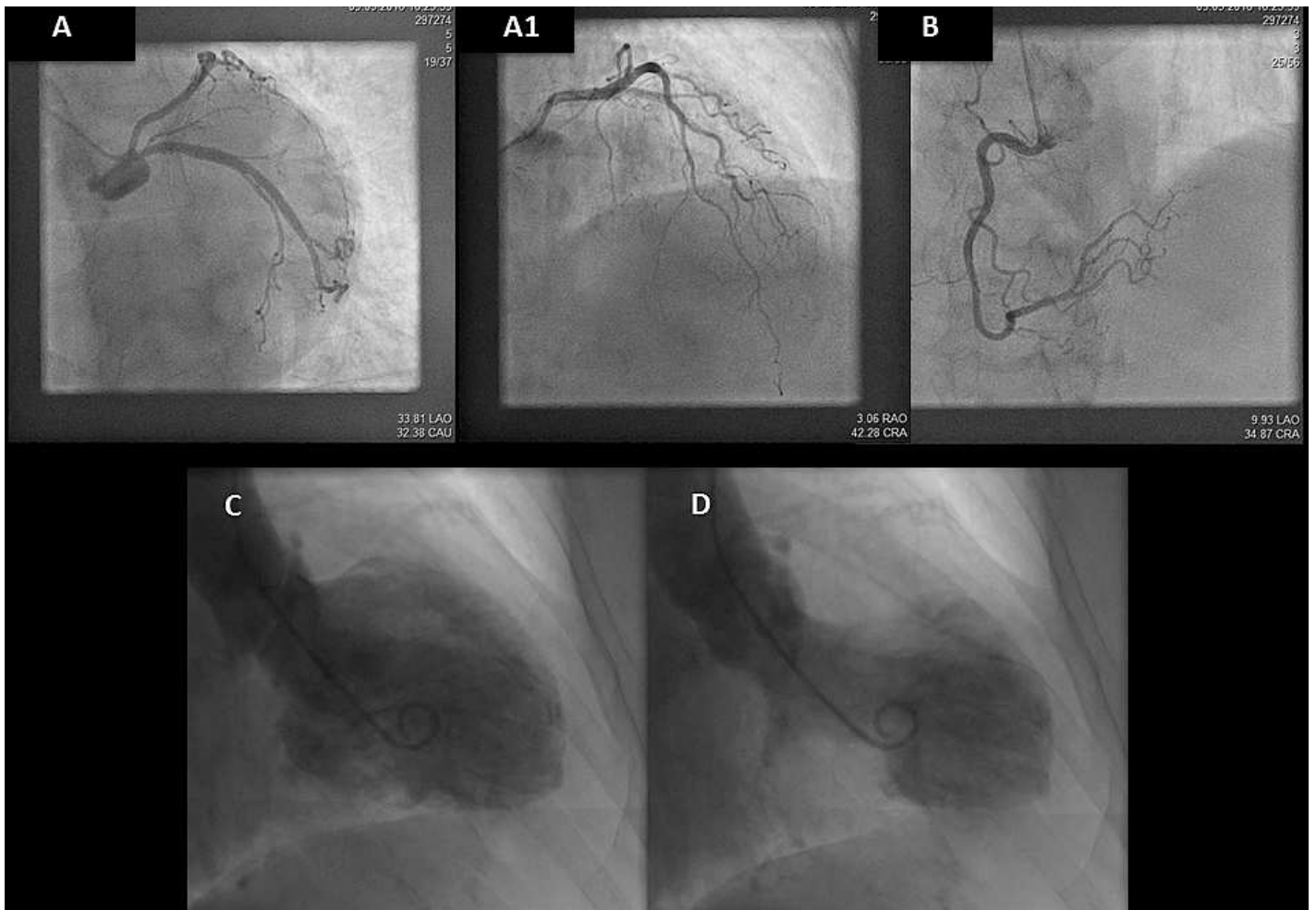


Figure 4: Coronary angiography. Panel A-A1-B showed normal coronary arteries; panel C-D ventriculography with apical ballooning.

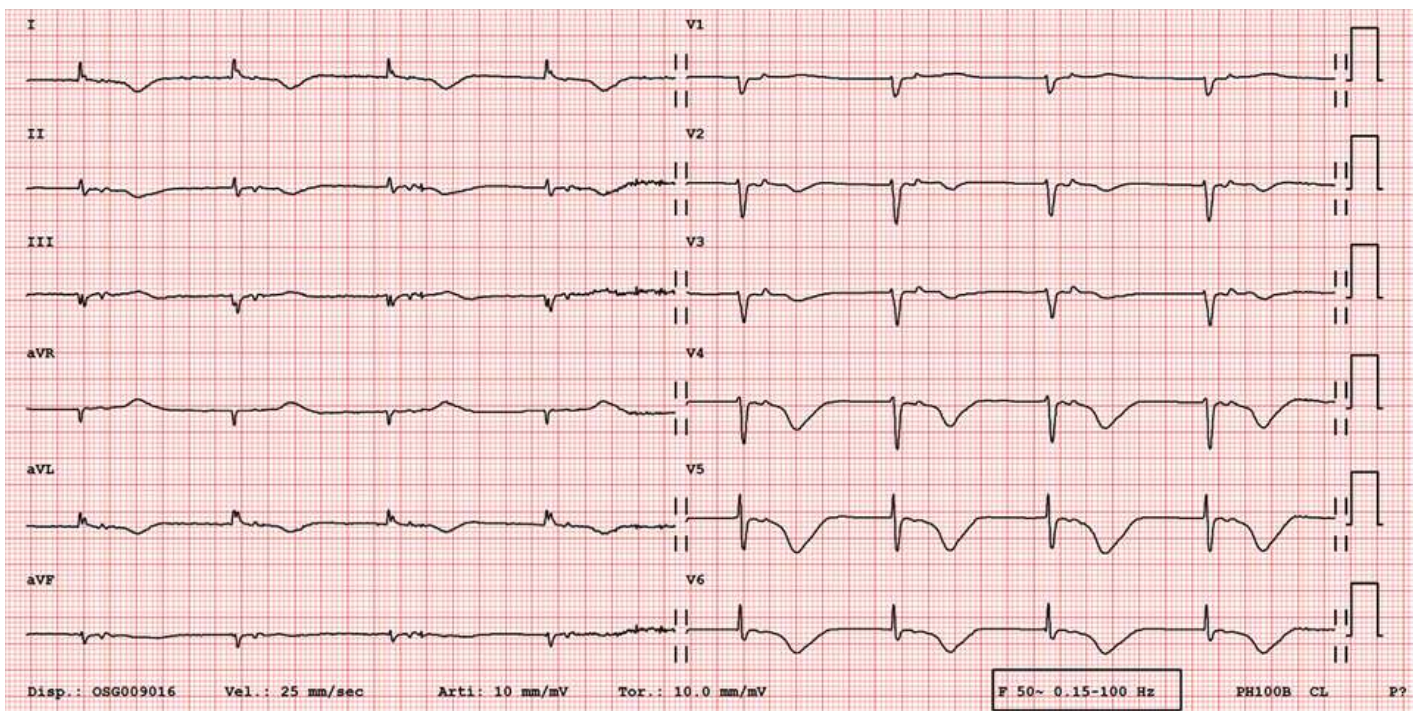


Figure 5: ECG showing junctional rhythm with very prolonged QTc interval and deep negative T-waves in antero-lateral leads.

In conclusion, our case illustrates a rare complication of electric cardioversion for atrial flutter leading to a Takotsubo syndrome. In elderly patients, the risks and benefits of electric cardioversion for atrial arrhythmias should be carefully evaluated.

**Disclosure statement**

No financial support and no other potential conflict of interest relevant to this article was reported.

**Correspondence:**

Marcello Di Valentino, MD  
Division of Cardiology  
Ospedale San Giovanni  
CH-6500 Bellinzona  
marcello.divalentino[at]  
eoc.ch

**References**

- 1 Lyon AR, Bossone E, Schneider B, Sechtem U, Citro R, Underwood SR, et al. Current state of knowledge on Takotsubo syndrome: a Position Statement from the Taskforce on Takotsubo Syndrome of the Heart Failure Association of the European Society of Cardiology. *Eur J Heart Fail.* 2016;18:8–27.
- 2 Templin C, Ghadri JR, Diekmann J, Napp LC, Bataiosu DR, Jaguszewski M, et al. Clinical Features and Outcomes of Takotsubo (Stress) Cardiomyopathy. *N Engl J Med.* 2015;373:929–38.
- 3 McCutcheon K, Butler I, Vachiat A, Manga P. Takotsubo syndrome in an elderly woman due to electrical cardioversion. *Int J Cardiol.* 2016;224:69–71.
- 4 Siegfried JS, Bhusri S, Guttenplan N, Coplan NL. Takotsubo cardiomyopathy as a sequela of elective direct-current cardioversion for atrial fibrillation. *Tex Heart Inst J.* 2014;41:184–7.