



## Bogota-VAC – A Newly Modified Temporary Abdominal Closure Technique

von Rüden, C ; Benninger, E ; Mayer, D ; Trentz, O ; Labler, L

**Abstract:** Background: We present Bogota-VAC, a newly modified temporary abdominal closure (TAC) technique for open abdomen condition after abdominal compartment syndrome (ACS). Methods: A thin isolation bag (Bogota bag) and a vacuum assisted closure (VAC) system were combined. A matching bag was tension-free fixed on the abdominal fascia by fascia suture. A ring shaped black polyurethane foam of the VAC system was placed into the gap between Bogota bag, abdominal fascia and the wound edge. A constant negative topic pressure of 50–75 mmHg was used in the VAC system. Results: Intra-abdominal pressure (IAP:  $22 \pm 2$  mmHg) of four patients with ACS after severe traumatic brain injury and one patient with isolated ACS after blunt abdominal trauma decreased significantly ( $p = 0.01$ ) after decompressive laparotomy and treatment with Bogota-VAC (IAP:  $10 \pm 2$  mmHg) and remained low, measured via urinary bladder pressure. Intracranial pressure (ICP) in the four traumatic brain injury patients decreased from  $42 \pm 13$  mmHg to  $15 \pm 3$  mmHg after abdominal decompression. Cerebral perfusion pressure ( $57 \pm 14$  mmHg) increased to  $74 \pm 2$  mmHg. Conclusion: The advantage of the presented Bogota-VAC is leak tightness, wound conditioning (soft tissue/fascia), skin protection and facilitation of nursing in combination with highest volume reserve capacity (VRC), thus preventing recurrent increased intra-abdominal and intracranial pressure in the initial phase after decompression of ACS compared to other TAC techniques.

DOI: <https://doi.org/10.1007/s00068-008-8007-y>

Posted at the Zurich Open Repository and Archive, University of Zurich

ZORA URL: <https://doi.org/10.5167/uzh-15893>

Journal Article

Published Version

Originally published at:

von Rüden, C; Benninger, E; Mayer, D; Trentz, O; Labler, L (2008). Bogota-VAC – A Newly Modified Temporary Abdominal Closure Technique. *European Journal of Trauma and Emergency Surgery*, 34(6):582-586.

DOI: <https://doi.org/10.1007/s00068-008-8007-y>

# Bogota-VAC – A Newly Modified Temporary Abdominal Closure Technique

Christian von Rden<sup>1</sup>, Emanuel Benninger<sup>1</sup>, Dieter Mayer<sup>2</sup>, Otmar Trentz<sup>1</sup>, Ludwig Labler<sup>1</sup>

## Abstract

**Background:** We present Bogota-VAC, a newly modified temporary abdominal closure (TAC) technique for open abdomen condition after abdominal compartment syndrome (ACS).

**Methods:** A thin isolation bag (Bogota bag) and a vacuum assisted closure (VAC) system were combined. A matching bag was tension-free fixed on the abdominal fascia by fascia suture. A ring shaped black polyurethane foam of the VAC system was placed into the gap between Bogota bag, abdominal fascia and the wound edge. A constant negative topic pressure of 50–75 mmHg was used in the VAC system.

**Results:** Intra-abdominal pressure (IAP:  $22 \pm 2$  mmHg) of four patients with ACS after severe traumatic brain injury and one patient with isolated ACS after blunt abdominal trauma decreased significantly ( $p = 0.01$ ) after decompressive laparotomy and treatment with Bogota-VAC (IAP:  $10 \pm 2$  mmHg) and remained low, measured via urinary bladder pressure. Intracranial pressure (ICP) in the four traumatic brain injury patients decreased from  $42 \pm 13$  mmHg to  $15 \pm 3$  mmHg after abdominal decompression. Cerebral perfusion pressure ( $57 \pm 14$  mmHg) increased to  $74 \pm 2$  mmHg.

**Conclusion:** The advantage of the presented Bogota-VAC is leak tightness, wound conditioning (soft tissue/fascia), skin protection and facilitation of nursing in combination with highest volume reserve capacity (VRC), thus preventing recurrent increased intra-abdominal and intracranial pressure in the initial phase after decompression of ACS compared to other TAC techniques.

## Key Words

Abdominal compartment syndrome (ACS) · Intra-abdominal pressure (IAP) · Temporary abdominal closure (TAC) · Vacuum-assisted closure (VAC) · Volume reserve capacity (VRC)

Eur J Trauma Emerg Surg 2008;34:582–6

DOI 10.1007/s00068-008-8007-y

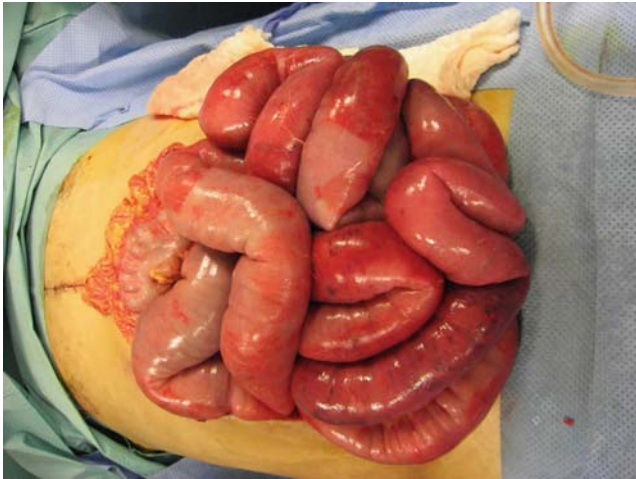## Introduction

Abdominal compartment syndrome (ACS) is defined as a situation of increased intra-abdominal pressure (IAP)  $\geq 20$  mmHg with isolated or multiple organ system failure that was not previously present [1]. The concept of damage-control laparotomy is a well-established technique for the primary treatment of abdominal trauma in severely injured patients [2] according to the advanced trauma life support (ATLS<sup>®</sup>) concept [3]. In many cases after damage-control surgery or ACS a primary fascial closure may not be possible because of intra-abdominal intestinal edema, retroperitoneal hematoma or packing of the abdominal cavity. Repeated intra-abdominal exploration of primarily closed laparotomy after damage-control procedures may result in ischemia or necrosis of the abdominal fascia leading to open abdomen condition [4]. In all these cases temporary abdominal closure (TAC) is indicated for prevention of contamination of the peritoneal cavity, bowel desiccation, evisceration, mechanical injury of the viscera [4], and fascia necrosis due to early laparotomy closure [5]. Existing TAC techniques encompass many different systems like the zipper system [6], different variations of vacuum-assisted closure (VAC) [7] or a bag silo closure, the so-called Bogota bag [8]. In a recent in vitro study, the influence of different TAC models on the increase of IAP and development of intra-abdominal hypertension (IAH) was evaluated, using the volume reserve capacity (VRC) as parameter of comparison. Following the results of the present study, bag silo closure showed highest VRC of all evaluated

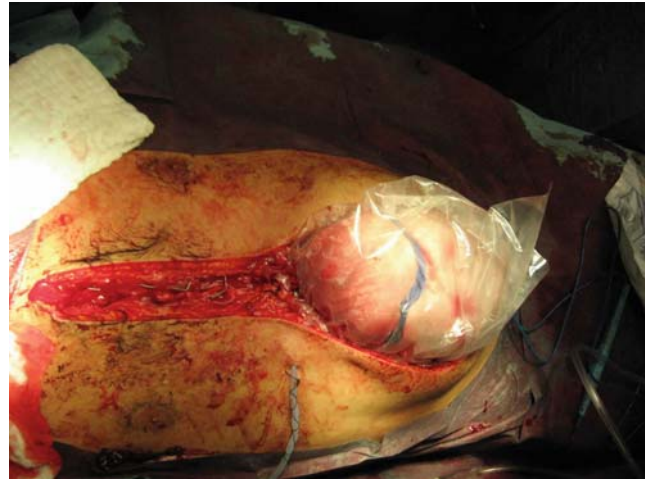<sup>1</sup>Division of Trauma Surgery, Department of Surgery, University Hospital Zurich, Zurich, Switzerland,

<sup>2</sup>Division of Cardiovascular Surgery, Department of Surgery, University Hospital Zurich, Switzerland.

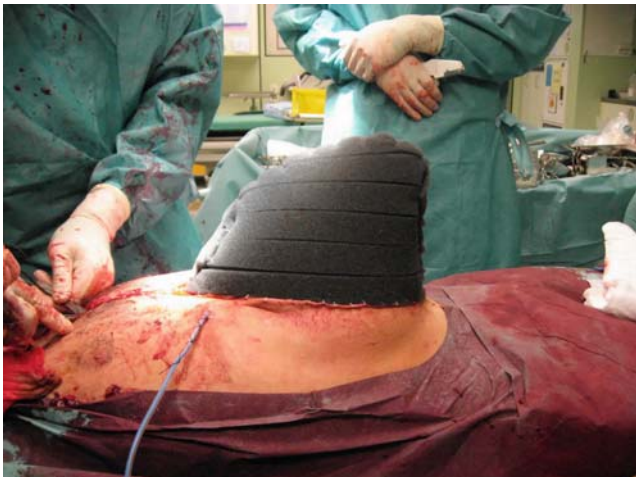Received: January 12, 2008; revision accepted: May 22, 2008;  
Published Online: July 22, 2008



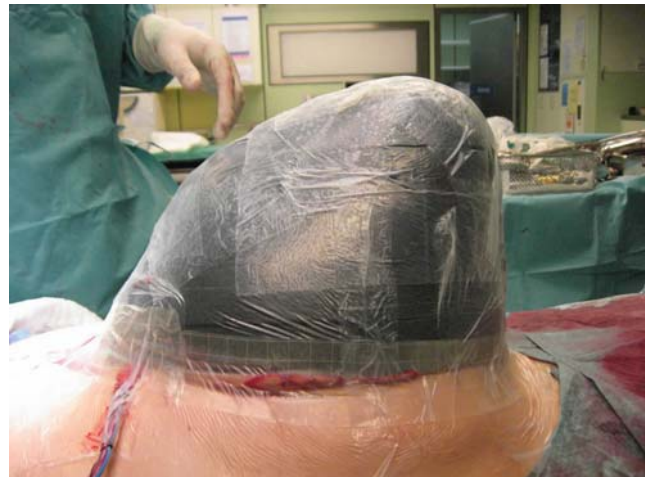**Figure 1.** Patient 1 with open abdomen condition after damage-control laparotomy.



**Figure 2.** A thin isolation bag, the so-called Bogota bag, was tension-free fixed on the abdominal fascia by fascia suture.



**Figure 3.** Bogota bag was encapsulated in the black polyurethane foam of the conventional VAC system.



**Figure 4.** The skin was cleaned with benzine. Adhesive dressing drapes of the VAC system were trimmed as a patchwork to seal the wound.

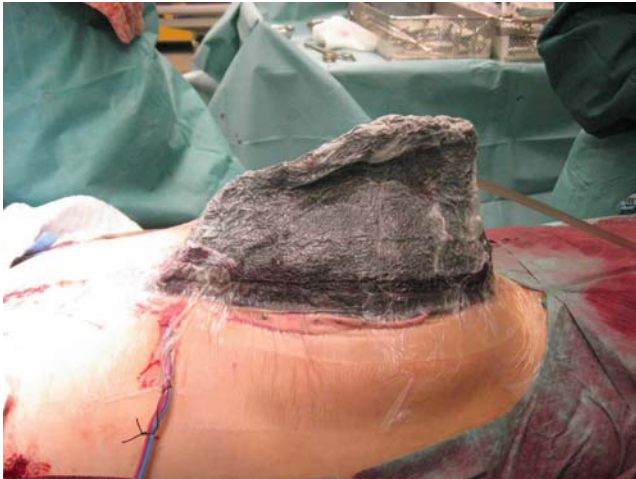different TAC techniques. VAC and zipper system resulted in significantly lower VRC compared with bag silo closure [9]. Due to these results, we searched for an abdominal temporary closure technique combining the advantages of both bag silo closure and VAC. A newly modified TAC technique for efficient treatment of open abdomen condition after ACS (Figure 1) was introduced. To our knowledge, this is the first report using the Bogota-VAC system for treatment of patients with ACS.

### Materials and Methods

In the first treated patient with open abdomen situation after decompressive laparotomy (Figure 1), a commercially available thin isolation bag (Vi-Drape<sup>®</sup>; MCD, St Paul, MN, USA) was used. The Vi-Drape<sup>®</sup>

was cut into shape at the base, forming a matching bag. It was fixed tension-free via running fascia suture to the abdominal fascia keeping a distance of about 1 cm between the sutures (Figure 2). In addition, a conventional abdominal wound dressing system (V.A.C.<sup>®</sup> Vacuum-Assisted Closure; KCI, San Antonio, TX, USA) was used (Figure 3). The Vi-Drape<sup>®</sup> was encapsulated in the black polyurethane foam of the VAC system. The skin surrounding the wound was cleaned with benzine. Adhesive dressing drapes (V.A.C.<sup>®</sup> Vacuum Assisted Closure; KCI, San Antonio, TX, USA) were trimmed as a patchwork to seal the wound (Figure 4). A hole of 1–2 cm in diameter was cut out in the dressing drape. The TRAC-PAD<sup>®</sup> (V.A.C.<sup>®</sup> Vacuum Assisted Closure; KCI, San Antonio, TX, USA) was positioned on the hole and





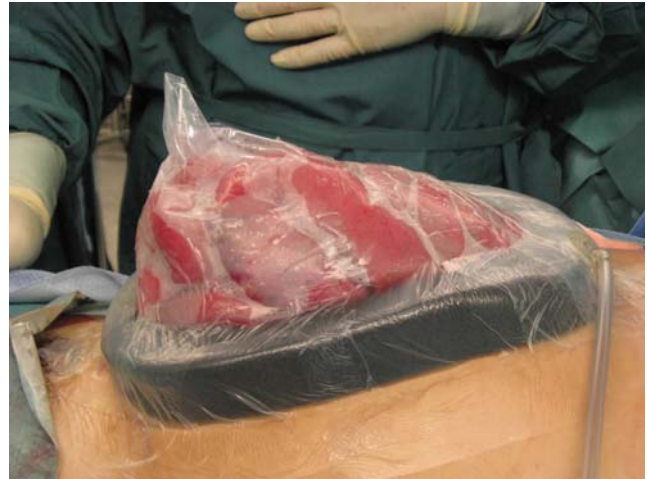**Figure 5.** The TRAC-PAD<sup>®</sup> was positioned on the hole of 1–2 cm in diameter and connected to a vacuum pump by a container. When suction was applied the layers with the foam collapsed.

connected to a vacuum pump by a container (V.A.C.<sup>®</sup> Vacuum Assisted Closure; KCI, San Antonio, TX, USA). When suction was started and the foam collapsed, the VRC decreased significantly under topic negative pressure of 50–75 mmHg (Figure 5).

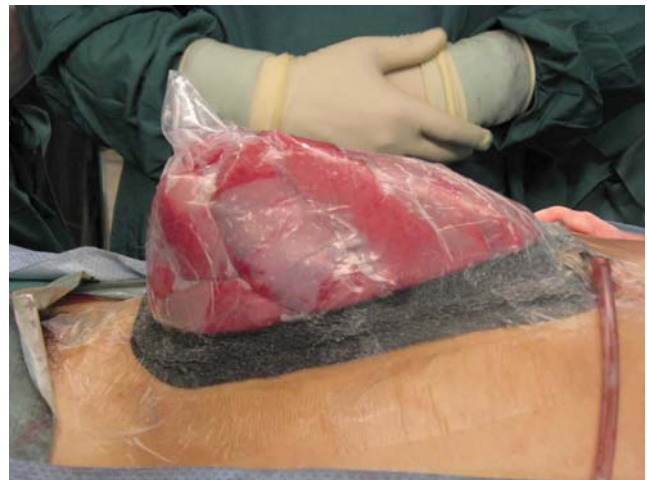In order to get a higher VRC than in the first treated patient in the next four patients the black polyurethane foam was cut into a ring shape. The ring shaped black polyurethane foam was put into the gap between Bogota bag, the abdominal fascia and the wound edge (Figure 6). If necessary, the foam was fixed to the skin edges by staples. According to treatment of the first patient, the skin surrounding the wound was cleaned with benzine and adhesive dressing drapes were used. The TRAC-PAD<sup>®</sup> (V.A.C.<sup>®</sup> Vacuum Assisted Closure; KCI, San Antonio, TX, USA) was positioned on a hole with a diameter of 1–2 cm in the dressing drape and connected to a vacuum pump by a container. When suction was applied the layers with the foam collapsed creating a constant negative topic pressure of 50–75 mmHg (Figure 7) on the wound edges to drain the abdominal cavity, but not to produce tension on the abdominal wall. Second look operations were performed every 2–3 days (Figures 8–12). Statistical analysis was performed using Excel<sup>®</sup> 10.0 for Windows XP<sup>®</sup> (Microsoft, Redmont, WA, USA).

### Results

In a prospective study Bogota-VAC application was tested in five patients. Intra-abdominal pressure (IAP:  $22 \pm 2$  mmHg) of four patients with ACS after severe

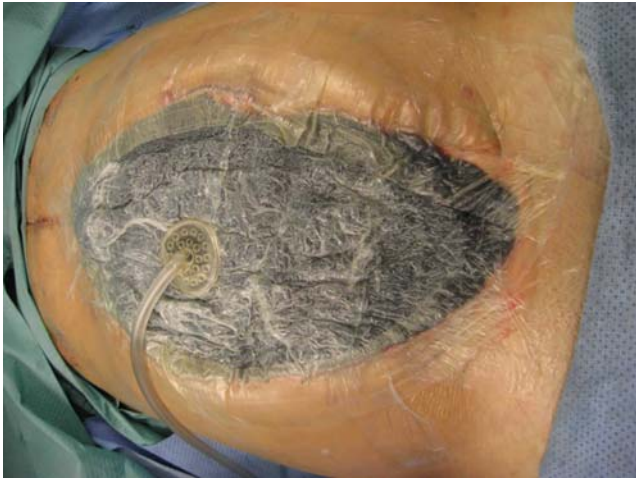

**Figure 6.** Patients 2–5: in addition to patient 1, Bogota bag was fixed tension-free via fascia suture to the abdominal fascia. In contrast to the first patient, a ring shaped black polyurethane foam of the VAC system was put into the gap between Bogota bag, abdominal fascia and the wound edge fixed to the skin edges by staples. A hole was punched and the TRAC-PAD<sup>®</sup> of the VAC system was positioned on the occlusive seals. The TRAC-PAD<sup>®</sup> was connected to a vacuum pump by a container.

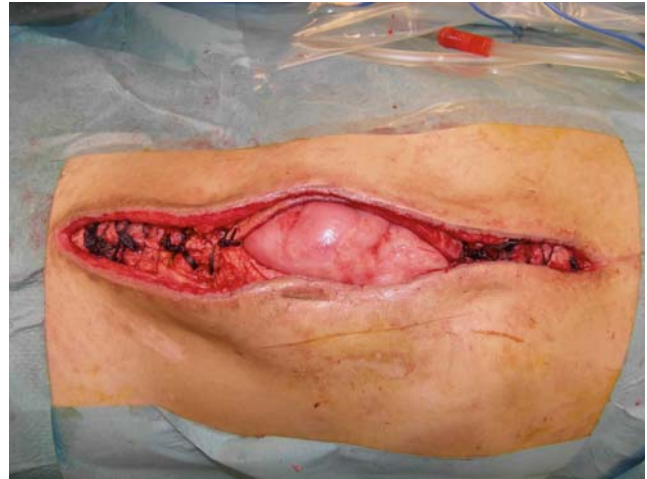

**Figure 7.** Suction was applied under constant topic negative pressure (50–75 mmHg), and Bogota-VAC collapsed.

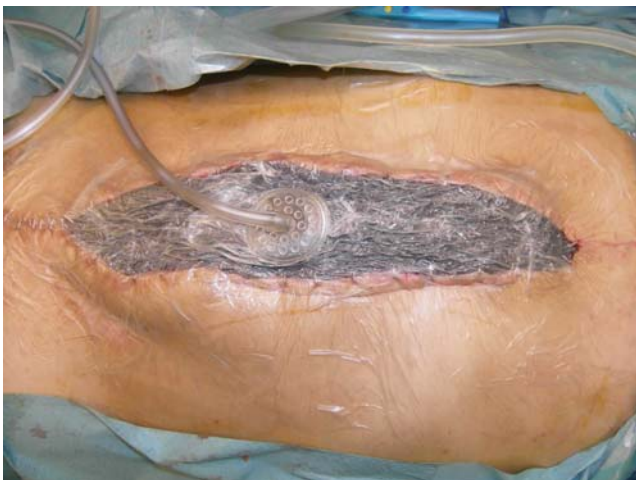traumatic brain injury and one patient with isolated ACS after blunt abdominal trauma decreased significantly ( $p = 0.01$ ; paired t test) after decompressive laparotomy and treatment with Bogota-VAC (IAP:  $10 \pm 2$  mmHg) and remained low, measured via urinary bladder pressure. The intracranial pressure in the four traumatic brain injury patients decreased from  $42 \pm 13$  to  $15 \pm 3$  mmHg after abdominal decompression. Cerebral perfusion pressure ( $57 \pm 14$  mmHg) increased to  $74 \pm 2$  mmHg. On average, treatment



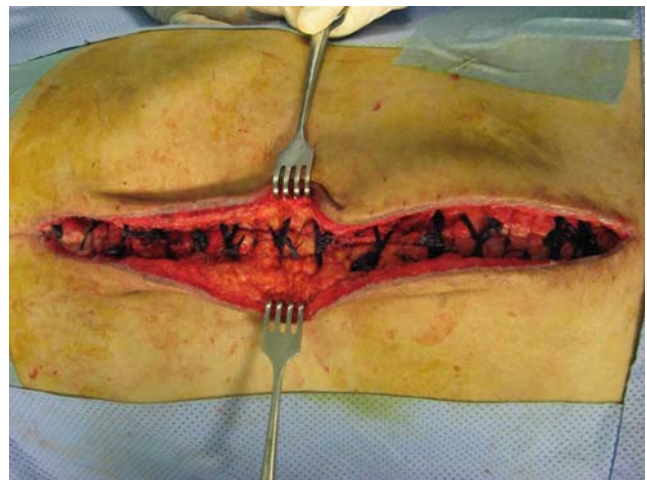
**Figure 8.** On average, initial treatment with Bogota-VAC was changed to conventional VAC system after 8 days.



**Figure 9.** When the edema resolved, no necrosis was present on fascia layers and granulation tissue formation of subcutaneous tissue took place, fascia was stepwise closed by suturing.



**Figure 10.** Second look operations were performed every 2–3 days.



**Figure 11.** Secondary wound closure was performed on average 22 days after damage-control laparotomy.

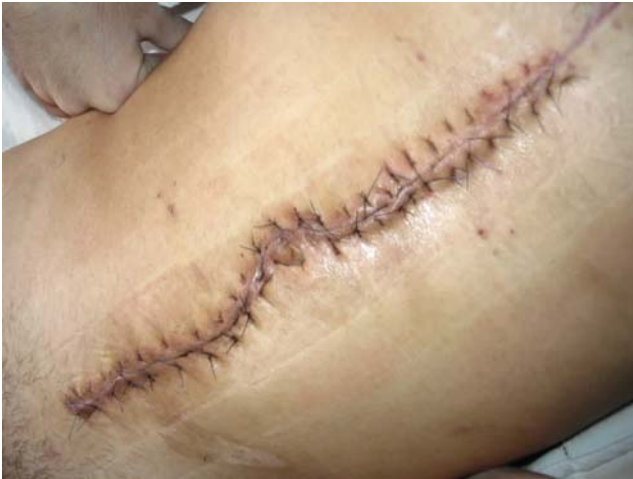with Bogota-VAC was changed to conventional VAC system after 8 days. Secondary wound closure was performed on average 22 days after damage-control laparotomy. In all patients, initial therapy with Bogota-VAC was performed without any complications caused by this system.

### Discussion

ACS demonstrates increasing incidence in modern trauma centers [10, 11]. When using TAC in order to manage this complex situation some authors advocate bag silo closure or other methods instead of common VAC technique [12]. Bogota-VAC combines advantages of both bag silo closure and VAC technology.

The components are commercially available for trauma centers in developed countries. The method can be applied in short time without any technical difficulties and is easy to handle. The advantages of commercially sold VAC technology are well known and include leak tightness, fluid assessment wound conditioning of soft tissue and fascia, easy handling, and the possibility to seal leaks using an additional piece of the adhesive dressing drapes. Replacement of polyurethane foam, adhesive dressing drapes and TRAC-PAD<sup>®</sup> is possible without any major problems at the bedside [4]. In most cases, use of VAC technique allows primary fascia closure preventing formation of large ventral hernias [4]. Thereby, use of ring shaped black polyurethane foam of VAC system facilitates skin protection and





**Figure 12.** Final situation after secondary wound closure.

nursing. Transparency of the so-called Bogota bag as part of Bogota-VAC allows continuous assessment of the intestinal bowel and for early detection of perfusion changes, caused for example, by ischemia at an earlier time point compared to conventional VAC system. As a result, early surgical intervention can be performed if needed. Well-known complications of the application of conventional VAC system in conditions of open abdomen include progressive ACS and fistula formations [7, 12, 13]. These problems may be prevented using the Bogota-VAC: a recent *in vitro* study using bag silo closure measured a VRC of approximately 3,000 ml [9]. Therefore, the Bogota bag part of Bogota-VAC demonstrated highest VRC of all TAC techniques and helped to prevent ACS.

### Conclusion

The advantages of the Bogota-VAC system presented in this study include leak tightness and wound conditioning (soft tissue/fascia) in combination with increased VRC. Therefore, Bogota-VAC may prevent recurrent increased intra-abdominal and intracranial pressure in the initial phase after decompression of ACS compared to other TAC techniques. Use of Bogota-VAC facilitates fluid assessment nursing and skin protection. In patients with low IAP and low risk for ACS, conventional abdominal VAC therapy remains the first choice.

### References

1. World Society for Abdominal Compartment Syndrome Consensus: Definitions and Recommendations. <http://www.wsacs.org>.
2. Shapiro MB, Jenkins DH, Schwab CW. Damage control: collective review. *J Trauma* 2000;49:969–78.
3. Collicott PE, Hughes I. Training in advanced trauma life support. *JAMA* 1980;243:1156–9.
4. Labler L, Zwingmann J, Mayer D, Stocker R, Trentz O, Keel M. V.A.C.<sup>®</sup> abdominal dressing system. *Eur J Traum* 2005;31:488–94.
5. Howdieshell TR, Yeh KA, Hawkins ML, Cu JI. Temporary abdominal wall closure in trauma patients: indications, technique, and results. *World J Surg* 1995;19:154–8.
6. Cuesta MA, Doblaz M, Castaeda L, Bengoechea E. Sequential abdominal reexploration with the zipper technique. *World J Surg* 1991;15:74–80.
7. Brock WB, Barker DE, Burns RP. Temporary closure of open abdominal wounds: the vacuum pack. *Am Surg* 1995;61:30–5.
8. Fernandez L, Norwood S, Roettger R, Wilkins HE. Temporary intravenous bag silo closure in severe abdominal trauma. *J Trauma* 1996;40:258–60.
9. Benninger E, Labler L, Seifert B, Trentz O, Menger MD, Meier C. In vitro comparison of intra-abdominal hypertension development after different temporary abdominal closure techniques. *J Surg Res* 2008;144:102–6.
10. Balogh Z, McKinley BA, Cox CS Jr, Allen SJ, Cocanour CS, Kozar RA, Moore EE, Miller CC III, Weisbrodt NW, Moore FA. Abdominal compartment syndrome: the cause or effect of postinjury multiple organ failure. *Shock* 2003;20:483–92.
11. Saggi BH, Sugerman HJ, Ivatury RR, Bloomfield GL. Abdominal compartment syndrome. *J Trauma* 1998;45:597–609.
12. Suliburk JW, Ware DN, Balogh Z, McKinley BA, Cocanour CS, Kozar RA, Moore FA, Ivatury RR. Vacuum-assisted wound closure achieves early fascial closure of open abdomens after severe trauma. *J Trauma* 2003;55:1155–6.
13. Barker DE, Kaufman HJ, Smith LA, Ciraulo DL, Richart CL, Burns RP. Vacuum pack technique of temporary abdominal closure: a 7-year experience with 112 patients. *J Trauma* 2000;48:201–7.

### Address for Correspondence

Dr. Christian von Rden  
 Division of Trauma Surgery  
 Department of Surgery  
 University Hospital Zurich  
 Rmistrasse 100  
 8091 Zurich  
 Switzerland  
 Phone (+41/44) -2551111 Fax -2554406  
 e-mail: christian.vonrueden@usz.ch