



**University of
Zurich**^{UZH}

**Zurich Open Repository and
Archive**

University of Zurich
University Library
Strickhofstrasse 39
CH-8057 Zurich
www.zora.uzh.ch

Year: 2018

Pseudolymphomatous Reaction to Red Tattoo Pigment

Saulite, Ieva ; Pekar-Lukacs, Agnes ; Kerl, Katrin ; Cozzio, Antonio ; Hoetzenecker, Wolfram ; Guenova, Emmanuella

DOI: <https://doi.org/10.1159/000489875>

Posted at the Zurich Open Repository and Archive, University of Zurich

ZORA URL: <https://doi.org/10.5167/uzh-160780>

Journal Article

Published Version



The following work is licensed under a Creative Commons: Attribution-NonCommercial 4.0 International (CC BY-NC 4.0) License.

Originally published at:

Saulite, Ieva; Pekar-Lukacs, Agnes; Kerl, Katrin; Cozzio, Antonio; Hoetzenecker, Wolfram; Guenova, Emmanuella (2018). Pseudolymphomatous Reaction to Red Tattoo Pigment. *Case Reports in Dermatology*, 10(2):162-168.

DOI: <https://doi.org/10.1159/000489875>

Case and Review

Pseudolymphomatous Reaction to Red Tattoo Pigment

Ieva Saulite^{a, c} Agnes Pekar-Lukacs^b Katrin Kerl^c Antonio Cozzio^a
Wolfram Hoetzenecker^d Emmanuella Guenova^c

^aDepartment of Dermatology, Cantonal Hospital St. Gallen, St. Gallen, Switzerland;

^bDepartment of Oncology and Pathology, Lund University, Lund, Sweden; ^cDepartment of Dermatology, University Hospital Zurich, University of Zurich, Zurich, Switzerland;

^dDepartment of Dermatology, Kepler University Hospital, Linz, Austria

Keywords

Pseudolymphomatous reaction · Red tattoo · Azo dye

Abstract

Decorative tattooing is a procedure in which exogenous pigment and/or dye is introduced into the dermis with the aim of creating a permanent skin decoration. The increasing prevalence of tattooed individuals leads to more reported tattoo-related complications. Pseudolymphomatous reaction is a benign reactive proliferation of lymphocytes that may uncommonly occur secondary to tattooing. We describe the clinical, histological, and molecular aspects of a pseudolymphomatous reaction to red tattoo pigment.

© 2018 The Author(s)
Published by S. Karger AG, Basel

Case Report

A 33-year-old woman presented with an itchy, livid red massive infiltrated tumor, sharply demarcated and limited to the red part of her red-, black-, and green-colored tattoo 9 months after the tattooing procedure ([Fig. 1a](#)).

The histopathological examination of the lesion revealed pronounced pseudoepitheliomatous hyperplasia with spongiosis, and focal necrosis of the epidermis. In the dermis, there was an extensive and dense infiltration of small to medium-sized lymphocytes, that spanned the epidermis to the deep subcutis with focal epidermotropism and follicular tropism without large atypical cells. However, some large activated lymphocytes could be observed in the infiltrate. No germinal centers were identified. In addition, granular red pigment deposition and eosinophilic infiltration was noticed. The presence of exogenous pigment suggested the correct diagnosis (Fig. 2a).

Immunohistological staining of the skin biopsy (Fig. 2b) showed that the majority (>80%) of lymphocytes were CD3⁺, and approximately 50% of all CD3⁺ cells expressed CD4, and 50% expressed CD8 phenotypic markers. Less than 2% of the T cells were positive for CD30; a few CD20⁺ B cells could also be detected in the dermal infiltrate. Less than 5% of all cells expressed the proliferation marker Ki-67.

We detected no clonal rearrangement of the T cell receptor in the polymerase chain reaction (Fig. 3). The differential blood count and all other routine laboratory tests remained within the normal range.

Based on the typical clinical appearance and the pseudolymphomatous histological pattern, we diagnosed the patient with a tattoo-associated pseudolymphomatous reaction to red tattoo pigment.

We treated the lesions topically with mid-potency corticosteroid cream (betamethasone valerate) once daily 5 days a week for 6 weeks and every second day for 5 additional months. During treatment, we observed gradual regression of the tumors; complete remission of the lesions occurred after 6 months of treatment (Fig. 1b). No relapse occurred during a follow-up period of 3 years.

Discussion

Pseudolymphomatous reactions are a heterogeneous group of benign T- or B-cell-rich infiltrates which histologically and/or clinically mimic cutaneous lymphoma [1]. Rare cases in the literature report the development of pseudolymphomatous reactions induced by tattooing [2]. At least 30 cases have been reported, and in most cases, the pseudolymphomatous reaction was related to the intradermal injection of red tattoo pigment [3]. It has been suggested that particles in tattoo pigments could act as antigens in the dermal skin layer and induce lymphoid cell proliferation, which then leads to a persistent reactive lymphocytic infiltration. However, the exact mechanism of the pathogenesis of the pseudolymphoma has yet to be defined [4, 5].

Like in most of the previously reported tattoo-associated pseudolymphomatous reactions, we also observed mostly T cells in the pseudolymphomatous infiltrate.

Interestingly, in former reports, the pseudolymphomatous reactions were also mostly confined to the red areas of the tattoo [3, 6]. Tattoo ink often contains metal compounds. Historically for reddish pigments, mercury (cinnabar) was often applied and has been suggested to enhance immunogenicity [3]. Previously, most authors indicated mercury as the causative agent [4, 7, 8]. Currently, due to regulations of the Food and Drug Agency (FDA) and the European Agency for the Evaluation of Medicinal Products (EMA), mercury is prohibited and is

no longer of major relevance for the development of pseudolymphomatous and/or allergic tattoo reactions. Here, we reported a pseudolymphomatous reaction due to the synthetic azo dye (pigment red 210, C₂₀H₁₀Cl₂N₂O₂). We identified pigment red 201, C₂₀H₁₀Cl₂N₂O₂, as a causative agent according to the information about the composition of the applied tattoo ink provided by the tattoo ink label and the tattoo studio. As the tattoo studio could not provide any ink samples for the further in vitro workup (C₂₀H₁₀Cl₂N₂O₂-dependent T cell proliferation and activation testing), this information should be used with caution. Tattoo ink labelling may be incorrect, and we cannot completely exclude inclusion of additional substances, other than C₂₀H₁₀Cl₂N₂O₂ or even mercury in the red tattoo pigment used in this case.

Although spontaneous remission of pseudolymphomatous reactions have been reported [4], pseudolymphomas are often difficult to treat, and the therapeutic approach is controversial (Table 1). Treatment modalities include topical and intralesional application of glucocorticosteroids as well as surgical excision and laser therapy [7, 9–13]. Additionally, systemic therapy with hydroxychloroquine was effective in a case of tattoo-associated pseudolymphomatous reaction in the green part of the tattoo [8].

According to cases reported by other authors, surgical excision of the pseudolymphomatous reaction is the most effective treatment [7, 10, 11, 14–17]. However, surgery may result in poor cosmetic outcome and is applicable for small areas only, and therefore its use is limited. Sepehri et al. [18] have recently suggested dermatome shave as a cosmetically acceptable rationale treatment modality for chronic tattoo reactions, as demonstrated in large series. Further, laser as treatment option is very disputatious, as some authors claim lasers aggravate the contact allergic reaction due to photochemical aspects [13]. In most of the cases reported with tattoo-associated pseudolymphomatous reaction limited to the red part of the tattoo, treatment with topical or intralesional corticosteroids did not induce remission [5, 12, 19–22]. In our patient, the pseudolymphomatous lesions resolved completely under topical corticosteroids. Therefore, we suggest that in the case when the excision of the lesions may be limited due to the size of the lesions or cosmetic concerns, therapy with local corticosteroids may be tried in first line, despite the high recurrence rates reported in most cases [18]. For our patient, the duration of therapy with topical corticosteroids was considerably longer than in cases described by other authors. Hence, we propose that a longer duration of treatment might be sufficient to induce remission in some cases. The very low efficacy of topical corticosteroids reported in the literature might also be influenced by the fact that patients who responded to topical corticosteroids might be lost for follow-up and therefore not reported. It remains very controversial and purely speculative whether pseudolymphomatous reactions may rarely transform into malignant lymphoma [8, 23]. We and others would rather suggest considering the pseudolymphomatous reactions to tattoo pigment as severely exaggerated delayed-type hypersensitivity reactions [13].

The presented case highlights tattooing, particularly with red ink, as a risk factor for adverse immunological reactions such as cutaneous pseudolymphomatous reactions. These adverse tattooing-related reactions lead to both diagnostic and treatment challenges.

Statement of Ethics

The study was conducted in accordance with the principles of the Declaration of Helsinki. The patient provided her written informed consent.

Disclosure Statement

The authors declare that they have no conflicts of interest.

Funding Sources

This project was supported by the Forschungskredit of the University of Zurich (FK-15-040), the Jubiläumsstiftung von SwissLife, the Promedica Stiftung (1406/M and 1412/M), one further Foundation and the Krebsliga Schweiz (KFS-4243-08-2017). The funders had no role in study design, data collection and analysis, decision to publish, or preparation of the manuscript.

References

- Mitteldorf C, Kempf W. Cutaneous Pseudolymphoma. *Surg Pathol Clin*. 2017 Jun;10(2):455–76.
- Serup J. Atlas of Illustrative Cases of Tattoo Complications. *Curr Probl Dermatol*. 2017;52:139–229.
- Forbat E, Al-Niaimi F. Patterns of Reactions to Red Pigment Tattoo and Treatment Methods. *Dermatol Ther (Heidelb)*. 2016 Mar;6(1):13–23.
- Gutermuth J, Hein R, Fend F, Ring J, Jakob T. Cutaneous pseudolymphoma arising after tattoo placement. *J Eur Acad Dermatol Venereol*. 2007 Apr;21(4):566–7.
- Kahofer P, El Shabrawi-Caelen L, Horn M, Kern T, Smolle J. Pseudolymphoma occurring in a tattoo. *Eur J Dermatol*. 2003 Mar-Apr;13(2):209–12.
- Mortimer NJ, Chave TA, Johnston GA. Red tattoo reactions. *Clin Exp Dermatol*. 2003 Sep;28(5):508–10.
- Marchesi A, Parodi PC, Brioschi M, Marchesi M, Bruni B, Cangì MG et al. Tattoo ink-related cutaneous pseudolymphoma: a rare but significant complication. Case report and review of the literature. *Aesthetic Plast Surg*. 2014 Apr;38(2):471–8.
- Patrizi A, Raone B, Savoia F, Bacci F, Pileri A, Gurioli C et al. Tattoo-associated pseudolymphomatous reaction and its successful treatment with hydroxychloroquine. *Acta Derm Venereol*. 2009;89(3):327–8.
- Shin JB, Seo SH, Kim BK, Kim IH, Son SW. Cutaneous T cell pseudolymphoma at the site of a semipermanent lip-liner tattoo. *Dermatology*. 2009;218(1):75–8.
- Tan LS, Oon HH, Lee JS, Chua SH. Successful Treatment of Tattoo-Induced Pseudolymphoma with Sequential Ablative Fractional Resurfacing Followed by Q-Switched Nd: YAG 532 nm Laser. *J Cutan Aesthet Surg*. 2013 Oct;6(4):226–8.
- King BJ, Lehman JS, Macon WR, Sciallis GF. Red tattoo-related mycosis fungoides-like CD8+ pseudolymphoma. *J Cutan Pathol*. 2018 Mar;45(3):226–228.
- Zinberg M, Heilman E, Glickman F. Cutaneous pseudolymphoma resulting from a tattoo. *J Dermatol Surg Oncol*. 1982 Nov;8(11):955–8.
- Serup J, Bäumlér W. Guide to Treatment of Tattoo Complications and Tattoo Removal. *Curr Probl Dermatol*. 2017;52:132–8.
- Muñoz C, Guilabert A, Mascaró JM Jr, Lopez-Lerma I, Vilaplana J. An embossed tattoo. *Clin Exp Dermatol*. 2006 Mar;31(2):309–10.
- Jaehn T, Kaiser A, Gruneis C, Saalabian AA, Reichert B. [Pseudolymphatic allergic immune reaction after tattooing] [Article in German]. *Handchir Mikrochir Plast Chir*. 2014 Dec;46(6):379–82.

- 16 Kuo WE, Richwine EE, Sheehan DJ. Pseudolymphomatous and lichenoid reaction to a red tattoo: a case report. *Cutis*. 2011 Feb;87(2):89–92.
- 17 Camilot D, Arnez ZM, Luzar B, Pizem J, Zgavec B, Falconieri G. Cutaneous pseudolymphoma following tattoo application: report of two new cases of a potential lymphoma mimicker. *Int J Surg Pathol*. 2012 Jun;20(3):311–5.
- 18 Sepehri M, Jørgensen B, Serup J. Introduction of dermatome shaving as first line treatment of chronic tattoo reactions. *J Dermatolog Treat*. 2015 Oct;26(5):451–5.
- 19 Cruz FA, Lage D, Frigério RM, Zaniboni MC, Arruda LH. Reactions to the different pigments in tattoos: a report of two cases. *An Bras Dermatol*. 2010 Sep-Oct;85(5):708–11.
- 20 Malki S, Onnis G, Lissia A, Montesu MA, Satta R. Cutaneous T pseudolymphoma on the red pigmented areas of a tattoo. *Int J Dermatol*. 2017 Aug;56(8):e172–3.
- 21 Cristaudo A, Forte G, Bocca B, Petrucci F, Muscardin L, Trento E et al. Permanent tattoos: evidence of pseudolymphoma in three patients and metal composition of the dyes. *Eur J Dermatol*. 2012 Nov-Dec;22(6):776–80.
- 22 Pasolini G, Ghidini P, Arisi M, Pedretti A, Ungari M, Pinton PC. Pseudolymphoma tattoo-induced. *Dermatol Rep*. 2011 Nov;3(3):e47.
- 23 Sangueza OP, Yadav S, White CR Jr, Braziel RM. Evolution of B-cell lymphoma from pseudolymphoma. A multidisciplinary approach using histology, immunohistochemistry, and Southern blot analysis. *Am J Dermatopathol*. 1992 Oct;14(5):408–13.

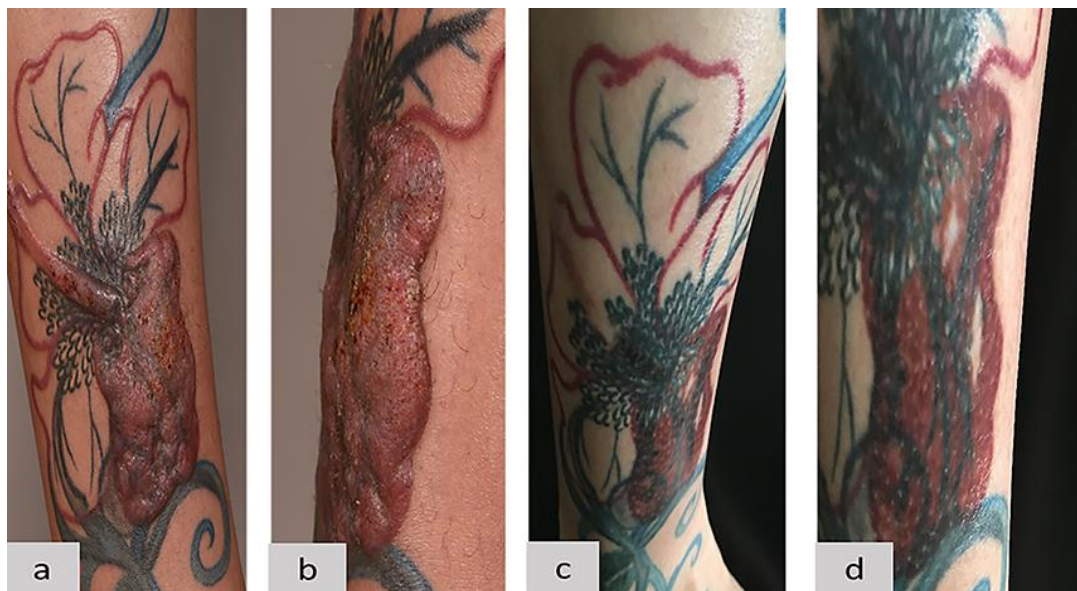

Fig. 1. Clinical images of the pseudolymphomatous reaction on the patient's right lower extremity within a red part of her tattoo. **a, b** A red massive infiltrated tumor sharply demarcated and limited within the red part of her red-, black-, and green-colored tattoo 9 months after the tattooing procedure. **c, d** Complete resolution of the pseudolymphomatous reaction 2 years after the initial 6-month treatment with topical corticosteroids.

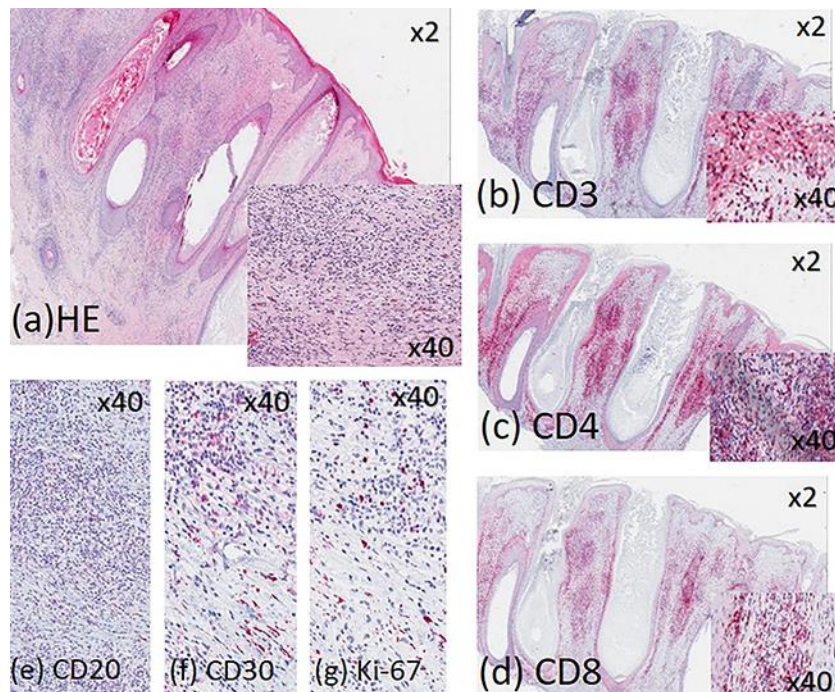


Fig. 2. Histopathological and immunohistochemical analyses of a skin biopsy from the red infiltrated part of the tattoo on the patient's right lower leg. **a** Hematoxylin and eosin (HE): pseudolymphomatous reaction. The insert shows the exogenous red pigment. **b** CD3 staining: approximately >80% of infiltrate positive. **c** CD4 staining: approximately 50% of infiltrate positive. **d** CD8 staining: approximately 50% of infiltrate positive. **e** CD30 staining: <2% of infiltrate positive. **f** CD20 staining: few positive cells. **g** Ki-67 staining: <5% of infiltrate positive. The inserts on pictures **b–d** represent the higher magnification of a given immunohistological staining.

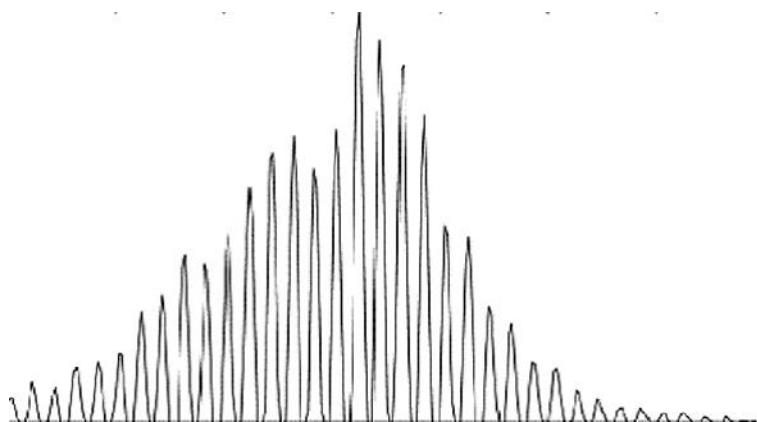


Fig. 3. Polymerase chain reaction of T cell receptors detected no T cell clonality.

Table 1. Treatment outcome in patients with pseudolymphomatous reaction to red pigment tattoo (PubMed)

First author [Ref.], year	Sex	Age, years	Time of onset, years	Therapy	Outcome
Muñoz [14], 2006	M	36	–	Surgical	Complete remission
Jaehn [15], 2014	F	30	0.5	Surgical	Complete remission
Kuo [16], 2011	W	40	20	Surgical	Complete remission
Marchesi [7], 2012	M	35	0.5	Surgical	Complete resolution
Kahofer [5], 2003	F	34	6	Topical corticosteroids	No remission
				Surgical	Complete remission
Camilot [17], 2012	F	39	0.4	Surgical	No follow-up
Camilot [17], 2012	M	46	0.3	Surgical	No follow-up
King [11], 2018	M	46	0.15	Surgical	Complete resolution
			4	Intralesional steroids	Complete remission after 1.4 years
Shin [9], 2009	F	46	1	Pulsed dye laser	No remission
				Intralesional corticosteroids	Recurrence
Zinberg [12], 1982	M	28		Intralesional corticosteroids	Recurrence
Cruz [19], 2010	M	30	1	Very potent topical corticosteroids	No remission
Malki [20], 2017	M	38	2	Medium-potency corticosteroids	No remission
Cristaudo [21], 2012	W	32	1	Very potent topical corticosteroids	No remission
Cristaudo [21], 2012	W	36	1.25	Very potent topical corticosteroids	No remission
Cristaudo [21], 2012	M	49	2	Very potent topical corticosteroids	No remission
Pasolini [22], 2011	M	34	0.15	Very potent topical corticosteroids	No remission
Tan [10], 2013	F	45	0.3	Potent topical and intralesional corticosteroids	No remission
				Ablative fractional resurfacing followed by Q-Switched Nd:YAG 532-nm laser	Complete remission
Gutermuth [4], 2007	M	57	0.5	No	Complete remission in 3 years