



**University of
Zurich**^{UZH}

**Zurich Open Repository and
Archive**

University of Zurich
University Library
Strickhofstrasse 39
CH-8057 Zurich
www.zora.uzh.ch

Year: 2019

Systemic inflammatory response after Hyperthermic Intraperitoneal Hemotherapy (HIPEC): the perfusion protocol matters!

Roth, Lilian ; Eshmuminov, Dilmurodjon ; Laminger, Felix ; Koppitsch, Claudia ; Schneider, Marcel ; Graf, Theresia Reding ; Gupta, Anurag ; Kober, Fritz ; Roka, Sebastian ; Gertsch, Philippe ; Lehmann, Kuno

DOI: <https://doi.org/10.1016/j.ejso.2019.03.036>

Posted at the Zurich Open Repository and Archive, University of Zurich

ZORA URL: <https://doi.org/10.5167/uzh-183557>

Journal Article

Accepted Version

Originally published at:

Roth, Lilian; Eshmuminov, Dilmurodjon; Laminger, Felix; Koppitsch, Claudia; Schneider, Marcel; Graf, Theresia Reding; Gupta, Anurag; Kober, Fritz; Roka, Sebastian; Gertsch, Philippe; Lehmann, Kuno (2019). Systemic inflammatory response after Hyperthermic Intraperitoneal Hemotherapy (HIPEC): the perfusion protocol matters! *European Journal of Surgical Oncology*, 45(9):1734-1739.

DOI: <https://doi.org/10.1016/j.ejso.2019.03.036>

Accepted Manuscript

Systemic inflammatory response after hyperthermic intraperitoneal chemotherapy (HIPEC): The perfusion protocol matters!

Lilian Roth, Dilmurodjon Eshmuminov, Felix Laminger, Claudia Koppitsch, Marcel Schneider, Theresia Reding Graf, Anurag Gupta, Fritz Kober, Sebastian Roka, Philippe Gertsch, Kuno Lehmann

PII: S0748-7983(19)30381-6

DOI: <https://doi.org/10.1016/j.ejso.2019.03.036>

Reference: YEJSO 5312

To appear in: *European Journal of Surgical Oncology*


Received Date: 24 February 2019

Revised Date: 17 March 2019

Accepted Date: 26 March 2019

Please cite this article as: Roth L, Eshmuminov D, Laminger F, Koppitsch C, Schneider M, Graf TR, Gupta A, Kober F, Roka S, Gertsch P, Lehmann K, Systemic inflammatory response after hyperthermic intraperitoneal chemotherapy (HIPEC): The perfusion protocol matters!, *European Journal of Surgical Oncology* (2019), doi: <https://doi.org/10.1016/j.ejso.2019.03.036>.

This is a PDF file of an unedited manuscript that has been accepted for publication. As a service to our customers we are providing this early version of the manuscript. The manuscript will undergo copyediting, typesetting, and review of the resulting proof before it is published in its final form. Please note that during the production process errors may be discovered which could affect the content, and all legal disclaimers that apply to the journal pertain.



**SYSTEMIC INFLAMMATORY RESPONSE AFTER HYPERTHERMIC
INTRAPERITONEAL CHEMOTHERAPY (HIPEC): THE PERFUSION
PROTOCOL MATTERS!**

Lilian Roth, MD^{1*} & ^{1*}Dilmurodjon Eshmuminov, MD^{1*}, Felix Laminger², Claudia Koppitsch², Marcel Schneider, MD¹, Theresia Reding Graf, PhD¹, Anurag Gupta, PhD¹, Fritz Kober, MD², Sebastian Roka, MD², Philippe Gertsch, MD¹, and Kuno Lehmann, MD PhD¹

* L.R. and D.E. contributed equally

¹*Surgical Oncology Research Laboratory, Department of Surgery & Transplantation, University Hospital of Zurich, Zurich, Switzerland*

²*Department of Surgery, Center for Peritoneal Carcinomatosis, Hanusch-Krankenhaus, Vienna, Austria*

Corresponding Author:

Prof. Dr. Kuno Lehmann, MD PhD

Surgical Oncology Research Laboratory

Department of Surgery and Transplantation

UniversityHospital Zurich

Raemistrasse 100

CH-8091 Zurich, Switzerland

Phone: +41 44 255 33 00

Fax: +41 44 255 44 49

Mail: kuno.lehmann@usz.ch

Short Title for Running Head:

Prolonged HIPEC triggers a systemic inflammatory response

Conflicts of interest:

The authors declared no conflict of interest. No third-party financial funds or materials were accepted or necessary for execution of this research project.

Keywords:

Cytoreductive Surgery (CRS)

Hyperthermic Intraperitoneal Chemotherapy (HIPEC)

Peritoneal Metastasis

ABBREVIATIONS

CRS	Cytoreductive surgery
HIPEC	Hyperthermic intraperitoneal chemotherapy
PCI	Peritoneal cancer index
CC-Score	Completeness of cytoreduction score
CRC	Colorectal carcinoma
CRP	C-reactive protein
PSP	Pancreatic stone protein
WBC	White blood cells

ABSTRACT

Background: CRS/HIPEC gained acceptance as a treatment for selected patients with peritoneal metastasis. However, the pathophysiology behind HIPEC is poorly understood, and a variety of regimens are currently in use. In this study, we describe for the first-time changes in the postoperative systemic inflammatory reaction, highly different among HIPEC treatment protocols.

Methods: HIPEC was performed with three protocols, different with regard to perfusion times and drugs: (mitomycinC/doxorubicin, 90min), (cisplatin, 90min) (oxaliplatin, 30min). Serial blood samples were assessed for C-reactive protein (CRP), white blood cells (WBC), pancreatic stone protein (PSP) and bacterial component (16s rDNA). The study was approved by the local ethics committee and registered at clinicaltrials.gov (NCT02741167).

Results: Overall, 140 patients from two European centers were included. In patients without postoperative complications, a secondary peak of inflammatory parameters, CRP ($p=0.015$) and PSP ($p=0.004$) was observed after HIPEC for 90 minutes with mitomycinC/doxorubicin or cisplatin but not after 30 minutes oxaliplatin. In patients after 90 minutes HIPEC, postoperative serum bacterial 16srDNA level were 2.1 times higher (95% CI 0.646-3.032, $p=0.015$) compared to 30 minutes oxaliplatin.

Discussion: In conclusion, we identified a secondary inflammatory reaction after 90 minutes HIPEC, either with mitomycinC/doxorubicin or cisplatin, not observed after short course HIPEC with oxaliplatin. This protocol dependent physiology of acute phase proteins should be known in the clinical management of patients after HIPEC.

Introduction

Peritoneal metastasis (PM) occurs from many gastrointestinal tumors, e.g. colorectal cancer or appendix cancer, and has an inferior prognosis than metastasis to the liver or lungs [1]. Cytoreductive surgery (CRS) and hyperthermic intraperitoneal chemotherapy (HIPEC), together with multimodal systemic treatment, has become a valuable option for selected patients [2-4] translating into considerable survival benefits [5, 6]. There is good *in-vitro* data about cytotoxic effects of HIPEC on cultured colorectal cancer cells [7], and data in humans show favorable pharmacokinetic effects for HIPEC. In contrast, specific effects of HIPEC on patient physiology and the postoperative course are poorly explored. In addition, existing HIPEC protocols differ with regard to drugs, temperatures and treatment duration. For example, in patients with colorectal PM, distinct HIPEC protocols are currently in use. One protocol, initially developed by Sugarbaker et al, is mitomycinC-based, and used for 90 minutes at 42°C, currently preferred by many US centers [8], while a majority of European centers use a shorter protocol for 30 minutes at 43°C which is oxaliplatin-based, and was originally published by French groups [9]. So far, no difference regarding overall survival between the two protocols has been shown in retrospective studies [10], and the choice for a specific protocol is center dependent. Currently, the main argument for the majority of surgeons preferring the French protocol is the shorter perfusion time compared to the US protocol. Many other protocols exist, for example with cisplatin, which is frequently applied during 90 minutes at 42°C and used for PM from ovarian cancer or peritoneal mesothelioma. Cisplatin is an alkylating agent like oxaliplatin, while the perfusion time and the applied temperature is similar to the mitomycin C protocol.

CRS/HIPEC induces complex physiological changes in patients, particularly during the operation and in the early postoperative phase [11]. During HIPEC, absorption of chemotherapeutic agents may systemically affect WBC counts [12-14]. In addition, local heat exposure and chemotherapy can induce direct toxic damage to abdominal organs with so far unknown effects on a patient's physiology [15]. This knowledge about HIPEC is currently not available but may help to improve efficacy without increasing risks of HIPEC in the near future. Here, we aimed to assess the systemic inflammatory response in patients after CRS/HIPEC without postoperative complications.

Material and Methods

Patients & Ethics

Patients from two centers (Zurich, Switzerland, and Vienna, Austria) treated with CRS/HIPEC for malignant gastrointestinal tumors between 2009 and 2017 were included in this study. Patient data were collected retrospectively (n=42) between 2009 and 2015, and within a prospective protocol (n=98) between 2015 and 2017. The study protocol was approved by the ethical committee and registered at clinicaltrials.gov (NCT02741167).

Treatment

Patients were discussed at interdisciplinary tumor boards after exclusion of extra-abdominal tumor manifestations by 18FDG-PET/CT or thoracic-abdominal CT. Patients received standard of care pre- and postoperative chemotherapy according to tumor entity and international guidelines. Anesthesia was conducted with propofol and volatile anesthetics combined with thoracic epidural anesthesia as described previously[11]. CRS was performed according to international standards and defined as radical (CC-Score 0) if no macroscopic residual tumor was visible [16]. HIPEC for appendix and colorectal tumors was performed using peritoneal dialysis solution for mitomycinC (30mg/m² body surface area, BSA according to the Mosteller formula) in combination with doxorubicin (15mg/m² BSA) for 42°C for 90 minutes, or oxaliplatin (300-400mgm² BSA) as single agent at 43°C for 30 minutes. The type of protocol used for appendix or colon cancer was changed in both centers in 2016 from the mitomycinC/doxorubicin protocol to the oxaliplatin protocol, which was then consistently used for these primary tumors. Patients with mesothelioma or ovarian cancer were treated with cisplatin-based HIPEC (75mg/m² BSA) for 90 minutes at 42°C.

Clinical parameters

Patients after CRS/HIPEC were visited daily by the operating surgeon according to standard clinical routine. In case of clinical symptoms or signs of infection, blood, urine and central catheters tips (jugular or subclavian) were taken for cultures. Imaging studies, usually an abdominal CT, were performed if CRP levels increased >30% after postoperative day 4. Complications were graded

according to the Clavien-Dindo classification[17], while infectious complications were defined according to the Center for Disease Control and Prevention (CDC) definitions [18].

Serum probes

C-reactive protein (CRP), white blood cell (WBC) counts, pancreatic stone protein (PSP) were measured in blood samples by the clinical laboratory service on a daily routine basis prior to surgery and for the 14 consecutive postoperative days[19]. PSP was measured from frozen serum samples with enzyme-linked immunosorbent assays (ELISA) as previously reported.[20] DNA was extracted from fresh frozen serum samples using the DNeasy Blood and Tissue Kit (Qiagen). Quantitative polymerase chain reaction (qPCR) with TaqMan (Pa04230899_s1) was performed to assess bacterial components (16srDNA)[21].

Statistical analysis

Continuous variables were compared with the student t-test, the Mann–Whitney U or the Wilcoxon test, where appropriate. Fischer's Exact tests was used to compare differences among proportions derived from categorical data. Normally distributed data are shown as mean +/- SD, non-normal variables as median and interquartile range (IQR). Missing values in the dataset were excluded. All p values were two-sided and considered statistically significant if $p \leq 0.05$. Statistical analysis was performed using SPSS version 25 and GraphPad Prism version 7.0.

Results

Demographic data

Overall, n=140 patients (n= 91 from Zurich, n=49 from Vienna) were included in the analysis. Patient characteristics are summarized in **Table 1**. Patients after HIPEC with oxaliplatin (n=44) were compared to patients after HIPEC with mitomycinC/doxorubicin (n=53) or cisplatin-based protocol (n=43). The mitomycinC/doxorubicin protocol and the oxaliplatin protocol were applied to similar types of primary tumors. Cisplatin-based HIPEC was primarily performed for mesothelioma or ovarian cancer. Detailed patient characteristics and differences between the treatment groups are summarized in **supplementary table 1**.

Prolonged HIPEC with mitomycinC/doxorubicin or cisplatin induces an unspecific secondary C-reactive protein peak

We expected to find a similar level of postoperative inflammation among protocols in patients without postoperative complications, However, in patients after CRS/HIPEC without any complication, we identified an unspecific secondary increase of CRP after HIPEC with mitomycinC/doxorubicin or cisplatin at 42°C for 90 minutes. This CRP increase was significant for mitomycinC/doxorubicin ($p=0.015$), and cisplatin ($p=0.026$) (**Figure 1A, 1B**). This effect was not observed in patients undergoing 30 minutes HIPEC with oxaliplatin at 43°C, where CRP levels gradually declined and returned to almost normal reference values within the first 14 postoperative days (**Figure 1C**).

Pancreatic stone protein confirms the presence of an inflammatory trigger

Pancreatic stone protein (PSP) is an acute phase protein produced in the pancreas after a septic stimulus[22]. Serum levels of pancreatic stone protein (PSP) dramatically increased in patients after HIPEC with the mitomycinC/doxorubicin protocol ($p=0.004$) and cisplatin-based HIPEC ($p=0.031$) between day 2 and 6, in contrast to patients after HIPEC with the oxaliplatin protocol, where no increase was observed (**Figure 2A - C**). The secondary rise of CRP (generated in the liver) and PSP (produced in the pancreas upon inflammation) suggest a triggering source from the gastrointestinal tract.

Bacterial components identified as a potential triggering source of inflammation

To explore the trigger of this secondary inflammatory reaction, we analyzed fresh frozen serum samples for the presence of bacterial components. Bacterial 16srDNA levels from patients with septic complications served as positive controls. The relative amount of bacterial DNA (16s rDNA) was 2.1 times higher (95% CI 0.646-3.032, $p=0.015$) in patients after HIPEC with the mitomycinC/doxorubicin protocol compared to the oxaliplatin protocol (**Figure 3**). In line with this finding, the relative bacterial components were 2.5 times higher (95% CI 0.567-4.85, $p=0.015$) after the treatment with the cisplatin-based protocol compared to the oxaliplatin protocol, suggesting prolonged perfusion times as the triggering factor.

White blood cells (WBC) increases after platin-based HIPEC

Median WBC counts remained within a normal range of 5-10 G/l among all three HIPEC regimens. However, a secondary WBC increase could be observed between day 4 and 7 after platin-based HIPEC (Figure 4B, 4C) treatment in patients without any complications. WBC did not change after mitomycinC/doxorubicin HIPEC treatment, even though these patient population showed a secondary CRP increase.

Discussion

Our study identifies novel findings related to the pathophysiology of acute phase proteins in patients after HIPEC. For the first time, we describe a secondary inflammatory reaction, associated to the presence of bacterial components in the systemic circulation after CRS/HIPEC. The data provides insight into the human pathophysiology after HIPEC which is necessary to understand the physiology and manage the postoperative course. In the future, it will help to direct future modifications of the HIPEC procedure.

Our finding of an unspecific secondary inflammation phase after HIPEC was unexpected. First, we thought about an influence of major surgery or the postoperative management, but a comparison with open colorectal and open gastroesophageal surgery (data not shown) highlighted an impact of HIPEC itself. To our surprise this secondary inflammatory peak was also not observed after HIPEC with oxaliplatin. Since these patients shared surgical characteristics of patients after HIPEC with mitomycinC/doxorubicin, we could exclude a potential role of the cytoreduction part or the perioperative management (e.g. parenteral nutrition, epidural anesthesia, intraabdominal drainage, central vein lines) as an additional source of inflammation. In our study, patients after 90 minutes HIPEC with mitomycinC/doxorubicin or cisplatin showed a secondary CRP peak, simultaneously with a marked elevation of PSP, and the presence of bacterial ribosomal DNA in the patient serum. Although difficult to prove in the human setting, this finding is suggestive of intestinal bacterial translocation. Support for this hypothesis comes from rat experiments, where increased bacterial components were identified in mesenteric lymph nodes on the third postoperative day after HIPEC [23]. Whether translocation occurred because of direct damage to the intestinal mucosa or due to decreased host defense remains so far unclear. To address the question whether different drugs or longer perfusion times are responsible, we compared a cisplatin-based protocol with the mitomycinC/doxorubicin and oxaliplatin protocol. Cisplatin is a compound similar to oxaliplatin but is usually performed at conditions similar to the mitomycinC/doxorubicin protocol (42°C, 90 minutes). Finally, after prolonged perfusion with cisplatin, we also observed a secondary inflammatory peak, indicating that prolonged exposure time to HIPEC might be the critical factor. This observation is similar to a report from Spain, where this observation was not reported but the data and figures indicate the same kinetics for CRP after a paclitaxel-based HIPEC protocol for 60 min at 42°C in absence of postoperative complications [24].

A justified question is the clinical relevance of our finding. Indeed, we did not observe a clinically relevant overall difference regarding postoperative complications between the different protocols. However, the ratio of deep organ space (CDC definition) infections was higher after HIPEC with mitomycinC/doxorubicin compared to oxaliplatin (30% vs 11%, $p=0.028$), and two patients in this protocol group had postoperative peritonitis without an underlying digestive fistula, and observation also made by others [25]. This may indicate that, although a rare event, bacterial translocation may contribute to adverse postoperative outcomes. Another question is whether HIPEC with oxaliplatin is still relevant after the results of PRODIGE7, since most centers may have changed to other protocols. Indeed, the goal of the present study is not to show a benefit of one over another protocol. Our data just highlights that protocol parameters, particularly temperature and duration, may significantly impact on the pathophysiology of our patients.

There is, however, another clinical value of these findings. When we initialized the study, we did not know about a potential increase in acute phase proteins in absence of complications after prolonged perfusion. Consequently, our patients regularly underwent a complex postoperative work-up including CT scans, and sometimes surgical reexploration, without revealing any infectious focus. This finding urged us to investigate the pathophysiology behind the secondary increase and we started measuring markers such as PSP and 16sDNA. Our findings finally highlight the complexity of HIPEC and underline the need for a dedicated and specialized team, not only for the procedure itself but also in the postoperative management and the interpretation of the clinical status of a patient after CRS/HIPEC. Based on our data, we learned that, while a secondary inflammatory reaction can occur after prolonged (90 minutes) HIPEC protocols, it was almost never observed after a short, 30 minutes protocol.

CRS/HIPEC treatment improves survival of patients with peritoneal metastasis. However, a majority of patients still has recurrent disease within the first two years [26], and future improvements of HIPEC are therefore needed. Today, parameters of HIPEC including drugs, perfusion time and temperatures are determined empirically, resulting in a huge variation, and major difficulty to compare and identify the role of a specific component. In addition, data from animal experiments may not be transferable to the human situation. A better understanding of molecular mechanisms, and the human pathophysiology of HIPEC is therefore required to intensify and improve existing protocols without increasing perioperative complications. Based on our findings we suggest that expanding perfusion

times of HIPEC should include a monitoring of acute phase proteins, and probably also parameters to exclude increased intestinal translocation.

Another open question is the long-term impact of systemic inflammation after CRS/HIPEC. The role of postoperative inflammation and infection on patient survival is controversially discussed in the literature, and there is data showing a negative impact on patient outcomes, while other studies show no impact on survival [27, 28]. The relevance of our present finding, inflammation in patients without complications, regarding patient survival is yet unclear, and would open another door to a molecular understanding of HIPEC.

An interesting finding in our study is the kinetics of WBC during the postoperative course of patients without a complication. Although, WBC values remained within normal range, we observed changes after platin-based HIPEC. Expecting a secondary increase after prolonged HIPEC treatment, we only detected an increase in patients after cisplatin-based HIPEC, which suggests a myelodepressive effect of mitomycinC/doxorubicin[29]. WBC also increased after oxaliplatin-based HIPEC, even though CRP values decreased in a linear manner almost to normal, indicating that a minimal bacterial translocation probably also occurs after oxaliplatin-based HIPEC, indicated also by the small quantity of bacterial components in the systemic circulation. Regarding the diagnostic workup of patients after CRS/HIPEC we would like to highlight a study published in 2016 which assessed the role of procalcitonin in the early postoperative phase after CRS/HIPEC. This study concluded that procalcitonin may improve the diagnosis of postoperative infection, but needs careful interpretation within the clinical context, similar to CRP and white-cell counts [30].

We would like to acknowledge the limitations of our study. The cohort of patients is heterogeneous regarding the type of primary tumors. However, treatment associated surgical factors are comparable among the three groups which will limit this bias. Finally, we acknowledge that the observed association of bacterial components in the bloodstream to systemic inflammation is not a mechanistic proof of intestinal translocation. This hypothesis is difficult to investigate and proof in humans, and animal experiments may finally be required. Overall, in the majority of patients, this effect did not result in a more complicated course. However, it indicates a critical mechanistic step in the pathophysiology of HIPEC and may explain the rare finding of peritonitis without a cause, sometimes observed in patients after HIPEC [25].

In conclusion, we identified novel aspects in physiologic changes after CRS/HIPEC, a secondary inflammatory reaction in patients after 90 minutes perfusion with HIPEC, associated to bacterial components in the systemic circulation. These protocol-specific effects after HIPEC should be known to physicians dedicated to the treatment of peritoneal surface malignancies for a better understanding of a patient's physiology. In future, they may help to direct the next evolution of technical refinements in perfusion protocols.

References

1. Franko J, Shi Q, Meyers JP, et al. Prognosis of patients with peritoneal metastatic colorectal cancer given systemic therapy: an analysis of individual patient data from prospective randomised trials from the Analysis and Research in Cancers of the Digestive System (ARCAD) database. *Lancet Oncol* 2016;17:1709-19.
2. Glehen O, Mohamed F and Gilly FN. Peritoneal carcinomatosis from digestive tract cancer: new management by cytoreductive surgery and intraperitoneal chemohyperthermia. *The lancet oncology* 2004;5:219-28.
3. Sugarbaker PH. New standard of care for appendiceal epithelial neoplasms and pseudomyxoma peritonei syndrome? *The lancet oncology* 2006;7:69-76.
4. Yan TD, Welch L, Black D and Sugarbaker PH. A systematic review on the efficacy of cytoreductive surgery combined with perioperative intraperitoneal chemotherapy for diffuse malignancy peritoneal mesothelioma. *Annals of oncology : official journal of the European Society for Medical Oncology / ESMO* 2007;18:827-34.
5. Elias D, Gilly F, Boutitie F, et al. Peritoneal colorectal carcinomatosis treated with surgery and perioperative intraperitoneal chemotherapy: retrospective analysis of 523 patients from a multicentric French study. *J Clin Oncol* 2010;28:63-8.
6. Verwaal VJ, van Ruth S, de Bree E, et al. Randomized trial of cytoreduction and hyperthermic intraperitoneal chemotherapy versus systemic chemotherapy and palliative surgery in patients with peritoneal carcinomatosis of colorectal cancer. *J Clin Oncol* 2003;21:3737-43.
7. Lehmann K, Rickenbacher A, Jang J-H, et al. New Insight Into Hyperthermic Intraperitoneal Chemotherapy Induction of Oxidative Stress Dramatically Enhanced Tumor Killing in In Vitro and In Vivo Models. *Annals of Surgery* 2012;256:730-8.
8. Turaga K, Levine E, Barone R, et al. Consensus guidelines from The American Society of Peritoneal Surface Malignancies on standardizing the delivery of hyperthermic intraperitoneal chemotherapy (HIPEC) in colorectal cancer patients in the United States. *Ann Surg Oncol* 2014;21:1501-5.
9. Elias D, Lefevre JH, Chevalier J, et al. Complete cytoreductive surgery plus intraperitoneal chemohyperthermia with oxaliplatin for peritoneal carcinomatosis of colorectal origin. *J Clin Oncol* 2009;27:681-5.
10. Prada-Villaverde A, Esquivel J, Lowy AM, et al. The American Society of Peritoneal Surface Malignancies evaluation of HIPEC with Mitomycin C versus Oxaliplatin in 539 patients with colon cancer undergoing a complete cytoreductive surgery. *J Surg Oncol* 2014;110:779-85.
11. Kajdi ME, Beck-Schimmer B, Held U, et al. Anaesthesia in patients undergoing cytoreductive surgery with hyperthermic intraperitoneal chemotherapy: retrospective analysis of a single centre three-year experience. *World journal of surgical oncology* 2014;12:136.
12. Hartmann JT and Lipp HP. Toxicity of platinum compounds. Expert opinion on pharmacotherapy 2003;4:889-901.
13. Rafiyath SM, Rasul M, Lee B, et al. Comparison of safety and toxicity of liposomal doxorubicin vs. conventional anthracyclines: a meta-analysis. *Experimental hematology & oncology* 2012;1:10.
14. Votanopoulos K, Ithemelandu C, Shen P, et al. A comparison of hematologic toxicity profiles after heated intraperitoneal chemotherapy with oxaliplatin and mitomycin C. *J Surg Res* 2013;179:e133-9.
15. Ceelen WP and Flessner MF. Intraperitoneal therapy for peritoneal tumors: biophysics and clinical evidence. *Nat Rev Clin Oncol* 2010;7:108-15.
16. Sugarbaker PH. Intraperitoneal chemotherapy and cytoreductive surgery for the prevention and treatment of peritoneal carcinomatosis and sarcomatosis. *Semin Surg Oncol* 1998;14:254-61.
17. Dindo D, Demartines N and Clavien PA. Classification of surgical complications: a new proposal with evaluation in a cohort of 6336 patients and results of a survey. *Ann Surg* 2004;240:205-13.
18. Mangram AJ, Horan TC, Pearson ML, Silver LC and Jarvis WR. Guideline for Prevention of Surgical Site Infection, 1999. Centers for Disease Control and Prevention (CDC) Hospital Infection

Control Practices Advisory Committee. American journal of infection control 1999;27:97-132; quiz 3-4; discussion 96.

19. Lehmann K, Eshmuminov D, Slankamenac K, et al. Where Oncologic and Surgical Complication Scoring Systems Collide: Time for a New Consensus for CRS/HIPEC. *World J Surg* 2016;40:1075-81.
20. Reding T, Palmiere C, Pazhepurackel C, et al. The pancreas responds to remote damage and systemic stress by secretion of the pancreatic secretory proteins PSP/regI and PAP/regIII. *Oncotarget* 2017;8:30162-74.
21. Jiang W, Lederman MM, Hunt P, et al. Plasma levels of bacterial DNA correlate with immune activation and the magnitude of immune restoration in persons with antiretroviral-treated HIV infection. *J Infect Dis* 2009;199:1177-85.
22. Fisher OM, Oberkofler CE, Raptis DA, et al. Pancreatic stone protein (PSP) and pancreatitis-associated protein (PAP): a protocol of a cohort study on the diagnostic efficacy and prognostic value of PSP and PAP as postoperative markers of septic complications in patients undergoing abdominal surgery (PSP study). *BMJ Open* 2014;4:e004914.
23. Bozer M, Turkcapar N, Bayar S and Kocaoglu H. Intraperitoneal hyperthermic perfusion may induce bacterial translocation. *Hepato-gastroenterology* 2005;52:111-4.
24. Medina Fernandez FJ, Munoz-Casares FC, Arjona-Sanchez A, et al. Postoperative time course and utility of inflammatory markers in patients with ovarian peritoneal carcinomatosis treated with neoadjuvant chemotherapy, cytoreductive surgery, and HIPEC. *Ann Surg Oncol* 2015;22:1332-40.
25. Honore C, Sourrouille I, Suria S, et al. Postoperative peritonitis without an underlying digestive fistula after complete cytoreductive surgery plus HIPEC. *Saudi J Gastroenterol* 2013;19:271-7.
26. Schneider MA, Eshmuminov D and Lehmann K. Major Postoperative Complications Are a Risk Factor for Impaired Survival after CRS/HIPEC. *Annals of Surgical Oncology* 2017;24:2224-32.
27. Schneider MA, Eshmuminov D and Lehmann K. Major Postoperative Complications Are a Risk Factor for Impaired Survival after CRS/HIPEC. *Ann Surg Oncol* 2017;24:2224-32.
28. Wallet F, Maucort Boulch D, Malfroy S, et al. No impact on long-term survival of prolonged ICU stay and re-admission for patients undergoing cytoreductive surgery with HIPEC. *Eur J Surg Oncol* 2016;42:855-60.
29. Goodman MD, McPartland S, Detelich D and Saif MW. Chemotherapy for intraperitoneal use: a review of hyperthermic intraperitoneal chemotherapy and early post-operative intraperitoneal chemotherapy. *J Gastrointest Oncol* 2016;7:45-57.
30. Saeed K, Dale AP, Leung E, et al. Procalcitonin levels predict infectious complications and response to treatment in patients undergoing cytoreductive surgery for peritoneal malignancy. *Eur J Surg Oncol* 2016;42:234-43.

Figure Legends

Figure 1: Kinetics of CRP during an uncomplicated course

Figure 1A: Kinetics of C-reactive protein (CRP) levels in patients without postoperative complications (n=107) showing a significant secondary CRP increase after HIPEC with mitomycinC/doxorubicin (P=0.015, n=34) between day 5 and day 8. Figure 1B: CRP in patients without complications (n=38) after HIPEC with cisplatin showing a secondary CRP increase (P=0.026) between day 6 and 10. Figure 1C: Patients treated with oxaliplatin (n=35) present a linear decline of the CRP. Data are shown as median and IQR.

Figure 2: PSP confirms an ongoing inflammatory process

Figure 2A: Postoperative pancreatic stone protein (PSP) in patients without postoperative complications after HIPEC with mitomycinC/doxorubicin (n=34). There is a significant PSP increase in patients between day 2 and 6 (P=0.004). Figure 2B: Patients after cisplatin – based HIPEC show a significant PSP increase (P=0.031) between day 2 and 6. Figure 1C: No increase of PSP can be observed within the first postoperative week after HIPEC with oxaliplatin. Data are shown as median and IQR.

Figure 3: Bacterial components associated to the inflammatory response

Relative changes of bacterial 16srDNA during the postoperative course in patients after uncomplicated CRS/HIPEC. Patients after HIPEC with mitomycinC/doxorubicin (P=0.015) or cisplatin (P=0.015) have a significantly higher load of bacterial ribosomal DNA (16s rDNA) in their circulation compared to patients after HIPEC with oxaliplatin. Septic patients served as a positive control group. Data are shown as median and IQR.

Figure 4: Kinetics of WBC during an uncomplicated course

Figure 4A: Kinetics of white blood cells (WBC) levels in patients without infectious complications after CRS/HIPEC (n=107). After an initial increase, WBC decrease and remain in normal range after mitomycinC/doxorubicin HIPEC (n=34). Figure 4B-4C: There is a significant secondary WBC increase in patients after platin-based HIPEC (n=38, cisplatin-based, p=0.011, n=35, oxaliplatin-based, p=0.027) between day 4 and day 7. Data are shown as median and IQR.

Table 1: Patient characteristics

	All patients (n=140)
Age	56 (47 – 64)
Sex (male/female)	86 (61.4%) 54 (38.6%)
Primary tumor	
Colorectal	54 (38.6%)
Appendix tumors	35 (25%)
Mesothelioma	10 (7.1%)
Others	41 (29.3%)
PCI	6 (3 – 14)
Operation time (min)	360 (291.25-449.5)
Anastomosis (number)	1 (0 – 1)
ICU stay (days)	1 (1-2.75)
Hospital stay (days)	15 (12-20.75)
Complications	
none	85 (60.7%)
Major complications (Clavien-Dindo \geq IIIb)	9 (6.4%)
Mortality (Clavien-Dindo Grade V)	1 (0.7%)

Patient characteristics are shown for the entire cohort and reported as median +/- IQR.

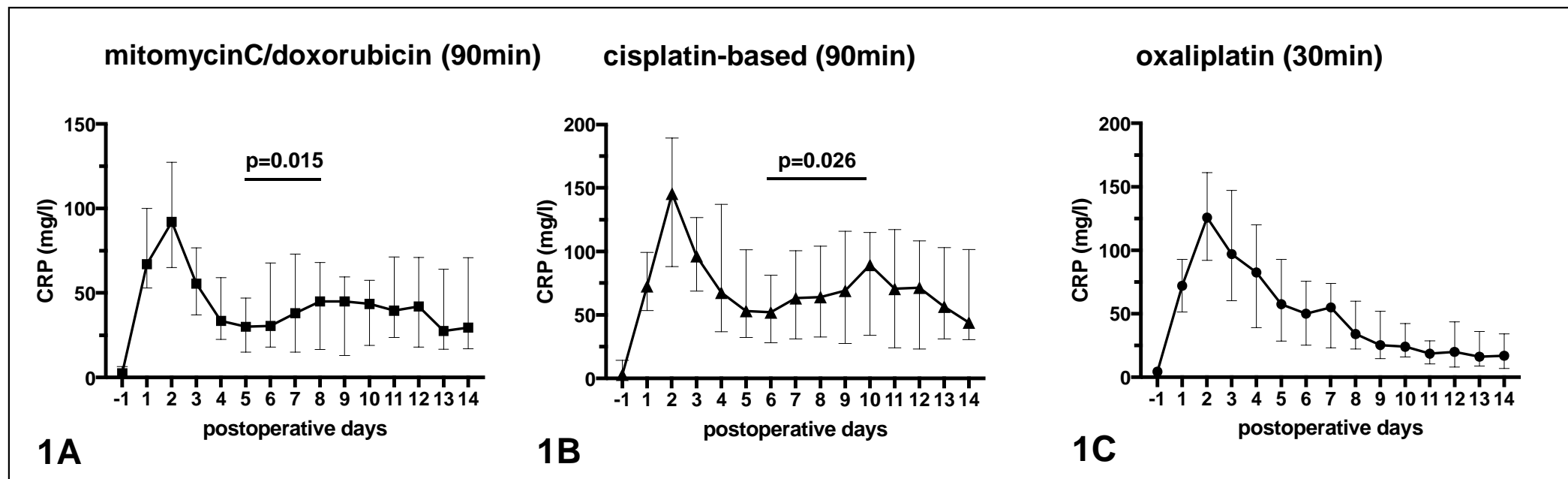


Figure 1: Kinetics of CRP during an uncomplicated course

Figure 1A: Kinetics of C-reactive protein (CRP) levels in patients without postoperative complications (n=107) showing a significant secondary CRP increase after HIPEC with mitomycinC/doxorubicin (P=0.015, n=34) between day 5 and day 8. Figure 1B: CRP in patients without complications (n=38) after HIPEC with cisplatin showing a secondary CRP increase (P=0.026) between day 6 and 10. Figure 1C: Patients treated with oxaliplatin (n=35) present a linear decline of the CRP. Data are shown as median and IQR.

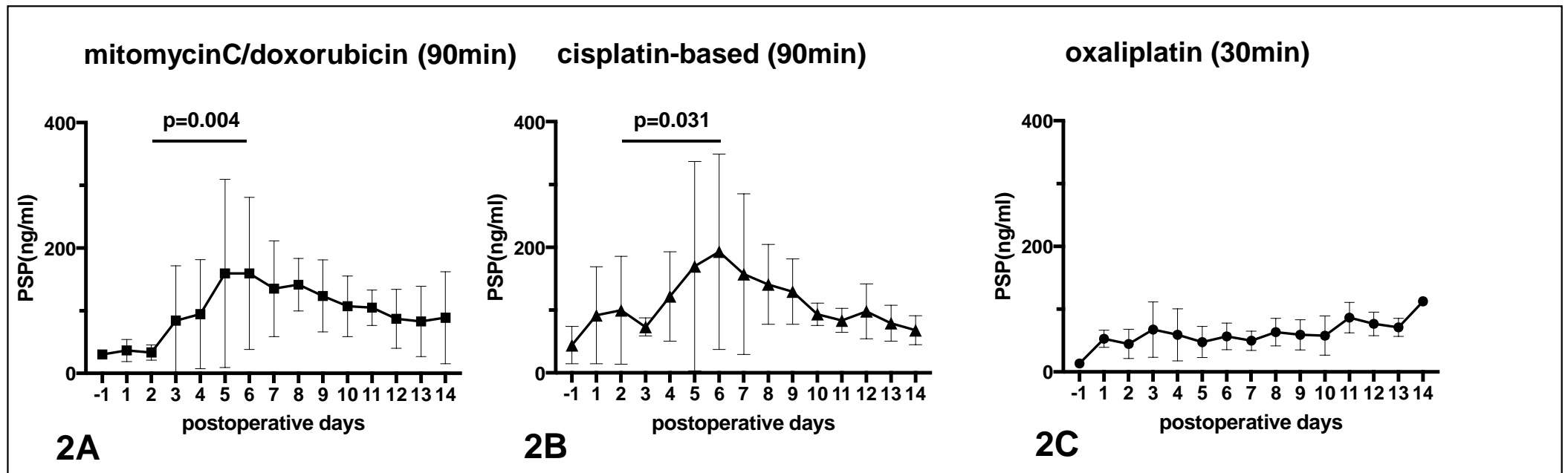


Figure 2: PSP confirms an ongoing inflammatory process

Figure 2A: Postoperative pancreatic stone protein (PSP) in patients without postoperative complications after HIPEC with mitomycinC/doxorubicin (n=34). There is a significant PSP increase in patients between day 2 and 6 ($P=0.004$). Figure 2B: Patients after cisplatin – based HIPEC show a significant PSP increase ($P=0.031$) between day 2 and 6. Figure 2C: No increase of PSP can be observed within the first postoperative week after HIPEC with oxaliplatin. Data are shown as median and IQR.

MS1

MS2

Slide 1

MS1 Marcel Schneider, 02-11-2018

MS2 Figure 2C: However, no increase in PSP was observed during in the first 14 postoperative days after HIPEC with Oxaliplatin.
Marcel Schneider, 02-11-2018

ACCEPTED MANUSCRIPT

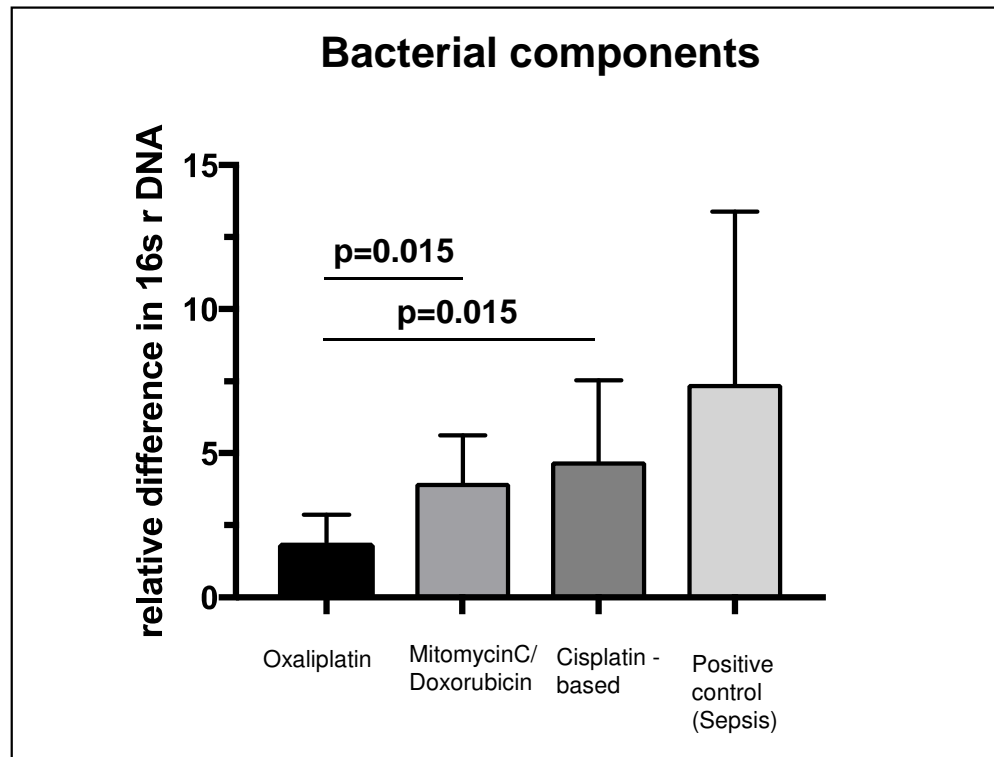


Figure 3: Bacterial components associated to the inflammatory response

Relative changes of bacterial 16srDNA during the postoperative course in patients after uncomplicated CRS/HIPEC. Septic patients served as a positive control group. Patients after mitomycinC/doxorubicin or cisplatin – based HIPEC treatment have a significant higher load of bacterial ribosomal DNA (16s rDNA) ($P=0.015$, $P=0.015$) in their circulation compared to patients after HIPEC with oxaliplatin. Data are shown as median and IQR.

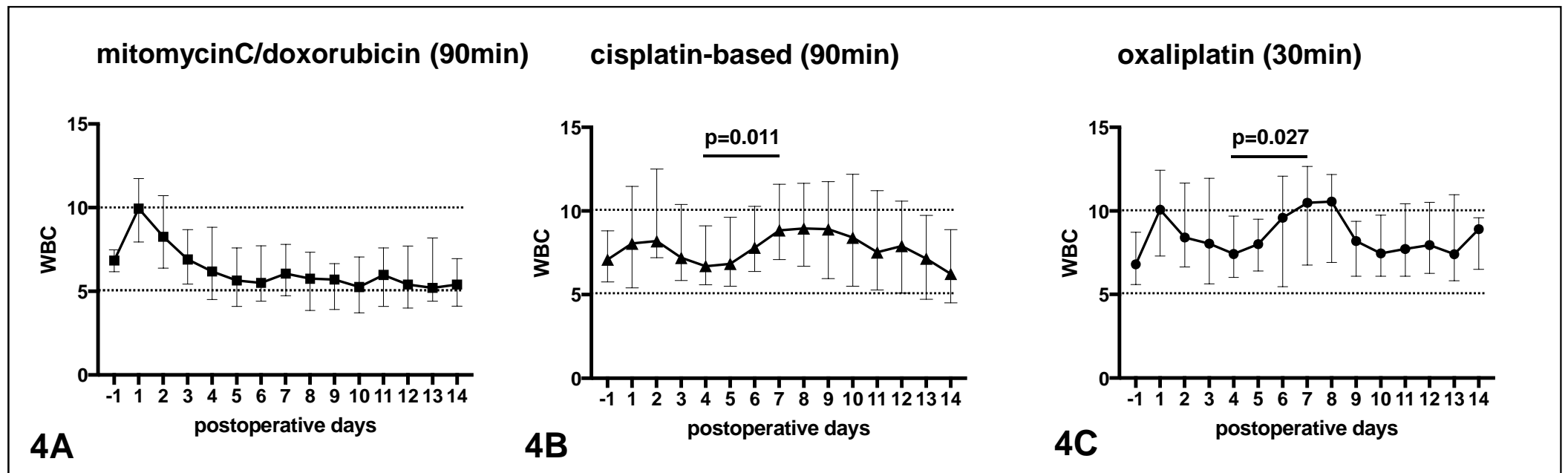


Figure 4: Kinetics of WBC during an uncomplicated course

Figure 4A: Kinetics of white blood cells (WBC) levels in patients without infectious complications after CRS/HIPEC (n=107). After an initial increase, WBC decrease and remain in normal range after mitomycinC/doxorubicin HIPEC (n=34). Figure 4B-4C: There is a significant secondary WBC increase in patients after platin-based HIPEC (n=38, cisplatin-based, p=0.011, n=35, oxaliplatin-based, p=0.027) between day 4 and day 7. Data are shown as median and IQR.