



University of  
Zurich<sup>UZH</sup>

Zurich Open Repository and  
Archive

University of Zurich  
University Library  
Strickhofstrasse 39  
CH-8057 Zurich  
[www.zora.uzh.ch](http://www.zora.uzh.ch)

---

Year: 2021

---

## Takotsubo Syndrome in Coronavirus disease 2019

Templin, Christian ; Manka, Robert ; Cammann, Victoria Lucia ; Szawan, Konrad Andreas ; Gotschy, Alexander ; Karolyi, Mihaly ; Winnik, Stephan ; Moch, Holger ; Meyer, Philippe ; Moreo, Antonella ; Bossone, Eduardo ; D'Ascenzo, Fabrizio ; Secco, Gioel Gabrio ; Mancone, Massimo ; Infusino, Fabio ; Gaido, Luca ; Giammaria, Massimo ; Wittstein, Ilan S ; Varga, Zsuzsanna ; Ghadri, Jelena R

DOI: <https://doi.org/10.1016/j.amjcard.2020.10.005>

Posted at the Zurich Open Repository and Archive, University of Zurich

ZORA URL: <https://doi.org/10.5167/uzh-190758>

Journal Article

Accepted Version



The following work is licensed under a Creative Commons: Attribution-NonCommercial-NoDerivatives 4.0 International (CC BY-NC-ND 4.0) License.

Originally published at:

Templin, Christian; Manka, Robert; Cammann, Victoria Lucia; Szawan, Konrad Andreas; Gotschy, Alexander; Karolyi, Mihaly; Winnik, Stephan; Moch, Holger; Meyer, Philippe; Moreo, Antonella; Bossone, Eduardo; D'Ascenzo, Fabrizio; Secco, Gioel Gabrio; Mancone, Massimo; Infusino, Fabio; Gaido, Luca; Giammaria, Massimo; Wittstein, Ilan S; Varga, Zsuzsanna; Ghadri, Jelena R (2021). Takotsubo Syndrome in Coronavirus disease 2019. *American Journal of Cardiology*, 138:118-120.

DOI: <https://doi.org/10.1016/j.amjcard.2020.10.005>

Takotsubo Syndrome in Coronavirus Disease 2019

Christian Templin MD, PhD , Robert Manka MD ,  
Victoria Lucia Cammann MD , Konrad Andreas Szawan MD ,  
Alexander Gotschy MD , Mihaly Karolyi MD, PhD ,  
Stephan Winnik MD, PhD , Holger Moch MD , Philippe Meyer MD ,  
Antonella Moreo MD , Eduardo Bossone MD, PhD ,  
Fabrizio D'Ascenzo MD, PhD , Gioel Gabrio Secco MD, PhD ,  
Massimo Mancone MD, PhD , Fabio Infusino MD ,  
Luca Gaido MD , Massimo Giammaria MD , Ilan S. Wittstein MD ,  
Zsuzsanna Varga MD , Jelena R. Ghadri MD



PII: S0002-9149(20)31071-7  
DOI: <https://doi.org/10.1016/j.amjcard.2020.10.005>  
Reference: AJC 24886

To appear in: *The American Journal of Cardiology*

Received date: 1 October 2020  
Accepted date: 5 October 2020

Please cite this article as: Christian Templin MD, PhD , Robert Manka MD ,  
Victoria Lucia Cammann MD , Konrad Andreas Szawan MD , Alexander Gotschy MD ,  
Mihaly Karolyi MD, PhD , Stephan Winnik MD, PhD , Holger Moch MD , Philippe Meyer MD ,  
Antonella Moreo MD , Eduardo Bossone MD, PhD , Fabrizio D'Ascenzo MD, PhD ,  
Gioel Gabrio Secco MD, PhD , Massimo Mancone MD, PhD , Fabio Infusino MD , Luca Gaido MD ,  
Massimo Giammaria MD , Ilan S. Wittstein MD , Zsuzsanna Varga MD , Jelena R. Ghadri MD ,  
Takotsubo Syndrome in Coronavirus Disease 2019, *The American Journal of Cardiology* (2020), doi:  
<https://doi.org/10.1016/j.amjcard.2020.10.005>

This is a PDF file of an article that has undergone enhancements after acceptance, such as the addition of a cover page and metadata, and formatting for readability, but it is not yet the definitive version of record. This version will undergo additional copyediting, typesetting and review before it is published in its final form, but we are providing this version to give early visibility of the article. Please note that, during the production process, errors may be discovered which could affect the content, and all legal disclaimers that apply to the journal pertain.

**Takotsubo Syndrome in Coronavirus Disease 2019**

Christian Templin<sup>1,\*,#</sup> MD, PhD; Robert Manka<sup>1,2,3,\*</sup>, MD; Victoria Lucia Cammann<sup>1</sup>, MD;  
 Konrad Andreas Szawan<sup>1</sup>, MD; Alexander Gotschy<sup>1,2,3</sup> MD;  
 Mihaly Karolyi<sup>2</sup>, MD, PhD; Stephan Winnik<sup>1</sup>, MD, PhD; Holger Moch<sup>4</sup>, MD; Philippe Meyer<sup>5</sup>, MD;  
 Antonella Moreo<sup>6</sup>, MD; Eduardo Bossone<sup>7</sup>, MD, PhD; Fabrizio D'Ascenzo<sup>8</sup>, MD, PhD;  
 Gioel Gabrio Secco<sup>9</sup>, MD, PhD; Massimo Mancone<sup>10</sup>, MD, PhD; Fabio Infusino<sup>10</sup>, MD;  
 Luca Gaido<sup>11</sup>, MD; Massimo Giammaria<sup>11</sup>, MD; Ilan S. Wittstein<sup>12</sup>, MD; Zsuzsanna Varga<sup>4</sup>, MD;  
 Jelena R. Ghadri<sup>1</sup>, MD

<sup>1</sup>University Heart Center, Department of Cardiology, University Hospital Zurich, Zurich, Switzerland

<sup>2</sup>Institute of Diagnostic and Interventional Radiology, University Hospital Zurich, Zurich, Switzerland

<sup>3</sup>Institute for Biomedical Engineering, University and ETH Zurich, Zurich, Switzerland

<sup>4</sup>Department of Pathology and Molecular Pathology, University Hospital Zurich, Zurich, Switzerland

<sup>5</sup>Service de cardiologie. Hôpitaux Universitaires de Genève, Geneva, Switzerland

<sup>6</sup>A. De Gasperis Cardio Center, ASST Grande Ospedale Metropolitano Niguarda, Milan, Italy

<sup>7</sup>Division of Cardiology, "Antonio Cardarelli" Hospital, Naples, Italy

<sup>8</sup>Division of Cardiology, Department of Medical Sciences, AOU Città della Salute e della Scienza, University of Turin, Turin, Italy

<sup>9</sup>Interventional Cardiology and Cardiac Surgery Unit, Azienda Ospedaliera SS Antonio e Biagio e Cesare Arrigo, Alessandria, Italy

<sup>10</sup>Department of Clinical Internal, Anesthesiological and Cardiovascular Sciences, Sapienza University of Rome, Rome, Italy

<sup>11</sup>Division of Cardiology, Maria Vittoria Hospital, Turin, Italy

<sup>12</sup>Division of Cardiology, Department of Medicine, Johns Hopkins University School of Medicine, Baltimore, Maryland

\* the first two authors contributed equally to this work

Declaration of interest: nothing to declare.

**#Correspondence:**

Christian Templin, MD, PhD, FESC

Professor of Cardiology

Director of Andreas Grüntzig Heart Catheterization Laboratories &

Acute Cardiac Care

University Hospital Zurich

University Heart Center - Department of Cardiology

Raemistrasse 100

8091 Zurich, Switzerland

Phone: +41 (0)44 255 9585

E-mail: Christian.Templin@usz.ch

Around one-fifth of patients with coronavirus disease 2019 (COVID-19) show evidence of acute myocardial injury. The precise etiology remains unclear and the observation that some patients do not show obstructive coronary artery disease (CAD) on coronary angiography has further complicated our understanding of the pathophysiology.

Takotsubo syndrome (TTS) constitutes an acute heart failure syndrome that may represent a form of acute catecholaminergic myocardial stunning. TTS presents with the typical symptoms of an acute coronary syndrome, like that observed in some patients with COVID-19.

11 patients with COVID-19 who were diagnosed with TTS based on current criteria were included and compared to 57 patients with COVID-19 alone and 3,215 patients with TTS to elucidate features of COVID-19 patients who develop TTS and to infer the underlying pathology. Furthermore, we have stratified COVID-19 patients with myocardial injury into 2 groups: those with wall motion abnormalities and those without.

While COVID-19 disproportionately affected men (68.0%), most patients with COVID-19+TTS were female (88.1%). Most COVID-19+TTS patients had either physical (72.7%) or emotional (18.2%) triggers, most likely from infection with the severe acute respiratory syndrome coronavirus 2 (SARS-CoV-2). Patients with COVID-19+TTS also tended to be older (mean age 72.4 years) compared to patients with COVID-19 alone (mean age 58.5 years) and TTS (mean age 67.8 years). Chest pain was more common among patients with TTS, irrespective of COVID-19, while dyspnea was most prevalent among COVID-19 patients who develop TTS. Importantly, patients with COVID-19 who developed TTS had significantly worse outcomes in terms of rates of respiratory therapy or in-hospital death (70.0%) than traditional cases of TTS (18.6%).

Troponin and brain natriuretic peptide (BNP) levels were typically elevated at the time of admission in COVID-19 patients with myocardial injury, suggesting that the systemic inflammatory response may be precipitating troponin release in these patients. In contrast, in patients with COVID-19 and TTS, troponin and BNP levels were generally low upon admission but increased during hospitalization. Left ventricular ejection fraction was most significantly reduced in patients COVID-19+TTS among all the groups we analyzed, which correlated with the highest peak BNP values.

Some of these cases of COVID-19 associated myocardial injury had global wall motion impairment, which we postulate may actually be a form of TTS. Although TTS typically presents with regional wall motion abnormalities (e.g., apical ballooning), a 'globally' reduced form has also been observed.<sup>1</sup> It is conceivable that the cytokine storm and catecholamine surge in patients with COVID-19 may cause a 'global' form of TTS in which the basal myocardium is not able to compensate, leading to global hypokinesia (Figure 1).

Patients with TTS also generally show localized edema in the region of the wall motion abnormality on CMR. Meanwhile, a marked biventricular pattern of myocardial edema has been reported in a case of COVID-19-associated myocardial injury.<sup>2</sup> We also observed a COVID-19 patient with TTS who showed marked edema in the region of the wall motion abnormality on CMR in addition to global edema (Figure 1). Indeed, as both TTS and COVID-19 can trigger microcirculatory dysfunction,<sup>3</sup> it is possible they could act jointly

resulting in significant cardiac complications. In particular, the cytokine storm that occurs in COVID-19 may work in concert with the exaggerated sympathetic stimulation of TTS to activate similar (albeit currently unknown) pathways, resulting in severe microcirculatory dysfunction, global/regional myocardial edema, and decompensated acute heart failure.

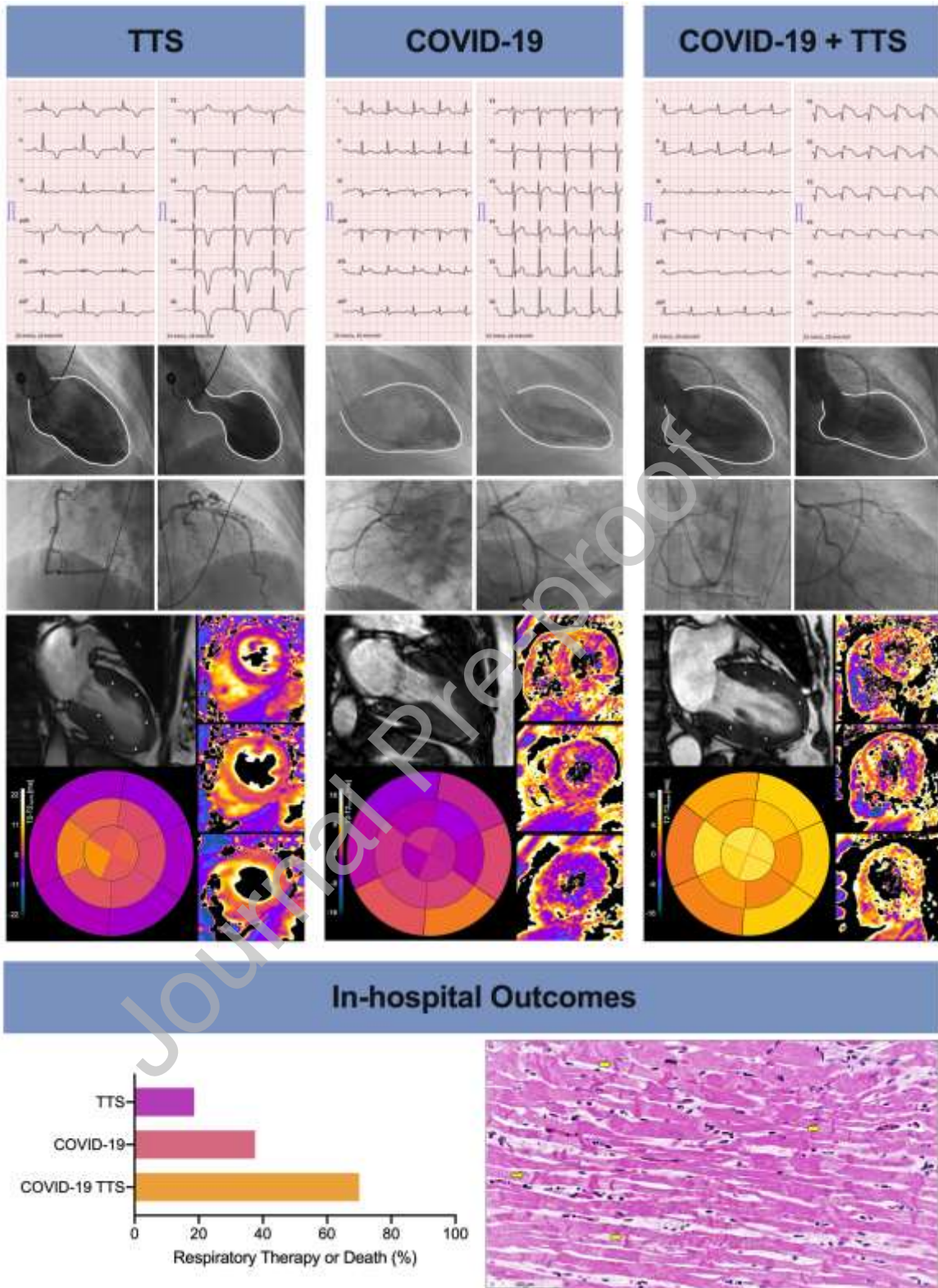
Of note, we observed contraction band necrosis with mononuclear infiltration in four of six patients who died due to COVID-19 and underwent autopsy (Figure 1). In comparison to coagulation necrosis in myocardial ischemia, contraction band necrosis can be seen as a result of the biopsy procedure or reflects catecholamine toxicity and sympathetic hyperactivity.<sup>4</sup> Indeed, the presence of contraction band necrosis and mononuclear infiltration has been reported previously in TTS,<sup>5</sup> potentially reflecting sympathetic overdrive. Contraction bands in combination with mononuclear infiltration, argue against artifactual changes and is indicative of the acute phase of severe left ventricular dysfunction. Therefore, an earlier biopsy may reveal the true incidence of contraction band necrosis in cases of COVID-19 myocardial injury with impaired wall motion abnormalities and normal coronary arteries.

In summary, the severe inflammatory response that occurs in COVID-19 may work in concert with the exaggerated sympathetic stimulation of TTS to activate similar pathways, resulting in severe microcirculatory dysfunction, global/regional myocardial edema, and decompensated acute heart failure. We hypothesize the coronary microcirculatory disturbances resulting from the combination of COVID-19+TTS could trigger a sudden calcium influx, culminating in contraction band necrosis. Therefore, patients with a dual diagnosis of TTS and COVID are at increased risk of adverse events.

## References

1. Bybee Kevin A and Prasad A. Stress-Related Cardiomyopathy Syndromes. *Circulation*. 2008;118:397-409.
2. Inciardi RM, Lupi L, Zaccone G, Italia L, Raffo M, Tomasoni D, Cani DS, Cerini M, Farina D, Gavazzi E, Maroldi R, Adamo M, Ammirati E, Sinagra G, Lombardi CM and Metra M. Cardiac Involvement in a Patient With Coronavirus Disease 2019 (COVID-19). *JAMA Cardiol*. 2020.
3. Madjid M, Safavi-Naeini P, Solomon SD and Vardeny O. Potential Effects of Coronaviruses on the Cardiovascular System: A Review. *JAMA Cardiol*. 2020.
4. Cebelin MS and Hirsch CS. Human stress cardiomyopathy. Myocardial lesions in victims of homicidal assaults without internal injuries. *Hum Pathol*. 1980;11:123-32.
5. Nef HM, Mollmann H, Kostin S, Troidl C, Voss S, Weber M, Dill T, Rolf A, Brandt R, Hamm CW and Elsasser A. Tako-Tsubo cardiomyopathy: intraindividual structural analysis in the acute phase and after functional recovery. *Eur Heart J*. 2007;28:2456-64.

Figure legend



Electrocardiography (ECG; top row), left ventriculography (second row), and cardiac magnetic resonance images (CMR; third row) from patients with TTS, COVID-19, and COVID-19+TTS. Coronary angiography showed unobstructed coronary arteries in all three patients. The CMR images display the 2-chamber cine frame; the basal, mid-ventricular, and

apical T2 maps, and the T2 bulls eye plot. In-hospital outcomes (including death or ventilation) are also summarised (bottom left). Routine hematoxylin and eosin (H&E) stained section of the posterior myocardial wall from a COVID-19+TTS patient (autopsy heart specimen; bottom right).

*First column:* TTS patients show deep negative T-waves and prolonged QTc time on ECG. Left ventriculography shows classical apical ballooning with compensatory hypercontractility of the basal segments. CMR with edema sensitive T2-mapping showed normal T2 values in the basal segments and edema of the mid-ventricular and apical segments (T2 z-score mid-ventricular and apical: 4 and 8).

*Second column:* COVID-19 patient with ST-segment elevation in I, aVL, V5, and V6, with normal QTc time on ECG. Left ventriculography shows mildly-reduced left ventricular ejection fraction with infero- and antero-lateral basal hypokinesia. CMR demonstrates diffusely elevated T2 values that are accentuated in the hypokinetic segments (infero-lateral basal, T2 z-score: 5).

*Third column:* COVID-19 TTS patients show significant ST-elevations in the septal and anterior chest leads on ECG after 3 weeks of intensive care treatment (including mechanical ventilation for acute respiratory distress syndrome). Left ventriculography shows rapid deterioration of left ventricular function with TTS wall motion pattern. Representative CMR shows excessively high T2 values over the entire myocardium, indicating global edema with peak values in the apical segments (T2 z-score: 9). The myocardial fibers show loss of cross-striations and nuclei are not visible in most areas. Inset (higher magnification) shows several irregularly-shaped wavy contractions extending across the myocardial fibers (arrows). Some congested small capillaries can be observed in the interstitial space with increased mononuclear cells.

## **Funding**

CT has been supported by the H.H. Sheikh Khalifa bin Hamad Al-Thani Research Programme and the Swiss Heart Foundation. The InterTAK Registry is supported by the Biss Davies Charitable Trust.