



**University of
Zurich**^{UZH}

**Zurich Open Repository and
Archive**

University of Zurich
University Library
Strickhofstrasse 39
CH-8057 Zurich
www.zora.uzh.ch

Year: 2021

**Evaluation of air polishing with a sterile powder and mechanical debridement
during regenerative surgical periimplantitis treatment: a study in dogs**

Solderer, Alex ; Pippenger, Benjamin E ; Donnet, Marcel ; Wiedemeier, Daniel ; Ramenzoni, Liza L ; Schmidlin,
Patrick R

DOI: <https://doi.org/10.1007/s00784-020-03572-2>

Posted at the Zurich Open Repository and Archive, University of Zurich

ZORA URL: <https://doi.org/10.5167/uzh-194448>

Journal Article

Accepted Version

Originally published at:

Solderer, Alex; Pippenger, Benjamin E; Donnet, Marcel; Wiedemeier, Daniel; Ramenzoni, Liza L; Schmidlin, Patrick R (2021). Evaluation of air polishing with a sterile powder and mechanical debridement during regenerative surgical periimplantitis treatment: a study in dogs. *Clinical Oral Investigations*, 25(5):2609-2618.

DOI: <https://doi.org/10.1007/s00784-020-03572-2>

Evaluation of air-polishing with a sterile powder and mechanical debridement during regenerative surgical peri-implantitis treatment: A study in dogs

Alex Solderer

Clinic of Conservative and Preventive Dentistry, Division of Periodontology and Peri-implant Diseases, Center of Dental Medicine, University of Zurich, Switzerland

Benjamin E. Pippenger

Preclinical & Translational Research Group, Straumann AG, Basel, Switzerland

Marcel Donnet

EMS, Nyon, Switzerland

Daniel Wiedemeier

Statistical Services, Center of Dental Medicine, University of Zurich, Switzerland

Liza L. Ramenzoni

Clinic of Conservative and Preventive Dentistry, Division of Periodontology and Peri-implant Diseases, Center of Dental Medicine, University of Zurich, Switzerland

Patrick R. Schmidlin

Clinic of Conservative and Preventive Dentistry, Division of Periodontology and Peri-implant Diseases, Center of Dental Medicine, University of Zurich, Switzerland

Corresponding author:

Patrick R. Schmidlin

Plattenstrasse 11, 8032 Zurich

Switzerland

Email: patrick.schmidlin@zzm.uzh.ch

Phone: +41 44 634 34 17

Abstract

Objectives: To evaluate the effectiveness of mechanical debridement and/or air-polishing on the healing of ligature-induced buccal peri-implantitis dehiscence defects in dogs.

Material and methods: Forty-eight implants were placed in the mandibles of twelve beagle dogs and peri-implantitis was induced for two months using ligatures. The resulting buccal dehiscence-type defects were surgically cleaned and augmented (xenogenic filler and resorbable membrane) according to one of the following treatments: 1) Cleaning with carbon curette (Debridement - D) and guided bone regeneration (GBR/G): DG, 2) air-polish cleaning (A) and GBR: AG, 3) a combination of D/A/G: DAG and 4) D/A without GBR: DA. After two months histomorphometric and inflammatory evaluations were conducted.

Results: The median bone gain after therapy ranged between 1.2 mm (DG) and 2.7 mm (AG). Relative bone gain was between 39% (DG) to 59% (AG). The lowest inflammation scores were obtained in DA without GBR (5.84), whereas significantly higher values between 8.2 and 9.4 were found in the groups with augmentation. At lingual sites without defects, scores ranged from 4.1 to 5.9. According to ISO, differences above 2.9 were considered representative for irritative properties.

Conclusions: All treatments resulted in partial regeneration of the defects. No treatment group showed a significantly ($p < 0.05$) better outcome. However, pretreatment with air-polishing showed a tendency for less inflammation. Noteworthy, inflammation assessment showed an overall irritative potential after GBR in the evaluated early healing phase.

Clinical relevance: Peri-implantitis treatment still represents a big issue in daily practice and requires additional preclinical research in order to improve treatment concepts.

Keywords: Dental Implants, Peri-implantitis, Guided Bone Regeneration, Air-polishing, Dehiscence defect

Introduction

The use of implants in dental practice has become a routine procedure in order to replace one or more missing teeth using either fixed or removable dentures. High success rates of up to 97% after 10 (1) and 75 % over 20 years (2) underline the excellent applicability of this treatment. However, prosthetic and biological complications may cast a cloud over this enthusiastic impression. Especially peri-implant inflammations diagnosed as mucositis and peri-implantitis should be mentioned in the first place (3). They are specified as a plaque-associated pathological conditions affecting the soft and hard tissues around dental implants, resulting in inflammation of the mucosa and progressive peri-implant bone loss (4). Peri-implantitis represents one of the main reasons for late implant failure (5, 6) and a meta-analysis estimated a weighted mean prevalence of 22% (CI: 14-30%) for disease development (7). Like periodontitis, peri-implantitis is mainly caused by pathogen biofilms, but may also be modulated by different co-factors (8).

Different approaches can be found for the treatment of implants with peri-implantitis and a plethora of surgical methods, techniques and materials applied during such interventions have been described in the literature so far (9). Regardless the existence of many different techniques, two treatment parameters remain common to peri-implant treatment procedures: i) cleaning and decontamination of the affected implant surfaces, i.e. calculus, biofilm and endotoxin (4) and – in the case of regenerative procedures - ii) the stable augmentation and coverage of the defects, which includes different possible filler materials and membranes with and without additional biologic agents (10). Not surprisingly, many different combinations with regard to techniques and materials used are reported in the literature (9), making a comparison of the outcomes, an elaboration of appropriate clinical treatment recommendations and/or defining reliable standards very difficult.

With regard to the cleaning of a contaminated surface, several physico-chemical anti-infective methods can be used including conventional mechanical debridement with hand and/or (ultra)sonic instruments lasers and photodynamic therapy (9). In addition, air-polishing represents an alternative or adjunct option (9) (11) (12). A recent consensus statement claimed that air-polishing represents a valuable alternative for effectively disrupting bacterial biofilms (11). Among the materials applied for this approach, glycine and sodium bicarbonate powders were found to be equally effective in biofilm removal (11). Clinically, air-polishing was shown to result in

significantly higher reduction of bleeding-on-probing (BOP) (11), even in a non-surgical peri-implantitis treatment protocol as compared to mechanical debridement or ER:YAG laser monotherapies (11). However, without surgical access, none of the non-surgical concepts may achieve complete and predictable disease resolution so far (11). Therefore, adequate decontamination of the infected implant surfaces to a critical level remains essential, especially when regenerative concepts are applied in order to allow for successful graft integration (9).

Regarding peri-implantitis-derived bone defect regeneration, the use of air-polishing in combination with guided bone regeneration (GBR) procedures has been already described in clinical studies and a recent review, in which air-polishing techniques showed beneficial effects (12). Since conclusive statements on the preclinical and/or clinical applicability of air-polishing for the management of peri-implantitis diseases remains elusive, additional studies are warranted to clarify the additional benefits.

The present animal study aimed to assess the healing after different cleaning options including debridement with carbon cures and/or air-polishing when treating peri-implantitis buccal dehiscence defects with or without simultaneous GBR. According to the author's knowledge, this is the first preclinical study using a sterilized air-polishing powder (sodium bicarbonate with a grain size ranging from 10 – 25 microns) applied with a specialized delivery system unit (prototype designed for sterile usage). Histomorphometric evaluations were conducted in order to measure bone gain and the inflammatory infiltrate (ISO 10993) (13). It was hypothesized that air-polishing leads to more bone formation and less inflammation due to improved cleaning of the affected implant surfaces.

Material and methods

Animals and anesthetic protocol

In the present animal study, twelve adult female Beagle dogs were included. They were all systemically healthy, 12-13 months old and with an average weight of 10 kg at the day of surgery. During the entire study, dogs were fed with soft food and water. The study was conducted at the BWEF, New Jersey, USA. The animals were housed in individual cages under controlled environment. This study was performed in accordance with applicable US laws regarding the treatment of experimental animals

and under the ethical approval number IACUC 16-BP-003. This study adhered to the ARRIVE Guidelines.

For each surgery, a standardized anesthesia protocol was applied. Inducing general anesthesia Propofol was administered intravenously and during surgery 2-5% Isoflurane was given via intubation tube. Before surgery, lidocaine/epinephrine was locally administered. After surgery, all animals received antibiotics (Enrofloxacin) for 7 days to prevent infections. The animals were monitored routinely after surgery and analgesics were given if necessary.

Surgical phases

The different surgical interventions performed in each animal are described below and Figure 1 depicts the timeline of the experimental conditions and procedures.

1. Protocol of anesthesia

On the day of surgery, the animals were pre-medicated by intramuscular injection of Atropine (0.05 mg/kg) followed by Xylazine (2.7 mg/kg) and Tiletamine-Zolazepam; (7.0 mg/kg intramuscular; Putney, Inc. Portland, ME), followed by mask inhalation of 2 to 5 percent Isoflurane mixed with oxygen. Each animal was then transferred to the surgical suite, intubated with an endotracheal tube, and general anesthesia continued with 2 to 5 percent Isoflurane mixed with oxygen. Directly before the surgical intervention, local injections of 1.0mL/hemi-mandible of 2% Lidocaine with Epinephrine 1:50,000 (20mg/mL + 12.5µg/mL) into the buccal and lingual gingiva are performed to ensure total pain management.

2. Tooth extraction

In this first surgical step, P2-M1 were removed after reflection of full-thickness flaps and tooth separation. Primary wound closure was attained by means of mattress sutures and the sites were allowed to heal for 3 months.

3. Implant placement

In a second surgical intervention, bilateral vestibular incisions were made and full-thickness flaps were elevated to expose the edentulous sites for implant placement in

the mandible. Two surgical implant beds were prepared bilaterally, at a distance of 8 mm apart, using a low-trauma surgical technique under copious irrigation with sterile 0.9% physiological saline. Two Bone Level Tapered SLActive titanium implants (BLT, SLActive) were placed in each side of the mandible (NC, Φ 3.3 mm, length 8 mm, Institut Straumann AG, Basel, Switzerland) (n = 4 implants per dog) according to a one-stage procedure and covered with healing abutments (Φ 3.6 x H 2 mm Straumann, Basel, Switzerland, height: 5 mm). The implants were inserted in a way so that the borderline between the bony and transmucosal parts (BTB) of the implant coincides with the bone crest. Following irrigation, mucoperiosteal flaps were repositioned and primary wound closure achieved with interrupted resorbable sutures. Following implant placement, a plaque control regime was initiated. Tooth and implant cleaning were performed by the use of a toothbrush with chlorhexidine gel 4 times a week for 2 months.

4. Peri-implantitis induction – ligature placement

In a third stage, two months after implant insertion, cotton ligatures were placed in a submucosal position around each implant by forcing them into an apical position. The ligatures were removed after another 2 months. Peri-implantitis induction resulted in buccal bone defects at all implant sites.

5. Peri-implantitis treatment and terminal procedure

The treatments were allocated to the implants randomly such that each treatment group was spread evenly across the different anatomical implant site positions. During the fourth and final surgery, bilateral intrasulcular and vertical releasing incisions were made and full-thickness mucoperiosteal flaps were reflected to expose the respective peri-implant bone defects. Intraoperative Pocket probing depth measurements were conducted. All measurements have been carried out by the senior author (PRS), an experienced periodontist, with UNC15 periodontal probe (Hu-Friedy) probes in 0.5mm increments, therefore no intra-examiner calibration had to be performed. Following replacement of the healing abutments by cover screws (Institute Straumann AG), the granulation tissue was removed from the defects and the respective implant surfaces were instrumented as follows: 1) mechanical debridement + GBR (DG) (Control group), 2) air-polishing using an experimental

sterile powder (EMS, Nyon, Switzerland) + GBR (AG) 3) mechanical debridement + air-polishing (DA) and 4) mechanical debridement + air-polishing + GBR (DAG). The air-polishing prototype device included a sterile single use water and powder-line, the first of this kind, and using a standard EMS AIRFLOW handpiece. Treatment was carried out as per recommendation usually done for subgingival treatment. After copious rinsing with saline solution of all the defect sites, in group 1,2 and 4 bovine bone mineral (BBM - Cerabone[®], Botiss, Straumann AG, Basel, Switzerland) was filled into the remaining defect volume and covered by a barrier membrane (Jason[®], Botiss, Straumann AG, Basel, Switzerland). The mucoperiosteal flaps were extended coronally to facilitate a submerged healing procedure. Primary wound closure was achieved with consecutive resorbable sutures. No randomization was performed (Fig. 2).

During the final healing phase, the animals received prophylactic antibiotic treatment for the first 3 days of the healing phase to avoid any surgical-related complications. Postoperative care consisted of chlorhexidine administration to the surgery site for 2 weeks post-operatively and then tooth brushing (2 times a week) for the remaining healing period. The total healing period was 2 months.

All animals were sacrificed 8 weeks after surgery 4. The termination was performed by inducing cardiac arrest with an intra-cardiac injection of a 20% solution of pentobarbital.

The block resection of the implant sites (mandible) was performed using an oscillating autopsy saw such that the soft tissue remained intact.

After the hemi-mandibles were isolated, they were fixed by immersion in formalin (formaldehyde 4% solution) for at least 2 weeks prior to sending for histological processing.

Histology and Histomorphometry

Histological processing and histopathologic evaluation was carried out by experienced pathologists (AnaPath Institute, Switzerland).

Bone samples (containing the implants) were immersed in formalin buffer solution, dehydrated using ascending grades of alcohol and xylene, infiltrated and embedded in methylmethacrylate for non-decalcified sectioning. Each site was cut in bucco-lingual direction. One section of 500 µm was obtained, grinded to a final thickness of

30-50 µm and stained with paragon (toluidin blue and basic fuchsin) for microscopic evaluation.

Histomorphometrical measurements were done on central buccal sections within the region of interest (ROI) (Fig. 3). The depth of the buccal bone wall defects was determined by probing measurements taken intrasurgically at the time of treatment. After surgery defects were left to heal for a period of 8 weeks. To determine if the cleaning procedure was effective, a standardized ROI was defined on the histological slides by:

- a. The diameter of the sectioned implant was measured at its widest point (each implant was not necessarily sectioned perfectly down the middle. It is important to determine how much implant is represented in the histological image to ensure consistency in ROI area generations).
- b. Considering the ROI only extends apically to the probe depth measures of the bone defect, any bone within this ROI can be considered as new bone growth (green area) after the cleaning process (Fig. 3).
- c. All measurements regarding bone gain were measured linearly on base of the histomorphometric analysis (Fig. 3) with computer programmes (Fiji and Image J, National Institutes of Health, Bethesda, Maryland, USA).

The following histological measurements were conducted at each implant (Fig. 3):

- Defect depth: distance from the implant shoulder to the most apical point of the peri-implantitis defect before treatment (independently verified by two examiners).
- Newly formed bone: distance from the base of the defect to the most coronal bone-to-implant contact (BIC). Bone gain was measured in the absolute amount in millimeter (absolute bone gain).

The relative bone gain in relation to the initial defect depth has been calculated and evaluated accordingly.

Within the region of interest, defined by the implant position, the borders of the buccal defect and the course of the mandibular bone, area measurements of remaining bone substitute material (if applicable), newly formed bone, soft tissues

and tissue deficiency have been measured via computerized planimetry by a blinded examiner for all groups.

Statistical analysis

The median values and IQR for the cumulative score are presented in a table (Table1, 3 & 4). The Wilcoxon's signed rank test was used to evaluate differences between the treatments in the defect size recorded at the time of surgery and post-treatment. *P* values of less than .05 were considered statistically significant.

Results

All dogs showed uneventful healing and survived all phases. Finally, a total of 33 out of 48 implants (7 DG, 9 DAG, 9 AG and 8 DA) could be included in the final analysis. Most implants were lost during peri-implantitis induction, i.e. before peri-implantitis treatment was started. After therapy, only two implants were actually lost (both in the DG group). Three implants (all in one dog; No. 10) were excluded due to insufficient bone integration at the buccal aspect, i.e. implants were completely outside the bony envelope (1 DAG, 1 DG, 1 DA).

Histopathology

In general, no inflammation was noted at peri-implant tissues representing successfully (re-)osseointegrated aspects. Bone growth was nicely joining the implant distance within the mandibular bone tissue. Fibrosis and inflammatory infiltrate were mainly noted at those sites, which achieved no bone gain; nevertheless, biofilm was not visually detectable (histology not shown).

At the lingual aspect, in general low irritation scores were measured ranging from 5.8 (DA - Debridement & Air-polishing) to 4.1 (DAG - Debridement & Air-polishing & GBR). At the buccal side, score ranged from 5.8 (DA - Debridement & Air-polishing) to 9.4 (AG - Air-polishing & GBR) with no significant differences between all groups. However, with regard an additional "irritative potential" according to ISO 10993-6:2016 (E), mean differences between test items above 2.9 can be considered indicating an inflammatory implication (13). Therefore, comparison at the lingual aspects showed no notable irritation potential or difference between groups, whereas a difference of 3.6 was considered a slight irritative potential as compared to the

group with the lowest score in the control (DA - Debridement & Air-polishing). The rather low score in the latter group was mainly due to low fibrosis, neovascularization and mononuclear cells. In all other groups the higher inflammation scores were influenced mainly by two factors, i.e. the presence of bone substitute particles and the implant setting in an oblique direction. On a cellular base inflammation was characterized through the presence of polymorphonuclear cells, lymphocytes, macrophages and plasma cells.

GBR procedures apparently resulted in significantly higher ($p < 0.05$) inflammatory scores at the buccal sites as compared to ungrafted ones (5.8 vs. 8.2-9.4). Histologically, the bone substitute material was not fully integrated into the bony tissue, and mainly in the gingival tissues, this caused a more accentuated inflammatory infiltrate accompanied by surrounding fibrotic changes. Figure 4 shows representative probes for all four treatment groups. Table 2 is elucidating cumulative score of the inflammatory cells, which corroborates a slight increase of lymphocytes in grafted sites.

Bone gain after treatment

No significant differences could be observed between treatment groups with regard to the initially created peri-implantitis defect characteristics (Table 3): Buccal bone defect depths ranged between 3.5mm (DA - Debridement & Air-polishing) and 4.5mm (DAG - Debridement & Air-polishing & GBR and AG - Air-polishing & GBR).

Regarding new BIC, no statistical difference was detected between the different treatment groups. No implant showed complete healing of the defect. Absolute bone gain ranged between a median of 1.2 mm (Debridement & GBR) and 2.7 mm (Air-polishing and GBR). The relative bone gains ranged from a median of 39% (DG - Debridement & GBR) to 59% (AG - Air-polishing and GBR), respectively (Table 3).

Area measurements

Area measurements performed on a preset area of interest including remaining substitute material, new bone tissue, soft tissue and tissue deficiency resulted in a mean new bone regeneration of 19 - 47.8 % between the different groups. In the three groups using bone substitute materials (DG, DAG, DG) remaining substitute materials of 11 to 21.5% could be detected within the region of interest. Soft tissue ranged from 52.9 to 61.9% with the

highest values in the DG-Group. Some implants showed soft tissue deficiencies resulting in recessions ranging in a mean of 2.3 to 8.2%. Statistical no significant differences could be found. (Table 4)

Discussion

The aim of the present study was to compare exemplary intra-surgical anti-infective protocols alone or in combination with GBR when treating peri-implantitis defects in a dog model. Disinfection of the surgically exposed implant surfaces was achieved using air-polishing and/or debridement with a carbon curette. GBR in this study consisted of the application BBM in combination with a resorbable collagen membrane.

All treatment approaches resulted in a partial regeneration of the defects. But no treatment group showed a significantly better outcome. However, pretreatment with air-polishing showed a tendency towards less inflammation and – noteworthy - inflammation assessment showed rather an irritative potential after GBR in the evaluated early healing phase.

So far, several anti-infective protocols have been proposed to primarily clean and disinfect the exposed dental implant in the management of peri-implantitis (9). The usage of air-polishing using glycine powder against biofilms at implants was already described in vitro and represents one of the most promising methods as compared to curette or sonic-scaler debridement (14) (15). A bacterial reduction of 99.9% on implant surfaces using different systems of air-polishing has been shown (16). Further air-polishing was already used and described as a decontamination protocol in a peri-implantitis dog study in 1997 (17). The surgical protocol in the current study includes the use of an experimental sterile bicarbonate-based powder. To date, the use of sterile powders has never been described in a preclinical study marking a novelty in biofilm disruption and peri-implantitis therapy.

Glycine powder used in the cited studies is a PERIO powder with a mean size of about 20-25 microns. Generally, sodium bicarbonate is of bigger size (40 – 65 microns) for supra-gingival cleaning, but in this study an experimental sodium bicarbonate powder with a mean particle size of 12-18 micron was used. Two reasons led to this decision: first reducing the size reduces the abrasivity of sodium bicarbonate powder to reach level similar to glycine PERIO powder. Secondly the possibility to sterilize this sodium bicarbonate powder arrived.

Furthermore, when it comes to open-flap surgery for the treatment of peri-implantitis, sodium bicarbonate air-polishing has been found to be an efficient tool to remove biofilms and has been verdicted as safe when used properly (18). This could relate to the fact that peri-implantitis-surgery, as described in this paper, does more correspond to a supragingival use as a full-thickness flap is elevated. Nevertheless, here the small sized sodium bicarbonate powder could combine the advantage of the efficiency and the low abrasivity. Additionally, the usage of this small sized sodium bicarbonate powder relay on the air-polishing studies using sodium bicarbonate to decontaminate implant surfaces. In vitro it was shown that thorough removal of biofilms on implant surfaces can be achieved (18). In 2011 Schwarz et al. have shown that sodium bicarbonate based air-polishing does not lead to significant alterations of the implant surface or coating (19). In in-vitro studies the biocompatibility of the titanium surface after air-polishing with sodium bicarbonate has been described as very high (18).

The ligature-induced peri-implantitis model in this study has been extensively used in peri-implant disease studies observing the pathophysiology and testing the efficacy of different therapeutic protocols (17) (20) (21) (22). After two months of ligature placement not rather Class-I-e-defects, as mostly described (23), but rather buccal dehiscence Class-I-a-defects, were observed (23). The authors attribute this finding on the one hand to the size of the included beagle dogs and the resulting small anatomy including ridge width of the mandibles compared to the implant diameter and on the other hand - as already been described – that the evaluated bone level implants as such show only minor defect progression and defect formation in animal peri-implantitis models (24). This fact might have also led to the relatively high number of lost implants (10 implants) during healing-phase. Similar defect morphologies were also observed in a recent peri-implantitis dog study (25).

The resulting dehiscence defects were treated with four different approaches. The different approaches led to improved clinical outcomes and bone gain. But none of the implants showed a complete resolution of the defects. Relative resolution of the defects resulted in 39-59%. Despite a large median difference of 20%, no statistical significance between the groups was shown. This relates mostly to the high statistical variance within the groups. No power analysis could have been carried out before due to a lack of comparable data. However, a quite large sample of 12 dogs including 33 implants appeared to be an adequate

sample size as compared to other peri-implantitis dog studies. Not more than tendencies to an improved bone gain are pointing towards treatment methods with the use of air-polishing with obtained bone gain values of 53-59% as compared to procedures without. Surprisingly, the control group without any GBR-procedures (Debridement & Air-polishing) showed similar results to the DAG-group (Debridement & Air-polishing & GBR) and even better results compared to DG (Debridement & GBR) alone after 2 months of healing.

Two-dimensional area measurements of a predefined region of interest further mirrored results in terms of new bone formation. DA-group without any GBR procedures resulted in a mean of 47.8% of newly formed bone, while GBR groups showed only 19-27.9% of real new bone. Adding the remaining bone substitute particles in the region (11-21-5%) all groups show a similar distribution of augmented hard tissues and soft tissues. Some implants showed a partial tissue deficiency in the region of interest resulting in a clinical recession.

Findings without additional benefit of GBR procedures in peri-implantitis therapy in dogs were also described in a similar study comparing two antimicrobial protocols with and without GBR (26). Further Nociti et al. in 2000 and 2001 made the same observations concluding that GBR in peri-implantitis defects in dogs does not lead to significant advances in terms of new bone formation (27) (28). These findings stand in contrast to a study by Hürzeler et al. in 1997 where additional bone gain through GBR compared to no regeneration procedure was shown (17). It has always to be kept in mind that the present study is assessing buccal dehiscence defects while most other studies describe saucer-shaped defects (17) (27) (28), hindering a direct comparison.

As an important finding of this study, it was shown that the groups treated with a combination of bone regeneration procedures with bone substitute materials in the first weeks cause a higher degree of inflammation compared to no GBR-procedures. Leading to the conclusion that bone substitute particles lead to enhanced tissue inflammation in early wound healing. This process was considered a physiological reaction and to be subject of resolution during the following months. Inflammation scoring show findings of doubtful clinical significance. However, it can be shown that the pre-clinically usage of the experimental sterile powder during open surgical treatments is not causing any inflammation and can be verdict as safe.

Three implants have been excluded of the analysis (dog no. 10), as all have been described bad positioned outside the bony envelope. The implantation caused at several implantation sites a massive destruction of the buccal bone tissue due to rather small alveolar bone width at the time of implantation. The implant at this site was mainly surrounded by previously existing connective tissues but not surrounded by bone tissue. Hence, the reaction was deemed to be the result of an inadequate technical issue related to the dog mandibular bone and the implant/drill diameter rather than a material-related finding. This led to an impossible situation for bony regeneration, favoring fibrosis and inflammation in the healing. Weak points of the study are clearly the high statistical variance of the results despite the relatively high amount of test animals and the powerful within-subjects design, leading to statistical not significant and thus unfortunately not entirely conclusive result. Finally the authors suggest further research with air-polishing powders and GBR in human, as the use of air-polishing can be considered safe and does not hinder grafting procedures.

Conclusion

Within the limits of this animal study it can be concluded that:

- All treatment approaches resulted in a certain degree of bony regeneration of the buccal dehiscence.
- Air-polishing cleaning resulted in a tendency to a greater new bone healing as compared to no air-polishing, though not statistically significant.
- Considering inflammatory infiltrate after cleaning, no significant differences were found between the groups.
- Preclinical use of sterile air-polishing powder and a sterile delivery system in open surgical treatment around implants does not result in an immune reaction considered to be irritating and can thus be considered safe, as per ISO 10993-6:2016. Though augmentation procedures in previously-infected and exposed sites may cause more inflammatory response than cleaning alone during early healing.

Compliance with Ethical Standards

Conflict of Interest:

Author Alex Solderer declares that he has no conflict of interest.

Author Benjamin E. Pippenger declares that he works for Straumann, but has no conflict of interest.

Author Marcel Donnet declares that he works for EMS, but has no conflict of interest.

Author Daniel Wiedemeier declares that he has no conflict of interest.

Author Liza Ramenzoni declares that she has no conflict of interest.

Author Patrick Schmidlin declares that he has no conflict of interest.

Funding: The work was supported by the Clinic of Preventive Dentistry, Periodontology and Cariology, Center of Dental Medicine, University of Zurich.

The study was partially financed by Straumann and EMS.

Ethical approval: This study was performed in accordance with applicable US laws regarding the treatment of experimental animals and under the ethical approval number IACUC 16-BP-003. This study adheres to the ARRIVE Guidelines.

Informed consent: For this type of study, formal consent is not required.

Acknowledgements: We would like to thank Dr. Klaus Weber and Nils Warfving from AnaPath Institute, Switzerland for the histological processing and histopathological evaluation.

References

1. Buser, D., S. F. Janner, J. G. Wittneben, U. Brägger, C. A. Ramseier, and G. E. Salvi. 2012. 10-year survival and success rates of 511 titanium implants with a sandblasted and acid-etched surface: a retrospective study in 303 partially edentulous patients. *Clin Implant Dent Relat Res* 14: 839-851.
2. Chappuis, V., R. Buser, U. Brägger, M. M. Bornstein, G. E. Salvi, and D. Buser. 2013. Long-term outcomes of dental implants with a titanium plasma-sprayed surface: a 20-year prospective case series study in partially edentulous patients. *Clin Implant Dent Relat Res* 15: 780-790.
3. Berglundh, T., G. Armitage, M. G. Araujo, G. Avila-Ortiz, J. Blanco, P. M. Camargo, S.

- Chen, D. Cochran, J. Derks, E. Figuero, C. H. F. Hämmerle, L. J. A. Heitz-Mayfield, G. Huynh-Ba, V. Iacono, K. T. Koo, F. Lambert, L. McCauley, M. Quirynen, S. Renvert, G. E. Salvi, F. Schwarz, D. Tarnow, C. Tomasi, H. L. Wang, and N. Zitzmann. 2018. Peri-implant diseases and conditions: Consensus report of workgroup 4 of the 2017 World Workshop on the Classification of Periodontal and Peri-Implant Diseases and Conditions. *J Periodontol* 89 Suppl 1: S313-S318.
4. Schwarz, F., J. Derks, A. Monje, and H.-L. Wang. 2018. Peri-implantitis. *Journal of Clinical Periodontology* 45: S246-S266.
 5. Anitua, E., L. Piñas, L. Begoña, and M. H. Alkhraisat. 2017. Prognosis of Dental Implants Immediately Placed in Sockets Affected by Peri-implantitis: A Retrospective Pilot Study. *Int J Periodontics Restorative Dent* 37: 713-719.
 6. Manor, Y., G. Chaushu, A. Lorean, and E. Mijiritzky. 2015. A Retrospective Analysis of Dental Implants Replacing Failed Implants in Grafted Maxillary Sinus: A Case Series. *International Journal of Oral & Maxillofacial Implants* 30: 1156-1160.
 7. Derks, J., and C. Tomasi. 2015. Peri-implant health and disease. A systematic review of current epidemiology. *J Clin Periodontol* 42 Suppl 16: S158-71.
 8. Lang, N. P., T. Berglundh, and G. O. S. E. W. O. P. Working. 2011. Periimplant diseases: where are we now?--Consensus of the Seventh European Workshop on Periodontology. *J Clin Periodontol* 38 Suppl 11: 178-181.
 9. Khoury, F., P. L. Keeve, A. Ramanauskaite, F. Schwarz, K. T. Koo, A. Sculean, and G. Romanos. 2019. Surgical treatment of peri-implantitis - Consensus report of working group 4. *Int Dent J* 69 Suppl 2: 18-22.
 10. Heitz-Mayfield, L. J., and A. Mombelli. 2014. The therapy of peri-implantitis: a systematic review. *Int J Oral Maxillofac Implants* 29 Suppl: 325-345.
 11. Schwarz, F., K. Becker, K. D. Bastendorf, D. Cardaropoli, C. Chatfield, I. Dunn, P. Fletcher, J. Einwag, A. Louropoulou, A. Mombelli, P. Ower, P. Pavlovic, P. Sahrman, G. E. Salvi, P. Schmage, Y. Takeuchi, F. Van Der Weijden, and S. Renvert. 2016. Recommendations on the clinical application of air polishing for the management of peri-implant mucositis and peri-implantitis. *Quintessence Int* 47: 293-296.
 12. Taschieri, S., R. Weinstein, M. Del Fabbro, and S. Corbella. 2015. Erythritol-Enriched Air-Polishing Powder for the Surgical Treatment of Peri-Implantitis. *ScientificWorldJournal* 2015: 802310.
 13. van Loon, J., and P. Mars. 1997. Biocompatibility: the latest developments. *Med Device Technol* 8: 20-24.
 14. Ronay, V., A. Merlini, T. Attin, P. R. Schmidlin, and P. Sahrman. 2017. In vitro cleaning potential of three implant debridement methods. Simulation of the non-surgical approach. *Clin Oral Implants Res* 28: 151-155.
 15. Keim, D., K. Nickles, B. Dannewitz, C. Ratka, P. Eickholz, and H. Petsos. 2019. In vitro efficacy of three different implant surface decontamination methods in three different defect configurations. *Clin Oral Implants Res* 30: 550-558.
 16. Quintero, D. G., R. B. Taylor, M. B. Miller, K. R. Merchant, and S. A. Pasieta. 2017. Air-Abrasive Disinfection of Implant Surfaces in a Simulated Model of Periimplantitis. *Implant Dentistry* 26: 423-428.
 17. Hurzeler, M. B., C. R. Quinones, P. Schupback, E. C. Morrison, and R. G. Caffesse. 1997. Treatment of peri-implantitis using guided bone regeneration and bone grafts, alone or in combination, in beagle dogs. Part 2: Histologic findings. *International Journal of Oral & Maxillofacial Implants* 12: 168-175.
 18. Petersilka, G. J. 2011. Subgingival air-polishing in the treatment of periodontal biofilm infections. *Periodontol 2000* 55: 124-142.
 19. Schwarz, F., D. Ferrari, K. Popovski, B. Hartig, and J. Becker. 2009. Influence of different air-abrasive powders on cell viability at biologically contaminated titanium

- dental implants surfaces. *J Biomed Mater Res B Appl Biomater* 88: 83-91.
20. Zitzmann, N. U., T. Berglundh, I. Ericsson, and J. Lindhe. 2004. Spontaneous progression of experimentally induced periimplantitis. *J Clin Periodontol* 31: 845-849.
 21. Berglundh, T., K. Gotfredsen, N. U. Zitzmann, N. P. Lang, and J. Lindhe. 2007. Spontaneous progression of ligature induced peri-implantitis at implants with different surface roughness: an experimental study in dogs. *Clinical Oral Implants Research* 18: 655-661.
 22. Lindhe, J., T. Berglundh, I. Ericsson, B. Liljenberg, and C. Marinello. 1992. Experimental breakdown of peri-implant and periodontal tissues. A study in the beagle dog. *Clin Oral Implants Res* 3: 9-16.
 23. Schwarz, F., M. Herten, M. Sager, K. Bieling, A. Sculean, and J. Becker. 2007. Comparison of naturally occurring and ligature-induced peri-implantitis bone defects in humans and dogs. *Clinical Oral Implants Research* 18: 161-170.
 24. Fickl, S., M. Kebschull, J. L. Calvo-Guirado, M. Hurzeler, and O. Zuhr. 2015. Experimental Peri-Implantitis around Different Types of Implants - A Clinical and Radiographic Study in Dogs. *Clinical Implant Dentistry & Related Research* 17 Suppl 2: e661-9.
 25. Sanz-Esporrin, J., J. Blanco, J. V. Sanz-Casado, F. Muñoz, and M. Sanz. 2019. The adjunctive effect of rhBMP-2 on the regeneration of peri-implant bone defects after experimental peri-implantitis. *Clin Oral Implants Res*
 26. Ramos, U. D., F. A. Suaid, U. M. E. Wikesjo, C. Susin, M. Taba, Jr., and A. B. Novaes, Jr. 2017. Comparison between two antimicrobial protocols with or without guided bone regeneration in the treatment of peri-implantitis. A histomorphometric study in dogs. *Clinical Oral Implants Research* 28: 1388-1395.
 27. Nociti, F. H., Jr., R. G. Caffesse, E. A. Sallum, M. A. Machado, C. M. Stefani, and A. W. Sallum. 2000. Evaluation of guided bone regeneration and/or bone grafts in the treatment of ligature-induced peri-implantitis defects: a morphometric study in dogs. *Journal of Oral Implantology* 26: 244-249.
 28. Nociti, F. H., Jr., M. A. Machado, C. M. Stefani, E. A. Sallum, and A. W. Sallum. 2001. Absorbable versus nonabsorbable membranes and bone grafts in the treatment of ligature-induced peri-implantitis defects in dogs. Part I. A clinical investigation. *Clinical Oral Implants Research* 12: 115-120.

Tables

Table 1:

Cumulative inflammation after different treatments according ISO 10993-6:2016(E) comparing the different treatments (for further details we refer to the respective Materials & Methods section).

Treatment groups	Debridement + GBR (DG)		Debridement + air-polishing + GBR (DAG)		Air-polishing + GBR (AG)		Debridement + air-polishing (DA)	
	Buccal	Lingual	Buccal	Lingual	Buccal	Lingual	Buccal	Lingual
Cumulative score	60	33	73.7	36.5	93.5	51.5	46	42
Group total	7	7	9	9	10	10	8	8
Average score	8.6	4.7	8.2	4.1	9.4	5.2	5.8	5.3

Table 2:

Cumulative score of inflammatory cells in each group at the buccal (augmented) sites according to ISO 10993-6:2016(E).

		Treatment			
		DG	DAG	AG	DA
1	Polymorphonuclear cells	0.1	0.1	0.3	0
2	Lymphocytes	1	1.1	1.3	0.4
3	Plasma cells	0	0	0	0
4	Macrophages	0.1	0.1	0.1	0

Table 3:

Measurements of the defect depths (A) and the respective absolute bone (B) in mm as well as the relative bone gain (B/A) in percent according to figure 3 (median and IQR (in brackets) are presented for each group).

Group	DG (n=7)	DAG (n=9)	AG (n=9)	DA (n=8)	p-Wert (stat. sig.)
A Defect depth (mm)	4.0 (1.8)	4.5 (2.5)	4.5 (1.0)	3.5 (2.3)	n.s.
B Bone gain (mm)	1.21 (0.94)	1.98 (0.90)	2.65 (2.45)	1.73 (1.05)	n.s.
Relative bone gain (%)	39% (34)	53% (17)	59% (44)	53% (29)	n.s.

Table 4: Mean (SD) + Median (IQR) – values in % for the prevalence of histologic measurements in the predefined region of interest (rounded to the first decimal digit after the comma). Significancy assessed through Wilcoxon’s signed rank test.

Group	DG (n=7)	DAG (n=9)	AG (n=9)	DA (n=8)	p-Wert (stat. sig.)
Substitute Material (%)	14.2 (6.6) 14.8 (5.1)	11.0 (8.0) 9.6 (5.7)	21.5 (12.3) 24.6 (15.2)	NA	n.s.
Bone tissue (%)	19.0 (10.9) 22.3 (17.3)	27.9 (14.4) 27.2 (18.7)	19.8 (13.2) 21.4 (23.4)	47.8 (22.6) 50.2 (27.3)	n.s.
Soft Tissue (%)	61.9 (11.8) 57.0 (16.3)	52.9 (19.5) 56.9 (23.7)	55.7 (12.8) 53.7 (13.6)	53.6 (18.6) 48.5 (16.3)	n.s.
Tissue deficiency (%)	4.8 (10.4) 0.0 (3.7)	8.2 (12.1) 0.0 (14.1)	3.0 (5.1) 0.0 (4.0)	2.3 (3.5) 0.0 (4.6)	n.s.

Figures

Figure 1:

Flow-chart of the experimental conditions and procedures.

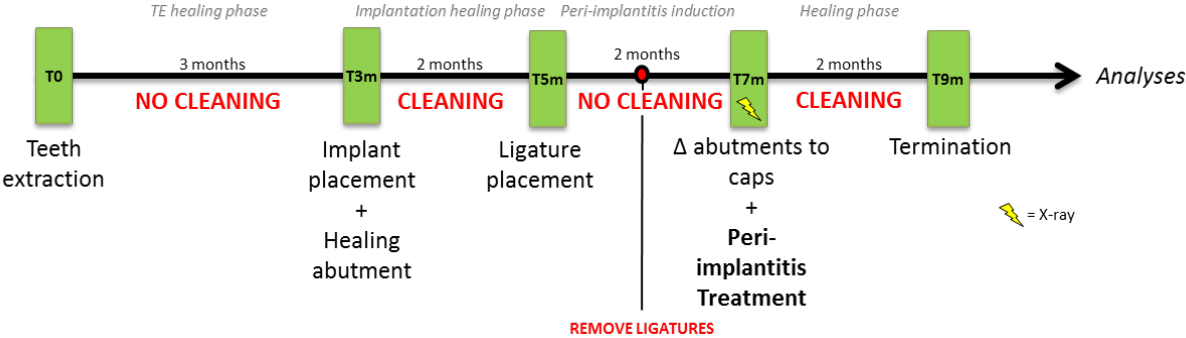


Figure 2:

Representative clinical images of the performed treatments at the recession-type defects buccally after flap elevation and cleaning (A) Afterwards, the membrane was placed and secured at the lingual aspect (B) and the implant surfaces and defects were buccally filled with a xenograft (C). The membrane was adapted to cover the augmented sites (D), the periosteum was released and the site was closed for primary intention healing.

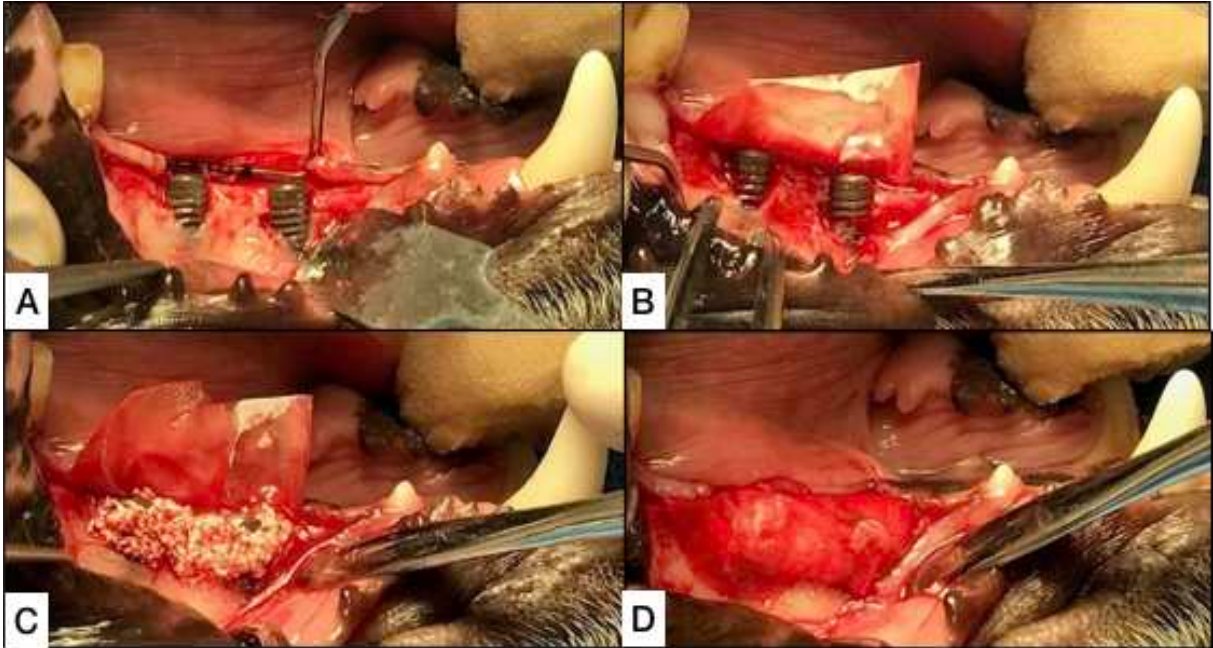


Figure 3:

Histologic example and schematic illustration of the measurements. The green area elucidates the new bone. **A**: Buccal defect depth before treatment. **B** Height of the newly formed bone after therapy (BIC).

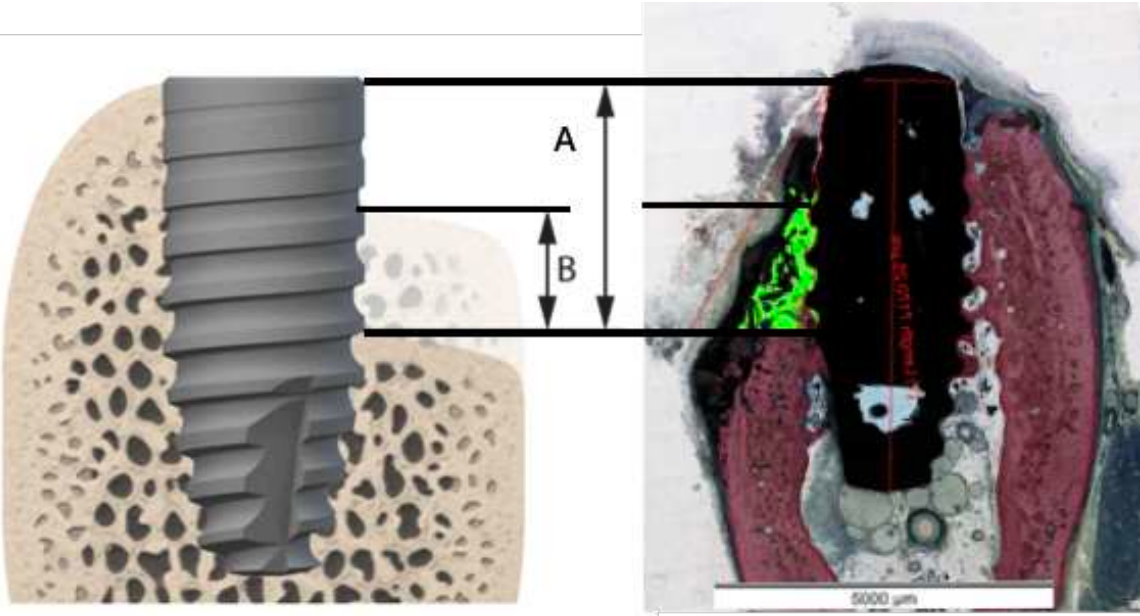


Figure 4:

Representative histologies of the buccal aspect for each treatment group:
A. Debridement & GBR B. Air-polishing & GBR C. Debridement Air-polishing & GBR
D. Debridement & Air-polishing

