



**University of  
Zurich**<sup>UZH</sup>

**Zurich Open Repository and  
Archive**

University of Zurich  
University Library  
Strickhofstrasse 39  
CH-8057 Zurich  
[www.zora.uzh.ch](http://www.zora.uzh.ch)

---

Year: 2020

---

## **Nonoperative Treatment of Anterior Glenoid Rim Fractures After First-Time Traumatic Anterior Shoulder Dislocation: A Study with 9-Year Follow-up**

Wieser, Karl ; Waltenspül, Manuel ; Ernstbrunner, Lukas ; Ammann, Elias ; Nieuwland, Arend ; Eid, Karim ; Gerber, Christian

DOI: <https://doi.org/10.2106/JBJS.OA.20.00133>

Posted at the Zurich Open Repository and Archive, University of Zurich

ZORA URL: <https://doi.org/10.5167/uzh-199409>

Journal Article

Published Version



The following work is licensed under a Creative Commons: Attribution-NonCommercial-NoDerivatives 4.0 International (CC BY-NC-ND 4.0) License.

Originally published at:

Wieser, Karl; Waltenspül, Manuel; Ernstbrunner, Lukas; Ammann, Elias; Nieuwland, Arend; Eid, Karim; Gerber, Christian (2020). Nonoperative Treatment of Anterior Glenoid Rim Fractures After First-Time Traumatic Anterior Shoulder Dislocation: A Study with 9-Year Follow-up. *JBJS Open Access*, 5(4):e20.00133.

DOI: <https://doi.org/10.2106/JBJS.OA.20.00133>

# Nonoperative Treatment of Anterior Glenoid Rim Fractures After First-Time Traumatic Anterior Shoulder Dislocation

A Study with 9-Year Follow-up

Karl Wieser, MD\*, Manuel Waltenspül, MD\*, Lukas Ernstbrunner, MD, PhD, Elias Ammann, MD, Arend Nieuwland, MD, Karim Eid, MD, and Christian Gerber, MD

*Investigation performed at the Balgrist University Hospital, Zurich; and Kantonsspital Baden, Baden, Switzerland*

**Background:** Primary traumatic anterior shoulder dislocations can be associated with displaced anterior glenoid rim fractures. Nonoperative treatment of such fractures has been shown to have excellent results in a small cohort of patients; as such, we have been treating these fractures nonoperatively, regardless of fragment size and degree of displacement, provided that post-reduction computed tomography scans revealed an anteroposteriorly centered humeral head. The aim of this study was to analyze the medium- to long-term results of nonoperative treatment of displaced anterior glenoid rim fractures, assessing in particular the residual instability and development of osteoarthritis.

**Methods:** In a 2-center study, 30 patients with a mean age of 48 years (range, 29 to 67 years) were evaluated clinically with use of the Subjective Shoulder Value, Constant score, American Shoulder and Elbow Surgeons score, and Western Ontario Shoulder Instability index, as well as radiographically with use of radiographs and computed tomography scans at a mean follow-up of 9 years (range, 5 to 14 years).

**Results:** Fracture-healing was documented in all patients. Seven patients (23%) had post-fracture onset of osteoarthritis (5 with Samilson grade I and 2 with Samilson grade IV). Of these, 1 patient had recurrent instability that was successfully treated with hemiarthroplasty 9 years after the index injury (relative Constant score, 101%), and was excluded from further analysis. No other patient had a recurrent redislocation, subluxation, or positive apprehension. The other 6 patients with new-onset radiographic osteoarthritis were pain-free (mean Constant score pain scale, 15 points) with good shoulder function (relative Constant score, 84% to 108%). A total of 26 patients (90%) rated their functional outcome as good or very good, and 3 patients (10%) rated it as fair. The mean relative Constant score was 97% (range, 61% to 108%), the mean American Shoulder and Elbow Surgeons score was 92 points (range, 56 to 100 points), and the mean Western Ontario Shoulder Instability index score was 126 points (range, 0 to 660 points). All patients returned to full-time work.

**Conclusions:** Nonoperative treatment of anterior glenoid rim fractures following primary traumatic anterior shoulder dislocation results in excellent clinical outcomes with a very low rate of residual instability and, thus, treatment failure. Asymptomatic radiographic osteoarthritis occurred in roughly 1 of 4 patients.

**Level of Evidence:** Therapeutic Level IV. See Instructions for Authors for a complete description of levels of evidence.

Primary traumatic anterior shoulder dislocation can be associated with displaced fractures of the anterior glenoid rim<sup>1,2</sup>. Such fractures occur in up to 21% of traumatic shoulder dislocations<sup>3</sup> and are classified as either Ideberg type IA if the fragment is  $\leq 5$  mm or type IB if it is  $>5$  mm<sup>4</sup>. Ideberg type-IA fractures, or so-called chip fractures, can be treated nonoperatively<sup>5</sup>, although there is a growing trend toward surgical stabilization of these fractures in young and active

\*Karl Wieser, MD, and Manuel Waltenspül, MD, contributed equally to this work.

**Disclosure:** The authors indicated that no external funding was received for any aspect of this work. The **Disclosure of Potential Conflicts of Interest** forms are provided with the online version of the article (<http://links.lww.com/JBJSOA/A235>).

Copyright © 2020 The Authors. Published by The Journal of Bone and Joint Surgery, Incorporated. All rights reserved. This is an open-access article distributed under the terms of the [Creative Commons Attribution-Non Commercial-No Derivatives License 4.0](https://creativecommons.org/licenses/by-nc-nd/4.0/) (CCBY-NC-ND), where it is permissible to download and share the work provided it is properly cited. The work cannot be changed in any way or used commercially without permission from the journal.

first-time dislocators<sup>6-8</sup>. Conversely, the treatment of Ideberg type-IB fractures, which predominantly occur in patients between 30 and 59 years old, remains controversial. For anterior glenoid rim fractures with a fracture fragment of >5 mm<sup>9,10</sup> or with fragment displacement of >5 mm<sup>11,12</sup>, surgical reduction and fixation is often suggested. Despite a lack of evidence of superiority over nonoperative treatment, many believe that surgical treatment is necessary to regain anatomic reduction because it reduces the risk of recurrent instability and posttraumatic osteoarthritis (OA). Nonoperative treatment of larger displaced glenoid rim fragments, however, has led to excellent results in 14 consecutive patients at a mean follow-up of 5.6 years<sup>13</sup>, with all patients showing a stable, pain-free, and functional shoulder without recurrent instability or other complications. Accordingly, at our clinic, anterior glenoid rim fractures are treated nonoperatively regardless of fragment size and degree of displacement as long as post-reduction computed tomography (CT) scans reveal anteroposterior centering of the humeral head on the glenoid (i.e., the humeral head does not follow the displaced fragment) (Fig. 1). The aim of the present study was to analyze the medium- to long-term results of a consecutive series of patients following nonoperative treatment of an anterior glenoid rim fracture, with particular attention paid to recurrent instability and development

of OA. We hypothesized that nonoperative treatment would lead to similar or superior results compared with surgical reduction and refixation of large anterior glenoid rim fractures subsequent to primary traumatic anterior shoulder dislocation.

### Materials and Methods

**E**thical approval for this study was granted by the responsible review board, and written informed consent was attained from all patients.

Patients were included who were ≥18 years old, had a primary traumatic anterior shoulder dislocation with a displaced Ideberg type-IB anterior glenoid rim fracture and a centered humeral head post-reduction, and underwent nonoperative treatment in the 2 orthopaedic departments participating in the study.

Patients were excluded who had associated injuries such as fractures of the tuberosities, the proximal aspect of the humerus, or the coracoid, or who had concomitant clinically evident large rotator-cuff injuries, neurological disorders (e.g., uncontrolled epilepsy or post-poliomyelitis syndrome).

### Nonoperative Treatment

If the humeral head was anteroposteriorly centered in the glenohumeral joint post-reduction, nonoperative treatment with a sling

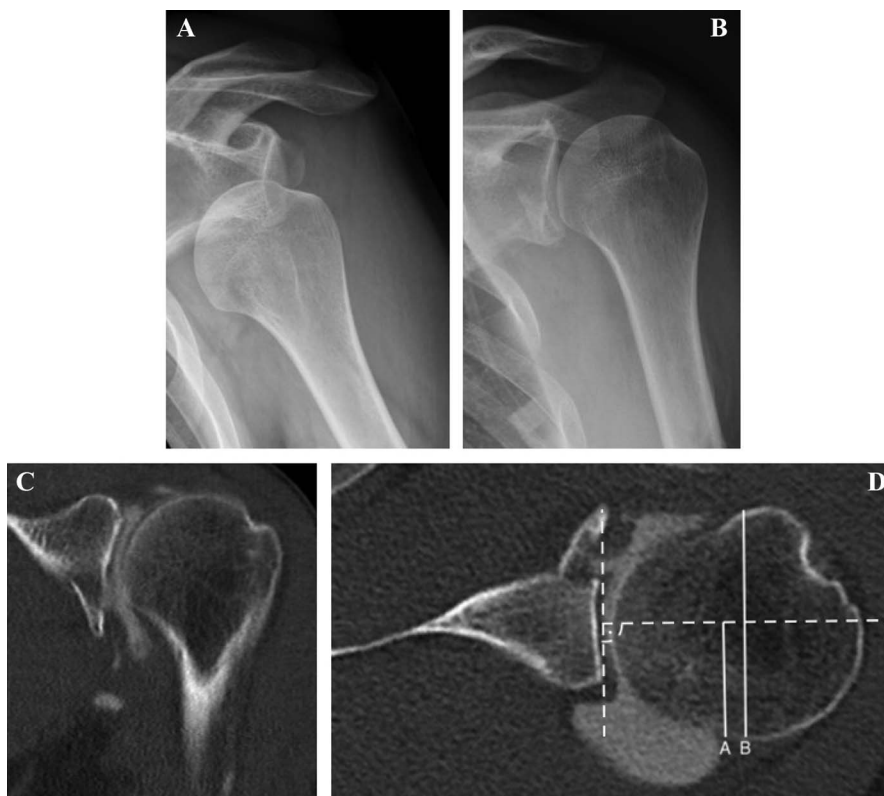

Fig. 1

**Figs. 1-A and 1-B** Radiographs showing the humeral head centered on the glenoid following reduction of glenohumeral dislocation. Radiographs made prior to (**Fig. 1-A**) and following (**Fig. 1-B**) reduction of the glenohumeral joint, with the glenoid rim fracture already visible. **Figs. 1-C and 1-D** CT arthrogram showing a dislocated anterior glenoid rim fracture and centered humeral head with an index of 52% following reduction. An index between 45% and 55% indicates a well-centered humeral head<sup>26</sup>.

was initiated for a maximum of 4 weeks. On a daily basis, patients underwent active-assisted and passive glenohumeral mobilization, as well as daily pendulum exercises; in addition, physiotherapy was performed twice weekly. Combined abduction and external rotation was disallowed for the first 3 months after the injury.

### Patients

From 2005 to 2014, a total of 48 patients were identified who met the inclusion criteria. Six of these patients would have qualified for nonoperative treatment following diagnostic imaging, but these patients instead underwent a surgical procedure at external institutions. Seven of the remaining 42 patients could only be contacted by email or telephone interview; as such, these patients were included in the instability and reoperation assessments but excluded from the radiographic and functional analyses. None had any complaints related to the injured shoulder, and none reported recurrent dislocation following the initial trauma. An additional 4 patients could not be traced, and 1 patient died during the follow-up period without having reported any additional shoulder problems. The remaining 30 patients, including 6 women and 24 men with a mean age of 48 years (range, 29 to 67 years) at the time of trauma, were assessed clinically and radiographically. There was an equal distribution of left and right shoulders (15 each), and 19 patients had injured their dominant shoulder. Two patients had a history of rotator cuff repair and acromioplasty, but no previous shoulder instability. Cross-sectional imaging was available in all but 1 patient at the time of the injury. For evaluation of the fracture fragment, imaging was assessed for fracture localization, fragment size, and extent of displacement at the time of the injury, including CT scans in 27 patients, magnetic resonance imaging (MRI) in 2 patients, and radiographs only in 1 patient.

Follow-up clinical examination included assessment of the absolute and relative Constant scores (CS), American Shoulder and Elbow Surgeons (ASES) score, Western Ontario Shoulder Instability index (WOSI), and Subjective Shoulder Value (SSV). The standard shoulder examination was performed with a particular focus on stability, which included subjective instability, objective instability with anterior and posterior apprehension tests, and active and passive range of motion.

Radiographic follow-up evaluation included conventional radiographs (i.e., anteroposterior, Neer, and axial views) and CT scans (nominal single collimation width of 2 mm; SIEMENS SOMATOM Edge Plus). Both radiographs and CT scans were evaluated for glenohumeral OA according to the modified Samilson and Prieto classification<sup>14</sup> at the time of the injury and at follow-up. Additionally, CT scans were analyzed for fracture alignment, reduction, and consolidation.

### Statistical Analysis

Data were assessed for normal distribution with use of the Shapiro-Wilk test. Accordingly, functional scores were compared with the contralateral shoulder with use of the Wilcoxon signed-rank test. The Fisher exact test was utilized for categorical variables ( $n < 5$ ). Significance was set at 0.05.

### Results

The mean follow-up was 9 years (range, 5 to 14 years). No additional surgical procedures were reported in 36 (97%) of the 37 patients included in the analysis of instability and reoperation. One patient had OA (Samilson grade IV) secondary to recurrent instability, which was successfully treated with hemiarthroplasty 9 years after the initial trauma. This patient was excluded from further analysis despite showing excellent clinical outcomes (relative CS, 101%, and SSV, 90%). Among the 29 patients included in the clinical and radiographic analysis, there were no cases of recurrent instability (dislocation or subluxation) or positive apprehension tests. Active range of motion was very good in all patients, with a mean CS mobility score of 37 out of a possible 40 (Table I). Compared with the contralateral side, there were no differences in passive range of motion, with a mean glenohumeral abduction of 87° (range, 80° to 100°) and external rotation in abduction of 60° (range, 20° to 90°) ( $p = 0.317$  and  $p = 0.773$ , respectively). The mean relative CS was 97% (range, 61% to 108%), the mean ASES score was 92 points (56 to 100 points), and the mean WOSI was 126 points (range, 0 to 660 points). All patients returned to full-time work, including 10 patients (34%) who reported working

TABLE I Clinical Results at the Time of the Latest Follow-up\*

No. of patients	29
CS†	
Absolute (points)	88.0 ± 11.9
Relative (%)	96.6 ± 10.3
Pain (points)	14.1 ± 1.5
Mobility (points)	37.2 ± 3.8
SSV† (%)	90.2 ± 13.5
Shoulder range of motion† (°)	
Active anterior elevation	165 ± 10
Abduction	160 ± 20
External rotation	60 ± 15
Satisfaction‡	
Very good	22 (76%)
Good	4 (14%)
Fair	3 (10%)
Unsatisfactory	0 (0%)
WOSI† (points)	125.6 ± 182.2
ASES† (points)	92.1 ± 10.8
Apprehension sign‡	0 (0%)

\*Results exclude 1 patient who underwent hemiarthroplasty for recurrent instability secondary to OA. †The values are given as the mean and standard deviation. ‡The values are given as the number of patients, with the percentage in parentheses.

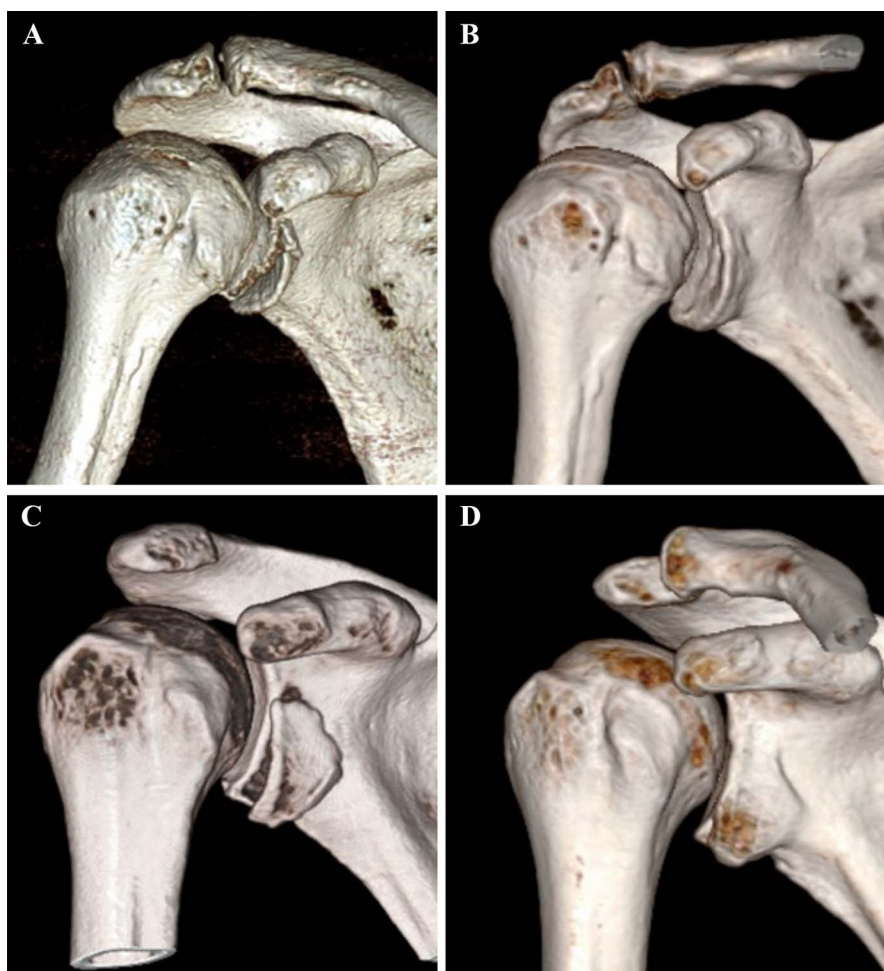


Fig. 2

**Figs. 2-A to 2-D** CT scans showing reduction (or remodeling) of the anterior glenoid rim fragment over time following nonoperative treatment in 2 different patients. **Figs. 2-A and B** A large, comminuted fragment healed over time without a step-off. **Figs. 2-C and 2-D** A large, displaced glenoid rim fracture immediately and 6 years after the injury with a nearly normally shaped glenoid rim.

heavy labor jobs (e.g., farmer or mechanic). Twenty-two patients rated their shoulder function as very good (76%), 4 as good (14%), and 3 as fair (10%). The 3 patients who reported fair function also presented with signs of a rotator cuff injury (by a positive Jobe test), with no signs of glenohumeral instability or of new-onset OA (relative CS, 84%, 61%, and 70%; ASES, 78, 56, and 73 points; and WOSI, 660, 543, and 556 points).

The mean maximum posttraumatic fragment displacement on initial imaging was 8 mm (range, 3 to 20 mm). The mean maximum fragment diameter ranged from 8 to 30 mm. Radiographic analysis at the time of latest follow-up showed fracture union in all patients. Complete reduction or remodeling of the fragment with no or little irregularity at the articular fracture zone was observed in 23 patients (79%), and partial reduction with a step-off of  $\leq 5$  mm was observed in the remaining 7 cases (24%) (Fig. 2). The difference between the mean maximum displacement of the fragment and the reduced, healed fragment on the latest CT scan was 6 mm (range, 1 to 17 mm).

In addition to the patient who underwent hemiarthroplasty for recurrent instability, 6 other patients (for a total 7 of 30, 23%) showed radiographic evidence of new-onset OA, including 5 Samilson grade I and 1 Samilson grade IV. All of these patients reported having good shoulder function (relative CS, 84% to 108%) and no pain on the CS pain scale (mean, 15 points).

Furthermore, 2 patients with preexisting signs of OA showed progression of OA by 1 grade each (from Samilson grade I to II and grade III to IV) during the follow-up period. The patient with grade-II OA was asymptomatic with no pain. The other patient had known rotator cuff arthropathy with a history of 2 prior surgical procedures, and had a relative CS of 61% and a CS pain scale of 10 points. This was the only patient with symptomatic OA in the cohort. No significant association was found between fragment displacement (i.e., nonanatomic reduction) and onset or progression of OA ( $p = 0.295$ ).



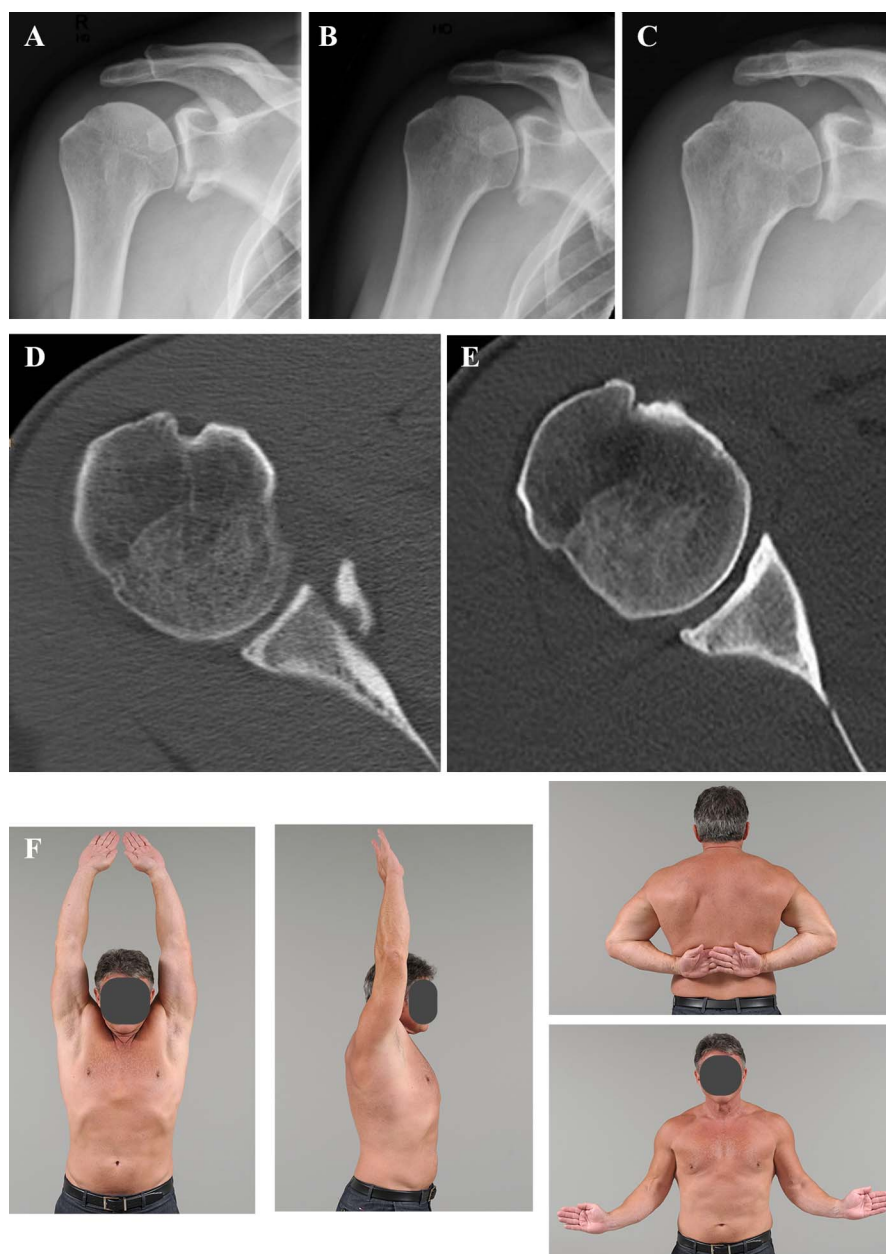


Fig. 3

**Figs. 3-A to 3-F** Radiographs, CT scans, and photographs of a patient who had reduction of a glenoid rim fragment via nonoperative treatment. **Figs. 3-A, 3-B, and 3-C** Radiographs made immediately following (**Fig. 3-A**) and at 2 years (**Fig. 3-B**) and 10 years (**Fig. 3-C**) after traumatic glenohumeral dislocation. Partial reduction and complete reduction and remodeling can be seen in **Figures 3-B and 3-C**, respectively. **Figs. 3-D and 3-E** CT scans made immediately following (**Fig. 3-D**) and at 10 years after (**Fig. 3-E**) traumatic glenohumeral dislocation. Complete reduction and remodeling can be seen in **Figure 3-E**. **Fig. 3-F** Photographs showing the patient at 10 years after the injury, with free active overhead function, active external rotation, and active internal rotation. Relative CS, 108%; SSV, 100%; WOSI, 0 points; and ASES, 0 points.

### Discussion

In the present study, nonoperative treatment of displaced Ideberg type-IB fractures following primary traumatic anterior shoulder dislocation was shown to have excellent functional outcomes, a low rate of recurrent instability (3%), and a low rate of new-onset OA (23%), in cases in which the humeral head was centered post-reduction.

The results of the present study are consistent with those of another study conducted at our institution<sup>13</sup>. In that study by Maquieira et al., a smaller cohort of 14 patients with an anterior glenoid rim fracture demonstrated excellent clinical function with no redislocation at a mean follow-up at 5.6 years after nonoperative treatment. Despite these published results and the lack of evidence of superiority, there is an ongoing trend

toward surgical treatment of such fractures. Many shoulder surgeons believe that a surgical procedure is necessary to regain anatomic reduction, supposedly reducing the risk of recurrent instability and posttraumatic OA<sup>9,15,16</sup>. Surgical refixation of the fragment can be achieved via either open or arthroscopic approaches, but may result in some functional impairment<sup>9,17</sup> and, rarely, in other complications such as chronic pain, nerve palsy, infections, or early onset of posttraumatic or even iatrogenic OA<sup>9,15,18–20</sup>. Furthermore, the main theoretical advantage of surgical fixation for achieving anatomic reduction must be questioned, as our radiographic results of nonoperatively treated and sometimes severely displaced rim fractures show a high potential for self-reduction and/or remodeling (Fig. 3).

Nonoperative treatment was carried out with use of a sling and therefore in internal rotation. Itoi et al.<sup>21</sup> have recommended external rotation to obtain better healing of the anterior capsule to the scapular neck. In a displaced fracture, there is typically no evidence that the capsule is detached from the relatively large osseous fragment. Thus, it can be theorized that the transient capsular shrinkage, which is associated with the healing process and clinically expressed in posttraumatic transient decreased passive external rotation, assists in reducing the fragment. It is most likely, however, that over longer periods of time, the glenoid also undergoes remodeling processes. Hence, how much of the ultimate anatomic result is the result of reduction or remodeling remains uncertain.

Compared with the published data on arthroscopically treated patients, the radiographic results of the present study are at least comparable, if not superior. In the largest published cohort, 7 (33%) of 21 arthroscopically treated rim fractures showed an average residual postoperative step-off of 2 mm, with an overall osteoarthritis rate of almost 30% and with 3 cases (14%) graded as severe OA<sup>9</sup>. Interestingly, the authors reported that a non-perfect anatomic reduction with a postoperative step-off was not associated with a significantly increased OA rate, which is in accordance with the results of the present study. Therefore, it seems that the risk of degenerative changes is associated with the traumatic event itself (i.e., fracture-dislocation) rather than with nonanatomic fracture consolidation, and might even be amplified by surgical refixation. Intra-articular injury at the time of trauma is a well-known risk factor for the development of OA<sup>22</sup>. During articular trauma, severe shear and compressive forces on the articular surface create fractures through the cartilage matrix, leading to separation of cartilage and bone fragments from the underlying subchondral bone<sup>23</sup>. As hyaline cartilage has a limited capacity for intrinsic healing and repair<sup>24</sup> and because trauma-induced inflammatory responses lead to further erosion of cartilage, the development of OA seems inevitable<sup>25</sup>. Additional trauma by surgical treatment itself might even accelerate this process.

In contrast with the typically young population of patients with shoulder instability, glenoid rim fractures are seen predominantly in elderly patients<sup>5</sup>. Compared with the cohort of surgically managed patients in the study by Scheibel et al., the

mean age in the present study was greater, which reflects the natural occurrence of glenoid fractures<sup>9</sup>. Fractures of the glenoid are most commonly seen in patients  $\geq 40$  years old. Nevertheless, one third (33%) of patients in the present study were injured at  $< 40$  years old. Even these younger patients showed no signs of recurrent instability during the follow-up period and were able to return to their normal level of physical activity.

This study had some potential limitations. It was a retrospective, single-arm analysis with the lack of a proper control group. Results were compared with published studies of surgically treatment, and thus differences between results should be interpreted carefully. Twelve of 42 patients could not be clinically examined after a mean follow-up of 9 years; however, 7 of these patients could be contacted via telephone and/or email, and we were able to verify that none experienced a complication or underwent a revision surgical procedure. Furthermore, the results of the present study were only valid for humeral heads that were centered after reduction as verified on CT or MRI. Anterior humeral head subluxation following reduction seemed to play an important role in the development of recurrent instability and OA. This relationship was also shown in the study by Maquieira et al., in which mild to moderate OA was observed in 3 of 14 cases with humeral head subluxation<sup>13</sup>. On the basis of those results, we now consider humeral head subluxation to be a contraindication for nonoperative treatment. However, in the present study, we observed only 3 decentered humeral heads following reduction, accounting for far less than 10% of all fractures. Remarkably, we did not observe any cases of secondary static subluxation in this study; an initially centered humeral head remained centered during the follow-up period in all patients.

Despite these limitations, to our knowledge, this study has the largest cohort and longest follow-up of nonoperatively treated Ideberg Type-IB anterior glenoid rim fractures following primary traumatic anterior shoulder dislocation.

### Conclusions

Nonoperative treatment of anterior glenoid rim fractures following primary traumatic anterior shoulder dislocation leads to excellent clinical results with a very low rate of recurrent instability and treatment failure (3%). Radiographic OA occurred in roughly 1 of 4 patients and was consistently asymptomatic. ■

Note: The authors thank the Swiss Center for Musculoskeletal Imaging, SCMI, Balgrist Campus AG, Zürich, for their support performing imaging.

Karl Wieser, MD<sup>1</sup>  
Manuel Waltenspül, MD<sup>1</sup>  
Lukas Ernstbrunner, MD, PhD<sup>1</sup>  
Elias Ammann, MD<sup>2</sup>  
Arend Nieuwland, MD<sup>1</sup>  
Karim Eid, MD<sup>2</sup>  
Christian Gerber, MD<sup>1</sup>

<sup>1</sup>Department of Orthopaedics, Balgrist University Hospital, University of Zurich, Zurich, Switzerland

<sup>2</sup>Department of Orthopaedics, Kantonsspital Baden, Baden, Switzerland

Email address for M. Waltenspül: [manuel.waltenspuel@balgrist.ch](mailto:manuel.waltenspuel@balgrist.ch)

ORCID iD for K. Wieser: [0000-0001-8495-6189](https://orcid.org/0000-0001-8495-6189)

ORCID iD for M. Waltenspül: [0000-0002-8192-0233](https://orcid.org/0000-0002-8192-0233)

ORCID iD for L. Ernstbrunner: [0000-0003-4920-8518](https://orcid.org/0000-0003-4920-8518)

ORCID iD for E. Ammann: [0000-0003-0860-2666](https://orcid.org/0000-0003-0860-2666)

ORCID iD for A. Nieuwland: [0000-0001-5676-6839](https://orcid.org/0000-0001-5676-6839)

ORCID iD for K. Eid: [0000-0002-1140-2983](https://orcid.org/0000-0002-1140-2983)

ORCID iD for C. Gerber: [0000-0002-4624-8285](https://orcid.org/0000-0002-4624-8285)

## References

- Bigliani LU, Newton PM, Steinmann SP, Connor PM, McIlveen SJ. Glenoid rim lesions associated with recurrent anterior dislocation of the shoulder. *Am J Sports Med.* 1998Jan-Feb;26(1):41-5.
- Schandelmaier P, Blauth M, Schneider C, Krettek C. Fractures of the glenoid treated by operation. A 5- to 23-year follow-up of 22 cases. *J Bone Joint Surg Br.* 2002Mar;84(2):173-7.
- Griffith JF, Antonio GE, Yung PS, Wong EM, Yu AB, Ahuja AT, Chan KM. Prevalence, pattern, and spectrum of glenoid bone loss in anterior shoulder dislocation: CT analysis of 218 patients. *AJR Am J Roentgenol.* 2008May;190(5):1247-54.
- Ideberg R, Grevsten S, Larsson S. Epidemiology of scapular fractures. Incidence and classification of 338 fractures. *Acta Orthop Scand.* 1995Oct;66(5):395-7.
- Hovellius L, Eriksson K, Fredin H, Hagberg G, Hussenius A, Lind B, Thorling J, Weckström J. Recurrences after initial dislocation of the shoulder. Results of a prospective study of treatment. *J Bone Joint Surg Am.* 1983Mar;65(3):343-9.
- Galvin JW, Ernat JJ, Waterman BR, Stadecker MJ, Parada SA. The epidemiology and natural history of anterior shoulder instability. *Curr Rev Musculoskelet Med.* 2017Dec;10(4):411-24.
- Boone JL, Arciero RA. First-time anterior shoulder dislocations: has the standard changed? *Br J Sports Med.* 2010Apr;44(5):355-60.
- Malhotra A, Freudmann MS, Hay SM. Management of traumatic anterior shoulder dislocation in the 17- to 25-year age group: a dramatic evolution of practice. *J Shoulder Elbow Surg.* 2012 Apr;21(4):545-53. Epub 2011 Mar 30.
- Scheibel M, Hug K, Gerhardt C, Krueger D. Arthroscopic reduction and fixation of large solitary and multifragmented anterior glenoid rim fractures. *J Shoulder Elbow Surg.* 2016 May;25(5):781-90. Epub 2015 Dec 2.
- Kummel BM. Fractures of the glenoid causing chronic dislocation of the shoulder. *Clin Orthop Relat Res.* 1970 Mar-Apr;69:189-91.
- van Oostveen DP, Temmerman OP, Burger BJ, van Noort A, Robinson M. Glenoid fractures: a review of pathology, classification, treatment and results. *Acta Orthop Belg.* 2014 Mar;80(1):88-98.
- De Palma AF. Fractures and fracture-dislocations of the shoulder girdle. Philadelphia: Lippincott; 1983.
- Maquieira GJ, Espinosa N, Gerber C, Eid K. Non-operative treatment of large anterior glenoid rim fractures after traumatic anterior dislocation of the shoulder. *J Bone Joint Surg Br.* 2007 Oct;89(10):1347-51.
- Samilson RL, Prieto V. Dislocation arthropathy of the shoulder. *J Bone Joint Surg Am.* 1983 Apr;65(4):456-60.
- Tauber M, Moursy M, Eppel M, Koller H, Resch H. Arthroscopic screw fixation of large anterior glenoid fractures. *Knee Surg Sports Traumatol Arthrosc.* 2008 Mar; 16(3):326-32. Epub 2007 Nov 14.
- Bonneville N, Clavert P, Arboucalot M, Bahlau D, Bauer T, Ehlinger M; SOFCOT. Contribution of arthroscopy in the treatment of anterior glenoid rim fractures: a comparison with open surgery. *J Shoulder Elbow Surg.* 2019 Jan;28(1):42-7. Epub 2018 Sep 24.
- Porcellini G, Campi F, Paladini P. Arthroscopic approach to acute bony Bankart lesion. *Arthroscopy.* 2002 Sep;18(7):764-9.
- Mayo KA, Benirschke SK, Mast JW. Displaced fractures of the glenoid fossa. Results of open reduction and internal fixation. *Clin Orthop Relat Res.* 1998 Feb; 347:122-30.
- Scheibel M, Magosch P, Lichtenberg S, Habermeyer P. Open reconstruction of anterior glenoid rim fractures. *Knee Surg Sports Traumatol Arthrosc.* 2004 Nov; 12(6):568-73. Epub 2004 Mar 18.
- Seybold D, Gekle C, Muhr G, Källicke T. [Severe complications after percutaneous transaxillary refixation of a glenoid rim fracture]. *Unfallchirurg.* 2006 Jan; 109(1):72-7. German.
- Itoi E, Hatakeyama Y, Sato T, Kido T, Minagawa H, Yamamoto N, Wakabayashi I, Nozaka K. Immobilization in external rotation after shoulder dislocation reduces the risk of recurrence. A randomized controlled trial. *J Bone Joint Surg Am.* 2007 Oct; 89(10):2124-31.
- Carbone A, Rodeo S. Review of current understanding of post-traumatic osteoarthritis resulting from sports injuries. *J Orthop Res.* 2017 Mar;35(3):397-405. Epub 2016 Jul 22.
- Falah M, Nierenberg G, Soudry M, Hayden M, Volpin G. Treatment of articular cartilage lesions of the knee. *Int Orthop.* 2010 Jun;34(5):621-30. Epub 2010 Feb 18.
- Sophia Fox AJ, Bedi A, Rodeo SA. The basic science of articular cartilage: structure, composition, and function. *Sports Health.* 2009 Nov;1(6):461-8.
- Lieberthal J, Sambamurthy N, Scanzello CR. Inflammation in joint injury and post-traumatic osteoarthritis. *Osteoarthritis Cartilage.* 2015 Nov;23(11):1825-34.
- Walch G, Badet R, Boulahia A, Khoury A. Morphologic study of the glenoid in primary glenohumeral osteoarthritis. *J Arthroplasty.* 1999 Sep;14(6):756-60.