



Year: 2020

Ganglion cell layer thickening in well-controlled patients with type 1 diabetes: an early sign for diabetic retinopathy?

Gerendas, Bianca S ; Hatz, Katja ; Kaider, Alexandra ; Zulewski, Henryk ; Lehmann, Roger ; Montuoro, Alessio ; Schmidt-Erfurth, Ursula ; Prunte, Christian

Abstract: **PURPOSE** To evaluate early changes in retinal layers using optical coherence tomography (OCT) in patients with long-standing type 1 diabetes (DM1) receiving intensified insulin therapy. **METHODS** In a cross-sectional case-control study 150 patients with DM1 and 150 age- and sex-matched healthy control participants underwent OCT imaging. Scans of both eyes were analysed for different layers (NFL, GCL (+IPL), INL, outer layer complex (OLC, including OPL, ONL and ELM) and photoreceptors (PR)) in all subfields of an ETDRS grid. All analyses were performed semi-automatically using custom software by certified graders of the Vienna Reading Center. ANOVA models were used to compare the mean thickness of the layers between patients and controls. **RESULTS** Six hundred eyes with 512 datapoints in 49 b-scans in each OCT were analysed. Mean thickness in patients/controls was 31.35 μm /30.65 μm (NFL, $p = 0.0347$), 76.7 μm /73.15 μm (GCL, $p \leq 0.0001$), 36.29 μm /37.13 μm (INL, $p = 0.0116$), 114.34 μm /112.02 μm (OLC, $p < 0.0001$) and 44.71 μm /44.69 μm (PR, $p = 0.9401$). When evaluating the ETDRS subfields separately for clinically meaningful hypotheses, a significant swelling of the GCL in patients could be found uniformly and a central swelling for the OLC, whereas the distribution of NFL and INL thickening suggests that their statistical significance was not clinically relevant. **CONCLUSION** These preliminary results demonstrate that preclinical retinal changes in patients with long-standing DM1 can be found by retinal layer evaluation. However, the changes are layer-specific, with significant thickening of the GCL and less so of the OLC suggesting a role as an early sign for diffuse swelling and the evolution of DME even in well-controlled diabetes.

DOI: <https://doi.org/10.1111/aos.14273>

Posted at the Zurich Open Repository and Archive, University of Zurich

ZORA URL: <https://doi.org/10.5167/uzh-200071>

Journal Article

Published Version



The following work is licensed under a Creative Commons: Attribution-NonCommercial 4.0 International (CC BY-NC 4.0) License.

Originally published at:

Gerendas, Bianca S; Hatz, Katja; Kaider, Alexandra; Zulewski, Henryk; Lehmann, Roger; Montuoro, Alessio; Schmidt-Erfurth, Ursula; Prunte, Christian (2020). Ganglion cell layer thickening in well-controlled patients with type 1 diabetes: an early sign for diabetic retinopathy? *Acta Ophthalmologica*, 98(3):e292-e300.

DOI: <https://doi.org/10.1111/aos.14273>

Ganglion cell layer thickening in well-controlled patients with type 1 diabetes: an early sign for diabetic retinopathy?

Bianca S. Gerendas,^{1,*}  Katja Hatz,^{1,2,3,*} Alexandra Kaider,⁴ Henryk Zulewski,⁵ Roger Lehmann,⁶ Alessio Montuoro,¹ Ursula Schmidt-Erfurth^{1,*}  and Christian Prunte^{3,7,8,*}

¹Vienna Reading Center, Department of Ophthalmology, Medical University of Vienna, Vienna, Austria

²Vista Klinik Binningen, Binningen, Switzerland

³Department of Ophthalmology, University of Basel, Basel, Switzerland

⁴Center for Medical Statistics, Informatics and Intelligent Systems, Section for Clinical Biometrics, Medical University of Vienna, Vienna, Austria

⁵Department of Endocrinology, University of Basel, Basel, Switzerland

⁶Department of Endocrinology, University of Zuerich, Zuerich, Switzerland

⁷Department of Ophthalmology, Kantonsspital Liestal, Liestal, Switzerland

⁸Institute of Molecular and Clinical Ophthalmology, Basel, Switzerland

ABSTRACT.

Purpose: To evaluate early changes in retinal layers using optical coherence tomography (OCT) in patients with long-standing type 1 diabetes (DM1) receiving intensified insulin therapy.

Methods: In a cross-sectional case-control study 150 patients with DM1 and 150 age- and sex-matched healthy control participants underwent OCT imaging. Scans of both eyes were analysed for different layers (NFL, GCL (+IPL), INL, outer layer complex (OLC, including OPL, ONL and ELM) and photoreceptors (PR)) in all subfields of an ETDRS grid. All analyses were performed semi-automatically using custom software by certified graders of the Vienna Reading Center. ANOVA models were used to compare the mean thickness of the layers between patients and controls.

Results: Six hundred eyes with 512 datapoints in 49 b-scans in each OCT were analysed. Mean thickness in patients/controls was 31.35 μm /30.65 μm (NFL, $p = 0.0347$), 76.7 μm /73.15 μm (GCL, $p \leq 0.0001$), 36.29 μm /37.13 μm (INL, $p = 0.0116$), 114.34 μm /112.02 μm (OLC, $p < 0.0001$) and 44.71 μm /44.69 μm (PR, $p = 0.9401$). When evaluating the ETDRS subfields separately for clinically meaningful hypotheses, a significant swelling of the GCL in patients could be found uniformly and a central swelling for the OLC, whereas the distribution of NFL and INL thickening suggests that their statistical significance was not clinically relevant.

Conclusion: These preliminary results demonstrate that preclinical retinal changes in patients with long-standing DM1 can be found by retinal layer evaluation. However, the changes are layer-specific, with significant thickening of the GCL and less so of the OLC suggesting a role as an early sign for diffuse swelling and the evolution of DME even in well-controlled diabetes.

Key words: diabetic retinopathy – early detection – early disease – image analysis – OCT

*Equal contribution.

Acta Ophthalmol. 2020; 98: e292–e300

© 2019 The Authors. Acta Ophthalmologica published by John Wiley & Sons Ltd on behalf of Acta Ophthalmologica Scandinavica Foundation.

This is an open access article under the terms of the Creative Commons Attribution-NonCommercial License, which permits use, distribution and reproduction in any medium, provided the original work is properly cited and is not used for commercial purposes.

doi: 10.1111/aos.14273

Introduction

As early as in the 1980s, the population-based Wisconsin Epidemiologic Study of Diabetic Retinopathy (WESDR) demonstrated a prevalence of diabetic retinopathy (DR) of 17% in patients with diabetes of less than 5 years and 97.5% of 15 or more years duration (Klein et al. 1984). Patients with recently diagnosed type 1 diabetes (DM1) had a lower risk for sight-threatening stages of DR such as proliferative diabetic retinopathy and/or diabetic macular oedema (DME) than those diagnosed longer before (Hovind et al. 2003; Nordwall et al. 2004). Strict blood-sugar control by intensified insulin therapy reduced the risk of developing microvascular diabetes complications such as DR, especially the late stages (The Diabetes Control and Complications Trial Research Group 1993; Fullerton et al. 2014). However, DR is still one of the leading causes of vision loss in adults aged 20–74 years (Cheung et al. 2010), which may lead to patients with DM1 retiring early (Gomes & Negrato 2015). Despite advances in diabetes care, many patients have complications for various reasons. Therefore, greater emphasis must be placed on a better understanding of the mechanisms by which diabetes affects the retina and early signs of diabetic retinal changes.

Optical coherence tomography (OCT) technology has markedly improved the

qualitative and quantitative evaluation of pathologic retinal changes in DR, especially in DME. Quantitative evaluations such as central retinal thickness (CRT) have become markers for evaluating treatment efficacies in clinical studies (Csaky et al. 2008). However, CRT is only modestly correlated with visual acuity in DME and sometimes visual acuity does not follow CRT improvement or worsening (Browning et al. 2007; Gerendas et al. 2014). With the introduction of spectral-domain (SD) and swept-source OCT technology with higher resolution, speed and reduced speckle noise, we can obtain images with more detailed information. Typical lesions in progressed DR/DME such as intraretinal cystoid fluid, subretinal fluid and hyper-reflective foci are easy to detect but discrete depth changes in mild DR or subclinical stages of DR are not obvious. Earlier studies concluded that at least thickness measurements in time-domain OCT are unhelpful in early DR (Ciresi et al. 2010). Today, automated algorithms, for example layer segmentation software, make quantifying the thickness of individual retinal layers and qualitatively evaluate lesions in each layer possible. Such early changes in DR on OCT, particularly retinal layer segmentation features, have been examined in animal models and clinically. In early diabetic mice, retinal thinning found by OCT corresponded to outer nuclear layer (ONL) thinning in histological sections when vascular changes were not visible in fluorescein angiography (FA) images (Yang et al. 2015). In diabetes mellitus type 2 (DM2), thinning of inner retinal layers, including the ganglion cell and inner plexiform layer (GCIPL) complex and retinal nerve fibre layer (NFL) was reported by several authors comparing the results of patients with different stages of DR and healthy control participants (van Dijk et al. 2012; Chhablani et al. 2015; Carpineto et al. 2016). The reduction in NFL thickness was confirmed, and a central increase in inner nuclear layer (INL) and outer plexiform layer (OPL) thickness found in a mixed DM1 and DM2 population while the GCIPL and inner retinal layer thicknesses showed no significant difference to the study's control group (Vujosevic & Midena 2013).

As patients with DM1 show different patterns of complications, including compared with DM2 (Cusick et al. 2005) differences within the early OCT changes between these patients may

exist, too. But thinning of the ganglion cell layer and the GCIPL complex, respectively, has also been found comparing patients with DM1 and healthy groups (van Dijk et al. 2009, 2010; Chen et al. 2016). Furthermore, total retinal thickness was reported as already reduced in patients with only minimal DR and/or after a short duration of DM1 compared with healthy groups (Bialosterski et al. 2007; Chen et al. 2016). Inner nuclear layer (INL) was thinner in DM1 than in control groups (van Dijk et al. 2009; Chen et al. 2016; Stem et al. 2016) and increased glycemic variability correlated with retinal thinning (Stem et al. 2016).

This study was designed to analyse retinal layer thicknesses in SD-OCT images within all ETDRS subfields in a DM1 population treated with intensified insulin therapy from disease diagnosis and compare the results with those of a healthy control group matched to it 1:1 for age and sex.

Material and methods

Study participants

Data sets for this study subanalysis were from a cross-sectional study of patients with DM1 and healthy control participants recruited at the outpatient clinic at the Department of Diabetology/Endocrinology of the University Hospital Basel and the Department of Diabetology/Endocrinology of the University Hospital Zurich between August 2010 and May 2014. Inclusion criteria for patients for the core study were age of >18 years, DM1 for ≥ 5 years and ≤ 30 years and treatment with intensified insulin therapy since disease diagnosis. Exclusion criteria were unsuitability for fluorescein angiography, uncontrolled hypertension and a change in antihypertensive treatment within 2 months pre-enrolment, pregnancy, any disease that could render the quality of images insufficient (e.g. cataract).

The control group was matched 1:1 for age and sex to the patient group. Exclusion criteria were any ocular disease or medication known to compromise retinal structure, history of diabetes, arterial hypertension or any systemic disease or medication known to compromise retinal structure, pregnancy, any disease that could render the quality of images insufficient (e.g. cataract).

All participants agreed to take part in the study and signed an informed consent form before the study. The study was approved by the local ethics committees (Ethikkommission Nordwestschweiz: BS 81/10; Kantonale Ethikkommission Zuerich: KEK-ZH 2012-0050), conducted in compliance with ICH GCP and adhered to the tenets of the Declaration of Helsinki. It was registered at clinicaltrials.gov as NCT02307110.

Examinations

Best-corrected visual acuity (BCVA), fundus biomicroscopy, intraocular eye pressure, standard 7-field colour fundus photographs and fluorescein angiography performed in the core study were not part of this subanalysis. All OCT images were recorded at a Heidelberg Spectralis (Heidelberg Engineering, Heidelberg, Germany) SD-OCT device located at Vistaklinik, Binningen, Switzerland (patients and controls) or at Vista Diagnostics, Zurich, Switzerland (patients only) by one trained and reading center-certified ophthalmologic photographer (CK). The scan protocol comprised macular raster scans of both eyes in the high-speed mode, a $20^\circ \times 20^\circ$ recording field (equivalent to 6×6 mm) with 49 b-scans (inter-scan distance 125 μm) and an averaging of 15 frames per b-scan.

OCT image analysis

All OCT images were analysed at the independent, fully digitalized Vienna Reading Center to provide a uniform, standardized and accurate assessment. Validated computer-assisted custom grading software was used. Graders were trained according to a standardized predefined study protocol and received regular supervision for training and quality control.

Five different layers were evaluated in OCT scans of both eyes: NFL (layer 1), a complex of the GCIPL (layer 2), INL (layer 3), a complex of the outer plexiform layer, outer nuclear layer, external limiting membrane until photoreceptor inner segments begin, referred to as the outer layer complex (OLC, layer 4) and photoreceptors (PR, layer 5). These five layers were evaluated in all subfields of a fovea-centred early treatment diabetic retinopathy study (ETDRS) grid. Figure 1 shows an example.

First, each of 49 b-scans was loaded and checked for image quality and the possibility to evaluate each of the layers. If an entire raster scan was of poor image quality the patient-control pair was excluded. Single b-scans of insufficient quality were excluded. If a region of a-scans within a b-scan could not be evaluated due to an artefact, a vessel shadow, etc., this region was excluded (Fig. 2 shows examples). Afterwards, an ETDRS grid was positioned on the foveal centre point (see Fig. 1). An automated layer segmentation at the Vienna Reading Center was used as a starting point for layer segmentation. Each layer was then manually adjusted on each b-scan and deleted. If the automated segmentation was too poor, the layer was solely manually segmented. Therefore, the segmentation can be described as a manually assisted.

Statistical analysis

Three-way analysis of variance (ANOVA) models were used to compare the mean thickness of the OCT layers of both eyes between patient and healthy participants.

The dependent variable *mean thickness*, group variable *patient/control*, and factors *layer* (NFL, GCL, INL, OLC and PR) and the nine different standard *ETDRS grid subfields* were considered in the ANOVA model for evaluation. The variable *partner match* was included as a random block factor to consider the 1:1 matching of patients and controls and the variable *subject* was included as a nested random factor. To evaluate whether differences between the two vary between the five different layers and between the nine different ETDRS grid subfields, respectively, interaction terms were included in the

ANOVA model. Due to statistical significance of these interaction terms, the group effects (patients vs. controls) were tested separately for each layer and each ETDRS grid subfield, respectively. Furthermore, subgroup analyses were performed evaluating the layers NFL, GCL, INL and OLC, separately, with respect to the different group effects in the ETDRS grid subfields, using two-way ANOVA models. Differences in the group effects depending on the ETDRS grid subfield were again evaluated by testing the respective interaction. Least squares (LS) means and the differences between LS means (with 95% confidence intervals (CI)) are given to describe the size of the group effects (patients versus controls). Extreme outliers (=observations with studentized residuals outside the range of ± 5 in the ANOVA model) were excluded from the analysis. To test for group effects in the intra-individual difference between the two eyes of the same participant, a three-way ANOVA model was used, considering the log-transformed absolute difference between the right and the left eye as a dependent variable. Two-sided p-values of <0.05 were interpreted as statistically significant. Due to the exploratory character of this study no correction for multiple testing was performed.

As a side note, the primary statistical analysis was performed in the entire ETDRS grid only. This resulted in many statistically significant findings as a large number of data points were tested; therefore, all values were evaluated for their clinical relevance. The following clinical hypotheses led to the described subgroup analyses for layers NFL, GCL, INL and OLC:

Hypothesis

Due to the natural distribution of the NFL, the ETDRS grid subfield outer nasal, which contains usually the thickest NFL (nearest to optic disc), shows a relatively larger difference in NFL thickness that is decreasing across the subfields from nasal to temporal areas, showing the smallest difference in the outer temporal ETDRS grid subfield, which usually contains the thinnest NFL (furthest away from optic disc).

Hypothesis

A swelling in the GCL is seen in all ETDRS subfields as cysts in the

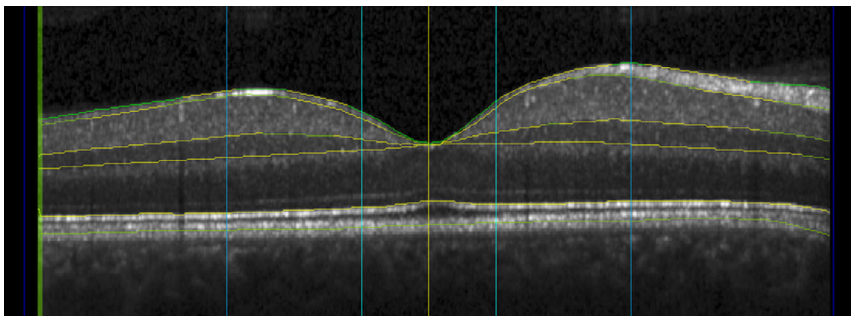


Fig. 1. Example central b-scan of optical coherence tomography with five evaluated layers, showing from top to bottom nerve fibre layer (NFL, layer 1), a complex of the ganglion cell and inner plexiform layers (GCL, layer 2), inner nuclear layer (INL, layer 3), a complex of the outer plexiform layer, outer nuclear layer, external limiting membrane until photoreceptor inner segments begin, referred to as the outer layer complex (OLC, layer 4) and photoreceptors (PR, layer 5); vertical lines are circles of early treatment diabetic retinopathy study grid in en-face view (yellow = foveal centre point, light blue = central millimetre subfield, blue = central 3 mm circle subfields, dark blue = 6 mm circle subfield; yellow segmentation lines are original lines from automated segmentation, green segmentation lines show where segmentation has been corrected by the Vienna Reading Center).

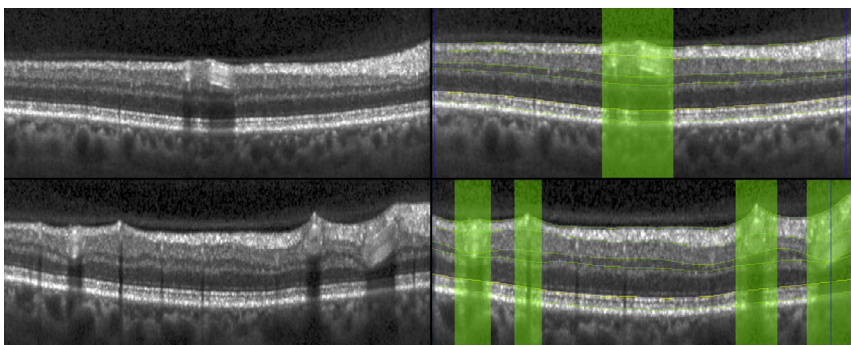


Fig. 2. Two example b-scans of optical coherence tomography with excluded areas due to vessels and vessel shadows. Left top and bottom: original b-scans, right top and bottom: corresponding b-scans with excluded areas (green, layer segmentation and horizontal grid lines for subfield).

ganglion cell layer appear without a relation to the centre and a swelling could be a diffuse macular oedema.

Hypothesis

A swelling in the INL and OLC is seen more prominently in the central subfield(s) as cysts in the inner and outer nuclear layers appear usually close to the fovea and this swelling could be a first sign of arising DME.

Results

Patient characteristics

One hundred and fifty patients and 150 age- and sex-matched healthy control participants in each group presented with a mean age of 40 ± 14 years, a 2:1 male ($n = 97$) to female ($n = 53$) ratio, and in the patient group a mean duration of diabetes of 14 ± 6 years (range 5–29 years), were included in this analysis. Patients were perfectly controlled metabolically with a mean blood pressure of 124 ± 14 mmHg/ 77 ± 10 mmHg and a median HbA1c of 7.4% [interquartile range 6.8–8.1%]. On fundus images, 75.3% of eyes (of 49 patients, 25 both eyes) showed no or only mild signs of DR and 24.7% higher stages of DR. 0.03% of eyes showed intraretinal cystoid fluid (nine eyes of seven patients) and 0.003% subretinal fluid (1 eye). Morphologic grading showed that no macular oedema was present except for singular small cystoid spaces. Interestingly, seven eyes (five controls) also showed such intraretinal cystoid fluid on OCT, although the inclusion criteria were fulfilled. Mean total retinal thickness in the central ETDRS grid subfield was $266 \mu\text{m}$ in patient and $263 \mu\text{m}$ in control participants. Table S1 shows total retinal thickness values (and standard deviations) of all ETDRS grid subfields. A precise description of the colour fundus and fluorescein angiography results and their correlation with systemic variables is published elsewhere (Hatz et al. 2019).

Statistical analysis was performed with and without inclusion of the 16 eyes with retinal fluid with no relevant difference between the results. The duration of diabetes was also tested as a covariable and no significant impact was found

($p = 0.45$). Here, the results are reported where eyes with retinal fluid were excluded and no correction for diabetes duration made, as described in the prospectively planned statistical analysis.

OCT layer thicknesses – descriptive overview

In total, 25 470 observation points (a-scan thicknesses) were segmented. The following section describes the data without exclusion of outliers. Figure 3 shows box plots of mean layer thicknesses in the entire ETDRS grid of each layer for patient versus control groups. The differences between patient and control groups are already very small compared with the total variance of the data. The mean thickness (\pm standard deviation) of the central millimetre subfield for the control and patient groups is $14.06 \pm 1.52 \mu\text{m}$ and $11.51 \pm 2.98 \mu\text{m}$ for the NFL, $36.48 \pm 8.39 \mu\text{m}$ and $39.6 \pm 10.40 \mu\text{m}$ for the GCIPL, $20.97 \pm 5.5 \mu\text{m}$ and $21.40 \pm 4.69 \mu\text{m}$ for the INL, $138.6 \pm 10.23 \mu\text{m}$ and $141.84 \pm 12.72 \mu\text{m}$ for the OLC, and $52.46 \pm 3.67 \mu\text{m}$ and 51.45 ± 3.99 for the PR. Table S1 shows values of all ETDRS subfields' mean thicknesses of the patient and control groups.

ANOVA model for the entire ETDRS grid

Eight observation points were excluded from the ANOVA model as extreme outliers ($8/25\ 470 = 0.03\%$). Overall, there was a significant difference in mean thickness for patient versus control participants ($p = 0.0003$). As expected, there was also a highly significant difference between thicknesses in different ETDRS subfields ($p < 0.0001$) and different layers ($p < 0.0001$). A highly significant difference of the group effect (patients versus controls) was found between the different layers ($p < 0.0001$). The difference [95% confidence interval] of the estimated LS-means (controls minus patients) was $-0.7 \mu\text{m}$ [-1.34 ; -0.05] for NFL (i.e. controls in mean thinner than patients, $p = 0.0347$), $-3.54 \mu\text{m}$ [-4.2 ; -2.9] for GCL (i.e. controls in mean thinner than patients, $p < 0.0001$), $0.83 \mu\text{m}$ [0.19 ; 1.48] for INL (i.e. controls in mean thicker than patients, $p = 0.0116$), $-2.32 \mu\text{m}$ [-2.97 ; -1.67] for OLC (i.e. controls in mean thinner than patients, $p < 0.0001$) and around zero (-0.02 [-0.67 ; 0.62], no significant difference, $p = 0.9401$) for PR.

In absolute values, the estimate for the layer thicknesses (LS-mean) of patient vs. control participants in the entire ETDRS grid was $31.35 \mu\text{m}$ versus $30.65 \mu\text{m}$ for NFL, $76.7 \mu\text{m}$ versus $73.15 \mu\text{m}$ for GCIPL, $36.29 \mu\text{m}$ versus $37.13 \mu\text{m}$ for INL, $114.34 \mu\text{m}$ versus $112.02 \mu\text{m}$ for OLC and $44.71 \mu\text{m}$ versus $44.69 \mu\text{m}$ for PR.

The total retinal thickness in the ETDRS grid subfields (which is the mean summarized thickness of the 5 layers in each subfield for all 300 study participants) was lowest with $263 \mu\text{m}$ in the central millimetre subfield of controls and highest with $336 \mu\text{m}$ in the inner nasal subfield of patients. The estimated mean thicknesses (LS means) in the ETDRS grid subfields were always lower in the control than in patient group and the differences ranged from -3.56 to $-12.24 \mu\text{m}$ with significances ($p = 0.0362$ to $p < 0.0001$). This overall thickening in patients was more pronounced in the outer subfields. Table 1 gives the exact numbers in all subfields. In addition, no significant difference between patient and control participants regarding the intra-individual difference between the right and left eye ($p = 0.1388$) was found. Therefore, values for all 600 eyes remained in the statistical analysis.

ANOVA model for separate ETDRS grid subfields

Nerve fibre layer

There was a highly significant difference in the group effect (patients versus controls) between different ETDRS grid subfields ($p < 0.0001$) in the NFL. The differences [95% confidence interval] of the estimated LS means (controls minus patients) for the five subfields from the outer temporal to outer nasal line were $-0.80 \mu\text{m}$ [-1.60 ; -0.002], $p = 0.0504$ (outer temporal); $-0.42 \mu\text{m}$ [-1.22 ; 0.38], $p = 0.2992$ (inner temporal); $2.51 \mu\text{m}$ [1.71 ; 3.31], $p < 0.0001$ (central subfield); $-1.06 \mu\text{m}$ [-1.86 ; -0.26], $p = 0.0094$ (inner nasal); and $-2.29 \mu\text{m}$ [-3.09 ; -1.48], $p < 0.0001$ (outer nasal). In absolute values, the estimate for the NFL thicknesses (LS means) of patient versus control participants for each ETDRS grid subfields was $22.19 \mu\text{m}$ versus $21.4 \mu\text{m}$ (outer temporal), $20.8 \mu\text{m}$ versus $20.38 \mu\text{m}$ (inner temporal), $11.54 \mu\text{m}$ versus $14.05 \mu\text{m}$ (central millimetre) $25.72 \mu\text{m}$ versus $24.66 \mu\text{m}$

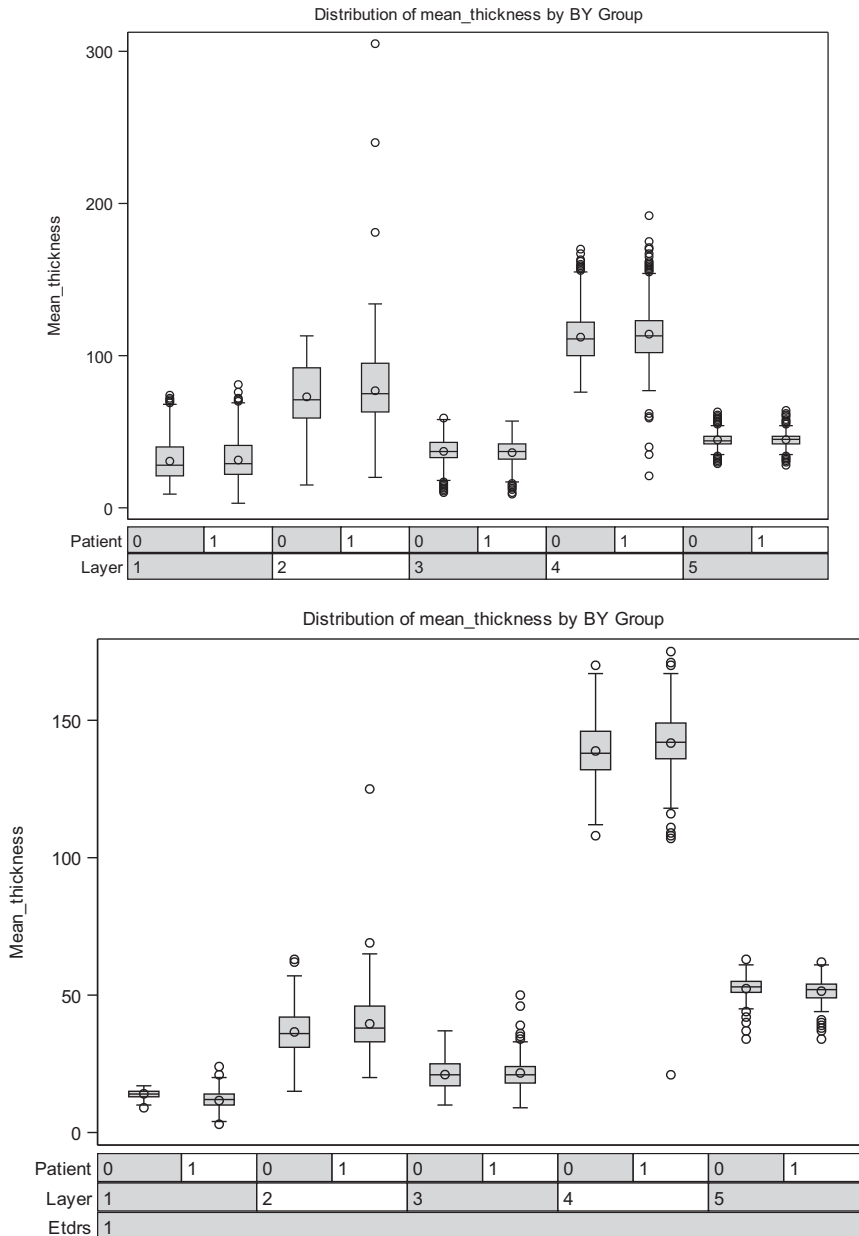


Fig. 3. Box plots of mean layer thicknesses of the nerve fibre layer (NFL, layer 1), a complex of the ganglion cell and inner plexiform layers (GCIPL, layer 2), inner nuclear layer (INL, layer 3), a complex of outer plexiform layer, outer nuclear layer, external limiting membrane until photoreceptor inner segments begin, referred to as the outer layer complex (OLC, layer 4) and photoreceptors (PR, layer 5) in patient (1) versus control participants (0) in the entire early treatment diabetic retinopathy study (ETDRS) grid (left) and just the central millimetre subfield (ETDRS 1) of the ETDRS grid (right).

(inner nasal) and 55.19 μm versus 52.9 μm (outer nasal). This rejects Hypothesis 1 and indicates a statistical significance with no clinical relevance.

Ganglion cell layer and inner plexiform layer complex

Again a highly significant difference was found in the group effect (patients versus controls) between different ETDRS grid subfields ($p = 0.0002$) in the GCIPL. The differences [95%

confidence interval] of the estimated LS means (controls minus patients) for the nine ETDRS subfields were all between $-2.52 \mu\text{m}$ [-3.92 ; -1.13] (inner temporal) and $-5.15 \mu\text{m}$ [-6.54 ; -3.76] (outer nasal), all $p < 0.0001$, except inner temporal $p = 0.0004$. Table 2 shows values of all ETDRS subfields, including absolute values. These findings support Hypothesis 2 and a diffuse swelling of the GCIPL in the patient group.

Inner nuclear layer

There was also a highly significant difference in the group effect (patients versus controls) between different ETDRS grid subfields ($p < 0.0001$) in the INL. The differences [95% confidence interval] of the estimated LS-means (controls minus patients) for the nine ETDRS subfields were all between $-0.58 \mu\text{m}$ [-1.31 ; 0.15] (central) and $1.89 \mu\text{m}$ [1.16 ; 2.62] (inner bottom), with some significant and some non-significant p-values. Table 2 shows values of all ETDRS subfields, including absolute values and p-values. These findings reject Hypothesis 3 for INL and a diffuse swelling of the INL in the patient group and indicate a statistical significance with no clinical relevance.

Outer layer complex, including the outer nuclear layer

There was a highly significant difference in the group effect (patients versus controls) between different ETDRS grid subfields ($p < 0.0001$) in the OLC. The significant differences [95% confidence interval] of the estimated LS means (controls minus patients) for the ETDRS subfields were all between $-3.76 \mu\text{m}$ [-5.53 ; -2] (central, $p < 0.0001$) and $-1.89 \mu\text{m}$ [-3.65 ; -0.12] (outer nasal, $p = 0.0366$), with the strongest difference in the central subfield. Although all nine ETDRS subfields showed lower thickness values for control than patient participants, some differences were not statistically significant. The subfields with no statistically significant difference were inner top, inner nasal and outer top. Table 2 shows values of all ETDRS subfields, including absolute values. These findings support Hypothesis 3 for OLC and a diffuse swelling of the outer nuclear layer in the patient group.

Summary of clinically relevant results

1 The hypothesized diffuse swelling of GCL in the entire macula probably is an early sign of DME.

2 The hypothesized diffuse swelling of OLC, most likely in the outer nuclear layer, strongest in the central millimetre around the fovea, may be associated with early DME.

Discussion

We compared the layer thicknesses of five different retinal layers in a group of

Table 1. Values of all ETDRS grid subfields' absolute LS-mean total retinal thicknesses for patient and control participants and the differences of the LS-mean thicknesses between them; negative differences mean patients' retinas are thicker than control participants'.

Subfield	LS-mean thickness patients	LS-mean thickness controls	Difference	Lower 95% CI	Upper 95% CI	p-value
Central millimetre	266.10	262.54	-3.56	-6.89	-0.23	0.0362
Inner top	333.74	329.38	-4.36	-7.69	-1.03	0.0103
Inner temporal	320.93	316.25	-4.67	-8.01	-1.34	0.0060
Inner bottom	331.76	326.38	-5.38	-8.71	-2.05	0.0016
Inner nasal	335.85	330.90	-4.95	-8.29	-1.62	0.0036
Outer top	287.15	281.38	-5.76	-9.09	-2.43	0.0007
Outer temporal	272.77	265.64	-7.13	-10.46	-3.80	<0.0001
Outer bottom	277.04	268.80	-8.24	-11.57	-4.90	<0.0001
Outer nasal	306.03	297.11	-8.91	-12.24	-5.58	<0.0001

CI = confidence interval of the difference.

Table 2. Values of all ETDRS grid subfields' absolute LS-mean thicknesses for a complex of the ganglion cell and inner plexiform layers (GCIPL), inner nuclear layer (INL) and a complex of the outer plexiform layer, outer nuclear layer, external limiting membrane until photoreceptor inner segments begin (OLC) layer for patients and controls and the differences in LS-mean thicknesses of the same layers between them; negative differences mean patients' layers are thicker than control participants'.

Subfield	Layer	LS-mean thickness patients	LS-mean thickness controls	Difference	Lower 95% CI	Upper 95% CI	p-value
Central millimetre	GCIPL	39.34*	36.47*	-2.87	-4.25	-1.47	<0.0001
Inner top		97.25	92.98	-4.27	-5.66	-2.88	<0.0001
Inner temporal		92.31	89.78	-2.52	-3.92	-1.13	0.0004
Inner bottom		96.52	92.80	-3.72	-5.11	-2.32	<0.0001
Inner nasal		97.29	93.78	-3.51	-4.90	-2.12	<0.0001
Outer top		64.51	61.09	-3.42	-4.81	-2.03	<0.0001
Outer temporal		70.96	66.87	-4.08	-5.48	-2.69	<0.0001
Outer bottom		62.09	58.28	-3.81	-5.20	-2.42	<0.0001
Outer nasal		70.89	65.74	-5.15	-6.54	-3.76	<0.0001
Central millimetre	INL	21.46*	20.88*	-0.58	-1.31	0.15	0.1191
Inner top		43.66	45.03	1.37	0.64	2.1	0.0002
Inner temporal		40.95	41.54	0.59	-0.14	1.32	0.1123
Inner bottom		43.08	44.97	1.89	1.16	2.62	<0.0001
Inner nasal		43.40	44.09	0.69	-0.05	1.42	0.0659
Outer top		32.97	33.37	0.4	-0.33	1.13	0.2873
Outer temporal		34.66	35.52	0.86	0.13	1.59	0.0217
Outer bottom		32.08	32.96	0.88	0.15	1.61	0.0182
Outer nasal		34.96	35.93	0.97	0.24	1.7	0.0091
Central millimetre	OLC	142.23*	138.47*	-3.76	-5.53	-1.99	<0.0001
Inner top		118.85	117.40	-1.46	-3.23	0.31	0.1065
Inner temporal		120.95	118.71	-2.23	-4	-0.47	0.0133
Inner bottom		116.89	114.61	-2.28	-4.05	-0.51	0.0115
Inner nasal		123.54	122.16	-1.38	-3.15	0.39	0.1255
Outer top		104.17	102.64	-1.53	-3.3	0.24	0.0896
Outer temporal		102.09	99.57	-2.52	-4.29	-0.75	0.0053
Outer bottom		95.94	93.79	-2.16	-3.93	-0.39	0.0169
Outer nasal		102.43	100.54	-1.89	-3.66	-0.12	0.0366

CI = Confidence interval of the difference.

Bold indicates the significance level ($p < 0.05$).

* The slight difference to the reported descriptive values in the central millimetre can be attributed to the exclusion of extreme outliers.

patients with DM1 well-controlled with intensified insulin therapy since diagnosis and an age- and sex-matched control group in a large group of 300 study participants with 600 eyes included in the study. We analysed 49 b-scans of each patient in high-speed mode (512 a-scans), resulting in a very large amount of data points. With this high number of data points, we found significant differences between the patient and

control groups in four out of five layers. Having regard to the physiological distribution of the layers, we conclude only two of these findings are clinically relevant. The other differences although statistical significance are too small and cannot be explained by our current knowledge of pathophysiology.

We found that the NFL is in mean $0.7 \mu\text{m}$ [-1.34; -0.05] thinner in the healthy than in the diabetes group.

Other studies have reported opposite results. Many of these did not distinguish patients with DM1 from those with DM2. Srinivasan et al. (2016a, b) maintained patients with DM1, DM2 or no classification could be assessed for the NFL in a single group. Therefore, we discuss studies in both DM1 and DM2. Furthermore, most studies investigated the NFL around the optic disc in a circular scan pattern (Park

et al. 2011; Shahidi et al. 2012; Carpineto et al. 2016; Chen et al. 2016; El-Fayoumi et al. 2016; Gundogan et al. 2016, 2016) and are not comparable with our study. We considered macular NFL thickness a more robust variable because thickness values for peripapillary NFL can be particularly easily misinterpreted as they heavily dependent on total retinal thickness (Yang et al. 2017) and vessels can lead to overestimation of thickness. A few studies have investigated macular NFL thickness, and some reported thinning of the NFL. van Dijk et al. (2012) analysis of 8 retinal layers in 64 patients with no or minimal signs of DR and 57 healthy participants revealed a significant difference in NFL thickness between patients with minimal DR and healthy participants with an absolute difference of $1.9 \mu\text{m}$ [0.3; 3.5]: The control had thicker NFL than the patient group, contrary to our mean finding. Chhablani et al. (2015) found the macular NFL in mean to be similar between 76 eyes of 62 treatment-naïve patients with DM and with or without DR and 67 eyes of 66 age-matched healthy participants but the minimum value was significantly lower in the DM group. This is not exactly what we found but our conclusion is the same: NFL is not altered in patients with DM with/without DR compared with healthy eyes. Chhablani's group also found the minimum thickness was less in eyes with DM ($9.41\text{--}10.2 \mu\text{m}$) than in healthy eyes ($13.16 \mu\text{m}$). They measured thickness in radial sectors while we measured it in ETDRS subfields. We found the minimum NFL thickness was lower in the central 3-mm subfields but it was higher in DM than in healthy eyes in the 3–6-mm ring around the centre (see Table S1). This indicates there is actually no difference in the NFL thicknesses of any of the groups, as found by Park et al. and Srinivasan et al. who analysed 126/143 eyes of patients with diabetes compared with 40/42 healthy participants. Both studies found no significant difference in macular thickness NFL values between the control and DM group with no (mild) signs of DR, (Park et al. 2011; Srinivasan et al. 2016a,b) similar to our cohort.

We also found thickening of the GCIPL in our patients and hypothesized a diffuse swelling as an early sign of DME. Wanek et al. found significant thickening of the GCIPL in 29 patients with DM and no or mild

nonproliferative DR compared with 22 control participants, as in our study. By contrast, other researchers report a general GCIPL thinning rather than a thickening in patients with DM (Srinivasan et al. 2016a,b). Many factors need to be considered when measuring individual layer thicknesses. Srinivasan et al. concluded GCIPL thickness was reduced in 84/67 patients with DM1/2 compared with 42 healthy participants. Closer examination reveals the patients with DM1 had a thickness of $97 \pm 8 \mu\text{m}$, with DM2 $93 \pm 8 \mu\text{m}$ and healthy participants $96 \pm 7 \mu\text{m}$. Ganglion cell and inner plexiform layer (GCIPL) thickness was therefore reduced in DM2 but not different or even thickened in DM1, as found in our study. Participants were not matched for age/sex, group sizes were uneven and 35%–46% of patients had signs of DR but how this was evaluated is not stated (Srinivasan et al. 2016a,b). Interestingly, it was this group who maintained tissue thickness can be measured in DM1 and DM2 interchangeably. Although possibly true for other layers, it is not true for GCIPL. This is also shown by Chen et al. who analysed different retinal layers and reported a significant thinning of 4–5 μm of the GCIPL in patients with DM1 compared with age- and sex-matched healthy eyes but the study group was small (26 DM1, 34 DM2 without DR) and the study possibly underpowered. A study by El-Fayoumi et al. in children with DM1 might explain why our findings contrast with studies reporting GCIPL thinning in patients with DM2. They found children with dyslipidaemia had a thinned GCIPL thickness, whereas patients with normal blood lipids had a thickness similar to the control group (El-Fayoumi et al. 2016). Given that many of the studies where GCIPL was thinned were in patients with DM2 (van Dijk et al. 2012; Chhablani et al. 2015; Carpineto et al. 2016; Ng et al. 2016), where lipid profiles are known to be worse than in DM1 (Duca et al. 2013), dyslipidaemia may have been a confounder in the DM2 studies that was reduced by our well-controlled patient group as patients with DM1 have been shown to have significantly less dyslipidaemia than healthy people (Wadwa et al. 2005). Regarding absolute values in mean, the GCIPL thickness of patients with hyperlipidemia was $6 \mu\text{m}$ less than in patients with no hyperlipidemia (El-Fayoumi et al. 2016).

Our GCIPL thickening was only $3.6 \mu\text{m}$. This could indicate that the thinning in other studies was due to hyperlipidemia and the GCIPL thickening was masked. In general, we hypothesize also that GCIPL thickening is greater in patients developing DME later and the GCIPL is unaltered in patients who remain without oedema. This must be proven in a follow-up analysis of our patients. Finally, our hypothesis may not hold as we measured the GCIPL complex rather than just the ganglion cell layer (GCL), as is commonly done because segmentation is easier. Possibly therefore while the GCL thins the inner plexiform layer (IPL) thickens. But taking account of our arguments mentioned above and as we found no literature reporting IPL thickening as an early change in DR, we believe we saw GCL rather than IPL thickening. Both our and reported data strongly indicate DR changes are multifactorial (Jonsson et al. 2016), and two pathways can be seen in the GCL – the neurodegenerative pathway, where a slow thinning of the GCL might be present due to atrophy of neurons, and the vascular pathway, where a thickening of the GCL might be an early indication for the development of DME with leaking vessels and diffuse and cystoid oedema. A retrospective analysis when DME development is known in the patients after a few years is needed to prove this.

One reason why especially in our cohort neurodegeneration is not/less seen in the form of mean NFL or GCIPL thinning could be that our patients received an intensified insulin therapy from the day of their diabetic disease diagnosis. A neuroprotective role of insulin to rescue retinal neurons from apoptosis by a phosphatidylinositol 3-kinase/Akt-mediated mechanism that reduces the activation of caspase-3 has been shown (Barber et al. 2001).

We found in mean the INL was thinner in patients with diabetes than in healthy participants. Although reported before for patient groups similar to ours (DM1 with no ($n = 32$) or minimal ($n = 25$) DR), (van Dijk et al. 2009; Chen et al. 2016) we believe this finding has no clinical relevance as we cannot explain why this thinning should not be the same over the entire macular region. In our study, we could neither find a general thinning nor a circled rule around the fovea for this thinning. We have not found support from the

literature, except in van Dijk et al. 's study with few patients. But Scarinci et al. (2017) recently reported a significant INL thickening in 76 patients with diabetes (DM1, no signs of DR) and Vujosevic & Midena (2013) reported increased INL thickness in 74 patients with diabetes and no or initial DR. Chen et al. (2016) concluded INL thickens in DM2 and INL thins in DM1. In sum, the available data from the literature and our study are too inconclusive to resolve the issue.

As in previous studies (Vujosevic & Midena 2013), we found that a significant thickening in the OLC (a complex mostly containing the outer plexiform and nuclear layers (OPL, ONL)), in patients with diabetes, most pronounced in the centre where DME usually starts. Chen et al. reported a significant para- and perifoveal thinning in the ONL of patients with DM1 compared with healthy participants and ONL thickening only in patients with DM2. On closer scrutiny, it is evident that these areas were thinned in patients with DM1 but the foveal area was thickened, supporting our hypothesis that the diffuse swelling in the ONL starts in the central area. Chen et al. found thickening everywhere in the ONL in DM2. Maybe, their finding of thinning of the para- and perifoveal areas in DM1 was due to chance and their small sample (Chen et al. 2016). Wanek et al. reported a significant thinning of the OPL and thickening of the ONL, strengthening our hypothesis that the ONL is the layer affected in our complex and the OPL has only a minor role.

The PR layer has been reported not to change in diabetes (Vujosevic & Midena 2013; Wanek et al. 2016) and from a pathophysiological view, alterations in this layer are hardly a marker for early signs of DR or DME. In the one publication about thinning of the PR layer in patients with diabetes, PR thickness was only measured at one unstandardized point of interest and it is doubtful that the results reported are reproducible with less variance than the reported 7 μm difference between the groups (Verma et al. 2009). In our opinion, the PR layer becomes more important for changes under therapy, both laser and anti-angiogenic therapy, and late changes of resolved oedema.

The strengths of our study are the large dataset (600 eyes), a well-controlled clinically homogenous group of

only patients with DM1 (many studies used mixed groups) and a standardized, blinded and quality-controlled reading centre evaluation. In general, comparison of published studies with our analysis is difficult as most studies have either used a fully automated segmentation without any corrections (van Dijk et al. 2012; Chhablani et al. 2015; Carpineto et al. 2016; Chen et al. 2016; El-Fayoumi et al. 2016; Gundogan et al. 2016; Ng et al. 2016) or solely a manual measurement of single points, which is usually quite erroneous (Browning et al. 2007; Verma et al. 2009). We used a fully automated segmentation but then corrected each layer on each b-scan manually. Every single raster scan needed correction. It must be remembered, especially with regard to significances throughout all studies around no more than 1–6 μm (e.g. 1.9 μm in [van Dijk et al. 2012;]) of thickness differences, that a pixel difference is usually already a few micrometres. Therefore, even a segmentation that looks good might not be good enough, especially in healthy cases. Also, not all studies were matched. Some were matched for age (van Dijk et al. 2009, 2012; Verma et al. 2009; Shahidi et al. 2012; Chhablani et al. 2015; Chen et al. 2016; El-Fayoumi et al. 2016; Ng et al. 2016; Srinivasan et al. 2016a,b) and few for sex, (van Dijk et al. 2009, 2012; Chen et al. 2016; El-Fayoumi et al. 2016) which is of critical importance. Sex-specific findings of greater macular retinal thickness in men than in women, in the centre, inner ring and outer temporal ring ETDRS grid areas have been found and taken into consideration by many studies analysing retinal layers in other diseases (Ooto et al. 2015); age is negatively correlated with inner retinal thickness (Ooto et al. 2011, 2015).

Another limitation of our study is the use of one time-point only and the different times of onsets of diabetes between patients, which is hard to standardize and will probably always be a weakness in such studies.

In conclusion, we believe GCL and OLC thickening are an early sign of DME in patients with diabetes with and without signs of DR. Further analyses are needed to find if this is only true for a subgroup of patients or a general finding. Our results suggest that the thickening could be an early sign for diffuse swelling and an arising

DME, which could be shown by a follow-up analysis.

References

- Barber A, Nakamura M, Wolpert E, Reiter C, Seigel G, Antonetti D & Gardner T (2001): Insulin rescues retinal neurons from apoptosis by a phosphatidylinositol 3-kinase/Akt-mediated mechanism that reduces the activation of caspase-3. *J Biol Chem* **276**: 32814–32821.
- Bialosterski C, van Velthoven M, Michels R, Schlingemann R, DeVries J & Verbraak F (2007): Decreased optical coherence tomography-measured pericentral retinal thickness in patients with diabetes mellitus type 1 with minimal diabetic retinopathy. *Br J Ophthalmol* **91**: 1135–1138.
- Browning D, Glassman A, Aiello L et al. (2007): Relationship between optical coherence tomography-measured central retinal thickness and visual acuity in diabetic macular edema. *Ophthalmology* **114**: 525–536.
- Carpineto P, Toto L, Aloia R et al. (2016): Neuroretinal alterations in the early stages of diabetic retinopathy in patients with type 2 diabetes mellitus. *Eye (London, England)* **30**: 673–679.
- Chen Y, Li J, Yan Y & Shen X (2016): Diabetic macular morphology changes may occur in the early stage of diabetes. *BMC Ophthalmol* **16**: 12.
- Cheung N, Mitchell P & Wong T (2010): Diabetic retinopathy. *Lancet* **376**: 124–136.
- Chhablani J, Sharma A, Goud A, Pequda H, Rao H, Bequm V & Barteselli G (2015): Neurodegeneration in type 2 diabetes: evidence from spectral-domain optical coherence tomography. *Invest Ophthalmol Vis Sci* **56**: 6333–6338.
- Ciresi A, Amato M, Morreale D et al. (2010): OCT is not useful for detection of minimal diabetic retinopathy in type 1 diabetes. *Acta Diabetol* **47**: 259–263.
- Csaky K, Richman E & Ferris F 3rd (2008): Report from the NEI/FDA ophthalmic clinical trial design and endpoints symposium. *Invest Ophthalmol Vis Sci* **49**: 479–489.
- Cusick M, Meleth A, Agron E et al. (2005): Associations of mortality and diabetes complications in patients with type 1 and type 2 diabetes: early treatment diabetic retinopathy study report no. 27. *Diabetes Care* **28**: 617–625.
- van Dijk H, Kok P, Garvin M et al. (2009): Selective loss of inner retinal layer thickness in type 1 diabetic patients with minimal diabetic retinopathy. *Invest Ophthalmol Vis Sci* **50**: 3404–3409.
- van Dijk H, Verbraak F, Kok P et al. (2010): Decreased retinal ganglion cell layer thickness in patients with type 1 diabetes. *Invest Ophthalmol Vis Sci* **51**: 3660–3665.
- van Dijk H, Verbraak F, Kok P et al. (2012): Early neurodegeneration in the retina of type 2 diabetic patients. *Invest Ophthalmol Vis Sci* **53**: 2715–2719.
- Duca L, Sippl R & Snell-Bergeon J (2013): Is the risk and nature of CVD the same in type

- 1 and type 2 diabetes? *Curr Diab Rep* **13**: 350–361.
- El-Fayoumi D, Badr Eldine N, Esmael A, Ghalwash D & Soliman H (2016): Retinal nerve fiber layer and ganglion cell complex thicknesses are reduced in children with type 1 diabetes with no evidence of vascular retinopathy. *Invest Ophthalmol Vis Sci* **57**: 5355–5360.
- Fullerton B, Jeitler K, Seitz M, Horvath K, Berghold A & Siebenhofer A (2014): Intensive glucose control versus conventional glucose control for type 1 diabetes mellitus. *Cochr Datab Syst Rev* **2**: Cd009122.
- Gerendas B, Simader C, Deak G et al. (2014): Morphological parameters relevant for visual and anatomic outcomes during anti-VEGF therapy of diabetic macular edema in the RESTORE trial. *Invest Ophthalmol Vis Sci* **55**: 1791.
- Gomes M & Negrato C (2015): Retirement due to disabilities in patients with type 1 diabetes a nationwide multicenter survey in Brazil. *BMC Public Health* **15**: 486.
- Gundogan F, Akay F, Uzun S, Yolcu U, Cagiltay E & Toyran S (2016): Early neurodegeneration of the inner retinal layers in type 1 diabetes mellitus. *Ophthalmologica* **235**: 125–132.
- Hatz K, Minder A, Lehmann R et al. (2019): The prevalence of retinopathy in patients with type 1 diabetes treated with education-based intensified insulin therapy and its association with parameters of glucose control. *Diab Res Clin Pract* **148**: 234–239.
- Hovind P, Tarnow L, Rossing K, Rossing P, Eising S, Larsen N, Binder C & Parving HH (2003): Decreasing incidence of severe diabetic microangiopathy in type 1 diabetes. *Diabetes Care* **26**: 1258–1264.
- Jonsson K, Frydkjaer-Olsen U & Grauslund J (2016): Vascular changes and neurodegeneration in the early stages of diabetic retinopathy: which comes first? *Ophthalmic Res* **56**: 1–9.
- Klein R, Klein B, Moss S, Davis M & DeMets D (1984): The Wisconsin epidemiologic study of diabetic retinopathy. II. Prevalence and risk of diabetic retinopathy when age at diagnosis is less than 30 years. *Arch Ophthalmol* **102**: 520–526.
- Ng D, Chiang P, Tan G et al. (2016): Retinal ganglion cell neuronal damage in diabetes and diabetic retinopathy. *Clin Exp Ophthalmol* **44**: 243–250.
- Nordwall M, Bojestig M, Arnqvist H & Ludvigsson J (2004): Declining incidence of severe retinopathy and persisting decrease of nephropathy in an unselected population of Type 1 diabetes-the Linköping Diabetes Complications Study. *Diabetologia* **47**: 1266–1272.
- Ooto S, Hangai M, Tomidokoro A et al. (2011): Effects of age, gender, and axial length on the three dimensional profile of normal macular layer structures. *Invest Ophthalmol Vis Sci* **52**(12): 8769–8779.
- Ooto S, Hangai M & Yoshimura N (2015): Effects of sex and age on the normal retinal and choroidal structures on optical coherence tomography. *Curr Eye Res* **40**: 213–225.
- Park H, Kim I & Park C (2011): Early diabetic changes in the nerve fibre layer at the macula detected by spectral domain optical coherence tomography. *Br J Ophthalmol* **95**: 1223–1228.
- Scarinci F, Picconi F, Virgili G, Giorno P, Di Renzo A, Varano M, Frontoni S & Parravano M (2017): Single Retinal Layer Evaluation in Patients with Type 1 Diabetes with No or Early Signs of Diabetic Retinopathy: the First Hint of Neurovascular Crosstalk Damage between Neurons and Capillaries? *Ophthalmologica* **237**: 223–231.
- Shahidi A, Sampson G, Pritchard N, Edwards K, Vagenas D, Russell A, Malik R & Efron N (2012): Retinal nerve fibre layer thinning associated with diabetic peripheral neuropathy. *Diab Med* **29**: e106–e111.
- Srinivasan S, Pritchard N, Sampson G, Edwards K, Vagenas D, Russell A, Malik R & Efron N (2016a): Retinal tissue thickness in type 1 and type 2 diabetes. *Clin Exp Optom* **99**: 78–83.
- Srinivasan S, Pritchard N, Sampson G, Edwards K, Vagenas D, Russell A, Malik R & Efron N (2016b): Retinal thickness profile of individuals with diabetes. *Ophthalmic Physiol Opt* **36**: 158–166.
- Stem M, Dunbar G, Jackson G, Farsiou S, Pop-Busui R & Gardner T (2016): Glucose variability and inner retinal sensory neuropathy in persons with type 1 diabetes mellitus. *Eye (London, England)* **30**: 825–832.
- The Diabetes Control and Complications Trial Research Group (1993): The effect of intensive treatment of diabetes on the development and progression of long-term complications in insulin-dependent diabetes mellitus. *N Engl J Med* **329**: 977–986.
- Verma A, Rani PK, Raman R et al. (2009): Is neuronal dysfunction an early sign of diabetic retinopathy? Microperimetry and spectral domain optical coherence tomography (SD-OCT) study in individuals with diabetes, but no diabetic retinopathy *Eye (London, England)* **23**: 1824–1830.
- Vujosevic S & Midena E (2013): Retinal layers changes in human preclinical and early clinical diabetic retinopathy support early retinal neuronal and Muller cells alterations. *J Diab Res* **2013**: 905058.
- Wadwa R, Kinney G, Maahs D, Snell-Bergeon J, Hokanson J, Garg S, Eckel R & Revers M (2005): Awareness and treatment of dyslipidemia in young adults with type 1 diabetes. *Diab Care* **28**: 1051–1056.
- Wanek J, Blair N, Chau F, Lim J, Leiderman Y & Shahidi M (2016): Alterations in retinal layer thickness and reflectance at different stages of diabetic retinopathy by en face optical coherence tomography. *Invest Ophthalmol Vis Sci* **57**: Oct341–Oct347.
- Yang Q, Xu Y, Xie P, Cheng H, Song Q, Su T, Yuan S & Liu Q (2015): Retinal neurodegeneration in db/db mice at the early period of diabetes. *J Ophthalmol* **2015**: 757412.
- Yang H, Woo J, Kim M, Kim D & Yoon Y (2017): Co-evaluation of peripapillary RNFL thickness and retinal thickness in patients with diabetic macular edema: RNFL misinterpretation and its adjustment. *PLoS ONE* **12**: e0170341.

Received on April 25th, 2019.
Accepted on September 14th, 2019.

Correspondence:

Ursula Schmidt-Erfurth, MD
Medical University of Vienna
Department of Ophthalmology
Wahringer Guertel 18-20
A-1090 Vienna
Austria
Tel.: + 43/1/40400-79310
Fax: + 43/1/40400-79320
Email: ursula.schmidt-erfurth@
meduniwien.ac.at

*Equal contribution.

The authors would like to express their sincere gratitude to all physicians in Zürich and the Basel areas, who helped to recruit the patients, and Christine Knodel, chief photographer of Vista Klinik, who performed all images and the transfer of the images to the Vienna Reading Center (VRC). Further, they thank the staff of VRC, especially Tobias Paul, and Theresia Pieler, Ursula Foteinou and Caroline Pilwachs, who mainly contributed to the image readings. The authors' sincere thanks also go to Susanne Mueller, Christina Palencia and Verena Wyss for reviewing data, collecting data and data management, Anja Burgherr who monitored the study and Elise Langdon-Neuner for editing the manuscript with for language. The authors thank the following physicians of Vista Klinik who performed the ophthalmological examinations: Florian Weisskopf MD, Bijan Alamouti MD, May Abou Hadeed MD, Robert Katamay MD and Thomas Müller MD.

This study has been supported in part by Bayer, Switzerland. The industry contributor had no role in the design or conduct of this study.

Gerendas, Hatz, Prunte, Schmidt-Erfurth: Consultancy.

Supporting Information

Additional Supporting Information may be found in the online version of this article:

Table S1 Values of all ETDRS grid subfields' mean thicknesses (and standard deviations) of five retinal layers (nerve fiber layer (NFL), a complex of the ganglion cell and inner plexiform layers (GCIPL), inner nuclear layer (INL), a complex of outer plexiform layer, outer nuclear layer, external limiting membrane until photoreceptor inner segments begin, referred to as the outer layer complex (OLC) and photoreceptors (PR) and total retinal thickness in patient and control participants.