



**University of
Zurich**^{UZH}

**Zurich Open Repository and
Archive**

University of Zurich
University Library
Strickhofstrasse 39
CH-8057 Zurich
www.zora.uzh.ch

Year: 2021

A rare case of pancraniosynostosis observed in a historical skull from the 19 th century cranial collection named “Królestwo Polskie” (“Polish Kingdom”)

Cieślik, Agata ; Nowaczewska, Wioletta ; Kołtowska, Anna ; Henneberg, Maciej

DOI: <https://doi.org/10.2478/anre-2021-0003>

Posted at the Zurich Open Repository and Archive, University of Zurich

ZORA URL: <https://doi.org/10.5167/uzh-214494>

Journal Article

Published Version

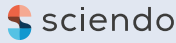

The following work is licensed under a Creative Commons: Attribution-NonCommercial-NoDerivatives 4.0 International (CC BY-NC-ND 4.0) License.

Originally published at:

Cieślik, Agata; Nowaczewska, Wioletta; Kołtowska, Anna; Henneberg, Maciej (2021). A rare case of pancraniosynostosis observed in a historical skull from the 19 th century cranial collection named “Królestwo Polskie” (“Polish Kingdom”). *Anthropological Review*, 84(1):29-36.

DOI: <https://doi.org/10.2478/anre-2021-0003>



A rare case of pancraniosynostosis observed in a historical skull from the 19th century cranial collection named “Królestwo Polskie” (“Polish Kingdom”)

*Agata Cieřlik¹, Wioletta Nowaczewska², Anna Kołtowska³,
Maciej Henneberg^{4,5}*

¹Hirszfeld Institute of Immunology and Experimental Therapy, Polish Academy of Sciences, Department of Anthropology, Wrocław, Poland

²Department of Human Biology, University of Wrocław, Wrocław, Poland

³Department of General Radiology, Interventional Radiology and Neuroradiology, Wrocław Medical University, Wrocław, Poland

⁴Biological Anthropology and Comparative Anatomy Research Unit, University of Adelaide, School of Medicine, Adelaide, Australia

⁵The Institute of Evolutionary Medicine, University of Zurich, Zurich, Switzerland

ABSTRACT: Rare diseases are a challenge in paleopathological research, mainly due to the ambiguity of skeletal signs, bad preservation state of the material, and lack of the reference material. The aim of our article is to present the skull characterized by the decreased values of the metrical traits and numerous pathological features of the cranial morphology and make an attempt to determine the possible cause of the observed anomalies.

The subject of our study is a cranium No KP 131 belonging to Polish skeletal collection named „Polish Kingdom”. We used both standard anthropometric methods, as well as the imaging techniques to detect the probable causes of the observed pathological changes.

This specimen presents a complex of pathologies. Decreased values of the metrical features, thinning of the lateral walls of the neurocranium and the presence of platybasia were probably caused by premature closure of all main cranial sutures.

Pathologies observed in cranium No 131 XIX might have had a common cause in some form of syndromic disorders.

KEY WORDS: pancraniosynostosis, microcephaly, platybasia, paleopathology

Introduction

Craniosynostosis (CS) is a condition in which one or more of cranial vault sutures fuse prematurely which usually leads to significant deformations of the *neurocranium*. There are several types of craniosynostosis, depending on how many and which sutures are involved. The most common type is sagittal craniosynostosis, followed by unicoronal, bicoronal, metopic, and lambdoid craniosynostosis (Buchanan et al. 2017).

The most severe form of craniosynostosis, pansynostosis, is characterized by premature fusion of three or more main cranial sutures (Foo et al. 2010). This form of complex synostosis may manifest early in the postnatal de-

velopment, eg. in a form of deformation called clover leaf skull (kleeblattschädel) (Fonesca and Borém 2014) or may develop later in the postnatal life resembling features observed in microcephaly: a markedly small head, but with normal proportions (Blount et al. 2007).

The main purpose of this paper is to present a rare case of a skull characterized by decreased values of the metric traits, and other pathological features that can be attributed to a unique form of pansynostosis – progressive postnatal pansynostosis (PPP).

Materials and methods

The object of the study is a skull which is a part of cranial series named “Królestwo

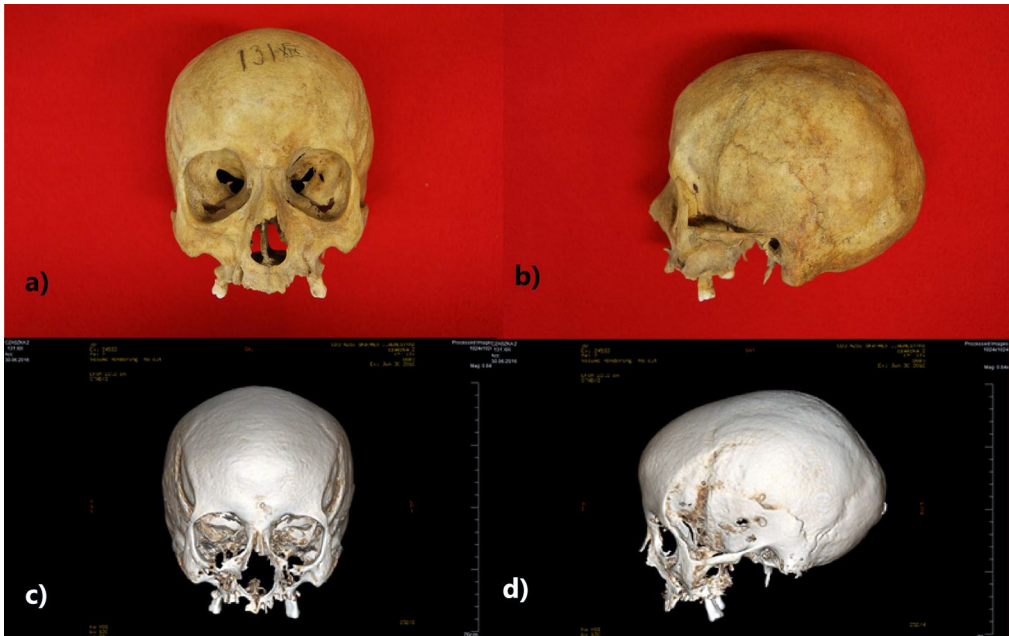


Fig. 1. The preservation state of the cranium labelled KP 131 XIX

a) Photograph showing the anterior aspect of the KP131, b) Left lateral view of the cranium No 131 KP XIX showing the closure stage of the cranial sutures, c) 3D – CT image of the cranium KP 131 XIX (anterior aspect), d) lateral aspect; note the undisturbed proportionality between the *splanchnocranium* and *neurocranium* of the skull.

Table 1. The values of the variables of the skull No KP131

Definition of the variables	Value
Measurements	
CC = Cranial capacity (ml)	950
OFC occipito-frontal circumference between the glabella and opisthocranium points (mm)	442
g-op (M1) maximal cranial length (mm)	149
eu-eu (M8) maximal cranial breadth (mm)	125
ba-b* (M17) height of the cranium (mm)	107
n-ba (M5) external length of the skull base (mm)	81
ast-ast (M12) biasterionic breadth (mm)	101
l*-o (M31) occipital sagittal chord (mm)	77
ba-o (M7) length of the foramen magnum (mm)	31
breadth of the foramen magnum (M16) (mm)	25
fnt-fnt (M43) outer biorbital breadth (mm)	91
ft-ft (M9) least frontal breadth (mm)	83
ek-ek (M44) (mm)	85
mf-mf (M50) anterior interorbital breadth (mm)	16
orbital height (M52) (left) (mm)	32
mf-ek (M51) orbital breadth (left) (mm)	37
zm-zm (M46) bimaxillary breadth (mm)	78
zy-zy (M45) bizygomatic breadth (mm)	111
apt-apt (M54) nasal breadth (mm)	17
n-ns (M55) nasal height (mm)	43
ba-pr* (M40) basion-prosthion length (mm)	77
n-pr* (M48) upper facial height (mm)	59
ol-sta (M62) internal palatal length (mm)	33
Indices	
$(eu-eu/g-op) \times 100$	83.89
$(ba-b*/g-op) \times 100$	71.81
$(ba-b*/eu-eu) \times 100$	85.60
$(n-pr*/zy-zy) \times 100$	53.15
$(orbital\ height /mf-ek) \times 100$ (left)	86.49
$(n-pr*/zm-zm) \times 100$	75.64
$(zy-zy/eu-eu) \times 100$	88.0
$(ft-ft/zy-zy) \times 100$	74.77
$(apt-apt/n-ns) \times 100$	39.53
GN measure of the neurocranium size = geometric mean of three measurements: g-op, eu-eu, ba-b	125.84
GS measure of the splanchnocranium size – the geometric mean of three measurements: n-pr*, zy-zy, ol-sta	60.01
GS/GN relative size of the splanchnocranium	0.48
$V - po \times 100/OFC$ acrocephalic index = (vertex-porion chord/OCF)	24.89

*the location of the craniometric point was estimated; # index proposed by Oostra et al. (2005); the numbers in parentheses following to Martin and Saller (1957) description. The values of indices are dimensionless.

Polskie, XIX w.” (Polish Kingdom, 19th century), belonging to the osteological collection of the Department of Anthropology, L. Hirszfeld Institute of Immunology and Experimental Therapy of the Polish Academy of Sciences in Wrocław. Skull No 131 was in a good state of preservation but lacked the mandible (Fig. 1a–d). The postcranial elements of the skeleton were also absent. To clarify the archaeological background of this skull, the radiocarbon dating procedure had been carried out. Results of the ¹⁴C calibration dates range between the years 1686 and 1927 with the probability at the level of 95.4%.

The sex of the individual was estimated as a female, according to the method established by Ferembach and Schwidetzky (1980). Based on the presence of the right third permanent molar in the maxilla and fused spheno-occipital synchondrosis (Fig. 1a–d), it can be concluded, that cranium No 131 belonged to an individual who was an adult at the time of death.

The standard cranial measurements of cranium No 131 were taken with sliding and spreading calipers according to Martin and Saller (1957) method. To measure the volume of the *neurocranium*, linseed was used (Breitinger 1936). Several indices describing the shape of the *neurocranium* and *splanchnocranium*, the size of the *splanchnocranium* in relation to the size of the *neurocranium*, as well as the acrocephalic index described by Oostra et al. (2005) were also calculated (Table 1).

The CT analysis and 3D–CT reconstructions of the examined skull were also performed for a more accurate assessment of the relation between the craniofacial structures and the *neurocranium* (Fig. 1c–d). To detect platybasia in the examined skull, the value of the Welcher’s basal angle was calculated. A value of this

angle greater than 140° indicates the presence of platybasia (Canon, Canon 2009, Harnsberger et al. 2006). Klaus’s index, which allows estimating the degree of the basilar invagination was also calculated.

Results

Skull No 131 has rounded and regular shape of the *neurocranium* and almost complete fusion of all cranial sutures. The horizontal circumference is only 442 mm and intracranial volume is only 950 ml, thus the skull is metrically and visually smaller than other skulls from the Polish Kingdom series (Fig. 2a–b).

In the frontal view of the skull, large, rhomboid in shape and symmetrical or-

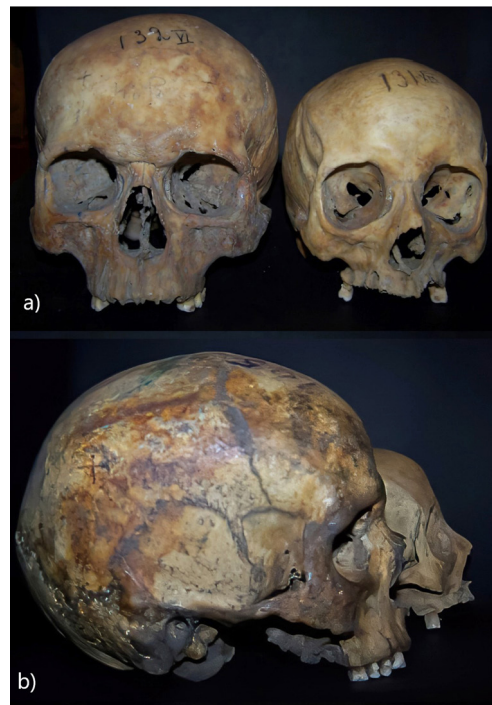

Fig. 2. Comparison between skull No 131 XIX and another skull from the Polish Kingdom series a) anterior aspect – KP 131 XIX on the right, b) lateral aspect (KP 131 XIX in the background).

bits are visible. The frontal bone is round and upright with prominent frontal eminences. The facial profile is slightly prognathic with strongly prominent nasal bones and slightly upturned anterior nasal spine (Fig. 1 and 2).

Most of the individual's dentition was lost post-mortem and some teeth ante mortem due to the pathological inflam-

matory processes caused by oral health problems. Only two of all the teeth (two permanent molars) had been left in the upper arch.

The lateral walls of the *neurocranium* show a significant degree of thinning. Bone tissue within the larger wing of the sphenoid (particularly left) (Fig. 3a) and roofs of the orbits is regionally translu-




Fig. 3. The thinning within the *neurocranium* of the KP 131 XIX

a) Close-up photograph showing thinning within left greater wing of the sphenoid bone, with visible translucencies, b) Photograph showing the thinning of the upper roof of the left orbit.

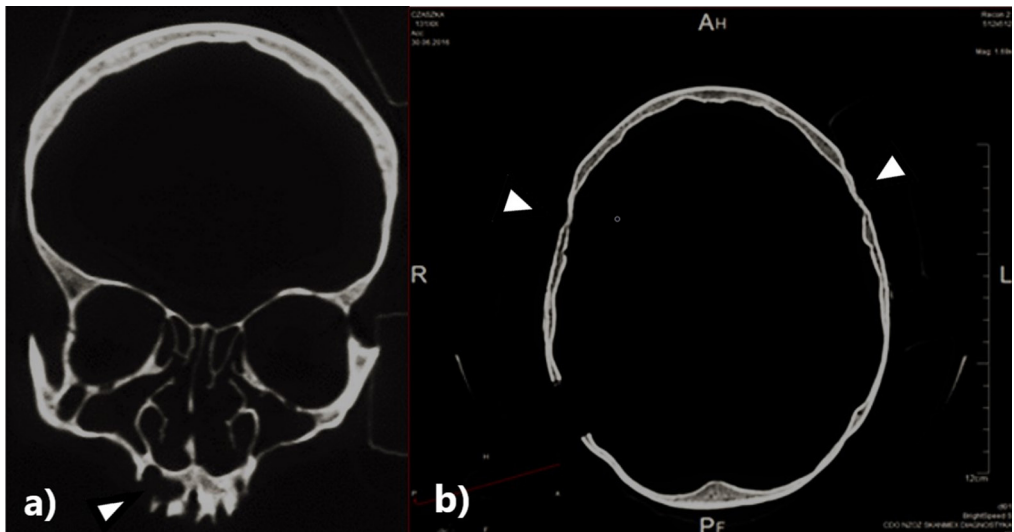


Fig. 4. Abnormalities in the cranial vault thickness

a) CT scan image showing thinning of the lateral walls of the *neurocranium* (coronal slice); note extensive lesions of inflammatory origin within the maxilla (marked with an arrow), b) CT scan showing lateral thinning of the cranium (horizontal slice)

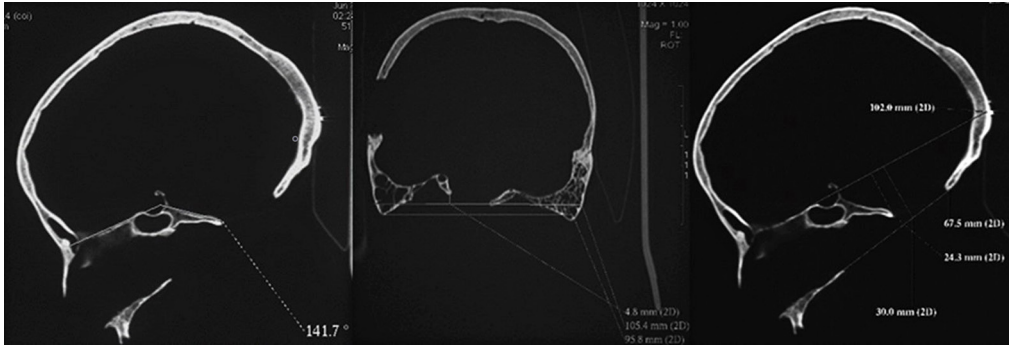


Fig. 5. CT scans based measurements

a) basal angle measurements, b) asymmetrical localization of the occipital condyles and their elevation above the line connecting the tips of the mastoid processes, c) presence of the basilar invagination.

cent (Fig. 3b). The thinning was also visible on the CT scans as grooving of the internal laminae of both temporal squamae, with more intensive on the left side (Fig. 4a–b); the occipital squama was also symmetrically thinned.

The Welcher's angle value is 141.7° which confirms the presence of platybasia and the *foramen magnum* lies significantly higher in relation to the bimastoid line. Additionally, it is situated asymmetricaly, about 5 mm higher on the right side (Koenigsberg et al. 2005). The low value of Klaus's index – probably less than 30 mm (between 24.3 and 30.0 mm) indicates an increased depth of the posterior cranial fossa and confirms the presence of the basilar invagination (Canon, Canon 2005, Yochum, Rowe 2011) (Fig. 5).

Discussion

Rare diseases are a challenge in paleopathological research, mainly due to the ambiguity of skeletal signs, bad preservation state of the osteological material and lack of the reference material. There are not many publications dedicated to the anomalies of the cranial sutures' obliteration and most of them relate to the sin-

gle suture synostosis (Giuffra et al. 2011, Skrzat et al. 2014, Évinger et al. 2016). Archaeological cases referring to panocraniosynostosis are extremely rare mainly due to the fact that there are difficulties in distinguishing panocraniosynostosis from some forms of microcephaly. Oostra et al. (2005) define it as a "chicken-versus-egg" problem as it is not always clear whether microcephaly may be the cause of the craniosynostosis although there are reports regarding multisuture CS as a cause of microcephaly.

It should be noted that most shape anomalies can also result from other, non-suture-related conditions, most of which have a postnatal, exogenous cause (Oostra et al. 2016). For instance, it has been proved that hypophosphatemic rickets is associated with synostosis of the single suturae (especially sagittal, lambdoid and coronal), as well as the panocraniosynostosis (Vega et al. 2016).

In the case of KP 131 XIX, small OFC and lower cranial capacity existed together with the features of elevated intracranial pressure (ICP) that caused the remodelling of the fronto-lateral segments of the *neurocranium*. Platybasia was also observed in the examined skull and this

pathology is usually recognized as a characteristic sign of Arnold Chiari malformations frequently associated with higher values of ICP (McClugage, Oakes 2019).

The above-described features indicate that the cranial sutures must have been closed while the brain was still expanding, and pathological changes caused by increasing ICP occurred during the postnatal growth of the cranium. This situation corresponds with the clinical picture of progressive postnatal pan-craniosynostosis (PPP) which occurs late during an individual's ontogeny and typically presents with signs of increased intracranial pressure with rather normal, albeit smaller than average head size (Wood et al. 2015).

PPP may have various backgrounds and is frequently observed as a syndromic form, especially in Crouzon's syndrome, Apert's syndrome, or Pfeiffer's syndrome which are associated with mutations in FGRFR genes (Blount et al. 2007). Another group of syndromes associated with multiple sutures craniosynostosis is related to ERF genes which can be characterized by a wide spectrum of developmental disorders including a greater tendency to multisutural synostosis. According to Glass et al. (2019), ERF-related craniosynostosis may develop after birth in the first few years, evolve insidiously, and be associated with a relatively normal head shape.

Conclusions

Cranium No 131 presents a complex of pathologies. Potentially all of them, especially decreased values of the metric traits, thinned lateral regions of the *neurocranium* and platybasia may have had a common cause in some form of syndromic disorders.

The Authors' contributions

AC designed and directed the project and wrote the manuscript, WN performed anthropological measurements and worked on the manuscript, AK performed radiological analyses of the cranium, MH aided in interpreting the results and worked on the manuscript. All authors read the final version of the manuscript.

Conflict of interest

The authors declare that there is no conflict of interest.

Corresponding author

Agata Cieřlik, Hirszfild Institute of Immunology and Experimental Therapy, Polish Academy of Sciences, Department of Anthropology, Wrocław, Podwale 75, 50-449
e-mail: agata.cieslik@hirszfild.pl

References

- Blount JP, Louis RG, Tubbs RS. 2007. Pan-synostosis: a review. *Childs Nerv Syst* 23: 1103–9.
- Breiting E. 1936. Zur Messung der Schädelkapazität mit Senfkörnern. *Anthropol Anz* 13:140–8.
- Buchanan EP, Xue Y, Xue AS, Olshinka A, Lam S. 2017. Multidisciplinary care of craniosynostosis. *J Multidiscip Healthc* 10:263–70.
- Canon L, Canon C. 2009. *Radiology*. New York: McGraw Hill Professional.
- Évinger S, Hajdu T, Biró G, Zádori P, Marcsik A, Molnár E, Wolff K. 2016. A case of unilateral coronal synostosis from Medieval Hungary (9th century A.D.). *Anthropol Anz* 73(1):81–8.
- Ferembach D, Schwidetzky ISM. 1980. Recommendations for age and sex diagnoses of skeletons. *J Hum Evol* 9:517–49.

- Fonesca JM, Borém LMA. 2014. Cloverleaf skull syndrome: case report. *Radiol Bras* 47(3):189–90.
- Foo R, Whitaker LA, Bartlett SP. 2010. Normocephalic pancraniosynostosis resulting in late presentation of elevated intracranial pressures. *Plast Reconstr Surg* 125:1493–502.
- Giuffra V, Sbrana F, Caramella D, Giustini D, Tixier B, Fornaciari G. 2011. Syndromic craniosynostosis in a modern-age skeleton from Siena, Italy. *J Craniofac Surg* 22(5):1743–5.
- Glass GE, O'Hara J, Canham N, Cilliers D, Dunaway D, Fenwick AL, Jeelani N, Johnson D, Lester T, Lord H, Morton JEV, Nishikawa H, Noons P, Schwiebert K, Shipster C, Taylor-Beadling A, Twigg SRF, Vasudevan P, Wall SA, Wilkie AOM, Wilson LC. 2019. ERF-related craniosynostosis: The phenotypic and developmental profile of a new craniosynostosis syndrome. *Am J Med Genet* 179A:615–27.
- Harnsberger HR, Osborn AG, Ross JS. 2006. Diagnostic and surgical imaging anatomy. Brain, head, neck, spine. Amirsys.
- Koenigsberg RA, Vakil N, Hong TA, Htaik TT, Faerber EN, Maiorano T, Dua MM, Faro S., Gonzales C. 2005. Evaluation of platybasia with MR imaging. *Am J Neuroradiol* 26(1):89–92.
- Martin R, Saller K. 1957. *Lehrbuch der Anthropologie*. Stuttgart: Gustav Fischer Verlag.
- McCluggage SG, Oakes WJ. 2019. The Chiari I malformation. *J Neurosurg Pediatr* 24:217–26.
- Oostra RJ, van der Wolk S, Maas M, Hennekam RCM. 2005. Malformations of the Axial Skeleton in the Museum Vrolik: II: Craniosynostoses and Suture-Related Conditions. *Am J Med Genet* 136A:327–42.
- Oostra RJ, Boer L, Van der Merve AE. 2016. Paleodysmorphology and Paleoteratology: Diagnosing and Interpreting Congenital Conditions of the Skeleton in Anthropological Contexts. *Clin Anat* 29:878–91.
- Skrzat J, Stepańczak B, Walocha J. 2014. The scaphocephalic skull of an adult male. *Folia Morphol* 3(1):92–8.
- Wood BC, Oh AK, Keating RF, Boyajian MJ, Myseros JS, Magge SN, Rogers GF. 2015. Progressive postnatal pansynostosis: an insidious and pernicious form of craniosynostosis. *J Neurosurg Pediatr* 16(3):309–16.
- Vega R, Opalak Ch, Harshbarger RJ, Fearon JA, Ritter AM, Collins JJ, Rhodes JL. 2016. Hypophosphatemic rickets and craniosynostosis: a multicenter case series. *J Neurosurg Pediatr* 17:694–700.
- Yochum RT, Rowe JL. 2005. *Essentials of Skeletal Radiology* (3rd ed.). Baltimore: Lippincott Williams and Wilkins.