



**University of
Zurich** UZH

**Zurich Open Repository and
Archive**

University of Zurich
University Library
Strickhofstrasse 39
CH-8057 Zurich
www.zora.uzh.ch

Year: 2022

Exacerbation of familial intrahepatic cholestasis in conjunction with COVID-19 vaccination

Guri, Yakir ; Vosbeck, Jürg ; Dickenmann, Michael ; Jetter, Alexander ; Bernsmeier, Christine

DOI: <https://doi.org/10.1016/j.jhep.2022.05.003>

Posted at the Zurich Open Repository and Archive, University of Zurich

ZORA URL: <https://doi.org/10.5167/uzh-222346>

Journal Article

Published Version



The following work is licensed under a Creative Commons: Attribution 4.0 International (CC BY 4.0) License.

Originally published at:

Guri, Yakir; Vosbeck, Jürg; Dickenmann, Michael; Jetter, Alexander; Bernsmeier, Christine (2022). Exacerbation of familial intrahepatic cholestasis in conjunction with COVID-19 vaccination. *Journal of Hepatology*, 77(3):872-874.

DOI: <https://doi.org/10.1016/j.jhep.2022.05.003>

months prior to donation. Although donors IE-112 and IE-224 donated within 1 week of each other, one lived in Dublin whilst the other lived in a rural area on the West coast. None of the donors travelled abroad in the 9 weeks prior to donation suggesting autochthonous transmission of HEV. No post-donation illnesses were reported. HEV-3ra sequences have mainly been identified in immunosuppressed individuals^{9,10} and the detection of IE-568 in a healthy blood donor is noteworthy. With the identification of the novel isolates IE-112 and IE-224, forming a new clade and potentially a tentative new genotype, further investigations are required to understand potential animal origins associated with these Irish isolates and potential routes of transmission which, in the case of HEV-3ra, where it has been identified in humans, remain elusive.

Financial support

The Irish Department of Health provided financial support for HEV blood donor screening by the Irish Blood Transfusion Service. In addition, this work was funded in part by core funding by the German Federal Ministry of Health (Bundesministerium für Gesundheit) (S.A.B.) and a grant ZMV11-2518FSB705 (V.M.C).

Conflicts of interest

The authors declare no conflicts of interest.

Please refer to the accompanying ICMJE disclosure forms for further details.

Authors' contributions

S.A.B - analysis of HEV-positive donor samples, writing and review of manuscript; N.O'F - HEV screening, review of manuscript; L.B. - HEV screening, review of manuscript; B.H. - analysis of HEV-positive samples, review of manuscript; VMC - analysis of HEV-positive donor samples, writing and review of manuscript.

Acknowledgements

We thank Michel Molier and Roswitha Kleiber for excellent technical assistance and Julia Schneider, Jörn Beheim-Schwarzbach and Tobias Blecker for help with sequencing.

Supplementary data

Supplementary data to this article can be found online at <https://doi.org/10.1016/j.jhep.2022.04.015>.

References

Author names in bold designate shared co-first authorship

- [1] Cordes AK, Goudeva L, Lütgehetmann M, Wenzel JJ, Behrendt P, Wedemeyer H, et al. Risk of transfusion-transmitted hepatitis E virus infection from pool-tested platelets and plasma. *J Hepatol* 2022;76:46–52.
- [2] van der Poel WH, Verschoor F, van der Heide R, Herrera MI, Vivo A, Kooreman M, et al. Hepatitis E virus sequences in swine related to sequences in humans, The Netherlands. *Emerging Infect Dis* 2001;7:970–976.
- [3] **Drexler JF, Seelen A**, Corman VM, Fumie Tateno A, Cottontail V, Melim Zerbinati R, et al. Bats worldwide carry hepatitis E virus-related viruses that form a putative novel genus within the family Hepeviridae. *J Virol* 2012;86:9134–9147.
- [4] Tamura K, Stecher G, Kumar S. MEGA 11: molecular evolutionary genetics analysis version 11. *Mol Biol Evol* 2021;38:3022–3027.
- [5] Smith DB, Izopet J, Nicot F, Simmonds P, Jameel S, Meng XJ, et al. Update: proposed reference sequences for subtypes of hepatitis E virus (species Orthohepevirus A). *J Gen Virol* 2020;101:692–698.
- [6] Cierniak F, von Arnim F, Heckel G, Ulrich RG, Groschup MH, Eiden M. A Putative novel hepatitis E virus genotype 3 subtype identified in rabbit, Germany 2016. *Viruses* 2021;13:1065.
- [7] Schilling-Loeffler K, Viera-Segura O, Corman VM, Schneider J, Gadicherla AK, Schotte U, et al. Cell culture isolation and whole genome characterization of hepatitis E virus strains from wild boars in Germany. *Microorganisms* 2021;9:2302.
- [8] Baylis SA, Hanschmann KO, Matsubayashi K, Sakata H, Roque-Afonso AM, Kaiser M, et al. Development of a World Health Organization International Reference Panel for different genotypes of hepatitis E virus for nucleic acid amplification testing. *J Clin Virol* 2019;119:60–67.
- [9] Abravanel F, Lhomme S, El Costa H, Schvartz B, Peron JM, Kamar N, et al. Rabbit hepatitis E virus infections in humans, France. *Emerging Infect Dis* 2017;23:1191–1193.
- [10] Sahli R, Fraga M, Semela D, Moradpour D, Gouttenoire J. Rabbit HEV in immunosuppressed patients with hepatitis E acquired in Switzerland. *J Hepatol* 2019;70:1023–1025.

Sally A. Baylis^{1,*}

Niamh O'Flaherty²

Lisa Burke²

Boris Hogema³

Victor M. Corman^{4,5}

¹Paul-Ehrlich-Institut, Langen, Germany

²Irish Blood Transfusion Service, Dublin, Ireland

³Sanquin, Amsterdam, The Netherlands

⁴Charité-Universitätsmedizin Berlin, Berlin, Germany

⁵German Center for Infection Research, Berlin, Germany

*Corresponding author. Address: Paul-Ehrlich-Institut, Paul-Ehrlich Straße 51-59, D-63225 Langen, Germany; Tel.: 0049 (0) 6103 773803.

E-mail address: Sally.Baylis@pei.de (S.A. Baylis)



Exacerbation of familial intrahepatic cholestasis in conjunction with COVID-19 vaccination

To the Editor:

The devastating global impact of the COVID-19 pandemic led to the fast development of efficient anti-COVID-19 vaccines. These

have in rare instances been associated with side effects including autoimmune hepatitis.^{1,2}

Herein, we report the case of a 53-year-old man presenting in our emergency department with jaundice and pruritus. Within 48 hours following BTN162b2 Pfizer-BioNTech mRNA COVID-19 vaccination he felt fatigued, developed nausea, severe ubiquitous pruritus and a temperature (37.5–38°C). Progressive

Received 28 April 2022; accepted 4 May 2022; available online 16 May 2022
<https://doi.org/10.1016/j.jhep.2022.05.003>

jaundice occurred within 72 h post vaccination. He denied consuming drugs, rarely drank alcohol, had no allergies and had no history of suspicious travel nor contact with animals. SARS-CoV-2 infection was repeatedly excluded (positive SARS-CoV-2 spike-antibodies [17.7 U/ml]; negative SARS-CoV-2 nucleocapsid-antibodies [0.107 COI]). He reported having been diagnosed with benign recurrent intrahepatic cholestasis (BRIC, Summerskill-Walshe-Tygstrup-Syndrome) in early childhood, as had 4 of his 13 siblings.

The clinical examination showed jaundice and excoriations. Vital signs and neurology were normal. An abdominal examination revealed no tenderness, a normal liver and spleen and no ascites. Upon admission, laboratory tests revealed hyperbilirubinemia (total bilirubin 480 $\mu\text{mol/L}$, upper limit of normal [ULN] 24 $\mu\text{mol/L}$), elevated alkaline phosphatase (412 U/L, ULN 130 U/L), bile acids (232.7 $\mu\text{mol/L}$, ULN 8 $\mu\text{mol/L}$), ALT 99 U/L (ULN 59 U/L), and AST 61 U/L (ULN 34 U/L). GGT, INR, albumin and creatinine were initially normal (Fig. 1A). An extensive workup showed no evidence for viral (HAV, HBV, HCV, HEV), autoimmune hepatitis or Wilson's disease and no signs of mechanical bile duct obstruction or cirrhosis. A presumptive diagnosis of cholestatic disorder was confirmed by liver histopathology showing marked canalicular and intracytoplasmic cholestasis in all zones, predominantly zone

III, with mild predominantly portal immune cell infiltration, particularly of macrophages, and minimal signs of portal fibrosis (Fig. 1B). Based on the above, he was diagnosed with an exacerbation of BRIC and a therapy with colestyramine 4 g b.i.d. and ursodeoxycholic acid 250 mg t.i.d., followed by rifampicin 150 mg b.i.d. and phototherapy was initiated. Subsequently the patient deteriorated, developing acute kidney injury (AKI, creatinine max. 353 $\mu\text{mol/L}$ [ULN 97 $\mu\text{mol/L}$]) due to bile-cast nephropathy (bilirubin max. 665 $\mu\text{mol/L}$; bilirubin-casts in urinary sediment). He was transferred to intensive care for temporary continuous veno-venous haemofiltration in combination with a Cytosorb[®] filter. Under this treatment clinical symptoms and renal function improved. Bilirubin levels peaked 8 weeks following vaccination and normalised within 16 weeks (Fig. 1A). The case was reported to the Swiss authority for drugs and therapeutic products (Swissmedic); causality was assessed as "possible" according to WHO criteria.

Genetic testing of the entire coding and flanking intronic sequence of the associated genes *ATP8B1*, *ABCB11* and *ABCB4* by next-generation sequencing revealed a rare, likely pathogenic homozygous missense variant in the *ATP8B1* gene in the patient. The detected variant c.749T>A (reference sequence NM_005603; chr18: g.55362714 (hg19)) is expected to result in an amino acid exchange of the highly conserved leucine to histidine at position 250 of the protein (p.(Leu250His)), which is predicted to have a deleterious effect on protein function by automated online prediction tools (SIFT, PolyPhen2, MutationTaster, CADD). The variant has no allele frequency in the population (e.g. not observed in gnomAD v2.1) and was just recently reported in a compound heterozygous constellation with another variant in a patient with familial intrahepatic cholestasis type 1 deficiency.³ No other potentially pathogenic variant was detected in *ATP8B1*, *ABCB11* and *ABCB4*. Genetic testing by Sanger sequencing in 9 of his available siblings prove the variant c.749T>A p.(Leu250His) to segregate with the BRIC phenotype in the homozygous state (3 affected homozygous siblings, 5 heterozygous and one non-mutated unaffected sibling). Of note, one affected sister received COVID-19 vaccination without experiencing a BRIC manifestation. The reasons for the different clinical evolution remain unknown. Potential factors such as her advanced age, variable gene expression or other genetic factors may have contributed.

The typical temporal relationship in the absence of other possible triggers suggests that BRIC exacerbation in this patient likely resulted from COVID-19 vaccination. Yet, direct causality cannot be definitively established. This is, to our knowledge, the first report of BRIC exacerbation developing post COVID-19 vaccination. The WHO database on adverse drug effects has reported no case of progressive familial intrahepatic cholestasis (PFIC) in combination with a COVID-19 vaccination to date (04 APR 2022, BRIC is not a search term). The underlying mechanism remains unclear, it is possible that immune responses and cytokine release triggered cholestasis similar to immune responses following infection. Previously, BRIC exacerbation was reported to occur following hepatitis A vaccination.⁴

We do not intend to discourage COVID-19 vaccination. Nonetheless, this severe manifestation of cholestasis complicated by AKI requiring intensive care in a patient with BRIC1 related to a homozygous *ATP8B1* variant should arouse our awareness of unknown hepatic responses to COVID-19 vaccination.

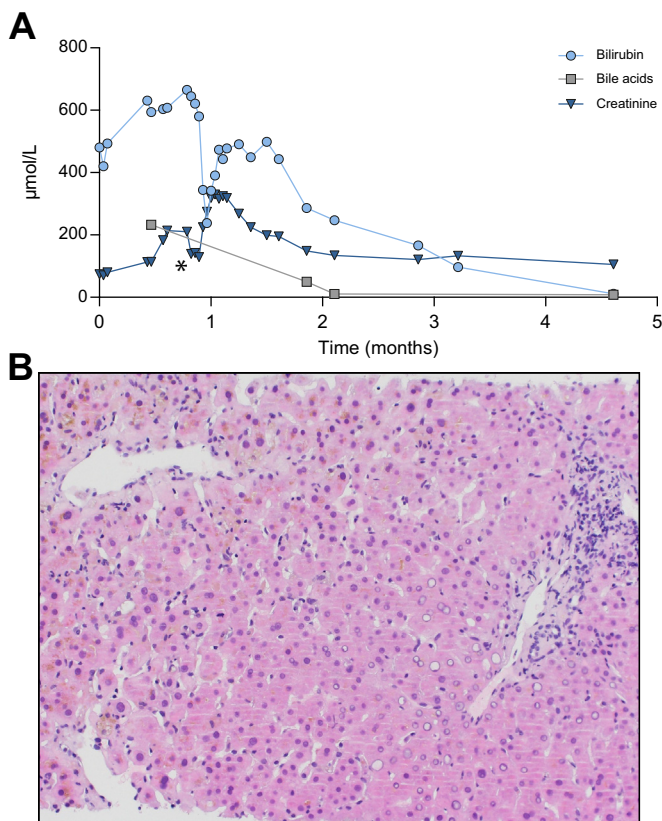


Fig. 1. 53-year-old patient with benign recurrent intrahepatic cholestasis. (A) The levels of bilirubin, bile acids and creatinine over the course of the BRIC exacerbation. On the x axis depicted is the time in months from the onset of BRIC exacerbation; an asterisk indicates the time over 5 days of continuous veno-venous haemofiltration (cvvHF) treatment. (B) Liver histology (H&E stain) of the index patient exhibiting a BRIC exacerbation. Marked canalicular and intracytoplasmic cholestasis in all liver zones, predominantly in Zone III with mild immune cell infiltration, magnification 200x. BRIC, benign recurrent intrahepatic cholestasis.

Financial support

The authors received no financial support to produce this manuscript.

Conflict of interest

The authors declare no conflicts of interest that pertain to this work.

Please refer to the accompanying ICMJE disclosure forms for further details.

Authors' contributions

YG, MD & CB, clinical care of the patient; YG & CB, drafting of the manuscript; JV, histopathological evaluation; AJ, genetic data analysis and interpretation. JV, MD, AJ & CB, critical revision of the manuscript;

Data availability statement

Additional data is available upon request to the corresponding author.

Acknowledgements

We acknowledge the whole patients' family who participated in the genetic family testing. Moreover, we acknowledge Julia Laube and Dr. Markus Zweier from the Institute of Medical Genetics at the University of Zurich for performing the sequencing analyses.

Supplementary data

Supplementary data to this article can be found online at <https://doi.org/10.1016/j.jhep.2022.05.003>.

References

- [1] Shroff H, Satapathy SK, Crawford JM, Todd NJ, VanWagner LB. Liver injury following SARS-CoV-2 vaccination: a multicenter case series. *J Hepatol* 2021. <http://dx.doi.org/10.1016/j.jhep.2021.07.024>. 0(0).
- [2] Tun GSZ, Gleeson D, Dube A, Al-Joudeh A. Immune-mediated hepatitis with the Moderna vaccine, no longer a coincidence but confirmed. *J Hepatol* 2021. <http://dx.doi.org/10.1016/j.jhep.2021.09.031>. S0168827821020936.
- [3] van Wessel DBE, Thompson RJ, Gonzales E, Jankowska I, Shneider BL, Sokal, et al. Impact of genotype, serum bile acids, and surgical biliary diversion on native liver survival in FIC1 deficiency. *Hepatology* 2021;74(2):892–906. <http://dx.doi.org/10.1002/hep.31787>.
- [4] Folvik G, Hilde O, Helge GO. Benign recurrent intrahepatic cholestasis: review and long-term follow-up of five cases. *Scand J Gastroenterol* 2012;47(4):482–488. <http://dx.doi.org/10.3109/00365521.2011.650191>.

Yakir Guri¹

Jürg Vosbeck²

Michael Dickenmann³

Alexander Jetter⁴

Christine Bernsmeier^{1,*}

¹University Centre for Gastrointestinal and Liver Diseases, University Hospital Basel, Basel, Switzerland

²Institute of Medical Genetics and Pathology, University Hospital Basel, Basel, Switzerland

³Clinic for Transplantation Immunology and Nephrology, University Hospital Basel, Switzerland

⁴Tox Info Suisse and Department of Clinical Pharmacology and Toxicology, University Hospital Zurich, University of Zurich, Switzerland

*Corresponding author. Address: University Centre for Gastrointestinal and Liver Diseases, University Hospital Basel,

Petersgraben 4, CH-4031 Basel, Switzerland. Tel.: +41-61-7777400, fax: +41-61-7777511.

E-mail address: c.bernsmeier@unibas.ch (C. Bernsmeier)



Impaired mitochondrial complex IV respiration in peripheral blood mononuclear cells discriminates acute-on-chronic liver failure from acute decompensation

To the Editor:

Systemic inflammation is discussed as a new paradigm in the development of acute decompensation (AD) and acute-on-chronic liver failure (ACLF).^{1–4} Systemic inflammation can result in dysregulation of mitochondrial bioenergetics in leukocytes,⁵ and, reciprocally, impaired mitochondrial function contributes causally to dysfunctional immunity.⁶ Two elegant studies by Moreau *et al.* and Zhang *et al.*, published in the *Journal of Hepatology*, have revealed that AD and in particular ACLF are associated with mitochondrial dysfunction in organs and immune cells.^{7,8}

In detail, an untargeted serum metabolome analysis by Moreau *et al.* revealed a metabolite fingerprint of ACLF indicating a rise in the blood levels of fatty acylcarnitines due to depressed

mitochondrial β -oxidation in peripheral organs, which seems to be paralleled by increased extra-mitochondrial glucose and amino acid metabolism.⁷ Zhang *et al.* performed an in-depth analysis of mitochondrial metabolism and ultrastructure in peripheral blood mononuclear cells (PBMCs) of patients with AD or ACLF, which identified cristae rarefaction and mitochondrial swelling, as well as an impaired tricarboxylic acid cycle associated with alternative energy production from carbon and nitrogen sources.⁸ However, these studies left open whether the described changes are accompanied by a reduction in mitochondrial respiration itself. We therefore analyzed in detail the function of mitochondrial respiration complexes in PBMCs of patients with AD or ACLF. Detailed methods are described in the [supplementary methods](#).

Patient characteristics are shown in [Table S1](#). One can note a typical clinical profile of patients with AD or ACLF, with the exception of high albumin levels in patients with ACLF. This is

Received 13 April 2022; received in revised form 25 April 2022; accepted 26 April 2022; available online 11 May 2022
<https://doi.org/10.1016/j.jhep.2022.04.037>