



**University of
Zurich**^{UZH}

**Zurich Open Repository and
Archive**

University of Zurich
University Library
Strickhofstrasse 39
CH-8057 Zurich
www.zora.uzh.ch

Year: 2022

The 'beating-heart butterfly technique' for repair of basal post-infarction ventricle septum defect

Mihalj, Maks ; Pasic, Miralem ; Carrel, Thierry

DOI: <https://doi.org/10.1093/icvts/ivac026>

Posted at the Zurich Open Repository and Archive, University of Zurich

ZORA URL: <https://doi.org/10.5167/uzh-229062>

Journal Article

Published Version



The following work is licensed under a Creative Commons: Attribution-NonCommercial 4.0 International (CC BY-NC 4.0) License.

Originally published at:

Mihalj, Maks; Pasic, Miralem; Carrel, Thierry (2022). The 'beating-heart butterfly technique' for repair of basal post-infarction ventricle septum defect. *Interactive Cardiovascular and Thoracic Surgery*, 34(5):919-920.

DOI: <https://doi.org/10.1093/icvts/ivac026>

Cite this article as: Mihajl M, Pasic M, Carrel T. The 'beating-heart butterfly technique' for repair of basal post-infarction ventricle septum defect. *Interact CardioVasc Thorac Surg* 2022;34:919–20.

The 'beating-heart butterfly technique' for repair of basal post-infarction ventricle septum defect

Maks Mihajl ^a, Miralem Pasic ^{a,b} and Thierry Carrel ^{a,c,*}

^a Department of Cardiovascular Surgery, University Hospital and University of Bern, Bern, Switzerland

^b Department of Cardiovascular Surgery, German Heart Center, Berlin, Germany

^c Department of Cardiac Surgery, University Hospital Zürich, Zurich, Switzerland

* Corresponding author. Department of Cardiac Surgery, University Hospital Zurich, CH-8091 Zurich, Switzerland. Tel: +41 44 255 47 29; e-mail: thierry.carrel@usz.ch (T. Carrel).

Received 11 August 2021; received in revised form 13 January 2022; accepted 24 January 2022

Abstract

Ischaemic ventricular septal defect is a serious complication of acute myocardial infarction with poor outcome. We present the 'beating-heart butterfly' technique to close the ventricular septal defect with a double-layered pericardial patch sewn to the intact septum under beating-heart cardiopulmonary bypass in 4 highest-risk patients. This technique combined with a liberal postoperative mechanical circulatory support and open-chest treatment allowed excellent results with 12 months of survival in all patients.

Keywords: Infarction • Ventricular septal defect • Surgical repair • Beating heart • Butterfly technique

INTRODUCTION

Post-infarction ventricular septal defect (VSD) is a serious condition associated with poor outcome [1]. While surgical repair using hypothermic cardioplegic cardiac arrest remains treatment of choice, the ideal timing remains uncertain due to fragilized tissue immediately post-infarction [2, 3]. Postponement of the procedure using circulatory support (veno-arterial extracorporeal membrane oxygenation and intra-aortic balloon pump) may be associated with better outcomes [4]. We present 4 patients with post-infarction basal VSD who received a novel 'beating-heart butterfly technique' to close the defect under normothermic cardiopulmonary bypass.

CASE PRESENTATION AND OPERATIVE TECHNIQUE

Surgical repair of a large basal post-infarction VSD was performed under normothermic bypass in 4 male patients (mean age 68 years): all received intra-aortic balloon pump and 1 veno-arterial extracorporeal membrane oxygenation support. Written informed consent was obtained from all patients.

The reconstruction of the septum is performed using a double-layered bovine xenopericardial patch in a modified 'butterfly' technique. The left ventricle is opened parallel to the

posterior descending branch (Fig. 1A). The folded pericardial patch is first sutured close to the annular level using U-stitches of Prolene 2.0 (SH needle) with the pledgets on the right side of the septum (Fig. 1B). Attention is paid to the atrioventricular valve and the subvalvular structures which are pulled aside by the assisting surgeon. The sutures are placed as deep as possible in the intact myocardium, whilst necrotic tissue is parsimoniously resected. After anchoring the patch at the basal level, continuous suturing is used to close both ventricles. Each layer of the pericardial patch is used to close the corresponding ventricle (Fig. 1C). The double-layered pericardial patch opens up 'as a butterfly', with one side used for the reconstruction of the left ventricle and the other for the right ventricle (Fig. 1D). The heart is repositioned in the pericardial cavity (Fig. 1E) and careful de-airing is performed through the aortic root cannula. The main steps are summarized in the intraoperative pictures (Fig. 2). In 3 patients, coronary artery bypass grafting was performed prior to VSD-repair and 1 patient received percutaneous coronary intervention prior to surgery. One patient received a bioprosthetic tricuspid valve replacement.

All patients were weaned from cardiopulmonary bypass with low catecholamine support while the preoperative mechanical support was continued. The chest was left open but the skin closed in all patients (mean duration of 3.5 days). Intra-aortic balloon pump-support could be removed between 2 and 5 days after surgery (median 3.5 days).

Postoperative intensive care unit-stay was 3, 7, 8 and 21 days (median 9.7 days), and median hospital stay was 23 days. All

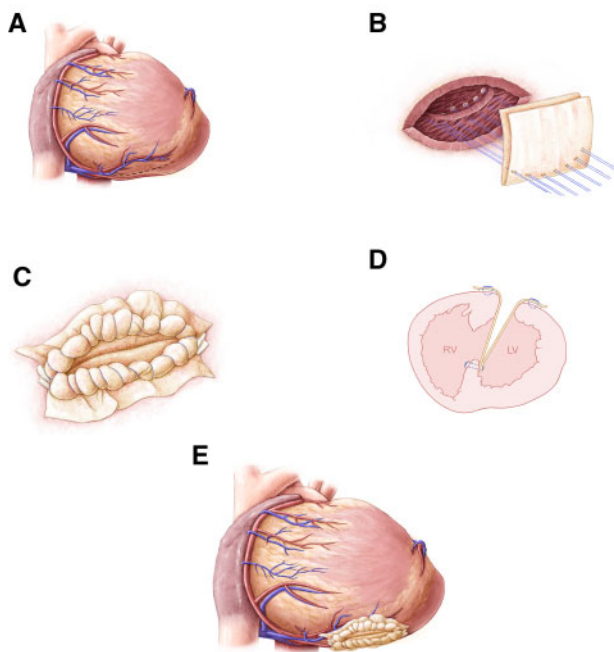


Figure 1: (A) The basal ventricular septum defect is approached through the left ventricle (incision parallel to the posterior descending artery). (B) A folded xenopericardial patch is attached on the left side of the septum with interrupted sutures that are reinforced with Teflon pledgets placed on the right side. (C) Each layer of the patch is used to reconstruct and close the corresponding ventricle. (D) Schematic representation of the double-layered 'butterfly patch'. (E) Repositioning of the heart in the pericardial cavity after closing both ventricles.

patients were discharged to a rehabilitation facility. Postoperative echocardiography showed a small residual VSD in 1 patient, which was closed with an Amplatzer occluder device (Abbott Laboratories, Abbott Park, IL, USA) 9 months after surgery. All patients were alive at 12 months of follow-up. Left ventricular function recovered in 3 patients and no patient had a residual shunt at 1 year of follow-up.

COMMENT

The 'beating-heart butterfly technique', avoiding additional ischaemia, is a promising technique to repair basal post-infarction VSD. All additional procedures (coronary artery bypass grafting, mitral, tricuspid valve repair/replacement) can be performed on beating heart as well. Optimized postoperative management including liberal use of mechanical circulatory support (MCS) and open-chest treatment was associated with 1 year of survival in all patients.

ACKNOWLEDGEMENT

The authors thank Mrs Nadja Baltensweiler, Ebikon, Switzerland, for the drawing of the main steps of this technique (www.nadjabaltensweiler.ch).

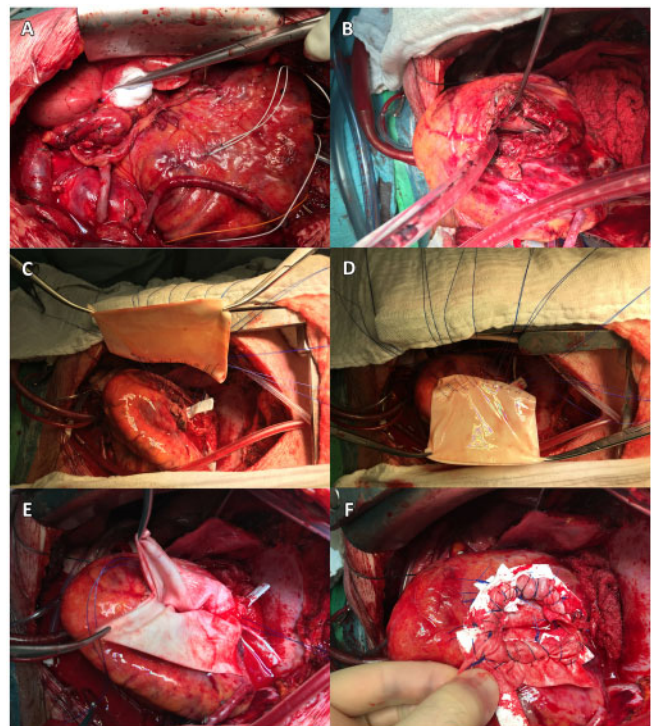


Figure 2: Intraoperative pictures of basal ventricular septal defect repair using a modified 'beating-heart butterfly technique' as a step-by-step approach (A–F). (A) Prior coronary revascularization with bypass grafting. (B) Opening the left ventricle parallel to the posterior descending artery through the infarcted tissue to access the basal ventricular septal defect. (C) Deep Teflon-armed U-stitches into the residual healthy septum. (D) These stitches are passed through a folded xenopericardial patch. (E) Continuous suturing to close each ventricle using one side of the patch. The patch opens up as a 'butterfly'. (F) Final view after closure of both ventricles.

Conflict of interest: none declared.

Reviewer information

Interactive CardioVascular and Thoracic Surgery thanks Pasquale Totaro and the other anonymous reviewers for their contribution to the peer review process of this article.

REFERENCES

- [1] Sakaguchi G, Miyata H, Motomura N, Ueki C, Fukuchi E, Yamamoto H *et al.* Surgical repair of post-infarction ventricular septal defect—findings from a Japanese National Database. *Circ J* 2019;83:2229–35.
- [2] Deja MA, Szostek J, Widenka K, Szafron B, Spyt TJ, Hickey MS *et al.* Post infarction ventricular septal defect—can we do better? *Eur J Cardiothorac Surg* 2000;18:194–201.
- [3] Imagawa H, Takano S, Shiozaki T, Ryugou M, Shikata F, Kawachi K. Two-patch technique for postinfarction inferoposterior ventricular septal defect. *Ann Thorac Surg* 2009;88:692–4.
- [4] McLaughlin A, McGiffin D, Winearls J, Tesar P, Cole C, Vallely M *et al.* Veno-arterial ECMO in the setting of post-infarct ventricular septal defect: a bridge to surgical repair. *Heart Lung Circ* 2016;25:1063–6.