



University of Zurich  
Zurich Open Repository and Archive

Winterthurerstr. 190  
CH-8057 Zurich  
<http://www.zora.uzh.ch>

---

*Year: 2006*

---

## Unilateral evisceration of an eye following cornea and lens perforation in a sulfur-crested cockatoo (*Cacatua galerita*)

Christen, C; Richter, M; Fischer, I; Eule, C; Spiess, B; Hatt, J M

Christen, C; Richter, M; Fischer, I; Eule, C; Spiess, B; Hatt, J M (2006). Unilateral evisceration of an eye following cornea and lens perforation in a sulfur-crested cockatoo (*Cacatua galerita*). *Schweizer Archiv für Tierheilkunde*, 148(11):615-619.

Postprint available at:  
<http://www.zora.uzh.ch>

Posted at the Zurich Open Repository and Archive, University of Zurich.  
<http://www.zora.uzh.ch>

Originally published at:  
*Schweizer Archiv für Tierheilkunde* 2006, 148(11):615-619.

# Unilateral evisceration of an eye following cornea and lens perforation in a sulfur-crested cockatoo (*Cacatua galerita*)

## **Abstract**

A 24-year old male sulfur-crested Cockatoo (*Cacatua galerita*) was presented with a subacute perforation of the cornea without involvement of the lens. The bird was treated conservatively and the eye remained quiescent up to a second traumatic corneal perforation associated with a lens capsule rupture 15 months later. Due to the second perforating trauma of an already blind eye involving the lens, evisceration of the eye was performed. Two months after surgery the cosmetic result was excellent. Treatment options for perforating ocular traumas in captive birds are discussed in detail.

# Unilateral evisceration of an eye following cornea and lens perforation in a sulfur-crested cockatoo (*Cacatua galerita*)

C. Christen<sup>1\*</sup>, M. Richter<sup>2\*</sup>, I. Fischer<sup>1</sup>, C. Eule<sup>2</sup>, B. Spiess<sup>2</sup>, J.-M. Hatt<sup>1</sup>

<sup>1</sup>Division of Zoo Animals and Exotic Pets and <sup>2</sup>Ophthalmology Service, Small Animal Department, University of Zurich

## Abstract

A 24-year old male sulfur-crested Cockatoo (*Cacatua galerita*) was presented with a subacute perforation of the cornea without involvement of the lens. The bird was treated conservatively and the eye remained quiescent up to a second traumatic corneal perforation associated with a lens capsule rupture 15 months later. Due to the second perforating trauma of an already blind eye involving the lens, evisceration of the eye was performed. Two months after surgery the cosmetic result was excellent. Treatment options for perforating ocular traumas in captive birds are discussed in detail.

Keywords: ophthalmology, surgery, enucleation, evisceration, bird

## Einseitige Eviszeration eines Auges infolge Perforation von Cornea und Linse bei einem Gelbhaubenkakadu (*Cacatua galerita*)

Ein 24 Jahre alter männlicher Gelbhaubenkakadu (*Cacatua galerita*) wurde mit einer subakuten Perforation der Cornea und unveränderter Linse vorgestellt. Der Vogel wurde konservativ behandelt und das Auge verhielt sich ruhig bis 15 Monate später ein Trauma zu einer zweiten Cornea Perforation mit einer Linsenkapselruptur führte. Da das Auge bereits blind war und beim zweiten perforierenden Trauma die Linse involviert war, wurde eine Eviszeration des Auges vorgenommen. Das kosmetische Resultat war zwei Monate nach der Operation exzellent. Die Behandlungsmöglichkeiten bei einem perforierenden Augentrauma bei Vögeln in Gefangenschaft werden im Detail diskutiert.

Schlüsselwörter: Ophthalmologie, Chirurgie, Enukleation, Eviszeration, Vogel

## Introduction

The main goal in treating ophthalmic disorders is to save vision and to prevent pain. However, removal of the eye has to be considered because of permanent discomfort and infections resistant to medical therapy or neoplasia. Three different enucleation procedures have been reported in birds (Altmann, 1997; Gelatt and Gelatt, 2001). Selection of the procedure is mainly influenced by globe shape and the possible risk of infection. In owls with an extensive external ear opening, transaural enucleation procedure has been recommended (Murphy et al., 1983). This method expands the palpebral fissure to allow removal of the large intact tubular-shaped globe. The second method, which may be used in any avian species, involves collapse of the globe to permit its removal through the palpebral fissure (Gelatt and Gelatt,

2001). The third technique is an evisceration method involving removal of the cornea and all of the intraocular tissues, but leaving the sclera and bony ossicles intact (Gelatt and Gelatt, 2001). A complete permanent tarsorrhaphy is then performed. The evisceration not only attempts to address the considerable disfigurement that occurs after removal of the entire globe but also attempts to minimize risk during surgical procedure. However, birds with possible panophthalmitis and intraocular neoplasia should not be considered candidates for this procedure, due to the risk of remaining infection or neoplastic cells at the surgery site.

The present case describes an evisceration of the left eye in a sulfur-crested cockatoo (*Cacatua galerita*) due to perforation of the cornea and the lens capsule and secondary uveitis with posterior synechia. With this case report we intend to show treatment options in

\* joined first author

captive birds with corneal perforation with and without lens involvement. The advantages of evisceration compared to enucleation will be discussed in detail.

## Case report

In February 2004 a 24-year old male sulfur-crested Cockatoo (*Cacatua galerita*) was presented because of ocular discharge of the left eye. The bird was kept as a single pet, housed indoors and was fed a commercial seed diet for parrots. The owner had observed a persistent cloudiness of the left eye of unknown etiology approximately two years ago. The eye seemed to be blind since then. According to the owner's statement the bird did not show any discomfort (blepharospasm, tearing) until 1 week prior to presentation and therefore the bird was not presented to a veterinarian and no therapy had been started so far.

Upon presentation the cockatoo was in a good general and nutritional condition and with the exception of the left eye the clinical examination was unremarkable. The left eye showed blepharospasm and tearing. Slit-lamp examination (KOWA SL-14, Kowa, Tokyo, Japan) of the injured eye revealed a small subacute perforation of the cornea with iris tissue attached to the perforation site (iris prolapse) and a collapsed anterior chamber. Close to the perforation site extensive deep stromal whitish crystalline deposits were noted in the cornea (Fig. 1). Because ophthalmic examination of the remaining deeper structures was not possible an ultrasound examination of the left eye was performed. The lens was in situ and without signs of cataract. The vitreous cavity was diffusely hyperechoic and not distinguishable from the retrobulbar space, which was considered to be due to intraocular hemorrhage or possible rupture of the sclera. Inflammation, degeneration and neoplasia are further differ-

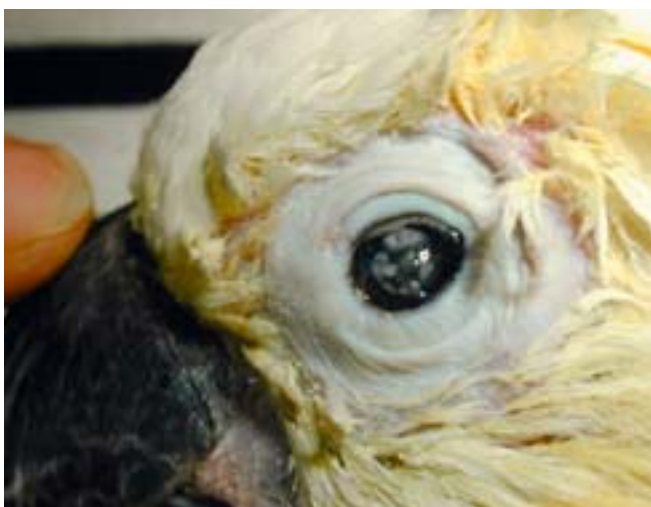

Figure 1: The left eye of a sulfur-crested cockatoo (*Cacatua galerita*) with a small subacute perforation of the central cornea, iris prolapse and extensive lipid degeneration of the cornea.

ential diagnoses for a hyperechoic vitreous and could not be ruled out. However, loss of ultrasonographic display of the posterior bulbar wall is usually due to intraocular bleeding associated with rupture of the bulbar tunics. The prognosis for vision was poor due to ultrasonographic diagnosis. A surgical treatment, such as corneal suture or conjunctival graft was recommended but the owner declined because of the potential anesthetic risk and due to financial constraints. During the three week hospitalization the bird did not show any other signs of pain. The bird was treated with topical ofloxacin (Floxal®/UD, Bausch & Lomb Swiss, CH) to prevent bacterial infection and retinol palmitat (Oculotec®, Novartis Pharma AG Schweiz, CH) to promote healing both 3 times daily and with carprofen (Rimadyl®, Gräub AG, CH, 4 mg/kg, SC) to limit inflammation for six days. The bird was discharged after three weeks with continued treatment for another two weeks. One week after cessation of medical therapy the bird was presented for a final recheck. The injured eye was unchanged (sealed perforation, extensive corneal mineral deposits) and the bird showed no discomfort. Eleven months after initial presentation the bird was sold and the new owner brought the bird in for a general health check. The clinical examination including fecal parasitological examination was unremarkable and the hematological and chemical blood values were within normal limits. No progression of the previously described injury on the left eye was noted and the eye was without discomfort.

Four months later the bird was presented again because of acute pain of the left eye. Ophthalmic examination revealed serous ocular discharge, blepharospasm, swollen eyelids and a focal hemorrhage on the third eyelid. Perforation of the cornea and the lens as well as posterior synechia (iris tissue attached to the lens) was diagnosed using slit-lamp biomicroscopy. Due to this second perforation of the same eye with involvement of the lens and discomfort of the eye removal of the injured eye was planned.

Due to many advantages of an evisceration over enucleation and due to the fact that the perforation was acute, evisceration of the left eye was performed. Presurgical management consisted of carprofen (Rimadyl®, Gräub AG, CH, 4 mg/kg, SC) and Buprenorphin (Temgesic®, Essex Chemie AG, CH, 0.05 mg/kg, IM) for analgesia, enrofloxacin (Baytril® 2.5%, Bayer, CH, 10 mg/kg, IM) as antibiotic and a single dose of lactated Ringer's solution (15 ml, s.c. Fresenius, CH). Following induction of anesthesia with an isoflurane/O<sub>2</sub> mixture with 4% of isoflurane (Isofluran Baxter, Baxter AG, CH) by face mask the bird was intubated and maintained on a semi-open system with 2.5% of isoflurane. For surgical intervention the bird was placed in right lateral recumbency on a heating pad to minimize the heat loss.

Feathers surrounding the eye were plucked, the skin was cleaned with chlorhexidini gluconas (Merfen, aqueous solution, Novartis, CH) and the conjunctival sac and cornea were rinsed with physiologic saline solution. To enlarge the palpebral fissure a medial and lateral canthotomy was performed using scissors followed by removal of the entire third eye lid including its gland (Harderian gland) and conjunctival tissue. The cornea was cut off along the limbus using corneal scissors following a clear corneal incision using a 2.8 mm microsurgery knife (Kai Europe GmbH, Solingen, Germany). Iris, ciliary body, choroid and retina were separated from the sclera with a cyclodialysis spatula pushing and rotating gently along the curvature of the scleral shell. Subsequently, the pecten and remaining intraocular structures (lens in resorption and liquefied vitreous) were extracted gently using suture tying forceps. Following removal of the intraocular structures the remaining scleral shell was flushed with physiologic saline solution and dried with sterile cotton tips until slight bleeding was stopped. Finally, the lid margins were cut off and closed in a bi-layered fashion using Vicryl 6/0 rapid (Ethicon GmbH, Norderstedt, D) for a subcutaneous continuous suture and Vicryl 5/0 for closure of the skin in an interrupted pattern. Hematological and biochemical blood values were checked one day after surgery and they were all within normal limits, except creatin-kinase which was increased (2040 U/l, reference range 147–418 U/l) (Fudge, 2000).

The postoperative treatment consisted of prophylactic application of antibiotics (enrofloxacin, Baytril® 2.5%, Bayer, CH, 10 mg/kg, IM) for five days and antimycotics (ketokonazole, Ketokonazol-sirup, Streuli & Co AG, Uznach, Switzerland, 20 mg/kg, PO) for eight days and analgesia (carprofen, Rimadyl®, Gräub AG, CH, 4 mg/kg, SC) for three days. One week after surgery, the bird was presented for recheck. The wound had healed properly (Fig. 2).



Figure 2: The same bird as in Fig. 1 one week after evisceration of the left eye.



Figure 3: The same bird as Fig 1 two months after evisceration. This frontal view shows the planar surface of the evisceration site.

Two months after evisceration the cosmetic result was excellent (Fig. 3).

## Discussion

Ocular trauma may lead to corneal perforation with and without lens capsule rupture. Corneal perforation without involvement of the lens in mammals is usually treated surgically performing a corneal suture or a conjunctival graft (Gilger and Whitley, 1999; Gelatt and Gelatt, 2001). In birds, acute corneal perforations without iris prolapse may be repaired by direct corneal suturing (Davidson, 1997). In corneal perforations with prolapse of iris tissue, amputation of the prolapsed portion may be necessary to close the wound. Conjunctival grafts in birds are more challenging than in mammals due to absence of loose conjunctival tissue. Chronic perforations with anterior synechia are left untreated, if nonpainful (Davidson, 1997). In this case, the bird was initially presented with a subacute corneal perforation with anterior synechia without involvement of the lens and no obvious discomfort. Due to owners denial of a surgical repair topical medical treatment was performed at that time.

In cases where perforation of the lens capsule and lens rupture occurred, the traumatized lens has to be removed as early as possible to prevent chronic destructive inflammatory reactions (Davidson et al., 1991). In general, traumatic disruption of the anterior lens capsule from a penetrating corneal or scleral injury, besides inducing a focal to diffuse cataract, often is associated with profound vision-threatening



anterior uveitis and secondary glaucoma or phthisis bulbi (Davidson et al., 1991). Phacoclastic uveitis is the result of sudden exposure of physiologically sequestered lens proteins to the uvea (Wilcock and Pfeiffer, 1987). Medical therapy alone usually does not prevent progressive uveitis and its sequels in eyes with lens capsule rupture (Muga and Maul, 1978; Davidson et al., 1991; Van der Woerd et al., 1992). The clinical syndrome of phacoclastic uveitis has been reported in several species, including the dog (Davidson et al., 1991), rabbit (Wolfer et al., 1993), cat (McCalla et al., 1988), horse (Grahn and Cullen, 2000) and bird (Miller et al., 1988) and may comprise blepharospasm, corneal or scleral perforation and ulceration, aqueous flare, miosis, hypopyon, cataract, and fragments of lens cortex that adhere to the iris or cornea. In birds traumatized lenses induce a granulomatous inflammatory reaction leading to chronic uveitis or endophthalmitis (Anderson and Buyukmichi, 1983; Miller et al., 1988). To prevent destruction of the eye, a ruptured lens should be removed as soon as possible. In general, removal of the lens may be done by extracapsular lens extraction or by phacoemulsification (Davidson et al., 1991, Brooks, 1997). In birds, phacoemulsification may be more advantageous than the extracapsular technique (Kern et al., 1984; Brooks, 1997; Brooks et al., 1983).

When the bird was represented with an acute trauma to the same eye involving the cornea and the lens, lens extraction was not the treatment of choice, because of pre-existing blindness and chronic corneal degeneration and anterior synechia. Due to blindness the left eye may have been prone to further traumatic injury. Since this was already a blind eye, yet with lens involvement and discomfort, the owner decided to let the eye remove. Enucleation in birds may be necessary after destruction of the eye and loss of vision following extensive trauma, intraocular infections, and non-infectious intraocular inflammation. Removal of the globe in birds is more challenging because the avian globe is very large in relation to the surrounding bony orbit (Fig. 4), and the extraocular space for surgery is smaller compared to mammals (Korbel, 1991), due to lack of retrobulbar fat tissue and the absence of a *M. retractor bulbi*. The avian sclera contains 10 to 18 small overlapping ossicles that form a bony ring and give shape to the avian eye (Tiemeier, 1950). Enucleation involving complete removal of the globe results in considerable disfigurement (Korbel, 1991) and may have a negative effect on the natural balance of the head especially in birds of prey (Murphy et al., 1983). Furthermore, as birds have a very thin bony interorbital septum, the risk of penetrating the septum and harming the other eye is increased

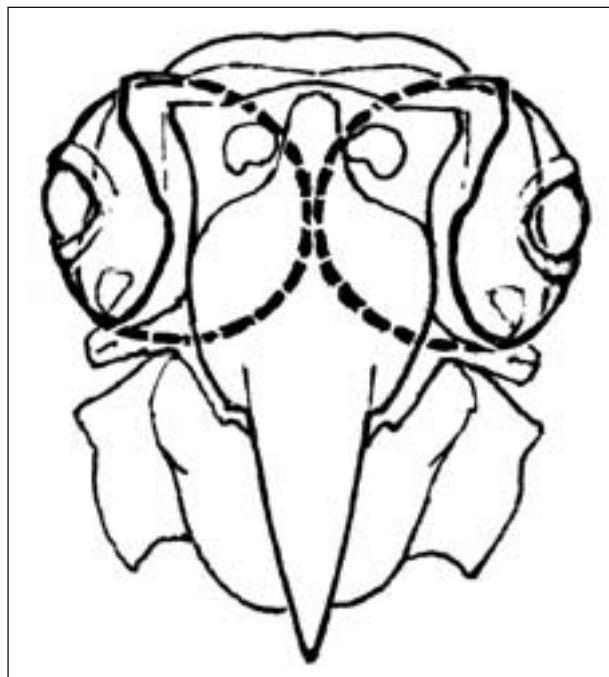


Figure 4: Ophthalmic anatomical conditions in a skull of a cockatoo. The interrupted lines illustrate size and vicinity of both orbits, which are separated by a very thin bony septum.

(Korbel, 1991). It should also be kept in mind, that birds have a very short optic nerve, and traction on the globe may result in damage to the contralateral optic nerve via traction at the optic chiasm (Korbel, 1991; Bennett and Harrison, 1994).

Leaving the scleral shell and its ossicles in the orbit, as in the evisceration method, reduces the intraoperative risks mentioned above and results in a better cosmetic outcome. However, in cases of intraocular neoplasia and microbial infections enucleation should be the preferred method.

This case report shows that conservative treatment of corneal perforation without involvement of the lens is possible if discomfort resolves upon medical treatment. However, due to the lateral placement of the eyes in birds the healthy eye of one site may not compensate for blindness of the other eye and thus the blind eye may be prone to further injury. Because of the discussed advantages of evisceration over enucleation, evisceration should be the preferred procedure if an eye cannot be preserved, provided that limiting factors like intraocular neoplasia or microbial infections do not exclude.

## Acknowledgement

The authors would like to thank Matthias Haab for the figure 4.

## References

- Altmann R.B.*: Soft tissue surgical procedures. In: Avian Medicine and Surgery. Eds. R.B. Altmann, S.L. Clubb, G.M. Dorrestein and K.E. Quesenberry, W.B. Saunders Company, Philadelphia, 1997, 704–732.
- Anderson G.A., Buyukmihci N.*: Phacoanaphylactic endophthalmitis in an owl. *Vet. Pathol* 1983, 20:776–778.
- Bennett A.R., Harrison G.J.*: Soft tissue surgery. In: Avian Medicine: Principles and Application. Eds. B.W. Ritchie, G.J. Harrison and L.R. Harrison, Wingers Publishing, Florida, 1994, 1096–1136.
- Brooks D.E.*: Avian cataracts. *Semin Avian Exot. Pet* 1997, 6: 131–137.
- Brooks D.E., Murphy C.J., Quesenberry K.E.*: Surgical correction of a luxated, cataractous lens in a Barred Owl. *J. Am. Vet. Med. Assoc.* 1983, 183: 1298–1299.
- Davidson M.G.*: Ocular consequences of trauma in raptors. *Semin Avian Exotic. Pet* 1997, 6: 121–130.
- Davidson M.G., Nasisse M.P., Jamieson V.E., English R.V., Olivero D.K.*: Traumatic anterior lens capsule disruption. *J. Am. Anim. Hosp. Assoc.* 1991, 27: 410–414.
- Fudge A.M.*: Laboratory Medicine – Avian and Exotic Pets. W.B. Saunders Company, Philadelphia, 2000.
- Gelatt K.N., Gelatt J.P.*: Small Animal Ophthalmic Surgery. In: Small Animal Ophthalmic Surgery. Eds. K.N. Gelatt and J.P. Gelatt, Butterworth Heinemann, Oxford, 2001, 381.
- Gilger B.C., Whitley R.D.*: Surgery of the cornea and sclera. In: Veterinary Ophthalmology. Ed. K.N. Gelatt, Lippincott Williams & Wilkins, Baltimore, 1999, 675–700.
- Grahn B., Cullen C.L.*: Equine phacoclastic uveitis: the clinical manifestations, light microscopic findings, and the therapy of 7 cases. *Can. Vet. J.* 2000 41: 376–382.
- Kern T.J., Murphy C.J., Riis R.C.*: Lens extraction by phacoemulsification in two raptors. *J. Am. Vet. Med. Assoc.* 1984, 185: 1403–1406.
- Korbel R.*: Update on ornithoophthalmology. *Tierärztl. Praxis* 1991, 19: 497–507.
- McCalla T., Moore C., Collier L.*: Phacoclastic uveitis and secondary glaucoma in a cat. *Comp. Anim. Pract.* 1988, 2: 13–17.
- Miller W., Boosinger T., Maslin W.*: Granulomatous uveitis in an owl. *Vet. Pathol.* 1988, 20: 365–366.
- Muga R., Maul E.*: The management of lens damage in perforating corneal lacerations. *Brit. J. Ophthalmol.* 1978, 62: 784–787.
- Murphy C.J., Brooks D.E., Kern T.J., Quesenberry K.E., Riis R.C.*: Enucleation in birds of prey. *J. Am. Vet. Med. Assoc.* 1983, 183: 1234–1237.
- Tiemeier O.W.*: The os opticus of birds. *J. Morphol.* 1950, 86: 25–46.
- Van der Woerd A., Nasisse M.P., Davidson M.G.*: Lens induced uveitis in dogs, 151 cases (1985–1990). *J. Am. Anim. Hosp. Assoc.* 1992, 201: 921–926.
- Wilcock B.P., Pfeiffer R.L.*: The pathology of lens-induced uveitis in dogs. *Vet. Pathol.* 1987, 27: 549–553.
- Wölfer J., Grahn B., Wilcock B., Percy D.*: Phacoclastic uveitis in the rabbit. *Progr. Vet. and Comp. Ophthalmol.* 1993, 3: 92–97.

## Address for correspondence

Cornelia Christen, Dr. med. vet., Division of Zoo Animals and Exotic Pets, Small Animal Department, Vetsuisse Faculty, University of Zurich, Winterthurerstrasse 260, 8057 Zurich, Switzerland, Phone +41-1-635 83 80, Fax +41-1-635 89 01, E-Mail: cchristen@vetclinics.unizh.ch

Received: 24 February 2006

Accepted: 10 March 2006