



**University of
Zurich**^{UZH}

**Zurich Open Repository and
Archive**

University of Zurich
University Library
Strickhofstrasse 39
CH-8057 Zurich
www.zora.uzh.ch

Year: 2010

Incarnation and animation: physical versus representational deficits of body integrity

Hilti, Leoni Maria ; Brugger, P

Abstract: Two apparently disparate phenomena of defective body integrity are reviewed. The first concerns dysmelia, characterized by the congenital absence or deformation of limbs, and the focus of the review is on phantom sensations of people with this kind of physical integrity disorder. The second phenomenon consists of non-psychotic individuals' desire to have a healthy limb amputated, which is interpreted as a mismatch between the physical integrity of a particular limb and its representation in multimodal cortical areas of the brain. We outlined commonalities and differences between the two conditions and note the absence, in both areas of research, of a unified theory that would account for the reported phenomenology. Phantom limbs in dysmelia and the desire for limb amputation most likely are the consequence of very early developmental dissociations between physical and phenomenal body shapes. They are mirror images of one another in that the former constitutes an "animation without incarnation" and, the latter, an "incarnation without animation".

DOI: <https://doi.org/10.1007/s00221-009-2043-7>

Posted at the Zurich Open Repository and Archive, University of Zurich

ZORA URL: <https://doi.org/10.5167/uzh-25250>

Journal Article

Accepted Version

Originally published at:

Hilti, Leoni Maria; Brugger, P (2010). Incarnation and animation: physical versus representational deficits of body integrity. *Experimental Brain Research*, 204(3):315-326.

DOI: <https://doi.org/10.1007/s00221-009-2043-7>

**Incarnation and animation:
Physical versus representational deficits of body integrity**

Leonie Hilti, Peter Brugger

Neuropsychological Unit,
Department of Neurology,
University Hospital Zurich,
CH-8091 Zurich

Corresponding author: Leonie Hilti, Neuropsychology Unit, Department of Neurology,
University Hospital Zurich, CH-8091 Zurich; phone ++41 44 255 5579; FAX: ++41 44
255 4429; e-mail: leonie.hilti@usz.ch

Abstract

Two apparently disparate phenomena of defective body integrity are reviewed. The first concerns dysmelia, characterized by the congenital absence or deformation of limbs, and the focus of the review is on phantom sensations of people with this kind of physical integrity disorder. The second phenomenon consists of non-psychotic individuals' desire to have a healthy limb amputated, which is interpreted as a mismatch between the physical integrity of a particular limb and its representation in multimodal cortical areas of the brain. We outlined commonalities and differences between the two conditions and note the absence, in both areas of research, of a unified theory that would account for the reported phenomenology. Phantom limbs in dysmelia and the desire for limb amputation most likely are the consequence of very early developmental dissociations between physical and phenomenal body shapes. They are mirror images of one another in that the former constitutes an "animation without incarnation" and, the latter, an "incarnation without animation".

Keywords

- body integrity identity disorder (BIID)
- paraphilias
- parietal lobes
- body image, body schema
- borderlands of psychiatry and neurology

This paper examines two apparently disparate phenomena of corporeal awareness. In both, the completeness or integrity of one's own body is hampered. The first is the occurrence of phantom limbs in individuals born with an "incomplete" body, in which the physical body is incomplete, but the missing limb seems to be represented in the subject's brain, at least as can be inferred from its phenomenal presence. The second phenomenon is the strong desire, by non-psychotic and otherwise well-adjusted healthy individuals, to have a fully functional limb removed. In this condition, it can be argued that despite the physical presence of a limb, the lack of acceptance is due to some underrepresentation in the subject's brain. We review the literature on both conditions and propose that phantom sensations of physically absent limbs and the request for removal of normally developed extremities may be mirror images of one another on the conceptual level: an animation without incarnation and an incarnation without animation, respectively.

Animation without incarnation: phantom sensations of congenitally absent limbs

Dysmelia is a heterogenous condition affecting the physical integrity of the body (O'Rahilly 1951; O'Rahilly and Gardner 1975). It involves a deficit in limb formation caused by genetic or developmental factors that results in a deformation of arms or legs. In cases of a complete absence of skeletal parts the term "amelia" is used. In general, limb reduction deficits are the result of an arrest of formation of the embryonic limb buds during early fetal development (prior to the 8th week of gestation in the case of amelia) or of later vascular, mechanical or teratogenic incidents (see Froster-Iskenius and Baird 1990 for review). Amelia of one or more limbs occurs with a frequency of 1.5 per 100'000 live births. While upper and lower limbs are affected comparably often, there is a preponderance of left-sided over right-sided defects (unless they are thalidomide-induced; Lenz 1988). The present review is not primarily concerned with the physical aspects of limb reduction defects, but with the observation that a minority of individuals, who show such defects, report phantom sensations of the congenitally absent limb (henceforth referred to as "congenital phantoms").

To our knowledge, the physiologist Gabriel Gustav Valentin (1810-1883) was the first to systematically question persons with dysmelia about phantoms of their missing limbs (Valentin 1836). During both his and more modern times the investigative focus of phantom limb research was almost exclusively on phantom limbs after amputation (Finger and Hustwit 2003; Halligan 2002). Valentin explored whether phantom sensations (he used the term "feelings of integration") were observed in persons born with incomplete bodies because he doubted the validity of theories that conceptualized such sensations as the brain's "sensorimotor memories" of once owned limbs. Specifically, he hoped "to definitely falsify the view that the integration would rely on certain memories of sensation" (p 330). He presented case studies of four persons born with one incomplete upper limb, who all reported phantom sensations qualitatively comparable to those described by amputees. For instance, one nineteen-year-old girl born without a left hand (shortened metacarpal bones, but no phalanges) noted the phantom presence of a regular palm including all five fingers. Valentin was not satisfied by this purely subjective report and tried to "objectify" it by administering several behavioral tasks. For instance, he provoked paresthesias in some of the phantom fingers by prolonged pressure on certain nerves in the stump. As the pattern of innervation in the

fingers could not be known by his subjects, the fact that tingling sensations were elicited in the “correct” phantom fingers was taken as evidence for the genuineness of the reported phantoms.

Valentin also designed a length estimation task, later re-invented for the same purpose by other authors (Weinstein and Sersen 1961). Using the normally developed limb as a reference, subjects were required to indicate the length of the phantoms of their missing limbs. Repeated measurements allowed a systematic determination of the size and shape of reported phantoms. On the basis of these observations, Valentin concluded that “[the integration of sensation] by persons born with limb dysplasia teaches us that it is out of the question that they could be accounted for by memory or recollective imagery” (Valentin 1836, p. 334). He speculated about the potential mechanisms of phantom sensations in the four individuals studied, emphasizing that peripheral and central nervous system factors were probably involved. Interestingly, Valentin was quick to caution scientists not to accept his speculations as “an axiom, i.e., the beginning of our ignorance or the borderlines of our knowledge” (p 334). It turned out that his concerns were entirely unjustified. His study was to remain unnoticed for more than a century, and it was the axiom he had set out to question (i.e., the view of previous limb use as a necessary precondition for phantom sensations) that was about to gain popularity in the decades to follow.

A paper by a Czech neurologist, Arnold Pick (1851- 1924), was most influential for the preservation of this axiom. In an overview on pathologies of corporeal awareness, Pick (1915) emphasized the continuous reconstruction of a central representation of one’s own body, the “body schema”, during child development. He equated phantom sensations in amputees with an activation of these central engravings: the physical part could be lost, but its representation would persist. In this context he rather parenthetically mentioned the following statement of affairs:

“... the absence of the phantoms discussed here in cases of congenital [aplasia] or after amputation experienced during early childhood. The amputated part has simply never been represented in the body schema of these particular persons” (p. 260).

Although Pick authoritatively labeled this statement a “fact”, his text contained no reference to his own empirical observations nor to any published data on people with congenital limb deficiencies. Only a casual note, Pick’s 1915 publication was quickly adopted as the key reference to document the non-existence of phantoms in individuals born with absent limbs. Simmel (1956; 1961) later helped to spread Pick’s reference to the English language literature, even though she herself had recognized that Pick’s statement was not based on observation (Simmel 1966). Still today, the notion of phantom limbs occurring exclusively after amputation acquired during adulthood or late childhood is widely and unquestionably accepted. We believe that the rarity of the condition is responsible for the persistence of this axiom. Furthermore, as dysmelia occurs in various types and degrees, the formation of a proposed theory depended considerably on the type of limb deficiencies an author had investigated. We critically

discuss several hypothetical mechanisms published in the rather scattered 20th century literature on congenital phantom limbs (Table 1).

Insert Table 1 about here

Phantoms of congenitally absent limbs as the product of wishful thinking and suggestibility

Sohn (1914), apparently unaware of Valentin's 1836 contribution, reported the case of a 19-years-old woman born without a left forearm and hand, who complained about painful sensations in her missing hand and fingers. He noticed the theoretical significance of this observation, but was unwilling to even speculate about any sensory, motor or representational mechanisms that could have accounted for the genesis of phantom sensations in this case. He preferred to point out that the "only mildly erotic" girl might have considered the lack of physical body integrity a barrier to marriage and therefore assumed "that the subjective sensation of pain in the fingers and the consciousness of a hand are equivalent to a wish fulfillment" (p 961). The notion of wish fulfillment on the part of the examiner was considered by Skoyles (1990), who raised concerns about general suggestibility effects shaping a patient's response to questions about phantom sensations. These concerns appear especially warranted as they addressed observations in *children* with congenital limb deficiencies (e.g. Poeck 1964; 1969; Simmel 1961; Weinstein and Sersen 1961; Weinstein et al. 1964). Skoyles emphasized the high vulnerability of child testimony to leading questions and situational demands, including the "length estimation game" to obtain measurements of the size and shape of a phantom.

Although we appreciate the recommendation to maintain a critical attitude when confronted with spontaneous claims about unusual experiences, or if questioning subjects about such experiences, we believe that some measures could have been taken in order to substantiate or invalidate an individual's claim. Valentin's (1836) selective provocation of paresthesias in some, but not other, phantom fingers is one simple, but effective, way to "objectify" an individual's report about phantom fingers. Another way is to ask about postural properties of claimed phantom limbs, especially when their characteristic physical responses are not immediately accessible to a layperson (Fig. 1).

Insert Figure 1 about here

Also, we note that some published observations do not substantiate of an "explanation" of congenital phantoms as a product of wish-fulfillment. For instance, as far as Sohn's (1914) "mildly erotic" girl is concerned, one is tempted to wonder whether a *painful* phantom could ever be the product of wishful thinking. Likewise, the relative over-

representation of certain phantom parts over others (e.g. the hallux over the calf) can hardly be explained by differential psychological needs for the different body parts (Weinstein and Sersen 1961). Moreover, gaps in the phenomenal experience of a phantom (for instance, the sensation of a thumb and a little finger without any fingers felt in between) can “scarcely be considered a fantasy worth its salt” (Weinstein and Sersen 1961, p. 909; see Ramachandran 1993, for similar arguments). Finally, wishful thinking does not need the type of mechanical trigger that often elicits sensations of congenitally absent limbs. Thus, superficial injury to the stump induced the first-ever awareness of congenital phantoms in three out of the four cases communicated by Saadah and Melzack (1994). Similarly, Xue (1986) treated two persons with congenital limb dysplasia with acupuncture (for reasons unrelated to their condition). Upon needle insertion in the stump region, two young women born with an absent or deformed left hand felt a sudden prolongation of the arm that took on the shape of a regular upper limb with a hand and five fingers.

To summarize the early historical development, recasting subjects’ reports of concrete sensations into mere fantasies marginalized the phenomenon under investigation. Any need to adjust the theory of phantom limbs as the brain’s sensorimotor memories thus became superfluous, and indirectly helped the axiom of the “nonexistence of congenital phantoms” to survive.

Phantoms of congenitally absent limbs as motor illusions induced by stump movements

Simmel (1961), in one of the first group studies on congenital phantom limbs, interviewed 27 people with dysplasia of the upper limbs about phantom sensations. Two persons reported such sensations, both were 10-year-old girls. While one of them was born with a completely absent forearm (no finger rudiments attached to the stump), the other was born with an incomplete hand. Specifically, while a “rudimentary thumb [was] present with some voluntary motion” (p 469), the fingers were absent. Simmel dismissed the former girl’s report about phantom finger sensations as due to the suggestive nature of the interview. At the same time, she interpreted the latter girl’s report about finger phantoms (mainly of the little finger) as an illusory projection of enhanced thumb motility into extracorporeal space: “The kinesthetic stimulation resulting from such abnormally great excursion may possibly provide a sufficient condition [...] which, under the special circumstances here, culminates in the experience of a ‘phantom finger’” (p. 470). Simmel was probably correct in pointing out that cases of completely absent limbs must be investigated separately from cases with rudimentary preservation of distal body parts attached to the stump (“intercalary aplasia”). However, she failed to notice that her proposal was at variance with Valentin (1836), who had explicitly stated “I have to note here that the feelings of integration are more vivid in individuals who lack all peripheral parts, e.g. all fingers, than in those that are more completely organized in this regard, i.e. who still have a thumb or thumb plus first digit” (p 331). Thus, while Simmel’s proposal may have some validity with respect to phantoms in individuals with intercalary aplasia, it inevitably fails to account for the congenital phantoms reported by people with complete aplasia of an entire limb.

Phantoms of congenitally absent limbs derived from a representation of the contralateral limb

Burchard (1965) found indications of phantom sensations in only one out of 17 cases examined (two more persons reported having felt the congenitally absent hand during their dreams; see also Brugger 2008; Valentin 1836). This individual was a 36-year-old woman born with a forearm only 9 cm long and with no hand. She occasionally felt a prolongation of the stump, so vivid that she would touch its physical tip to ascertain that the felt forearm was only a creation of her mind. Fifteen of Burchard's patients had strictly unilateral limb defects, including the woman with the fleeting phantom percept. The author therefore speculated (p 370) that congenital phantoms are mediated by information about the existing limb that reached the deafferented cortex from homotopic areas of the contralateral hemisphere. This idea was later elaborated on by Grouios (1996), who introduced the case of a 12-year-old boy born without a right elbow and forearm and reporting phantom sensations of the missing hand and fingers. He argued that

"It seems that the upper and lower limbs in people with congenital limb deficiency are linked in the brain as a result of frequent co-activation. Hence, sensory input of the left upper limb, for example, projects not only to the somatosensory cortex of the right cerebral hemisphere but – by identified or unidentified commissural pathways – to mirror-symmetrical points in the left cerebral hemisphere. It thus contributes to a weak formation of the cortical representation of the right upper limb." (Grouios 1996, pp 503-504)

The conceptualization of a congenital phantom as the phenomenal awareness of the mirror limb is not without experimental support from the literature on amputation phantoms (Jacobson 1931), from reports on referred sensations from a normal to an anesthetic hand (Sathian 2000) and from work on the crossmodal integration of somesthetic and visual information in limb observation tasks (Funk and Brugger 2008). However, the generalization of this theory is limited; clearly, it cannot account for reports of congenital phantoms in people with *bilateral* absence of upper and/or lower limbs. We emphasize that the theoretical importance of cases of bilateral limb aplasia was already noted in this specific context by Valentin (1836).

Phantoms of congenitally absent limbs derived from a schema for hand-mouth coordination

A novel theoretical contribution to the issue of congenital phantoms was provided by Gallagher et al. (1998). These authors suggested a very specific mechanism for the formation of phantom percepts in individuals with deficient physical body integrity, i.e. the activation of an innate schema for hand-mouth coordination. The empirical data on which Gallagher et al.'s proposal rests comes from investigations of human fetal behavior. Not only are right upper limb preferences already determined at around 10 weeks of gestation, but the precision of hand-to-mouth movements for thumb sucking, from their very first occurrence around week 12 (Hepper et al. 1998; 2005), suggests an innate schema representing these movements. Gallagher et al. proposed that evocation of this schema stimulating hand and mouth simultaneously could give rise to sensations of a

hand even in the physical absence of a hand; specifically, they suggested that activation of the mouth part of the schema would always be accompanied by activation of the hand part of the schema. "Activation of the expanded face-representing neural map may also reactivate the indigenous limb-representing neurons and thus cause the phantom experience" (p 59). We note that Gallagher et al. were the first to ground a hypothesis that an innate component of body schema is responsible for congenital phantoms on focal empirical findings. However, these authors did not address cases of phantoms in persons with congenitally absent *lower* limbs. In fact, their tabular overview of published reports on congenital phantoms meticulously and comprehensively lists cases of upper limb phantoms (explained by their theory) but omits cases of congenital phantoms of legs and feet, even if these had been described by the same original authors. Hence, this theory may have its merits, but it clearly cannot account for all observational data from the clinical literature on congenital phantoms.

Phantoms of congenitally absent limbs as manifestations of an innate body schema

The strongest conclusion from cases of congenital phantoms is that „... a structural basis for the phantom experience is encoded in the DNA. We are born with a full-blown potential for imaging body parts“(Abramson and Feibel 1981, p 99). In more moderate terms, a genetically built-in component for a body schema was described by Melzack (1990; Melzack et al. 1997). According to this author, a widespread network of thalamocortical and limbic loops (the "neuromatrix") is basically innate, but continuously shaped during a person's life by sensory inputs and motor commands. The concept of a neuromatrix is not only compatible with reports of phantom sensations of physically not developed limbs, but it could also explain phenomena of neural migration and the synchronized early development of physically separated brain areas (Melzack 1990). However, we would like to add that agreement about the genuineness of congenital phantoms does not automatically imply agreement about a genetic basis of corporeal awareness. Even if an infant's congenital phantoms could ever be "objectified" a few moments after birth, this should not necessarily be taken as evidence for a genetic hardwiring of a four-limbed body; "innate" must not be equated with "genetically determined". In fact, as pointed out above, the human fetus shows remarkably rich motor behavior (e.g., McCartney and Hepper 1999), possibly accompanied by corresponding sensory impressions. A central representation of the body could at least theoretically be built on this richness of very early intrauterine life, even if the motor commands have not emerged from cortical, but spinal, centers. Note that most cases of impaired body integrity (i.e. of dysmelia) are not caused by genetic defects, but by unspecified "accidents", involving limb amputation, during embryogenesis. We suggest that explanations for unequal frequencies of congenital phantoms for upper and lower as well as for left and right limbs (Table 2) may ultimately be found in the "laws" governing fetal development - such as the slightly earlier development of upper compared to lower limbs (O'Rahilly and Gardner 1975) and the differential vascularization of left and right limb buds (Bouwes Bavinck and Weaver 1986). With respect to this laterality issue, we note the surprisingly low interest by embryologists, teratologists and developmental neuroscientist in this issue and plead for a closer collaboration across the different medical and psychological disciplines. Fetal determination of congenital phantom limbs is also considered in the four-component theory introduced by Price (2006). This

thoughtful theory offers an alternative to the genetic hardwiring of body form by delineating the importance of prenatal and postnatal factors, the incorporation of prostheses, and visual factors related to the observation of other people moving their limbs.

Phantoms of congenitally absent limbs as manifestations of the human mirror system

There is anecdotal evidence for phantom sensations being triggered by the observation of other people moving their limbs, both in cases of traumatic amputation (Henderson and Smyth 1948) and congenital limb deficiency (Melzack et al. 1997). A woman born without arms and legs described how visually observing her sister's movements could evoke *feeling* these movements as if they were her own:

"Ever since Deb could walk she was taking care of me. I saw her body move from childhood's awkwardness to adult gracefulness and strength. But not only did I see this, I felt her movements. In a sense, part of her body (the part I lacked on the exterior) was mine too..." (Frank 1986, p 191)

Extensive work with a woman born without forearms and legs (AZ; 44 years old at the time of testing; see Fig. 1) led us to suggest that the visual observation of limb movements could be an important factor in the genesis of congenital phantoms (Brugger et al. 2000). AZ reports that she has been aware of a complete body for as long as she can remember. Specifically, she provided vividness ratings of different body parts that indicated greater awareness for hands and feet compared to lower arms and lower legs, and also seemed to reflect "right-handedness". Not all toes were experienced, and on being shown pictures of hands and ask to adopt their finger postures, she could not imitate all postures depicted (Fig. 1). In a paradigm investigating "apparent motion of body parts" (Shiffrar and Freid 1990), we compared AZ's performance with that of CL, a 43-year-old journalist born without arms, but who had never experienced any phantom sensations (Funk et al. 2005). In this paradigm, what is seen is determined by what can be performed with one's limbs. With hand stimuli, AZ showed the same flash rate-dependent perception of short vs. long apparent motion trajectories as did control individuals with limbs, while CL perceived the short, anatomically impossible trajectories at all interstimulus intervals. It thus turned out that the subjective feeling of having arms and hands was more decisive for the performance in this task than was the physical development of these body parts. More recent research with two aplasic individuals explicitly investigated the reorganization of the human mirror system in the absence of hands (Gazzola et al. 2007). In an fMRI experiment, these subjects and normally limbed control subjects observed a series of hand actions. Compared to a static observation condition, hand movement observation activated major components of the fronto-parieto-temporal mirror system also in the amelic participants. However, there was a matching of visual observation and *action goals* rather than effector-specific execution; that is, visual observation of hand movements led to robust activations of cortical regions involved in the planning and execution of mouth and foot movements. While experiments such as the one by Gazzola et al. (2007) are indispensable for the understanding of the plasticity of the mirror system, they do not tell us about the genesis of congenital phantoms (the authors do not report whether or not their two amelic participants reported phantom

sensations). What is of key interest is a potentially differential reorganization pattern for those (few) amelic persons with phantom experiences compared to those without. This holds not only for the mirror system in particular, but also for any reorganizational process, whether structural (e.g. Funk et al. 2008; Gowers 1878; Nordmann and Lindemann 1940; Stoeckel et al. 2005) or functional (e.g. Cruz et al. 2003; Hamzei et al. 2001), and notably also for cases with an acquired loss of a limb (Giummarra et al. 2007).

Phantoms of congenitally absent limbs: a concluding note

The first part of this review dealt with an aspect of body integrity, which may be exceptional, but is not pathological *per se*. While the physical deficit itself, the absence or deformation of one or several limbs, clearly does reflect a pathological development, the “sensation of integrations” (Valentin 1836) experienced by those reporting congenital phantoms are “as if” experiences, clearly without any delusional coloring. The case of congenital phantoms is highly illustrative from a philosophy-of-science perspective. The nonrecognition of the phenomenon as a “scientific fact” (Fleck 1935/1979; see Brugger and Funk 2006, for discussion) is still ongoing and in stark contrast to the considerable though scattered literature documenting its existence.

In the second part of our review, we discuss a phenomenon that shares as many similarities with the sensation of physically not developed limbs as it shows differences. It is the desire, by non-psychotic individuals, to have a fully functional, physically normally developed limb amputated.

Incarnation without animation: the desire for healthy limb amputation ("body integrity identity disorder", BIID)

Towards the end of the 18th century, a French surgeon was contacted by an Englishman, who asked that one of his legs be removed. The surgeon first refused to comply, but was soon forced to proceed at gunpoint: “...against his will, the surgeon separated the leg from the body, which had fitted perfectly, but had been proscribed by a very particular fantasy” (Sue 1785, p 222). Ironically, the Englishman had himself fitted for a prosthesis, returned to England and sent the surgeon 250 guineas by mail. The accompanying letter contained words of thanks for having removed “a limb which put an invincible obstacle to my happiness” (p 223).

By reporting this anecdote (see also Johnston and Elliott 2002), we want to argue against the view that the desire for healthy limb amputation would constitute “a new way to be mad” (Baubet et al. 2007; Elliott 2000) or an internet-propagated bizarreness. In fact, educated discussions concerning the preoccupation with amputation of one or more of one’s limbs have been around for more than one hundred years. They first surfaced in the early literature on fetishism and sexual paraphilias (von Krafft-Ebing 1886/1965). The emphasis was thus on the erotic component of the desire, present in disorders like “apotemnophilia”, that is, the primarily sexually motivated wish to become an amputee (Money et al. 1977) or “acrotomophilia”, i.e. the sexual preference for amputee partners (Money and Simcoe 1984/86; see Bruno 1997, for a taxonomy of what he called “factitious disability disorder”). Despite the view that an erotic or sexual component may always be part of the desire for amputation (Elliott 2000; First 2005), our own work with

affected persons (Blanke et al. in press; unpublished observations) indicates that there is a “pure form” of amputation desire, not less intense and longstanding, but relatively uncontaminated by aspects related to sexual identity. Individuals presenting with this pure form typically state that they feel “overcomplete” with four limbs, that the image of themselves does not find a reflection in the body they feel trapped in, or simply that the limb they do not identify with is felt as a nuisance or an annoying appendage to their body. Very typically, there is a clear and stable demarcation line between “accepted” and “rejected” areas of a limb.

First (2005) provided the first large-scale study on “an unusual dysfunction in the development of one’s fundamental sense of anatomical (body) identity” (p.919) and for which he proposed the term “body integrity identity disorder” (BIID). Telephone interviews with 52 affected persons without a history of mania, delusions or hallucinations revealed the following pattern (see Table 2): more than 90% were men; age of onset was “overwhelmingly during childhood or early adolescence” (p 924); the amputation desire concerned major limbs rather than single fingers or toes; those individuals desiring a single leg amputation outnumbered those wanting an arm amputation (38 vs. 7 individuals, all bilateral amputation desires concerned legs); left-sided limbs were more often affected (55%) than right-sided limbs (27%); individuals were *not* psychotic and their desire differed from the psychotically motivated urge to perform self-mutilations; co-morbid psychopathology was unremarkable, mainly consisting of mild symptoms of anxiety or depression. In a recent study, we have confirmed the general pattern of these findings (Blanke et al. in press) and proposed an interpretation in neurological terms.

Insert Table 2 about here

The neurological basis of BIID

Specifically, we have suggested that BIID reflects a disturbed integration of multisensory limb information into a coherent cerebral representation of one’s own body as a whole (Blanke et al., in press). A phenomenologically similar disturbance in neuropsychiatric patients is asomatognosia (Arzy et al. 2006; Dieguez et al. 2007), the feeling that a body part is absent or has disappeared from corporeal awareness. Also related may be somatoparaphrenia (Bottini et al. 2002; Gerstmann 1942), the experience of a disownership of body parts contralateral to a unilateral lesion, mostly of the right hemisphere (Vallar and Ronchi 2009, for a recent overview). Still another condition which at least superficially resembles BIID is misoplegia, defined as the hatred of paralyzed limbs that involves cursing at and physical aggression towards a limb (Critchley 1974). We have shown that misoplegia is by no means confined to the presence of a paresis (Loetscher et al. 2006), but as a rule the targets of self-aggression are left-sided body parts (Brugger 2007). Other authors have linked Cotard delusion, which is the conviction that one is dead and one’s body has rotted (Berrios and Luque 1995), to the integrity disorder underlying the desire for amputation (Carruthers 2007;

2008). The qualitative similarities between BIID and these neurological disorders of corporeal awareness suggest that the parietal lobes, especially the multisensory integration areas of the right superior parietal lobule, may be involved. Specifically, we postulated a “disturbed integration of multisensory information of the affected body parts into a coherent cerebral representation of one’s own body” (Blanke et al. in press) as triggering the amputation desire. The affected limb may be entirely functional, yet lack the sort of animation (“*Beseelung*”, in German) we usually feel to be an intrinsic property of any part of our own body.

Recently, this de-animated state of a limb, whose amputation is desired, was demonstrated experimentally. McGeoch et al. (2009) used magnetoencephalography while three individuals with a desire for unilateral leg amputation were touched on the left and the right foot. While in control subjects touch elicited a reliable response in the *right* superior parietal lobule, irrespective of the body side stimulated, in the three persons with BIID the same region was activated upon touch of the normally integrated foot, but it remained silent upon touch of the critical, “unwanted” foot. In one additional participant, who wanted to have both legs amputated, tactile stimulation to neither foot was accompanied by above-threshold right parietal activation. We note that these observations have not yet been subject to the regular peer review process, and further substantiation of these findings seems therefore advisable. Other empirical evidence for a neurological basis of amputation desire comes from the same research group. Brang et al. (2008) applied pinprick stimulation both proximal and distal to the demarcation line on the legs of two persons suffering from BIID. In both cases, distal stimuli elicited an increased electrodermal response compared to proximal stimuli (and to pinpricks of the accepted leg in the subject who wanted a unilateral amputation). No comparable differences between analogous locations were found in control subjects. The magnitude of the electrodermal response is a reliable indicator of sympathetic arousal and is under control of right anterior and limbic circuits (Critchley 2002). Brang et al. (2008) thus interpreted the observed increase in the electrodermal response as the consequence of a dysfunctional superior parietal lobule, which had never learned to integrate (normally received) somatosensory signals from the periphery into a higher-order body representation. A further potential link between BIID and parietal lobe function was pointed out by Ramachandran and McGeoch (2007a), who speculated that caloric vestibular stimulation (specifically left-ear cold water irrigation) could be used to treat BIID by activation of right parietal projection areas of the vestibular system. In fact, somatoparaphrenic delusions can be temporarily abolished by this procedure (Bisiach et al. 1991), but vestibular stimulation is very unlikely to ever “heal” BIID, as it is well known that its effects on bodily awareness vanish as soon as the nystagmoid response has ceased.

BIID and related identity disorders and conditions of self-directed aggression

The metaphor of “the wrong body”, before being used in connection with BIID, was created to illustrate the suffering of people with gender identity disorder (GID). Both GID and BIID are characterized by a profound discontent with actual embodiment; in both, the desire arises to surgically change the current body state. Simulation of the desired identity state occurs in BIID (“pretending” behavior; Bruno 1997) and GID (“crossdressing”;

Schrock and Reid 2006), and there may be a sexual attraction to persons with the target embodiment (the apotemnophilia component in the case of BIID). For a comprehensive review of these and other commonalities see Lawrence (2006). While neuroscientists' relative neglect of issues relating to sexuality has been lamented (Herbert 2008), the few focal attempts to elucidate the brain bases of gender identity deserve to be laudably mentioned, especially as they are highly relevant for the neurological understanding of BIID as well. Ramachandran and McGeoch (2007b; 2008) set out to determine the incidence of phantom penis sensations in male-to-female transsexuals after sex reassignment surgery. They found it to be roughly 30% (6/20), i.e. only about half the figure of 58% reported in the literature on post penectomy phantoms in men without BID. Even more surprising were the findings of a similar survey conducted in female-to-male transsexuals before the desired operation. Eighteen of the 29 persons questioned reported phantom penis experiences (while none of 10 control women did). Together, these observations form strong support for the view that "female-to-male transsexuals do (at least in some respects) possess a man's brain in a woman's body and that the converse is true for male-to-female transsexuals" (Ramachandran and McGeoch 2008, p 14). They also support our notion of BIID as an "incarnation without animation", or a negative phantom limb experience.

Among the conditions not usually regarded as an identity disorder is "compulsive targeted self-injurious behaviour" (SIB), mostly described in people suffering from neuropathic pain (Mailis 1996). As in BIID, specific, circumscribed target areas on the body are identified by those committing SIB (as compared to general, nondirected forms of self-mutilation). Viewed as the human equivalent of animal autotomy (Mailis 1996), the disorder postulates a lack of mental representation of the body part against which physical self-aggression is directed (Lewis et al. 2007). The use of the term "autotomy" in these contexts was criticized by Wilkie et al. (2007), because in zoology it has already a precise and delimited meaning (i.e. self-detachment of a limb), and unlike self-mutilation, the phenomenon is adaptive. Nevertheless, conceived of as "*mental* autotomy" (Brugger 2007; Bilikiewicz 1969 used the term "autotomia imaginaria"), the desire of amputation receives a broader conceptualization, extending it to the field of general vertebrate behavior. A comprehensive listing of the desire (and realization) of body modifications less incisive than limb amputation can be found in the monograph by Kasten (2006).

Observations not readily compatible with BIID as a deficit in limb representation

Although we have ourselves propagated dysfunction of the right parietal lobe as implicated in the genesis of BIID (Brugger 2007; Blanke et al. in press), and others have provided textbook like empirical illustrations of such a dysfunction (McGeoch et al. 2009), we would like to add a word of caution as to the general validity of the "parietal cortex theory" of BIID. Several observations are at variance even with a moderate version of this theory, acknowledging that widely distributed networks between the parietal lobes and other cortical and subcortical structures are involved. The first is the documentation of a change in the desire such as the exceptional shift from wanting a left leg removed to desiring removal of the right. (Kasten 2009; Kasten and Stirn 2009). Another observation not readily compatible with the traditional neurological account of BIID concerns those (minority) cases of the disorder, in which amputation of a target

limb does not bring about the desired relief, and a new amputation desire suddenly develops for a previously well-integrated limb (e.g. Berger et al. 2005). The case communicated by Sorene et al. (2006) is exemplary in this respect (Fig. 2); a 51-year-old non-psychotic civil servant was seen by the authors after having cut his left forearm with an axe. The compulsive desire to have this body part removed newly emerged after several other forced or self-conducted amputations of other limbs, starting with the amputation of the right leg 10 years before. Although rather atypical, this case illustrates that there is still a need for a unifying theory of BIID, which accounts for the broad variability in individual symptoms. We note, however, that in defense of the theory of a defective parietal lobe, it is still possible that a (sub)cortical dysregulation of corporeal awareness could be the cause of an amputation desire for different body parts at different times. For instance, it is known that the right parietal lobe is generally dominant for the attribution of a proper “sense of self” to single body parts, whether left-sided or right-sided (Tsakiris et al. 2008). Thus, amputation at one body site might bring about a transient relief of the desire for amputation, but qualmish feelings about one’s body integrity may later reoccur, and target a body part at a different site and even side.¹

Insert Figure 2 about here

On the other hand, observations like the one reported by Sorene et al. (2006) are also compatible with the view that BIID reflects a general desire for reaching a disabled state (Baubet et al. 2007; Kasten 2009), and that limb specificity is rather secondary. In line with this view are reports about variants of BIID in which the amputation of a limb would be abhorred, but a state of sensory loss is desired instead (desire for paraplegia; Kasten 2009; desire for deafness: Veale 2006).

Finally, the fact that persons with BIID, who succeeded in realizing the desired amputation, do report phantom limbs (Kasten, 2006, p.165; own unpublished observation) seems to speak against a life-long lack of animation of the lost limb. However, it would be unwise to assume that decades of limb use would not have left traces in the brain. Clearly, more research is needed to assess the vividness and persistence of phantom sensations after desired compared to undesired amputation. A first hint in favour of the view of BIID as a “negative phantom” phenomenon is found in the dream reports of persons having had the desired amputation. Compared with published figures for traumatic amputees (reviewed in Brugger 2008), the time until an individual dreams of being amputated is much shorter after a desired amputation (unpublished observations).

BIID: a concluding note

BIID poses fundamental problems to medicine, psychology, ethics and the law. From a medical perspective, there is no consensus on what causes the desire for amputation. Currently, BIID is not listed in the *Diagnostic and Statistical Manual of Mental Disorder* (DSM-IV-TR), and its prevalence, diagnostic classification and potential treatments are unknown or controversial. There is a remarkable upsurge of ethical discussions about

¹ We thank an anonymous referee for pointing out this possibility.

how to cope with the amputation requests of a rapidly growing community of people avowing themselves to BIID. While the ethical aspects of GID are relatively clear, those concerning BIID are a matter of fervent debate (Müller 2008 and associated open peer commentary). With regard to the many open questions surrounding BIID, Johnston and Elliot (2002, p 435) concluded: “We believe that the proper response to people who wish to have healthy limbs amputated will not become clear until much more is known about the nature of the condition itself.” We hope that the present review will sensitize clinicians and researchers to recognize a phenomenon, whose understanding may not only lead to novel insights about how the brain mediates the experience of an embodied self, but whose investigation will necessarily help in bridging the many gaps that still exist between neurology and psychiatry.

Acknowledgment:

We acknowledge a fellowship of the Roche Research Foundation to the first author. The work on congenital phantom limbs was supported by the Swiss National Science Foundation (grant no. 3100-67168.01). We thank Caroline Schwarz (Zürich) for helpful comments.

References

- Abramson AS, Feibel A (1981) The phantom phenomenon: its use and disuse. *Bulletin of the New York Academy of Medicine* 57:99-112
- Arzy S, Petit L, Landis T, Blanke O (2006) Neural mechanisms of embodiment. Asomatognosia due to premotor cortex damage. *Archives of Neurology* 63:1022-1025
- Baubet T, Gal B, Dendoncker-Viry S, Masquelet AC, Gatt MT, Moro MR (2007) Apotemnophilia as a contemporary frame for psychological suffering. *Encephale* 33:609-615.
- Berger BD, Lehrmann JA, Larson G, Alverno L, Tsao CI (2005) Nonpsychotic, nonparaphilic self-amputation and the internet. *Comprehensive Psychiatry* 46:380-383
- Berrios GE, Luque R (1995) Cotard's syndrome: analysis of 100 cases. *Acta Psychiatrica Scandinavica* 91:185-188
- Bilikiewicz T (1969) Total somatectomy and its psychopathological consequences. *Polish Medical Journal*, 8:481-493
- Bisiach E, Rusconi ML, Vallar G (1991) Remission of somatoparaphrenic delusion through vestibular stimulation. *Neuropsychologia* 10:1029-1031
- Blanke O, Morgenthaler FD, Brugger P, Overney LS (in press) Preliminary evidence for a fronto-parietal dysfunction in able-bodied participants with a desire for limb amputation. *Journal of Neuropsychology*
- Boonstra AM, Rijnders LJ, Groothoff JW, Eisma WH (2000) Children with congenital deficiencies or acquired amputations of the lower limbs: functional aspects. *Prosthetics and Orthotics International* 24:19-27
- Bottini G, Bisiach E, Sterzi R, Vallar G (2002) Feeling touches in someone else's hand. *Neuroreport* 13:249-252
- Bouwes Bavinck JN, Weaver DD (1986) Subclavian artery supply disruption sequence: hypothesis of a vascular etiology for Poland, Klippel-Feil, and Moebius anomalies. *American Journal of Medical Genetics* 23: 903-918
- Braam AW, Visser S, Cath DC, Hoogendijk WJG (2006) Case study: investigation of the syndrome of apotemnophilia and course of a cognitive-behavioural therapy. *Psychopathology* 39:32-37
- Brang D, McGeoch PD, Ramachandran VS (2008) Apotemnophilia: a neurological disorder. *Neuroreport* 19:1305-1306
- Brugger P (2007) Hostile interactions between body and self. *Dialogues in Clinical Neuroscience* 9:210-213
- Brugger P (2008) Phantom limbs in dreams. *Consciousness and Cognition* 17:1272-1278
- Brugger P, Funk M (2006) Out on a limb: neglect and confabulation in the study of "aplastic phantoms". In: Sala S (ed) *Tall tales about the mind and brain. Separating fact from fiction*. Oxford University Press. Oxford, pp 348-368
- Brugger P, Kollias SS, Müri RM, Crelier G, Hepp-Reymond MC, Regard M (2000) Beyond re-membering: phantom sensations of congenitally absent limbs. *Proceedings of the National Academy of Sciences of the USA* 97:6167-6172
- Bruno RL (1997) Devotees, pretenders and wannabes: two cases of factitious disability disorder. *Journal of Sexuality and Disability* 15:243-260

- Burchard JM (1965) Zur Frage nach der Natur von Phantomerlebnissen bei angeborener Gliedmassenverstümmelung. *Archiv für Psychiatrie und Nervenkrankheiten* 207:360-377
- Carruthers G (2007) A model of the synchronic self. *Consciousness and Cognition* 16:533-550
- Carruthers G (2008) Types of body representation and the sense of embodiment. *Consciousness and Cognition* 17:1302-1316
- Critchley M (1974) Misoplegia, or hatred of hemiplegia. *Mount Sinai Journal of Medicine* 41:82-87
- Critchley HD (2002) Electrodermal responses: what happens in the brain. *Neuroscientist* 8:132-142
- Cruz VT, Nunes B, Reis AM, Pereira JR (2003) Cortical remapping in amputees and dysmelic patients: a functional MRI study. *NeuroRehabilitation* 18:299-305
- Dieguez S, Staub F, Bogousslavsky J (2007) In: Godefroy O, Bogousslavsky J (eds.) *The behavioral and cognitive neurology of stroke*. Cambridge University Press, Cambridge, pp 215-253
- Elliott C (2000) A new way to be mad. *Atlantic Monthly*, digital edition. <<http://www.theatlantic.com/doc/200012/madness>> Accessed 15 April 2009
- Finger S, Hustwit MP (2003) Five early accounts of phantom limb in context: Paré, Descartes, Lemos, Bell, and Mitchell. *Neurosurgery* 52:675-686
- First MB (2005) Desire for amputation of a limb: paraphilia, psychosis, or a new type of identity disorder. *Psychological Medicine* 35:919-928
- Fisher K, Smith R (2000) More work is needed to explain why patients ask for amputation of healthy limbs. *British Medical Journal* 320:1147
- Fleck L (1935/1979) *Genesis and Development of a scientific fact*. University of Chicago Press, Chicago/London (Original: *Entstehung und Entwicklung einer wissenschaftlichen Tatsache. Einführung in die Lehre vom Denkstil und Denkkollektiv*. Schwabe, Basel)
- Frank G (1986) On embodiment: a case study of congenital limb deficiency in American culture. *Culture, Medicine and Psychiatry* 10:189-219
- Froster-Iskenius UG, Baird PA (1990) Amelia: incidence and associated defects in a large population. *Teratology* 41:23-31
- Funk M, Brugger P (2008) Mental rotation of congenitally absent hands. *Journal of the International Neuropsychological Society* 14:81-89
- Funk M, Lutz K, Hotz-Boendermaker S, Roos M, Summers P, Brugger P, Hepp-Reymond MC, Kollias SS (2008) Sensorimotor tongue representation in individuals with unilateral upper limb amelia. *Neuroimage* 43:121-127
- Funk M, Shiffrar M, Brugger P (2005) Hand movement observation by individuals born without hands: Phantom limb experience constrains visual limb perception. *Experimental Brain Research* 164:341-346
- Gallagher S, Butterworth G, Lew A, Cole J (1998) Hand-mouth coordination, congenital absence of limb, and evidence for innate body schemas. *Brain and Cognition* 38:53-65
- Gazzola V, van der Worp H, Mulder T, Wicker B, Rizzolatti G, Keysers C (2007) Aplasics born without hands mirror the goal of hand actions with their feet. *Current Biology* 17:1235-1240

- Gerstmann J (1942) Problem of imperception of disease and of impaired body territories with organic lesions. Relation to body scheme and its disorders. *Archives of Neurology and Psychiatry* 48:890-913
- Giummarra MJ, Gibson SJ, Georgiou-Karistianis N, Bradshaw JL (2007) Central mechanisms in phantom limb perception: the past, present and future. *Brain research reviews* 54:219-232
- Gowers WR (1878) The brain in congenital absence of one hand. *Brain* 1:388-390
- Grouios G (1996) Phantom limb perceptuomotor “memories” in a congenital limb child. *Medical Science Research* 24:503-504
- Halligan PW (2002) Phantom limbs: The body in mind. *Cognitive Neuropsychiatry* 7:251-269
- Hamzei F, Liepert J, Dettmers C, Adler T, Kiebel S, Rijnjes M, Weiller C (2001) Structural and functional cortical abnormalities after upper limb amputation during childhood. *Motor Systems* 12:957-962
- Henderson WF, Smyth GE (1948) Phantom limbs. *Journal of Neurology, Neurosurgery, and Psychiatry* 11:88-112
- Hepper PG, McCartney GR, Shannon EA (1998) Lateralized behaviour in first trimester human foetuses. *Neuropsychologia* 36:531-534
- Hepper PG, Wells DL, Lynch C (2005) Prenatal thumb sucking is related to postnatal handedness. *Neuropsychologia* 43:313-315
- Herbert J (2008) Who do we think we are? The brain and gender identity. *Brain* 131:3115-3117
- Jacobson E (1931) Electrical measurements of neuromuscular states during mental activities. VI: A note on mental activities concerning an amputated limb. *American Journal of Physiology* 96:122-125
- Johnston J, Elliott C (2002) Healthy limb amputation: ethical and legal aspects. *Clinical Medicine* 2:431-435
- Kasten E (2006) *Body-Modification. Psychologische und medizinische Aspekte von Piercing, Tattoo, Selbstverletzung und anderen Körperveränderungen.* Ernst Reinhardt, München
- Kasten E (2009) Body Integrity Identity Disorder (BIID): Befragung von Betroffenen und Erklärungsansätze. *Fortschritte der Neurologie-Psychiatrie* 77:16-24
- Kasten E, Stirn A (2009) Body Integrity Identity Disorder (BIID). Wechselnder Amputationswunsch vom linken auf das rechte Bein. *Zeitschrift für Psychiatrie, Psychologie und Psychotherapie* 57:55-61
- Kooijman CM, Dijkstra PU, Geertzen JHB, Elzinga A, van der Schans CP (2000) Phantom pain and phantom sensations in upper limb amputees: an epidemiological study. *Pain* 87:33-41
- Lawrence AA (2006) Clinical and theoretical parallels between desire for limb amputation and gender identity disorder. *Archives of Sexual Behavior* 35:263-78
- Lenz W (1988) A short history of thalidomide embryopathy. *Teratology* 38:203-215
- Lewis JS, Kersten P, McCabe CS, McPherson KM, Blake DR (2007) Body perception disturbance: a contribution to pain in complex regional pain syndrome (CRPS). *Pain* 133:111-119

- Loetscher T, Regard M, Brugger P (2006) Misoplegia: a review of the literature and a case without hemiplegia. *Journal of Neurology, Neurosurgery & Psychiatry* 77:1099-1100
- Mailis A (1996) Compulsive targeted self-injurious behaviour in humans with neuropathic pain: a counterpart of animal autotomy? Four case reports and literature review. *Pain* 64:569-578
- McCartney G, Hepper P (1999) Development of laterlized behaviour in the human fetus from 12 to 27 weeks' gestation. *Developmental Medicine and Child Neurology* 41:83-86
- McGeoch PD, Brang D, Song T et al (2009) Apotemnophilia - the neurological basis of a 'psychological' disorder. Available from Nature Precedings <<http://hdl.handle.net/10101/npre.2009.2954.1>> (2009) Accessed 30 July 2009
- Melzack R (1990) Phantom limbs and the concept of a neuromatrix. *Trends in Neurosciences* 13:88-92
- Melzack R, Israel R, Lacroix R, Schultz G (1997) Phantom limbs in people with congenital limb deficiency or amputation in early childhood. *Brain* 120:1603-1620
- Mikorey M (1952) *Phantome und Doppelgänger*. JF Lehmanns, Munich
- Money J, Jobaris R, Furth G (1977) Apotemnophilia: Two cases of self-demand amputation as a paraphilia. *Journal of Sex Research* 13:115-125
- Money J, Simcoe KW (1984-86) Acrotomophilia, sex and disability: new concepts and case reports. *Sexuality and Disability* 7:43-50
- Müller S (2008) Body Integrity Identity Disorder (BIID) – Lassen sich Amputationen gesunder Gliedmassen ethisch rechtfertigen? *Ethik in der Medizin* 20:1-13
- Nordmann M, Lindemann K (1940) Tetraparomelie und Zentralnervensystem. *Virchows Archiv für Pathologische Anatomie und Physiologie und für klinische Medizin*, 306:175-182
- O'Rahilly R (1951) Morphological patterns in limb deficiencies and duplications. *American Journal of Anatomy* 89:135-193
- O'Rahilly R, Gardner E (1975) The timing and sequence of events in the development of the limbs in the human embryo, *Anatomy and Embryology* 148:1-23
- Pick A (1915) Zur Pathologie des Bewusstseins vom eigenen Körper. Ein Beitrag aus der Kriegsmedizin. *Neurologisches Centralblatt* 34:257-265
- Poeck K (1964) Phantoms following amputation in early childhood and in congenital absence of limbs. *Cortex* 1:269-275
- Poeck K (1969) Phantome nach Amputation und bei angeborenem Gliedmassenmangel. *Deutsche Medizinische Wochenschrift* 94:2367-2374
- Price EH (2006) A critical review of congenital phantom limb cases and a development theory for the basis of body image. *Consciousness and Cognition* 15:310-322
- Ramachandran VS (1993) Behavioral and magnetoencephalographic correlates of plasticity in the adult human brain. *Proceedings of the National Academy of Sciences of the USA* 90:10413-10420
- Ramachandran VS, McGeoch P (2007a) Can vestibular caloric stimulation be used to treat apotemnophilia? *Medical Hypotheses* 69:250-252
- Ramachandran VS, McGeoch P (2007b) Occurrence of phantom genitalia after gender reassignment surgery. *Medical Hypotheses* 69:1001-1003

- Ramachandran VS, McGeoch P (2008) Phantom penises in transsexuals. *Journal of Consciousness Studies* 15:5-16
- Saadah ES, Melzack R (1994) Phantom limb experiences in congenital limb-deficient adults. *Cortex* 30:479-485
- Sathian K (2000) Intermanual referral of sensation to anesthetic hands. *Neurology* 54:1866-1868
- Scatena P (1990) Phantom representations of congenitally absent limbs. *Perceptual and Motor Skills* 70:1227-1232
- Schrock DP, Reid LL (2006) Transsexuals' sexual stories. *Archives of Sexual Behavior* 35:75-86
- Shiffrar M, Freyd JJ (1990) Apparent motion of the human body. *Psychological Science* 1:257-264
- Simmel M (1956) On phantom limbs. *Archives of Neurology and Psychiatry* 75:637-647
- Simmel ML (1961) The absence of phantoms for congenitally missing limbs. *American Journal of Psychology* 74:467-470
- Simmel ML (1966) Developmental aspects of the body scheme. *Child Development* 37:83-95
- Skoyles JR (1990) Is there a genetic component to body schema? *Trends in Neuroscience* 13:409
- Sohn DL (1914) The psychic complex in congenital deformity. *New York Medical Journal* 100:959-961
- Sorene ED, Heras-Palou C, Burke FD (2006) Self-amputation of a healthy hand: a case of body integrity identity disorder 31B:593-595
- Stoeckel MC, Jörgens S, Witte OW, Seitz RJ (2005) Reduced somatosensory hand representation in thalidomide-induced dysmelia as revealed by fMRI. *European Journal of Neuroscience* 21:556-562
- Sue P (1785) *Anecdotes historiques, littéraires et critiques sur la médecine, la chirurgie et la pharmacie* (part 1). Le Boucher, Paris, Amsterdam
- Tsakiris M, Constantini M, Haggard P (2008) The role of the right temporo-parietal junction in maintaining a coherent sense of one's body. *Neuropsychologia* 46: 3014-3018
- Valentin G (1836) Über die subjektiven Gefühle von Personen, welche mit mangelhaften Extremitäten geboren sind. *Repertorium für Anatomie und Physiologie* 1:328-337
- Vallar G, Ronchi R (2009) Somatoparaphrenia: a body delusion. A review of the neuropsychological literature. *Experimental Brain Research* 192:533-551
- Veale D (2006) A compelling desire for deafness. *Journal of Deaf Studies and Deaf Education* 11:369-72
- von Krafft-Ebing R (1965) *Psychopathia Sexualis* (F.S. Klaf, Trans.). Stein and Day, New York. (Original work published 1886)
- Weinstein S, Sersen EA (1961) Phantoms in cases of congenital absence of limbs. *Neurology* 11:905-911
- Weinstein S, Sersen EA, Vetter RJ (1964) Phantoms and somatic sensation in cases of congenital aplasia. *Cortex* 1:276-290
- Wilkie IC, Dolan S, Lewis J, Blake DR (2007) 'Autotomy': a terminological inexactitude. *Pain* 128:286-287

Wilkins KL, McGrath PJ, Finley GA, Katz J (1998) Phantom limb sensations and phantom limb pain in child and adolescent amputees. *Pain* 78:7-12

Xue CC (1986) Acupuncture induced phantom limb and meridian phenomenon on acquired and congenital amputees. *Chinese Medical Journal* 99:247-252

Table Captions and Figure Legends

Table 1:

Published reports on phantom sensations of congenitally absent or deformed limbs. Not included are cases of phantom limbs that first occurred after major stump surgery, after amputations in very early childhood, or exclusively in night dreams.

(Adopted from Brugger and Funk 2006 and Price, 2006)

Table 2:

Similarities and differences between the condition of congenital phantoms and the desire for amputation. Selected key references document the respective points of similarity explicitly.

Figure 1:

One way to diminish the chances that one is duped by a dysmelic individual's claims about phantom limbs, is to ask about postural details, which can hardly be faked without expert knowledge. Top: subject AZ (born without lower arms; left panel) reported that she occasionally folded her phantom arms "as normal people do". Folding them on command, she indicated that the left was on top of the right (middle panel). On being asked to fold her phantom arms "the other way round" (i.e. to put the right on top of the left; right panel) she immediately showed an expression of discomfort and commented that this posture "feels extremely awkward". Bottom: shown drawings of hands with the request to mimic the depicted finger posture and to indicate the vividness of the resulting phantom sensation (on a 7-point scale), AZ' vividness ratings matched those of normal controls, who had to imagine taking the shown postures. Specifically, item 4 received a very low rating (note the anatomical impossibility of a fully stretched ring finger!).

Figure 2:

Even if atypical, this case of a man in his early fifties illustrates that theories of BIID unilaterally focusing on a failed integration of a particular limb cannot account for all clinical shades of the disorder. After having forced an amputation of the right leg, satisfying the initial desire for amputation, a new desire arose, this time targeting the right little finger. Later the desire for amputation spread to the little finger and then to the ring finger of the left hand, and ultimately to the whole forearm.

After Sorene et al. (2006), Fig. 2; reprinted with permission.

TABLE 1:

References:	nb. of congenital phantoms per nb. of persons examined	cumulative nr. of cases with congenital phantom limbs
Valentin 1836; Sohn 1914; Mikorey 1952; Poeck 1964; Ramachandran 1993; Grouios 1996; Brugger et al. 2000	1/1 each	7
Burchard 1965	1/17	8
Boonstra et al. 2000	1/26	9
Kooijman et al. 2000	1/27	10
Simmel 1961	2/27	12
Xue 1986	2/2	14
Wilkins et al. 1998	2/17	16
Valentin 1836	4/4	20
Saadah & Melzack 1994	7/75	27
Weinstein & Sersen 1961	5/30	32
Weinstein et al. 1964	13/71	45
Melzack et al. 1997	15/76	60*

* average incidence (the 7 single case reports excluded) = 16.1%

TABLE 2:

	phantom sensations of congenitally absent limbs	desire for amputation (BIID)
COMMONALITIES:		
May be underreported (reluctance to mention the condition)	Abramson and Feibel 1981; Scatena 1990	Fisher and Smith 2000; Braam et al. 2006
First manifestation early in life	Melzack et al. 1997	First 2005
Bias in favour of left-sided limbs*	Price 2006	Brugger 2007
Visual triggering of sensation/desire reported	Frank 1986; Melzack et al. 1997	Blanke et al. in press; Kasten 2009
Cortical correlates of condition demonstrated	Brugger et al. 2000	Brang et al. 2008; McGeoch et al. 2009
No unifying theory formulated	Brugger and Funk 2006; Price 2006	Kasten 2009; Müller 2008
MAJOR DIFFERENCES:		
Gender bias	absent	more frequent in men
Upper vs. lower extremities	more frequent for arms	more frequent for legs
Suffering	absent	present
Sexual component	absent	may be present
Obsessive-compulsive component	absent	often present
Stability of affected limb	stable	may shift

* for phantom sensations a consequence of a higher incidence of left-sided dysmelia in general, at least for upper limbs (e.g. Simmel 1961, footnote 6)

Figure 1:

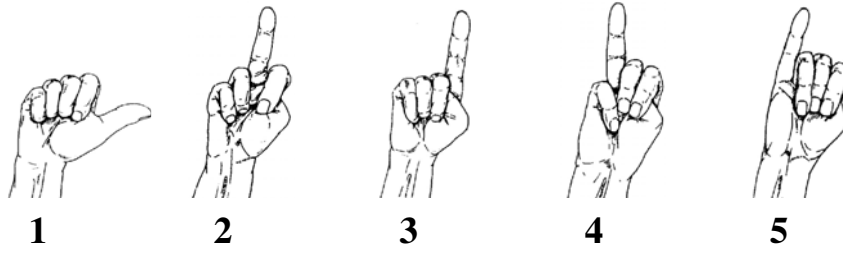


Figure 2:

