



**University of
Zurich**^{UZH}

**Zurich Open Repository and
Archive**

University of Zurich
University Library
Strickhofstrasse 39
CH-8057 Zurich
www.zora.uzh.ch

Year: 2010

Diagnostic evaluation of a foal with cerebellar abiotrophy using magnetic resonance imaging (MRI)

Pongratz, Michaela Carina ; Kircher, Patrick R ; Lang, J ; Hilbe, Monika ; Wehrli Eser, Meret

DOI: <https://doi.org/10.21836/PEM20100410>

Other titles: Diagnosestellung bei einem Fohlen mit zerebellärer Abiotrophie mittels Magnetresonanztomographie (MRT)

Posted at the Zurich Open Repository and Archive, University of Zurich

ZORA URL: <https://doi.org/10.5167/uzh-42223>

Journal Article

Originally published at:

Pongratz, Michaela Carina; Kircher, Patrick R; Lang, J; Hilbe, Monika; Wehrli Eser, Meret (2010). Diagnostic evaluation of a foal with cerebellar abiotrophy using magnetic resonance imaging (MRI). *Pferdeheilkunde*, 26(4):559-562.

DOI: <https://doi.org/10.21836/PEM20100410>

Diagnostic evaluation of a foal with Cerebellar Abiotrophy using Magnetic Resonance Imaging (MRI)

Michaela C. Pongratz¹, Patrick Kircher², Johann Lang³, Monica Hilbe⁴ und Meret Wehrli Eser¹

Equine Department¹, Section of Diagnostic Imaging² and Department of Veterinary Pathology⁴, Vetsuisse Faculty of the University of Zurich, Switzerland; and Section of Clinical Radiology³, Vetsuisse Faculty of the University of Bern, Switzerland

Summary

Cerebellar abiotrophy (CA) is a neurological disease in foals that is most frequently observed in pure-bred and part-bred Arabians. The disease is caused by progressive cell death of the Purkinje cells starting shortly after birth. Since these cells cannot regenerate, cellular apoptosis results in atrophy and permanent loss of the affected cerebellar region, resulting in cerebellar ataxia characterized by proprioceptive deficits, hypermetric gait, head tremors, and lack of menace reflex. The triggering factors are unknown to date, but an inborn intrinsic metabolic defect is discussed. In previous reports, exogenous insults as, heavy metal intoxications, inherited susceptibility and virus infections were discussed. Similarities can be seen between the pathology of CA in foals and the one found in other species with cerebellar degeneration, as for example the feline panleucopenia virus infection in kittens, the Rubella virus infection in humans, or the intrauterine Akabane Virus infection causing hydranencephaly and arthrogryposis in cattle. Therefore, a viral etiology cannot be excluded in horses. However, more recent results are strongly suggestive of an inheritable genetic predisposition caused by an autosomal recessive gene. Although the clinical signs are distinctive, histopathological examinations are necessary for definitive diagnosis. Up to now, no genetic test is available to confirm the diagnosis ante mortem. Diagnostic imaging may be helpful to support the diagnosis of CA, but distinctive findings of computed tomography (CT) and magnetic resonance imaging (MRI), respectively, have not been described in the foal so far. This report describes clinical signs and MRI findings in a foal diagnosed with CA.

Keywords: Arabian horse, foal, cerebellar abiotrophy, MRI diagnostics, histopathologic findings

Diagnosestellung bei einem Fohlen mit zerebellärer Abiotrophie mittels Magnetresonanztomographie (MRT)

Die zerebelläre Abiotrophie (ZA) ist eine neurologische Erkrankung beim Fohlen, welche vor allem bei Araberpferden und deren Kreuzungen beobachtet wird. Die Erkrankung wird durch einen progressiven Zelltod der Purkinjezellen verursacht, der kurz nach der Geburt beginnt. Da Purkinjezellen nicht regenerieren können, resultiert die Apoptose in einer Atrophie der entsprechenden Zellen und führt somit zu einem permanenten Verlust in der betroffenen zerebellären Region. Das betroffene Tier zeigt eine zerebelläre Ataxie, die vor allem charakterisiert ist durch propriozeptive Defizite, hypermetrischen Gang, Kopftremor und Verlust des Drohreflexes. Die auslösenden Faktoren sind bis heute unbekannt, aber ein angeborener intrinsischer metabolischer Defekt wird diskutiert. In früheren Publikationen wurden auch exogene Einflüsse diskutiert, wie Schwermetallintoxikationen, vererbte Empfänglichkeit und Virusinfektionen. Ähnlichkeiten zwischen der Pathologie der ZA bei Fohlen und zerebellärer Degeneration bei anderen Spezies können beobachtet werden, zum Beispiel bei der Infektion von Katzenwelpen mit dem feline Panleukopenievirus, beim Säugling mit dem Rubellavirus oder bei Kälbern mit dem Akabanevirus, welches sogar eine Hydranencephalie und Arthrogryposis verursachen kann. Aufgrund dieser Ähnlichkeiten kann eine virale Ätiologie beim Pferd nicht vollständig ausgeschlossen werden. Die neusten wissenschaftlichen Ergebnisse jedoch sprechen stark für eine vererbte genetische Prädisposition verursacht durch ein autosomal rezessives Gen. Obwohl die klinischen Krankheitsanzeichen sehr charakteristisch sind, ist nach wie vor eine histopathologische Untersuchung nötig, um die Diagnose definitiv zu bestätigen. Bis heute ist noch keine genetischer Test auf dem Markt, um eine Diagnose ante-mortem zu belegen. Bildgebende Verfahren sind hilfreiche Mittel um die Diagnose ZA zu untermauern, aber beweisende Resultate erstellt mittels Computertomographie (CT) bzw. Magnetresonanztomographie (MRT) wurden bis heute beim Fohlen nicht beschrieben. Dieser Fallbericht beschreibt die klinischen Symptome und die MRT Befunde eines Fohlens mit zerebellärer Abiotrophie.

Schlüsselwörter: Araberpferd, Fohlen, zerebelläre Abiotrophie, MRT Diagnosestellung, Histopathologische Befunde

Introduction

Cerebellar abiotrophy (CA) is a neurological disease in foals that is most frequently observed in pure-bred and part-bred Arabians (Baird und Mackenzie 1974, Dungworth und Fowler 1966). The disease is caused by progressive cell death of the Purkinje cells starting shortly after birth. Since these cells cannot regenerate, cellular apoptosis results in atrophy and permanent loss of the affected cerebellar region, resulting in cerebellar ataxia characterized by proprioceptive deficits, wide-legged stance, stiff or hypermetric gait, head tremors (intention tremors), coarse or jerky head bobs, and lack of menace reflex (Blanco et al. 2006, Fox et al. 2000, Scarratt

2004). Neonates often appear normal. Clinical signs become obvious within the first weeks or months of age, and most of the affected animals are diagnosed before the age of six months (Adams und Mayhew 1984, Adams und Mayhew 1985, DeBowes et al. 1987, Furr 2008a, Gerber 1995, LeGonidec et al. 1981, Mayhew 1988, Palmer et al. 1973).

The triggering factors are unknown to date, but an inborn intrinsic metabolic defect is discussed (Blanco et al. 2006, Fox et al. 2000, Scarratt 2004). In previous reports, exogenous insults as, cerebellar nematodiasis (Palmer et al. 1973) plant, heavy metal or mineral toxic intoxications (Hartley et al. 1982, LeGonidec et al. 1981) head traumas (MacKay 2004)

inherited susceptibility (DeBowes et al. 1987) and virus infections (Gerber 1995, Palmer et al. 1973) were discussed. Similarities can be seen between the pathology of CA in foals and the one found in other species with cerebellar degeneration, as for example the feline panleucopenia virus infection in kittens, the Rubella virus infection in humans, or the intra-uterine Akabane Virus infection causing hydranencephaly and arthrogryposis in cattle. Therefore, a viral etiology cannot be excluded in horses (Palmer et al. 1973). However, more recent results are strongly suggestive of an inheritable genetic predisposition caused by an

autosomal recessive gene. In humans, cerebellar ataxias can be inherited by autosomal recessive or dominant traits, and for several conditions the genetic defect has been identified (Klockgether und Evert 1998) Much less is known about the genes involved in similar disease in domestic animals.

Other possible causes such as neurotoxicity, nutritional deficiency, or a spontaneous dominant mutation cannot be ruled out (Fox et al. 2000). The relatively high heritability of 8% in horses is presumably caused by consanguinity such as in inbred or linebred breeds (Gerber 1995). Cerebellar Abiotrophy (CA) is considered a non-curable disease and cannot be prevented other than by selective breeding (Gerber 1995). There are, however, anecdotal reports describing varying degrees of clinical improvement with almost complete resolution of clinical signs when reaching adulthood. This could be caused by some degree of learned accommodation in higher cerebral centres that allowed some affected individuals to improve over time. (DeBowes et al. 1987) Nevertheless, in practice, the majority of horses suffering from CA are euthanized before adulthood as they are of significant danger to themselves and others.

Although the clinical signs are distinctive, histopathological examinations are necessary for definitive diagnosis. Up to now, no genetic test is available to confirm the diagnosis ante mortem. Diagnostic imaging may be helpful to support the diagnosis of CA, but distinctive findings of computed tomography (CT) and magnetic resonance imaging (MRI), respectively, have not been described in the foal so far. This report describes clinical signs and MRI findings in a foal diagnosed with CA.

Case Report

A three-month-old pure-bred Arabian colt was presented to the Equine Department at the Vetsuisse Faculty of the University of Zurich with a history of progressive ataxia and head tremors that had started 3 weeks prior to admission. The foal had previously been presented at the hospital as a neonate for treatment of hypogammaglobulinemia. At that time, the foal did not show any neurologic deficits, was able to stand and walk, and it had a normal suckle reflex. Temporary weakness, trembling, and slight incoordination were only noticed immediately after sedation and plasma transfusion and were not attributed to neurological disease at that time.

When the foal presented three months later, it was in good general condition, alert, responsive, and neither showed weight loss nor loss of muscle tone. The physical examination revealed tachycardia (88 bpm) and tachypnea (80 bpm). Rec-

tal temperature was within normal limits (38.5 C°). The mucus membranes were normal as well as thoracic, cardiac, and abdominal auscultation. The neurologic examination revealed normal cranial nerve functions with the exception of a reduced bilateral menace reflex. The foal had normal palpebral reflexes and no visual deficits. It showed vertical head tremor (intention tremor) especially when it was excited or trying to focus on objects such as food, the dam's udder, stable equipment, or items on the ground. The foal showed generalized, grade 2-3/5 ataxia (De Lahunta 1983, Furr 2008b, Mayhew 1989, Reed 1998) and hypermetric gait. At a walk, the lurching and swaying movements were exaggerated by neck extension or turnings in tight circles. Backing up was not performed as the foal had a history hyperresponsiveness leading to rearing and flipping over backwards even with normal handling.

Complete blood count (CBC), plasma fibrinogen concentration, erythrocyte sedimentation rate, and serum biochemistry analysis were all within normal limits. Radiographs of the cervical vertebral column were judged within normal limits.

Based on these findings, the suspected clinical diagnosis was CA. The list of differential diagnoses included occipital atlanto-axial malformation (OAAM), cervical vertebral malformation, cerebellar hypoplasia, primary pituitary gland diseases, cerebellar hematoma, abscess, or neoplasia (Palmer et al. 1973, Scarratt 2004) Further diagnostic tests, including cerebrospinal fluid (CSF) analysis and MRI examination, were proposed but declined by the owner.

Five months later, the owner decided to have the foal evaluated by MRI because the clinical signs had progressed significantly. At that time, a MRI interrogation was conducted, but no CSF analysis was performed. A low-field MRI unit (0.3 Tesla)^o was used. The foal was positioned in dorsal recumbency on a non-metallic scanning table under general anaesthesia. A small body coil was installed with the neurocranium positioned in its isocenter. The protocol included a T1-weighted spin echo sequence (TE: 18.3; TR: 400) in a transverse plane, T2-weighted fast spin echo sequences (TE: 125; TR: 3540) in transverse und sagittal planes (Figure 1 A and B), and a fluid attenuation inversion recovery (FLAIR) sequence (Figure 2 B) in dorsal plane (TE: 120; TR: 8000; IR: 900). In addition, a dorsal plane spoiled steady state acquisition rewinded gradient echo sequence (BASG, Figure 2 A), a sequence with high resolution and soft tissue contrast, was acquired.

All MR images were characterized by a distinct increased visibility of the arbor vitae (arborisation). The T2-weighted images showed substantially enlarged spaces of cerebrospinal fluid in the caudal fossa (Figure 1). The fluid signal was adequately suppressed in the FLAIR sequence, proofing normal cerebrospinal fluid within those spaces (Figure 2 B). In T1 and the BASG sequence, a significantly thinned marrow bed and an overall moderate to severe decreased volume of the cerebellar cortex were visualized (Figure 2 A). As an incidental finding, a very small and flat shaped pituitary gland was detected. The cerebrum and the brainstem were within normal limits. These MRI findings in conjunction with the clinical signs were compatible with CA.

Because of the severity and rapid progression of the clinical signs the prognosis was considered guarded to poor and the

owners decided to euthanize the foal during anesthesia. A complete necropsy was performed subsequently. The post mortem examination revealed a distinct reduction in size of

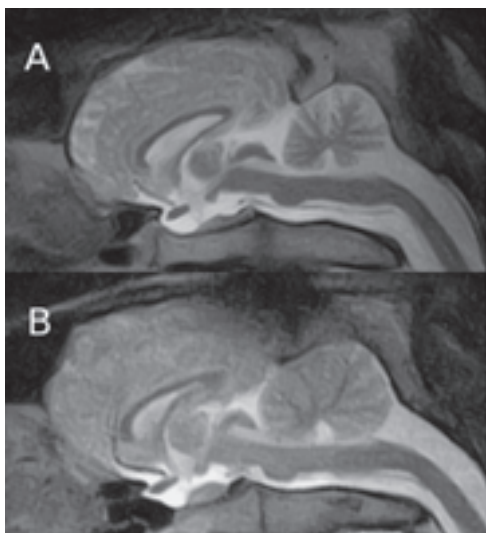


Fig. 1 Sagittal images, T2-weighted: Note the increased CSF spaces with marked reduction of the cortical volume of the cerebellum leaving an increased visibility of the arbor vitae in the foal with CA (A) compared to the normal control (B).

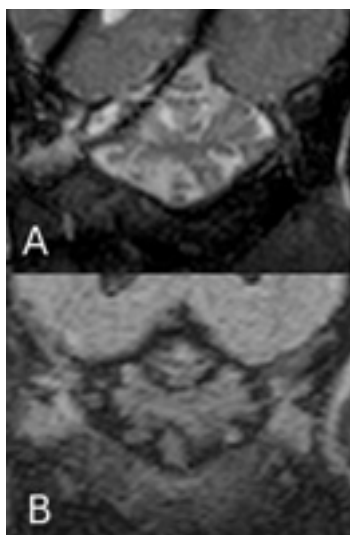


Fig. 2 A, Dorsal plane steady state gradient echo (BASG) of the cerebellum. B, Dorsal plane fluid attenuated recovery sequence (FLAIR). In the BASG sequence there is marked widening of the CSF spaces visible. These hyperintense spaces are suppressed in the FLAIR indicating the CSF nature of the fluid within the spaces.

the cerebellum (Figure 3) and a dorsoventral flat shaped pituitary gland and medulla oblongata. Histology was arranged with brain, entire spinal cord, pituitary gland. These tissues were fixed in 4% neutral buffered formalin, processed, embedded in paraffin, sectioned at 2-3 μ m and stained with hematoxylin eosine (HE). The histological examination of the cerebellum revealed moderate to distinct generalized rarefaction and local thinning of the granular layer and marked reduction in the number of Purkinje cells. The few remaining Purkinje cells had a normal histological appearance, only some showing hyper eosinophilic cytoplasm and a pyknotic nucleus interpreted as degeneration. Bergman glia was prominent and increased. Neither degeneration and demyeliza-

tion nor inflammatory processes were seen in brain and spinal cord. An additional finding was a decreased size of the pars distalis of the pituitary gland interpreted as atrophy.

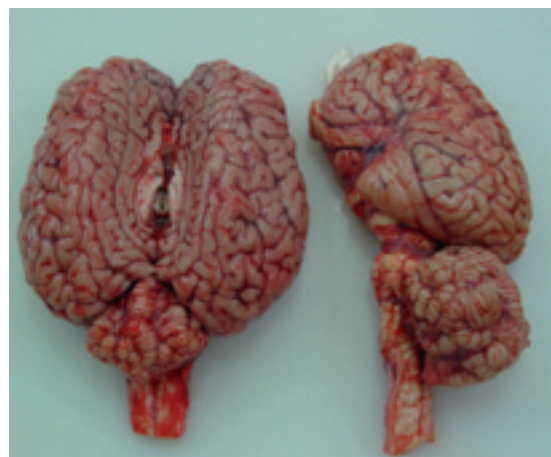

Fig. 3 The cerebellum of the CA foal at the left side compared to a normal one at the right side (half of a cerebellum)

The post mortem diagnosis was cerebellar abiotrophy with dorsoventral flattening of the medulla oblongata and pituitary gland with atrophy of the pars distalis, thereby confirming the MRI findings.

Discussion

To our knowledge this is the first report describing the MRI findings in a foal with CA, allowing ante mortem confirmation of the clinical diagnosis. CA is a rare disease, but the most common cerebellar abnormality in horses. The disease is mostly diagnosed based on the history, the typical clinical signs, and the exclusion of other differential diagnoses (Palmer et al. 1973, Scarratt 2004) The foal described in this report presented at the age of 3 months with the typical history and clinical signs including hypermetric gait, intention tremor, and hyperresponsiveness. Therefore the clinical suspicion of CA was very high. The weakness and trembling previously observed once on the foal's first days of life were attributed to the effects of sedation and/or adverse reactions to the administered plasma and therefore were not predictive for the later diagnosis of CA.

Laboratory diagnosis of CA is not possible and hematologic and serum biochemistry findings, as in the present case, are usually normal. Although radiography and cerebral spinal fluid cytology provide insights into some causes of neurologic disease, they do not allow diagnosing CA. Evaluation of CSF usually is unremarkable although some foals may have high CSF protein concentrations and increased CSF CK activity, consistent with active neurodegeneration and demyelinating processes at the time of CSF collection (DeBowes et al. 1987, Furr und Tyler 1990, Turner-Beatty 1985). Nonetheless, CSF analysis may be indicated in foals which are suspected to suffer from CA to exclude other diseases. Although a genetic background is suspected, there is currently no DNA test for identifying CA in horses, but extensive research is performed in the United States as well as in Europe.

MRI evaluation of the equine head is a feasible and valuable neurodiagnostic modality for the assessment of equine neurologic disease (Ferrell et al. 2002). As compared to computed tomography (CT) (Sogaro-Robinson et al. 2009), MRI provides high anatomic detail and exceptional soft tissue contrast of the central nervous system (CNS). Therefore MRI has an enormous potential in the assessment of suspected brain and spinal cord disorders in the horse. In light of these facts, MRI has an enormous diagnostic potency in the assessment of suspected brain or brain stem disorders in horses. A variety of lesions, including masses, deformities, traumas and other disorders can be identified or confirmed and a definitive ante mortem diagnosis may be possible. Even though knowledge and expertise for the use of MRI in neurodiagnostics in horses is limited, clinicians should be aware of this diagnostic tool and take it into consideration for evaluation and/or confirmation of neurologic diseases, for example as a supportive implement of an ante mortem diagnosis of CA. CA has been described in dogs (van der Merwe und Lane 2001) and sporadically in cats. Only few reports exist demonstrating MRI as a diagnostic tool in this disease entity (van der Merwe und Lane 2001).

To the knowledge of the authors, reports about MRI in foals with CA do not exist up to date. Hence, this report is the first one describing the MRI findings in a foal with confirmed CA. The MRI findings clearly demonstrated distinct enlarged spaces of cerebrospinal fluid in the caudal fossa, a significantly thinned marrow bed and an overall moderate to severe decreased volume of the cerebellar cortex and allowed ante mortem confirmation of CA in this foal and exclusion of other structural cerebellar diseases.

Final confirmation of the diagnosis was achieved by the typical macroscopic findings at necropsy, supported by the distinctive results of the histological examination. We therefore conclude that MRI is a useful diagnostic tool for ante mortem diagnosis of CA and exclusion of other cerebellar disorders in foals. To date a confirmed diagnosis of CA has only been possible through post mortem evaluation of the cerebellum. In contrast to previously reported cases of CA, this foal's diagnose was supported by MRI findings.

Acknowledgments

The authors thank Dr. Nina Waldern and Dr. Thea Ryhner for providing compassionate care for the hospitalized foal and Dr. Colin Schwarzwald for revising the manuscript.

Hersteller's address

° Hitachi AIRIS II, Hitachi Medical Systems, Düsseldorf, Germany

References

Adams R. und Mayhew I. G. (1985) Neurologic diseases. *Vet. Clin. North Am. Equine Pract.* 1, 209-234
 Adams R. und Mayhew I. G. (1984) Neurological examination of newborn foals. *Equine Vet. J.* 16, 306-312
 Baird J. D. und Mackenzie C. D. (1974) Cerebellar hypoplasia and degeneration in part-Arab horses. *Aust. Vet. J.* 50, 25-28

Blanco A., Moyano R., Vivo J., Flores-Acuna R., Molina A., Blanco C. und Monterde J. G. (2006) Purkinje cell apoptosis in arabian horses with cerebellar abiotrophy. *J. Vet. Med. A Physiol. Pathol. Clin. Med.* 53, 286-287
 De Lahunta A. (1983) *Veterinary Neuroanatomy and Clinical Neurology.* W.B. Saunders Co., Philadelphia, PA
 DeBowes R. M., Leipold H. W. und Turner-Beatty M. (1987) Cerebellar abiotrophy. *Vet. Clin. North Am. Equine Pract.* 3, 345-52
 Dungworth D. L. und Fowler M. E. (1966) Cerebellar hypoplasia and degeneration in a foal. *Cornell Vet.* 56, 17-24
 Ferrell E. A., Gavin P. R., Tucker R. L., Sellon D. C. und Hines M. T. (2002) Magnetic resonance for evaluation of neurologic disease in 12 horses. *Vet. Radiol. Ultrasound* 43, 510-516
 Fox J., Duncan R., Friday P., Klein B. und Scarratt W. (2000) Cerebello-olivary and lateral (accessory) cuneate degeneration in a juvenile American Miniature horse. *Vet. Pathol.* 37, 271-274
 Furr M. O. (2008a) *Specific Disease Syndromes.* Equine Neurology. Furr M. O., Reed, S. M., Wiley & Sons Ltd Distribution Centre Bognor Regis, 250-252
 Furr M. O. und Reed S. M. (2008b) *Neurologic Examination.* Equine Neurology. Furr M.O., Reed, S.M., Wiley & Sons Ltd Distribution Centre Bognor Regis, 65-76
 Furr M. O. und Tyler R. D. (1990) Cerebrospinal fluid creatine kinase activity in horses with central nervous system disease: 69 cases (1984-1989). *J. Am. Vet. Med. Assoc.* 197, 245-248
 Gerber H. (1995) Cerebelläre Abiotrophie bei Vollblutaraber-Fohlen. *Pferdeheilkunde* 11, 423-443
 Hartley W. J., Kuberski T., LeGonidec G. und Daynes P. (1982) The pathology of Gomen disease: a cerebellar disorder of horses in New Caledonia. *Vet. Pathol.* 19, 399-405
 Klockgether T. und Evert B. (1998) Genes involved in hereditary ataxias. *Trends Neurosci.* 21, 413-418
 LeGonidec G., Kuberski T., Daynes P. und Hartley W. J. (1981) A neurologic disease of horses in New Caledonia. *Aust. Vet. J.* 57, 194-195
 MacKay R. J. (2004) Brain injury after head trauma: pathophysiology, diagnosis, and treatment. *Vet. Clin. North Am. Equine Pract.* 20, 199-216
 Mayhew I. G. (1988) Neurological and neuropathological observations on the equine neonate. *Equine Vet. J. Suppl* 28-33
 Mayhew I. J. (1989) Neurologic evaluation. *Large Animal Neurology.* Mayhew I. G., Lea & Febinger Philadelphia, PA, 15-47
 Palmer A. C., Blakemore W. F., Cook W. R., Platt H. und Whitwell K. E. (1973) Cerebellar hypoplasia and degeneration in the young Arab horse: clinical and neuropathological features. *Vet. Rec.* 93, 62-66
 Reed S. M. (1998) Neurologic examination. *Equine Internal Medicine.* Reed S.M., Bailey, W.M., W.B. Saunders Co. Philadelphia, PA, 427-434
 Scarratt W. K. (2004) Cerebellar disease and disease characterized by dysmetria or tremors. *Vet Clin North Am Food Anim Pract* 20, 275-286, vi
 Sogaro-Robinson C., Lacombe V. A., Reed S. M. und Balkrishnan R. (2009) Factors predictive of abnormal results for computed tomography of the head in horses affected by neurologic disorders: 57 cases (2001-2007). *J. Am. Vet. Med. Assoc.* 235, 176-183
 Turner-Beatty M. T., Leipold H. W. und Cash W. (1985) Cerebellar disease in the horse. *Proceedings of the 21st annual convention of the American Association of Equine Practitioners,*
 van der Merwe L. L. und Lane E. (2001) Diagnosis of cerebellar cortical degeneration in a Scottish terrier using magnetic resonance imaging. *J. Small Anim. Pract.* 42, 409-412

Dr. med. vet. Meret Wehrli Eser, Dipl. ECEIM, FVH für Pferde
 Departement für Pferde
 Vetsuisse-Fakultät Zürich
 Winterthurerstrasse 260
 8057 Zürich
 Schweiz
 mwehrli@vetclinics.uzh.ch