



**University of
Zurich**^{UZH}

**Zurich Open Repository and
Archive**

University of Zurich
University Library
Strickhofstrasse 39
CH-8057 Zurich
www.zora.uzh.ch

Year: 2011

A simple and flexible concept for computer-navigated surgery of the mandible

Lübbbers, H T ; Obwegeser, J A ; Matthews, F ; Eyrich, G ; Grätz, K W ; Kruse, A

Abstract: Computer navigation is a common tool in the daily routine of craniomaxillofacial surgery, particularly for the mid-face region, but experience in mandible application is still limited. **Materials and methods** Three cases are presented with navigation of the mandible: two cases of removal of a wisdom tooth fragment and one case of resection of an ameloblastoma. **Results** The described method is simple and time-saving. In all three patients the surgical technique was easy to perform. No typical complications followed, like damage of the lingual nerve or a hematoma of the mouth floor, which can appear when the surgeon intensely looks for a tooth fragment. **Conclusions** Computer navigation of the mandible is a promising tool, in particular for removal of foreign bodies, tooth fragments, and cystic or tumor lesion with clear margins. Advantages are 3D presentation of the lesion, evaluation of nerve location, and possible preoperative evaluation of graft size. Further applications could be orthognathic surgery, including distraction planning, bony tumor surgery, cyst removal, and planning for bony reconstructions.

DOI: <https://doi.org/10.1016/j.joms.2010.01.009>

Posted at the Zurich Open Repository and Archive, University of Zurich

ZORA URL: <https://doi.org/10.5167/uzh-45417>

Journal Article

Accepted Version

Originally published at:

Lübbbers, H T; Obwegeser, J A; Matthews, F; Eyrich, G; Grätz, K W; Kruse, A (2011). A simple and flexible concept for computer-navigated surgery of the mandible. *Journal of Oral and Maxillofacial Surgery*, 69(3):924-930.

DOI: <https://doi.org/10.1016/j.joms.2010.01.009>

Manuscript Number: JOMS-D-09-00911

Title: A simple and flexible concept for computer-navigated surgery of the mandible

Article Type: Technical Note

Keywords: Computer-assisted surgery; navigation surgery; mandible; splint; registration; surgical planning

Corresponding Author: Dr. Dr. Heinz-Theo Lübbers, M.D., D.M.D.

Corresponding Author's Institution: UniversitätsSpital Zürich

First Author: Heinz-Theo Lübbers, M.D., D.M.D.

Order of Authors: Heinz-Theo Lübbers, M.D., D.M.D.; Joachim A Obwegeser, M.D., D.M.D.; Felix Matthews, M.D.; Gerold Eyrich, M.D., D.M.D.; Klaus W Grätz, Prof., M.D., D.M.D.; Astrid Kruse, M.D., D.M.D.

Abstract: Background

Computer navigation is a common tool in the daily routine of craniomaxillofacial surgery, particularly for the mid-face region, but experience in mandible application is still limited.

Materials and methods

Three cases are presented with navigation of the mandible: two cases of removal of a wisdom tooth fragment and one case of resection of an ameloblastoma.

Results

The described method is simple and time-saving. In all three patients the surgical technique was easy to perform. No typical complications followed, like damage of the lingual nerve or a hematoma of the mouth floor, which can appear when the surgeon intensely looks for a tooth fragment.

Conclusions

Computer navigation of the mandible is a promising tool, in particular for removal of foreign bodies, tooth fragments, and cystic or tumor lesion with clear margins. Advantages are 3D presentation of the lesion, evaluation of nerve location, and possible preoperative evaluation of graft size. Further applications could be orthognathic surgery, including distraction planning, bony tumor surgery, cyst removal, and planning for bony reconstructions.

Suggested Reviewers:

Journal of Oral and Maxillofacial Surgery
Editor-in-Chief

University Hospital Zurich
Clinic for Cranio-, Maxillofacial and Oral Surgery
Heinz-Theo Lübbers
Frauenklinikstr. 24
CH-8091 Zurich
Switzerland

September 23, 2009

Article submission: “A simple and flexible concept for computer-navigated surgery of the mandible.”

Dear Sir or Madam.

Attached please find our paper, *A simple and flexible concept for computer-navigated surgery of the mandible*, which we are submitting to your journal to be considered for publication.

We think our article is particularly suited to the Journal of Oral and Maxillofacial Surgery because computer navigation is more and more common in the world of maxillofacial surgeons and your journal focussed on this issue before. So we can expect your readers to be interested in the topic.

We would be grateful if you would consider the attached paper for publication. Nevertheless to say, our paper has not been submitted for publication elsewhere. We would be pleased to provide any further information your request.

Kind regards,
Heinz-Theo

Lübbers

PS:

Please be aware that we exclude the following literature. Photos in the articles suggest that the same surgery is shown. We therefore were not able to objectively judge the total of patients treated by the group of authors

1. Wittwer G, Adeyemo WL, Schicho K et al.: Navigated flapless transmucosal implant placement in the mandible: a pilot study in 20 patients. *Int J Oral Maxillofac Implants* 2007;22:801
2. Wittwer G, Adeyemo WL, Schicho K et al.: Computer-guided flapless transmucosal implant placement in the mandible: a new combination of two innovative techniques. *Oral Surg Oral Med Oral Pathol Oral Radiol Endod* 2006;101:718
3. Wittwer G, Adeyemo WL, Wagner A, Enislidis G: Computer-guided flapless placement and immediate loading of four conical screw-type implants in the edentulous mandible. *Clin Oral Implants Res* 2007;18:534

A simple and flexible concept for computer-navigated surgery of the mandible.

Heinz-Theo Lübbers M.D. D.M.D.^{1, 2)}, Joachim A. Obwegeser M.D. D.M.D.¹⁾, Felix Matthews M.D.²⁾, Gerold Eyrich, M.D., D.M.D.³⁾, Klaus Wilhelm Grätz Prof. M.D. D.M.D.¹⁾, Astrid Kruse M.D. D.M.D.¹⁾

- 1) Clinic for Cranio-, Maxillofacial and Oral Surgery, University Hospital of Zurich, Frauenklinikstrasse 24, CH-8091 Zurich, Switzerland. (Head: K.W. Grätz, Prof. M.D. D.M.D.)
- 2) Surgical Planning Lab, Harvard Medical School, Brigham and Women's Hospital, 75 Francis Street, Boston, MA 02115 USA. (Head: R. Kikinis, Prof. M.D.)
- 3) Gerold Eyrich, Private Practice, Oberdorfstrasse, CH - 8853 Lachen Switzerland

Keywords:

Computer-assisted surgery; navigation surgery; mandible; splint; registration; surgical planning

Corresponding author:

Heinz-Theo Lübbers

Clinic for Cranio-Maxillofacial Surgery

University Hospital Zurich

Frauenklinikstrasse 24, CH-8091 Zurich, Switzerland

Phone: +41 (44) 634 34 21

FAX: +41 (44) 634 43 23

E-Mail: t.luebbers@gmail.com

A simple and flexible concept for computer-navigated surgery of the mandible

ABSTRACT

Background

Computer navigation is a common tool in the daily routine of craniomaxillofacial surgery, particularly for the mid-face region, but experience in mandible application is still limited.

Materials and methods

Three cases are presented with navigation of the mandible: two cases of removal of a wisdom tooth fragment and one case of resection of an ameloblastoma.

Results

The described method is simple and time-saving. In all three patients the surgical technique was easy to perform. No typical complications followed, like damage of the lingual nerve or a hematoma of the mouth floor, which can appear when the surgeon intensely looks for a tooth fragment.

Conclusions

Computer navigation of the mandible is a promising tool, in particular for removal of foreign bodies, tooth fragments, and cystic or tumor lesion with clear margins. Advantages are 3D presentation of the lesion, evaluation of nerve location, and possible preoperative evaluation of graft size. Further applications could be orthognathic surgery, including distraction planning, bony tumor surgery, cyst removal, and planning for bony reconstructions.

Keywords

Computer-navigated surgery; maxillofacial surgery; craniofacial surgery, cone beam computer tomography

INTRODUCTION

Computer navigation plays an increasingly important role in modern cranio-maxillofacial surgery. Baseline data is derived mostly from computer tomography (CT) and, nowadays, more and more from cone beam computer tomography (CBCT). [1]

Most of the appliances and studies focus on the mid-face region, especially the orbit with its complex anatomy. Even the fronto-orbital and skull region is addressed. For the lower jaw most authors work with navigation via prefabricated drill guides or templates. [2, 3] Insecurity, however, still surrounds navigation of the mandible, and the literature deems the situation for navigation in the mandibular area as unsatisfactory, [4] partly because of lack of experience. To date, very few appliances for dynamic navigation of the lower jaw region are described, mostly in the context of dental implantology. An overview is given in Table 1. This lack is, of course, due to the mobility of the lower jaw, on the one hand, and the lack of space for positioning a dynamic reference frame (DRF), on the other hand. [5]

For navigation of the lower the literature describes three techniques as feasible:

- 1) maxillomandibular fixation, which immobilizes the mandible;
- 2) positioning the mandible in another defined position against the maxilla via occlusion or special templates; [5-11]
- 3) the mounting of a DRF to the mandible. [6, 10, 12]

Modern navigation systems have multiple options for referencing patient anatomy and obtained datasets, mainly from laser surface scanning of the skin or point-to-point registration via anatomical landmarks or fiducials. These fiducials are either glued to the skin, anchored in the bone, or mounted onto a dental splint in the upper jaw. The aim of the study was to evaluate an easy and simple method of navigation in the lower jaw.

METHOD AND PATIENTS

In a first session, impressions of the upper and lower jaw were taken, and for each jaw a splint was designed in the laboratory. Titanium screws were mounted on the vestibular side of the splint to serve as fiducials for the registration process.

In a second session, the splints were checked for stable position on the dentition and, with the patient's cooperation, a position of the lower jaw was defined that allowed maximum surgical access for the planned procedure and still kept enough of the mouth opening for slipping the splints in and out. In this position, the splints were temporarily fixated with the help of a prefabricated acrylic triangle that was glued in between. The splints were removed in one piece, and the interconnection was finalized chair side to achieve maximum stability along with minimum interference with the surgical procedure. (Figure 1) Then the splint, now one piece, was repositioned and the 3d dataset acquired either by CT (Siemens Somatom Sensation 16, Siemens AG, Erlangen, Germany) or CBCT (KaVo 3D eXam, KaVo Dental AG, Brugg, Switzerland).

Surgical planning was performed with iPlan CMF 2.6 (Brainlab AG, Heimstetten, Germany), following the standards for computer navigated procedures of data conversion by orientating the dataset, marking the fiducials, and finally—in the presented cases—marking the foreign bodies, the tumor, and its planned resection margins, respectively.

A third session prior to surgery was necessary only if the patient wanted to see the detailed planning before undergoing surgery. One of the patients voted for this option and had 3 instead of 2 preoperative consultations.

Right before surgery the data of the pre-surgical plan was imported into the VectorVision² navigation system (Brainlab AG, Heimstetten, Germany). Then the base of the DRF was mounted to a hair-covered area of the skull, and after that

disinfection and coverage of the patient were performed. A small incision was made right above the base of the DRF, and the DRF itself fixed under sterile conditions.

The registration process was performed immediately before navigation was used for the first time during the single procedures. Accuracy checks were performed against the fiducials and additional anatomical landmarks right after registration and before any following period of navigation, regardless of whether the splint had been removed and repositioned in between or not.

Patient 1

A 22-year-old female patient was referred to our clinic right after an attempt to remove the lower right wisdom tooth. During the procedure a root fragment was dislocated through the lingual cortical plate and could not be located again. A CT revealed the fragment to be in the mouth floor lingual and below the level of the extraction alveole. (Figure 2)

The initial decision was to leave the fragment in place and to place the patient on an antibiotic regime for one week to prevent infection. After an uneventful 3 months, scar formation and a stable position of the fragment was assumed. A splint, as shown in figure 1, was designed and a preoperative dataset acquired by CT. The fragment was identified and marked in the navigation system's planning software, and the patient had surgery under general anesthesia.

For the surgery an intraoral approach was used in the crestal region. After the mucoperiosteal flap was lifted, the fragment could be felt with the navigation system's pointer in under 1 minute; and in another 10 minutes, it was within a clamp. (Figure 3) Visualization was not possible due to the lingual bulge of the mandible in the molar and retromolar region. However, the fragment could be removed within a few more minutes after blunt dissection from the surrounding tissues.

After extensive rinsing the wound was closed primarily. Postoperative recovery was uneventful.

Patient 2

A 20-year-old female patient was referred to our clinic two weeks after an attempt had been made to remove the lower right wisdom tooth. During the procedure a root fragment was dislocated through the lingual cortical plate. At that time the patient was immediately transferred to an oral surgeon, who approached the fragment through an intraoral approach on the lingual side of the mandible. Because he could neither visualize nor feel the fragment, removal was impossible for him. Initial CBCT at our clinic revealed the fragment to be in the mouth floor close to the extraction site, next to and a little below the lingual bulge of the mandible. (Figure 4)

A decision was made against an antibiotic regime due to the delayed presentation. After an uneventful 3 months, scar formation and a stable position of the fragment was assumed. A splint, as shown in figure 1, was designed and a preoperative dataset acquired by CBCT. The fragment was identified and marked in the navigation system's planning software, and the patient had surgery under general anesthesia.

During the surgery an intraoral approach was used in the crestal region, and after the mucoperiosteal flap was lifted, the fragment could be felt immediately with the navigation system's pointer and grabbed with a clamp. Visualization was possible in this case because the position was more medial than below the lingual bulge of the mandible. The fragment (Figure 5) could be removed within some minutes after blunt dissection from the surrounding tissues.

After extensive rinsing, the wound was closed primarily. Postoperative recovery was uneventful.

Patient 3

A 26-year-old male patient was referred to our clinic with a diagnosis of an unicystic ameloblastoma of the left mandible. Prior to consultation, zystostomie and biopsy was performed by an oral surgeon, followed by an 8-month period of open treatment with only a little bone recovery. The initial orthopantomography is shown in figure 6. After discussing the therapeutic options, a decision was made for resection and secondary reconstruction. A bi-occlusal splint was designed to position the mandible against the maxilla. Fiducials were included, and a CT was performed. The dataset served also for pre-surgical planning of the computer-assisted surgery, as well as for fabrication of a selected laser sintering (SLS) model of the patient. A reconstruction plate was pre-bent at the SLS model (Figure 7), and the tumor was marked inside the planning tool of the navigation system, along with an additional resection margin. Surgery was carried out through an intraoral approach, and the lower alveolar nerve was preserved. Figure 8 shows a navigated check of the resection margin against the surgical plan. The postoperative phase was uneventful. The necessary reconstruction was performed in two steps: first, calvaria full-thickness graft augmentation and, second, implantation. Patient experienced full rehabilitation about one year after primary surgery.

RESULTS

The production of the splints was simple, and no splint had to be redone. Fixation in the mouth with the help of the preformed acrylic triangles was fast and stable until final interconnection was performed chair side.

Registration against the fiducials was unproblematic and accurate. The systems log files revealed a precision of 0.271mm for patient 1, 0.243mm for patient 2, and 0.333mm for the first registration in patient 3, with 0.397mm for a re-registration performed about 1h later after a suspected movement of the DRF.

All surgical interventions were uneventful in matters of computer navigation. The splint was removed and repositioned without any problems or major time loss. No significant loss of accuracy was observed during subsequent episodes of navigation or the frequent checks against anatomical landmarks or any of the fiducials.

The surgical goals were achieved in all three cases, and the postoperative healing was uneventful as was the general recovery of the patients. None of the patients mentioned that the region of DRF-fixation to the skull was a problem.

DISCUSSION

The first two patients represent a classical foreign body situation as described in the literature due to various reasons. [13-17]

Surgery on the first patient was based on a CT dataset, which is a common technique and known to be accurate for navigation purposes. [18, 19] Clinically, in this patient with no possible visualization of the fragment, the navigation allowed a significantly reduced morbidity. Without navigation it would have been necessary to reduce the lingual bulge of the mandible to achieve a better overview. This might have led to more bleeding and a reduced view, adding more difficulties to the situation. It is certain that postoperative swelling and discomfort would have been more serious. Potapov et al. showed a significant improvement in the quality of life if new physical trauma can be limited in an already physically and emotionally traumatized patient. [20] The case is consistent with those that other authors have reported concerning the success of navigation in removal of foreign bodies from the midface region. [1, 4, 17]

Surgery on the second patient was based on a CBCT dataset. A number of studies shows that the accuracy of CBCT is comparable to that of CT; therefore, the use of CBCT is recommended, due to its significantly reduced radiation dose, whenever CBCT can provide the necessary clinical information. [1, 19, 21, 22] Our

experience strongly supports this recommendation. No difficulties or inaccuracies occurred in work with the CBCT dataset. Contrary to other systems [1], with the KaVo 3D eXam an adjustable field of view of up to 23x17cm poses almost no limitations on the type of maxillofacial surgery procedure.

A dynamic reference frame mounted to the mandible must not be removed unless the surgeon is willing to re-register before any new navigation episode. Additionally, any remounting of a dynamic reference results in at least one new screw hole in the mandible.

Concerning the procedure in the third patient, some authors advocate taking intraoperative x-rays of the bony section in order to evaluate the bony margins. With navigation, this time-consuming procedure can be avoided. Another point to take into consideration is the possibility of having a three-dimensional view of the lesion, and furthermore, a presentation of the nerve distance is possible. To sum up, the present case demonstrates that navigation of the mandible can be used in all larger tumor/cystic lesions with clear margins for preoperative and intraoperative planning. In a further step the size and form of a bone graft could be more easily measured before surgery.

The described method is simple and easy. Any problems with the surgical view or instrument access can immediately be resolved by removing the splint. Further navigation is possible right after repositioning of the splint. Instead of the described technique of Hoffmann et al. [8], the chair-side fixation significantly reduces the laboratory work and can provide a more optimal position of the lower jaw for patients' and surgeons' needs.

The immobilization of the mandible reduces soft tissue changes, especially in the region close to the mandible, its ascending ramus, and the masticatory muscles. This allows navigation not only of the bony structures, but also in the soft tissues

close to the bone, as shown in the two cases above that concerned removal of foreign bodies from the mouth floor lingual to the wisdom tooth's area.

Furthermore this technique reduces complications because, particularly in the mouth floor, the lingual nerve could be easily injured during the search for tooth fragments.

Registration through a maxillary splint is known to be accurate up to the area of the orbital floor, but not at the fronto-orbital region or the skull. [18] The wider polygon of fiducials should theoretically provide a higher degree of accuracy for the registration process and, therefore, the area of accurate navigation should be bigger. This, of course, needs to be verified with further studies.

Further applications could be orthognathic surgery, including distraction planning, bony tumor surgery, cyst removal, and planning for bony reconstructions. [23]

CONCLUSIONS

The described technique allows navigation of the mandible and the soft tissues close to it. The necessary effort is not significantly greater than the one for a standard computer assisted procedure with a registration splint in the upper jaw. It therefore can expand the technology of computer navigation to the lower jaw.

ACKNOWLEDGEMENTS

The authors would like to thank the Surgical Planning Lab at the Harvard Medical School in Boston for hosting the planning phase of the study.

The authors wish to acknowledge Dr. Marius Bredell, who performed surgery on patient 3, and Jörg Achinger of Brainlab for his great support in all technical questions regarding the navigation system.

We also thank Hildegard Eschle, senior librarian of the Dental School at the University in Zurich, for helping with the literature research.

CONFLICT OF INTEREST

The authors declare that they have no conflict of interest.

Authors	Procedure	Concept	No. of patients
Schultes et al.[9]	Screw removal out of the condyle via extraoral approach	Positioning of the mandible via acrylic splint	1
Hoffmann et al.[8]	Removal of osteosynthesis material, dental implantation, laser-induced interstitial thermotherapy	Positioning of the mandible via acrylic splint	4
Watzinger et al.[10]	Distraction osteogenesis	Positioning of the mandible via acrylic splint & mounting DRF to mobile segment	2
Casap et al.[12]	Dental implantation	Mounting DRF to the mandible	1
Casap et al.[7]	Dental implantation	Mounting DRF to the mandible	1
Casap et al.[6]	Dental implantation	Mounting DRF to the mandible	2
Total			11

Table 1. Reported dynamic computer navigations in the lower jaw

Figure 1. Completed splint ready for insertion and data acquisition

Figure 2. Root fragment lingual and below level of the extraction site

Figure 3. Approaching the root segment in the mouth floor under navigation control

Figure 4. Root fragment located in cone beam computer tomography

Figure 5. Removed root fragment

Figure 6. Initial presentation of unicystic ameloblastoma of the left mandible

Figure 7. SLS model after removal of vestibular expansion of the mandibular bone and adjustment of a pre-bent reconstruction plate

Figure 8. Check of the resection margin against the pre-surgical plan. Probe on the distal cranial resection border, tumor red, additional margin green.

References

1. Eggers G, Muhling J, Hofele C: Clinical use of navigation based on cone-beam computer tomography in maxillofacial surgery. *Br J Oral Maxillofac Surg* 2009;47:450
2. Tardieu PB, Vrielinck L, Escolano E: Computer-assisted implant placement. A case report: treatment of the mandible. *Int J Oral Maxillofac Implants* 2003;18:599
3. Eufinger H, Pack M, Terheyden H, Wehmoller M: Experimental computer-assisted alloplastic sandwich augmentation of the atrophic mandible. *J Oral Maxillofac Surg* 1999;57:1436
4. Siessegger M, Mischkowski RA, Schneider BT et al.: Image guided surgical navigation for removal of foreign bodies in the head and neck. *J Craniomaxillofac Surg* 2001;29:321
5. Heiland M, Habermann CR, Schmelzle R: Indications and limitations of intraoperative navigation in maxillofacial surgery. *J Oral Maxillofac Surg* 2004;62:1059
6. Casap N, Wexler A, Eliashar R: Computerized navigation for surgery of the lower jaw: comparison of 2 navigation systems. *J Oral Maxillofac Surg* 2008;66:1467

7. Casap N, Tarazi E, Wexler A et al.: Intraoperative computerized navigation for flapless implant surgery and immediate loading in the edentulous mandible. *Int J Oral Maxillofac Implants* 2005;20:92
8. Hoffmann J, Troitzsch D, Westendorff C et al.: Temporary intermaxillary fixation using individualized acrylic splints permits image-data-based surgery of the lower jaw and oropharynx. *Laryngoscope* 2004;114:1506
9. Schultes G, Zimmermann V, Feichtinger M et al.: Removal of osteosynthesis material by minimally invasive surgery based on 3-dimensional computed tomography-guided navigation. *J Oral Maxillofac Surg* 2003;61:401
10. Watzinger F, Wanschitz F, Rasse M et al.: Computer-aided surgery in distraction osteogenesis of the maxilla and mandible. *Int J Oral Maxillofac Surg* 1999;28:171
11. Hoffmann J, Westendorff C, Gomez-Roman G, Reinert S: Accuracy of navigation-guided socket drilling before implant installation compared to the conventional free-hand method in a synthetic edentulous lower jaw model. *Clin Oral Implants Res* 2005;16:609
12. Casap N, Wexler A, Lustmann J: Image-guided navigation system for placing dental implants. *Compend Contin Educ Dent* 2004;25:783

13. Tumuluri V, Punnia-Moorthy A: Displacement of a mandibular third molar root fragment into the pterygomandibular space. *Aust Dent J* 2002;47:68
14. Koseglu BG, Gumru O, Kocaelli HA: Lower third molar displaced in the sublingual space. *Dentomaxillofac Radiol* 2002;31:393
15. Paoli JR, Dekeister C: A tooth in the orbit. *Br J Oral Maxillofac Surg* 2001;39:327
16. Mahmood S, Lello GE: Tooth in the nasopharynx. *Br J Oral Maxillofac Surg* 2002;40:448
17. Grobe A, Weber C, Schmelzle R et al.: The use of navigation (BrainLAB Vector vision(2)) and intraoperative 3D imaging system (Siemens Arcadis Orbic 3D) in the treatment of gunshot wounds of the maxillofacial region. *Oral Maxillofac Surg* 2009;13:153
18. Luebbbers HT, Messmer P, Obwegeser JA et al.: Comparison of different registration methods for surgical navigation in cranio-maxillofacial surgery. *J Craniomaxillofac Surg* 2008;36:109
19. Eggers G, Senoo H, Kane G, Muhling J: The accuracy of image guided surgery based on cone beam computer tomography image data. *Oral Surg Oral Med Oral Pathol Oral Radiol Endod* 2009;107:e41

20. Potapov AA, Yeolchiyan SA, Tcherekaev VA et al.: Removal of a cranio-orbital foreign body by a supraorbital-pterion approach. *J Craniofac Surg* 1996;7:224
21. Pohlenz P, Blessmann M, Blake F et al.: Clinical indications and perspectives for intraoperative cone-beam computed tomography in oral and maxillofacial surgery. *Oral Surg Oral Med Oral Pathol Oral Radiol Endod* 2007;103:412
22. Zizelmann C, Gellrich NC, Metzger MC et al.: Computer-assisted reconstruction of orbital floor based on cone beam tomography. *Br J Oral Maxillofac Surg* 2007;45:79
23. Kaban LB, Seldin EB, Kikinis R et al.: Clinical application of curvilinear distraction osteogenesis for correction of mandibular deformities. *J Oral Maxillofac Surg* 2009;67:996

Figure 1
[Click here to download high resolution image](#)

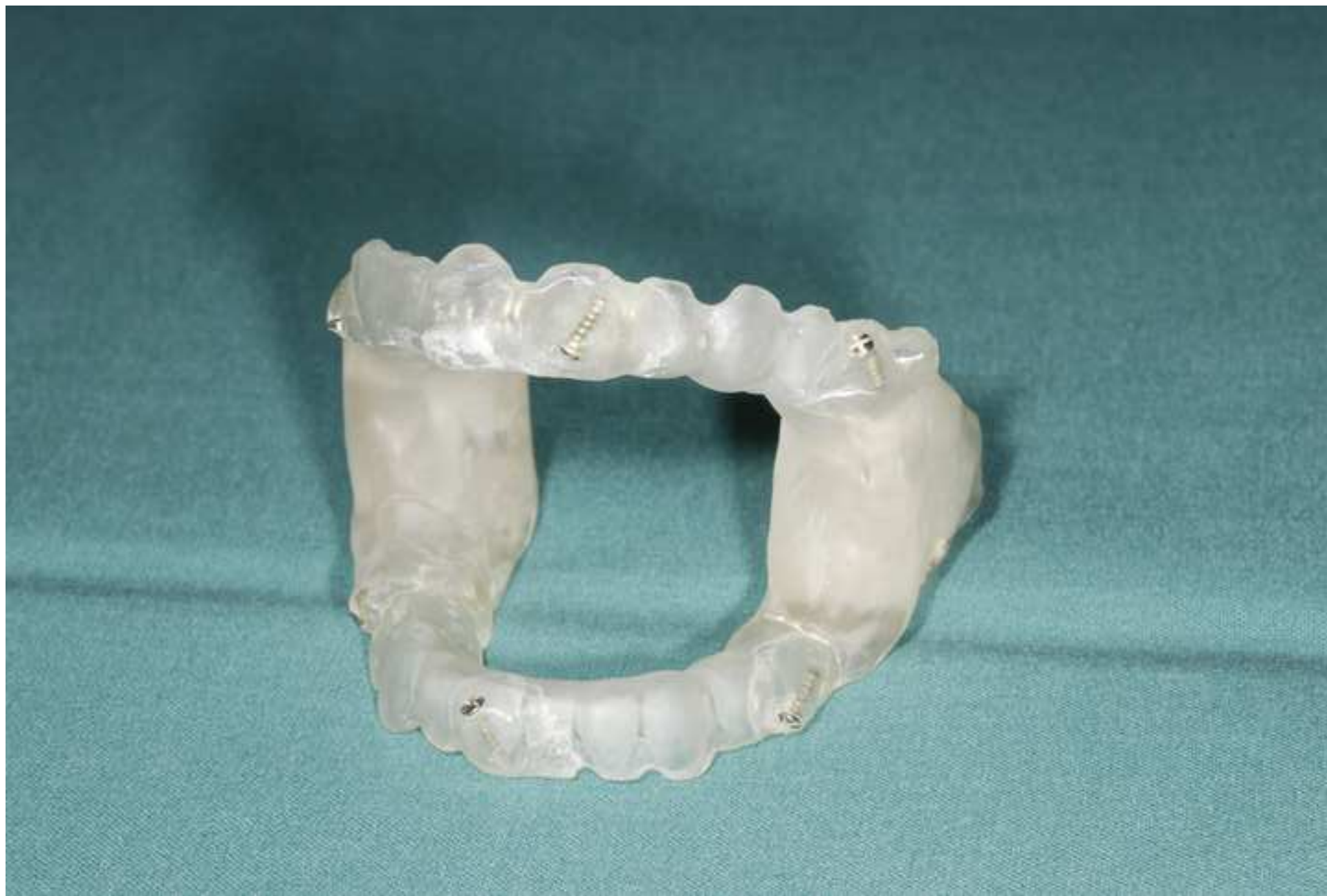

Figure 2
[Click here to download high resolution image](#)

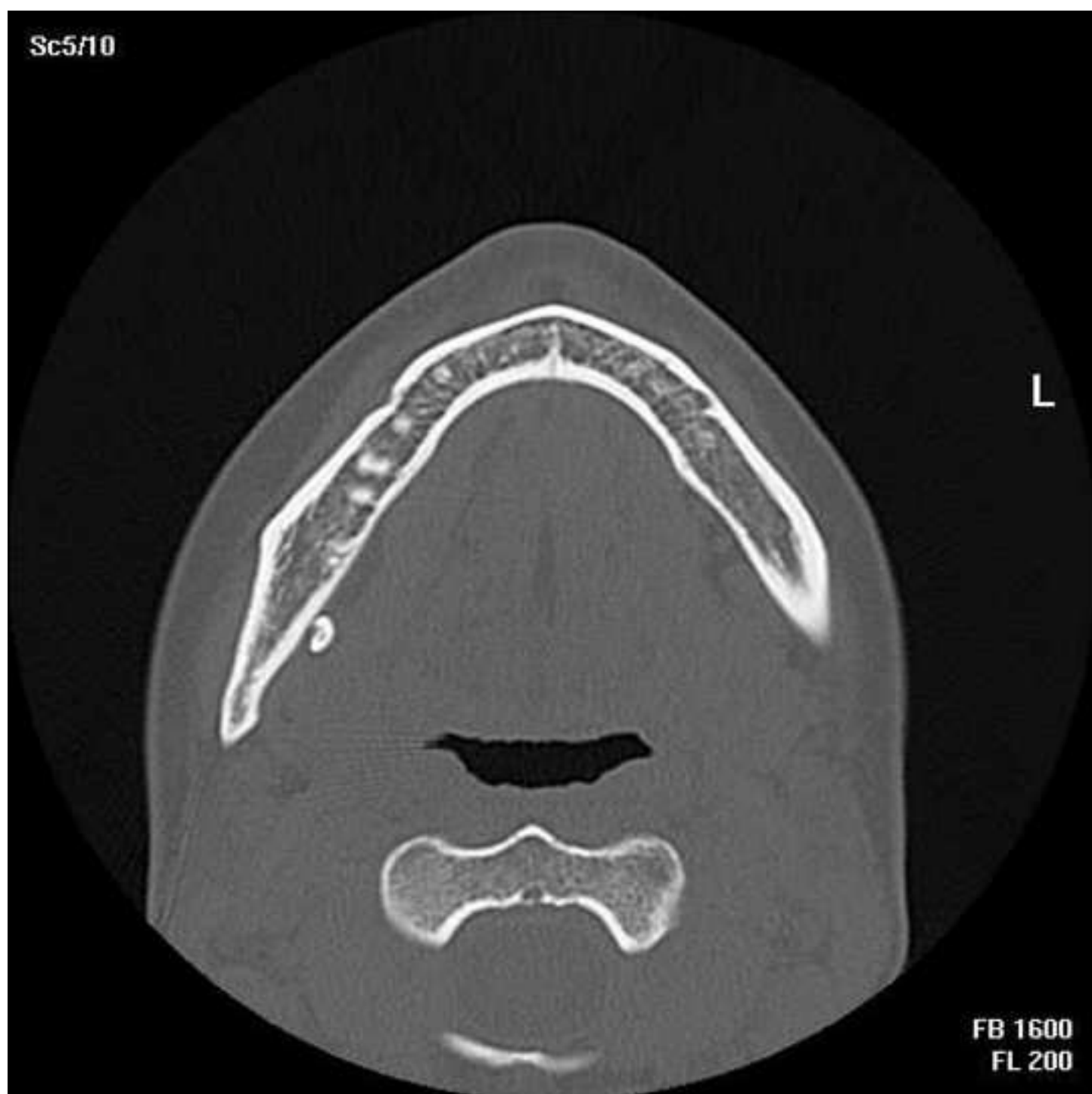

Figure 3
[Click here to download high resolution image](#)

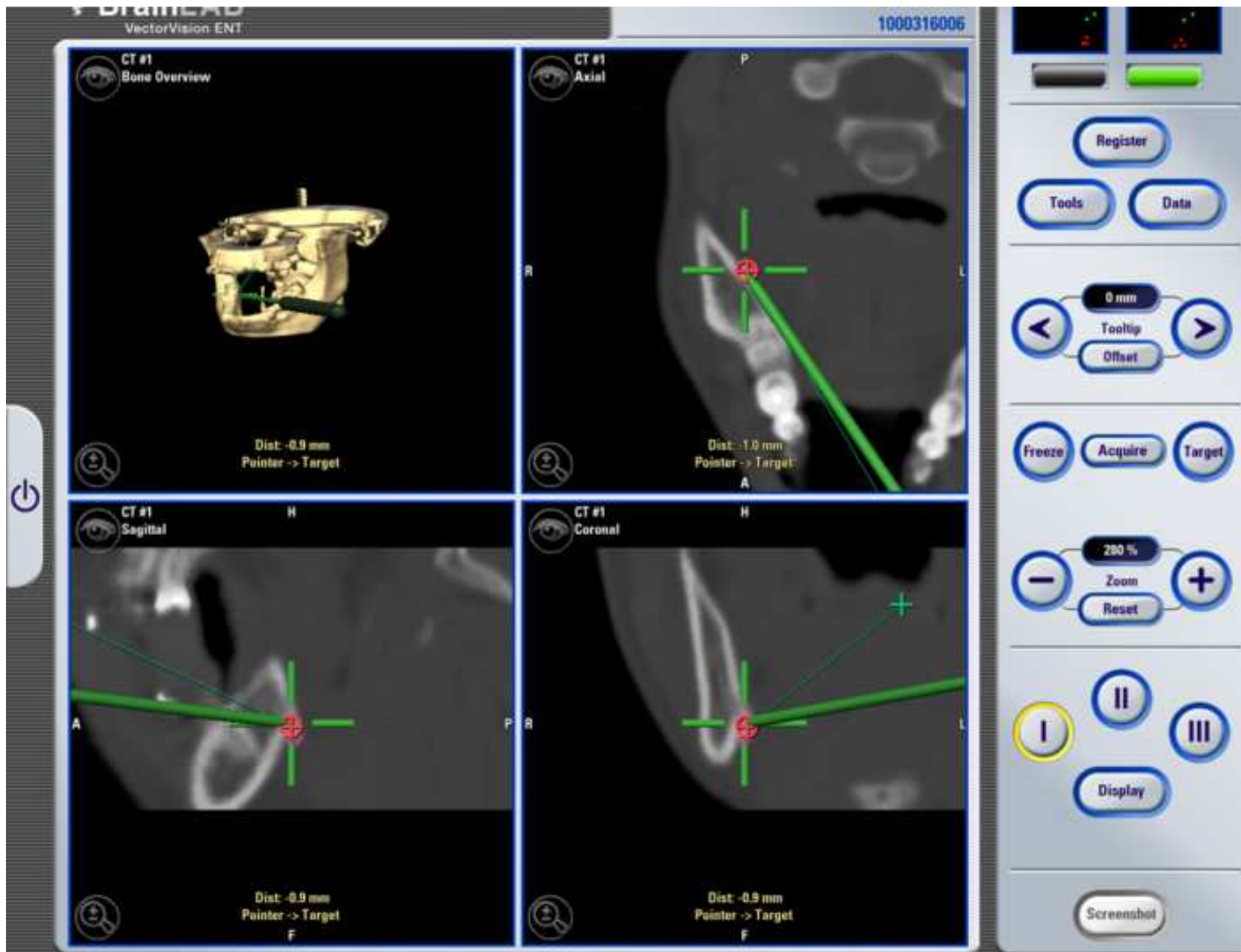


Figure 4
[Click here to download high resolution image](#)

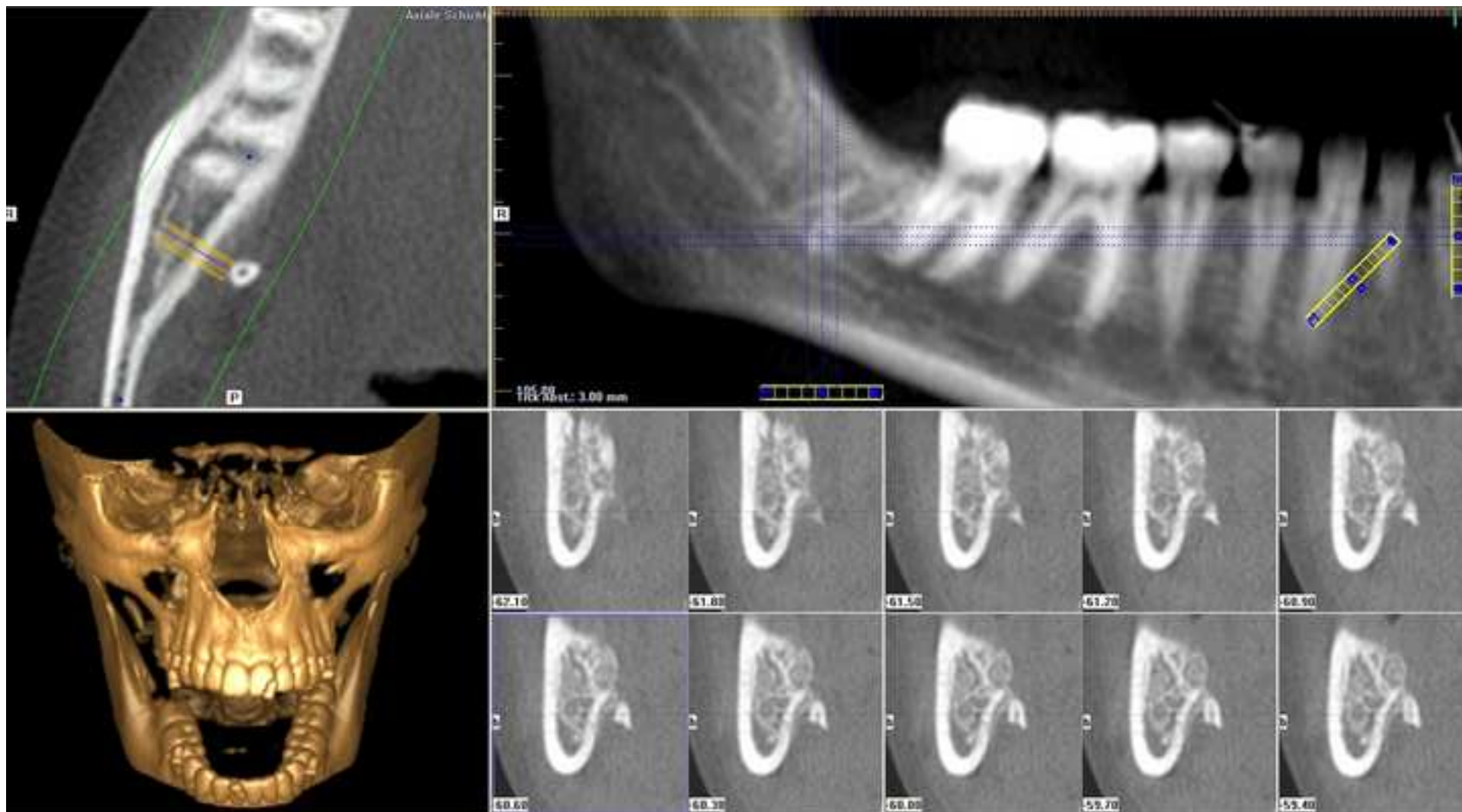


Figure 5
[Click here to download high resolution image](#)

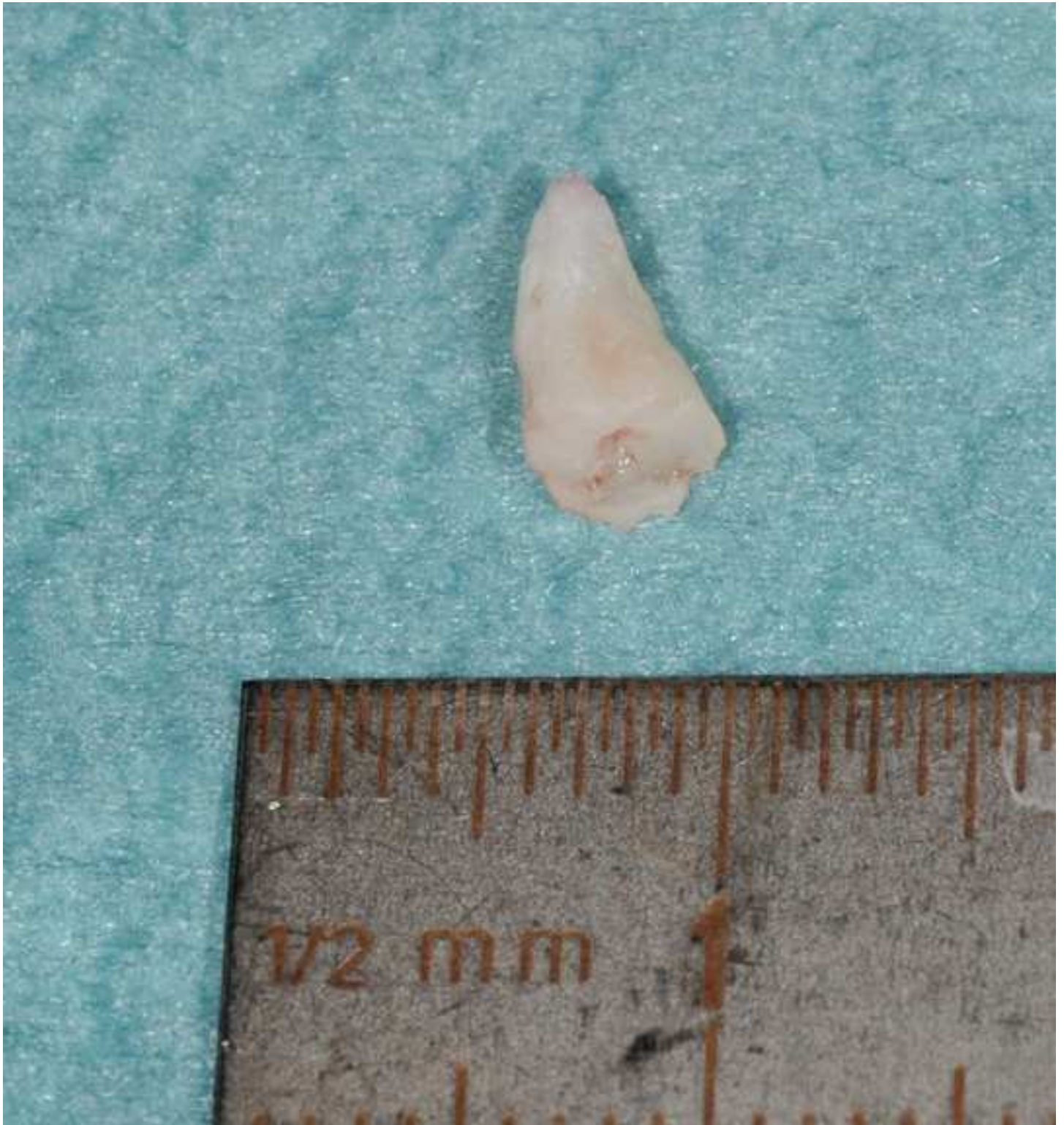

Figure 6
[Click here to download high resolution image](#)

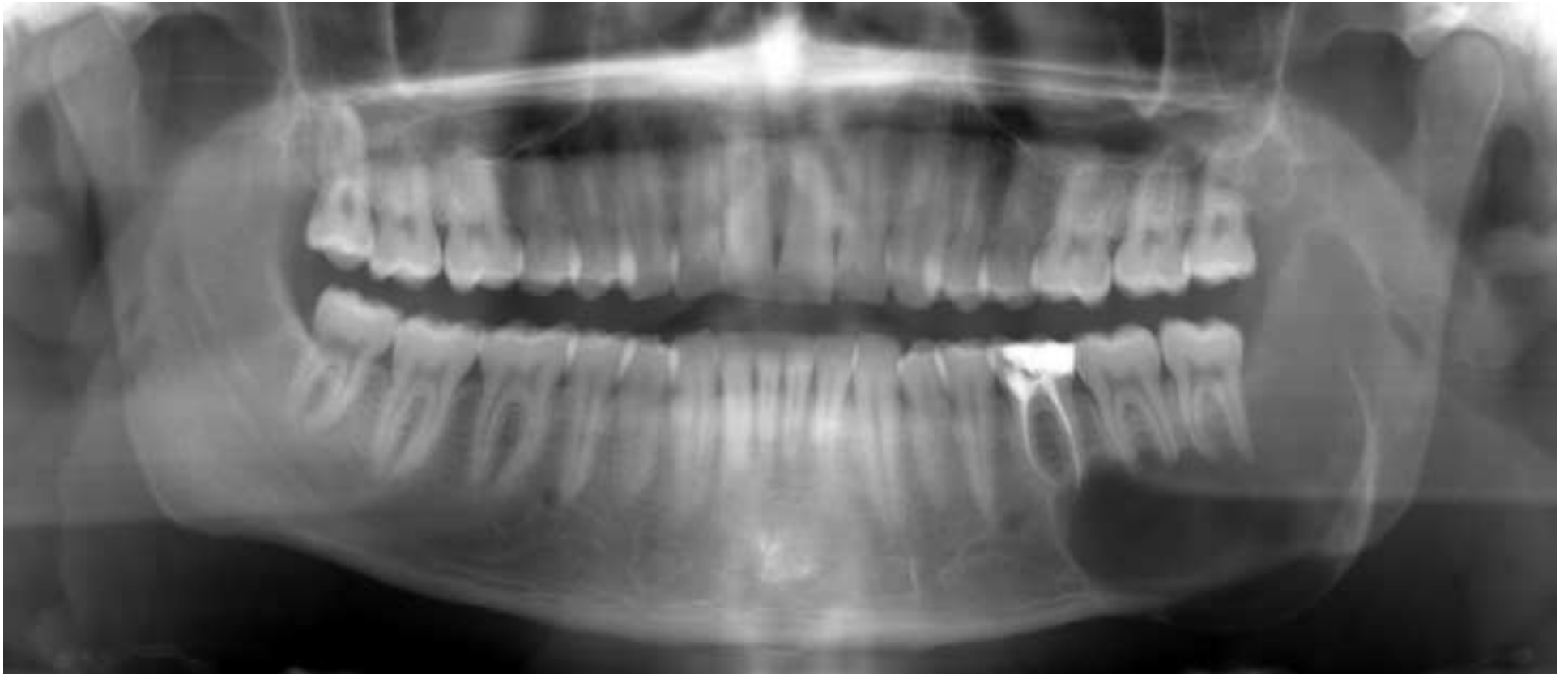
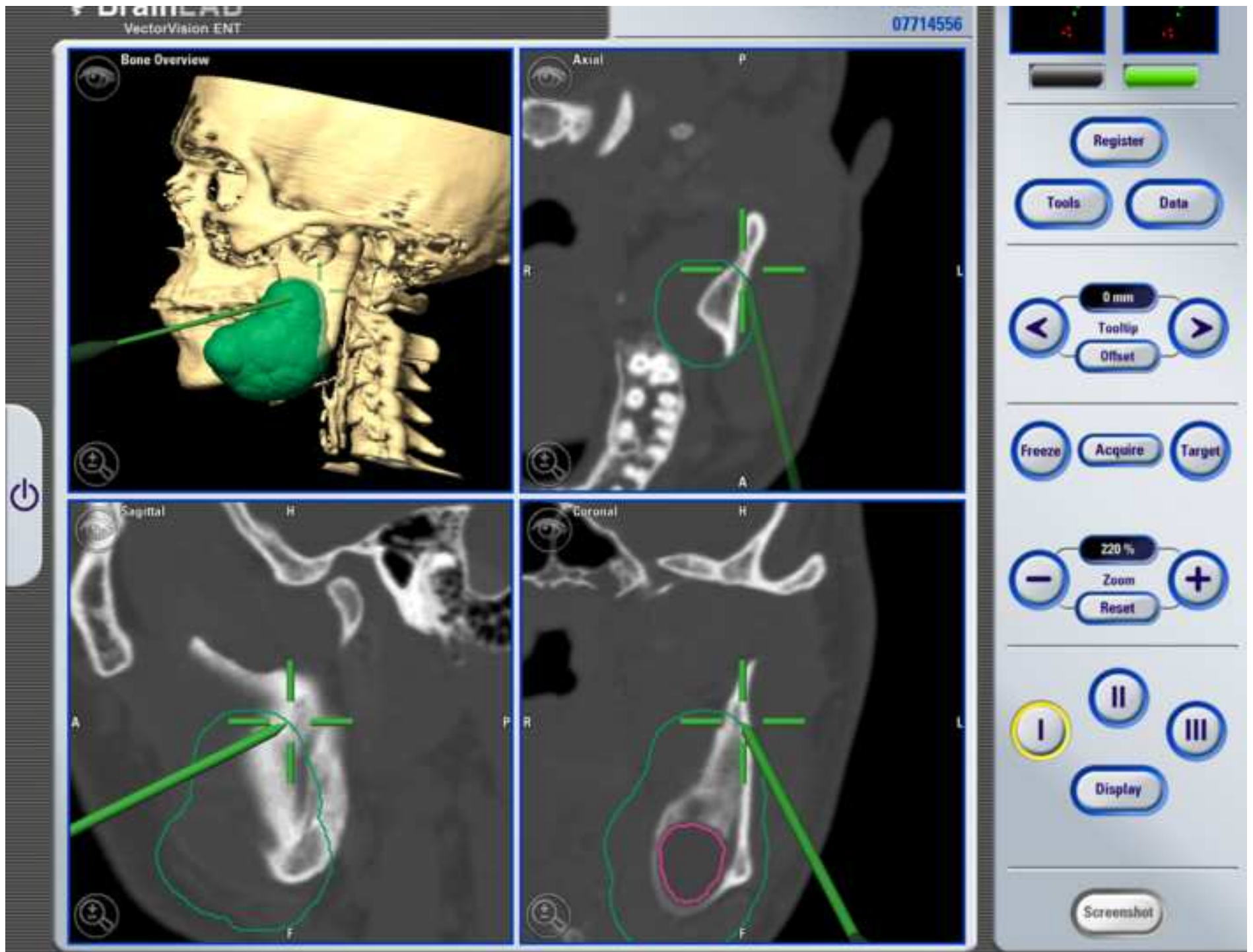


Figure 7
[Click here to download high resolution image](#)

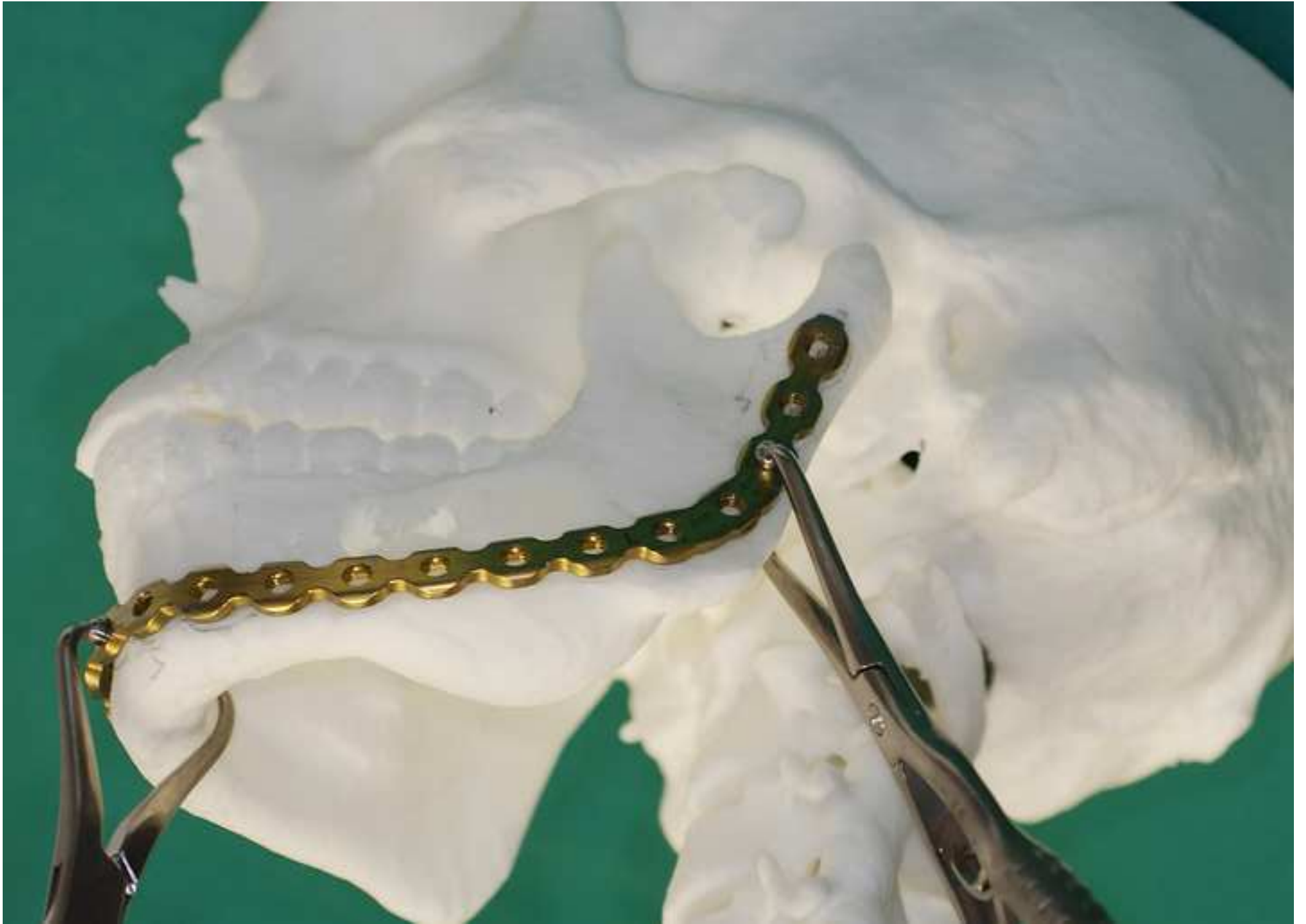

Figure 8
[Click here to download high resolution image](#)



***AAOMS Conflict of Interest Disclosure Form**

[Click here to download AAOMS Conflict of Interest Disclosure Form: AAOMS COI needed.doc](#)

Manuscript submitted prior to COI requirement
AAOMS dual commitment disclosure form needed