



**University of  
Zurich**<sup>UZH</sup>

**Zurich Open Repository and  
Archive**

University of Zurich  
University Library  
Strickhofstrasse 39  
CH-8057 Zurich  
[www.zora.uzh.ch](http://www.zora.uzh.ch)

---

Year: 2010

---

## **Cardiac arrest in a 22-year old college student**

Mutschelknauss, M ; Hellstern, M ; Keller, D I ; Sticherling, C

Posted at the Zurich Open Repository and Archive, University of Zurich

ZORA URL: <https://www.zora.uzh.ch/46673>

Journal Article

Originally published at:

Mutschelknauss, M; Hellstern, M; Keller, D I; Sticherling, C (2010). Cardiac arrest in a 22-year old college student. *Cardiovascular Medicine*, 13(7/8):245-246.

# Cardiac arrest in a 22-year-old college student

Marcus Mutschelknauss<sup>a</sup>, Mona Hellstern<sup>c</sup>, Dagmar I. Keller<sup>b</sup>, Christian Sticherling<sup>a</sup>

<sup>a</sup> Division of Cardiology, University of Basel Hospital, Basel, Switzerland

<sup>b</sup> Department of Internal Medicine, University Hospital Zurich, Zurich, Switzerland

<sup>c</sup> Department of Internal Medicine, Kantonsspital Baden, Baden, Switzerland

We present the case of a young woman who was resuscitated on an aircraft shortly before take-off. The initial ECG showed a prolonged QT-interval along with a complete atrioventricular block.

## Case presentation

A 22-year-old student was admitted to our hospital after she had been resuscitated in an airplane at the local airport. According to the emergency personnel, the patient was found unconscious shortly before take-off. Upon arrival, the paramedics initiated cardiopulmonary resuscitation. Figure 1 shows the initial rhythm documentation. The patient had no known diseases or family history of sudden cardiac death (SCD) and had never had an ECG taken before. She took no medications and used no illicit drugs.

Coronary angiography was performed, due to initially reduced left ventricular ejection fraction (LVEF 35%), and revealed normal coronary arteries. Cardiac MRI showed no signs of myocarditis.

## Questions

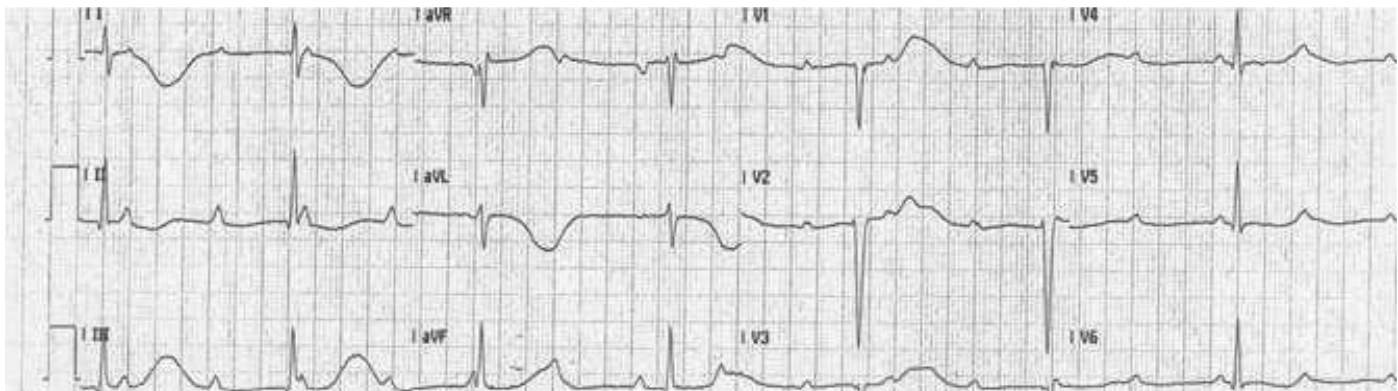
1. Which pathology is displayed on the ECG?
2. Are there any ECG clues for the cause of the cardiac arrest?

## Commentary

Firstly, a third degree atrioventricular block (AVB) with a junctional escape rhythm of 44 bpm and a sinus rate of 90 bpm was present. Secondly, the QT-interval was markedly prolonged (QT 800 ms, QTc 653 ms). In the absence of acquired causes for QT prolongation, the diagnosis was therefore congenital long QT syndrome (LQTS) along with complete AVB.

LQTS is the most common genetic arrhythmia syndrome. To date, 12 LQTS phenotypes are known, of which LQTS 1–3 are most common. The T-wave pattern with a long ST-segment interval before a late onset of the T-wave and the circumstances of the arrest during physical rest are indicative for the LQTS3 pheno-

**Figure 1**  
Initial ECG on arrival of emergency medical services (25 mm/sec).



The authors declare no conflict of interest.

Correspondence:  
Christian Sticherling  
Division of Cardiology  
University of Basel Hospital  
Petersgraben 4  
CH-4031 Basel  
Switzerland.  
SticherlingC@uhbs.ch

type [1]. The complete AVB with prolonged ventricular cycle length in association with LQTS made bradycardia induced Torsade de Pointes (TdP) tachycardia with spontaneous termination the most likely reason for syncope in our patient [2]. Coexistence of LQTS with inherited cardiac conduction system defects have been reported [3], especially in patients with mutations in the *SCN5A* gene encoding the cardiac sodium channel. In our patient, we could not find a mutation in the *SCN5A* gene. However, a genetic disorder cannot be excluded since only in up to 60% of patients with a clear LQTS phenotype, mutations in the target genes can be identified. After neurological recovery, complete recovery of the LVEF and discussion with the family, our pa-

tient opted for a dual chamber ICD for secondary prevention after presumed survived SCD. During a five-year follow-up, the complete AVB persisted and no ventricular arrhythmias occurred.

## References

- 1 Schwartz PJ, et al. Genotype-phenotype correlation in the long QT syndrome: gene-specific triggers for life-threatening arrhythmias. *Circulation*. 2001;103(1):89–95.
- 2 Viskin S, et al. Arrhythmias in the congenital long QT syndrome: how often is torsade de pointes pause dependent? *Heart*. 2000;83(6):661–6.
- 3 Wolf CM, Berul CI. Inherited conduction system abnormalities – one group of diseases, many genes. *J Cardiovasc Electrophysiol*. 2006;17(4):446–55.