



**University of
Zurich**^{UZH}

**Zurich Open Repository and
Archive**

University of Zurich
Main Library
Strickhofstrasse 39
CH-8057 Zurich
www.zora.uzh.ch

Year: 2011

Neurotoxicity related to combined treatment with lithium, antidepressants and atypical neuroleptics: a series of cases

Boeker, H <javascript:contributorCitation('Boeker, H');>; Seidl, A <javascript:contributorCitation('Seidl, A');>; Schopper, C <javascript:contributorCitation('Schopper, C');>

Posted at the Zurich Open Repository and Archive, University of Zurich

ZORA URL: <https://www.zora.uzh.ch/47690>

Journal Article

Originally published at:

Boeker, H; Seidl, A; Schopper, C (2011). Neurotoxicity related to combined treatment with lithium, antidepressants and atypical neuroleptics: a series of cases. *Schweizer Archiv für Neurologie und Psychiatrie*, 162(2):72-76.

Neurotoxicity related to combined treatment with lithium, antidepressants and atypical antipsychotics

A series of cases

Heinz Boeker, Andrea Seidl, Christian Schopper

Psychiatrische Universitätsklinik Zürich, Switzerland

Funding/potential conflict of interest: No funding. No conflict of interest.

Summary

Neurotoxicity is an important side effect of lithium therapy. It has been described both in lithium mono-therapy with normal serum levels or with toxic levels, and in combined treatment with other therapeutics, particularly with antipsychotics or antidepressants. This paper reports three different cases of patients with affective disorders who developed severe encephalopathy under combined lithium treatment. In case 1, neurotoxicity occurred under a combination of lithium and risperidone. Case 2 reports a patient who developed neurotoxic symptoms under lithium, trazodone and bupropion. Finally in case 3, neurotoxicity developed under the combination of lithium and tranylcypromine.

Neurological examination, psychopathological state and the results of EEG and serum analysis are presented. Besides the clinical state, EEG was shown to be the most important investigational method for both the acute phase and the follow-up.

Neurotoxicity caused by different combination therapies with lithium and antipsychotics or antidepressants probably results from different interaction mechanisms which are discussed in the paper. A malignant neuroleptic syndrome MNS should be considered as possible differential diagnosis in treatment with lithium and neuroleptics. Somatic co-morbidities and co-medication as well as the patient's age might influence the possibility of the occurrence of neurotoxicity during lithium therapy. Therapeutic alternatives such as mono-therapy with antidepressants or antipsychotics should be considered.

Key words: neurotoxicity; lithium combination treatment; EEG

Introduction

Lithium is still considered an essential therapy in the treatment of affective disorders, and because of its high effectiveness it is also believed to be one of the most important strategies.

Since the introduction of lithium therapy [1], a great amount of literature has been published on clinical experience with the neuropsychiatric side effects of lithium. Acute lithium toxicity has a mortality of 15%, and 10% of

survivors suffer permanent neurological sequelae that are largely unpredictable, although persons with the longest and most clinically severe intoxication are probably at a higher risk [2].

Neurotoxic side effects can occur with normal serum levels [3, 4], but typically also with lithium levels over 1.5 mmol/l in the sense of an intoxication, with the corresponding symptoms. Only a few cases showing symptoms of acute delirium with sudden onset after exposure to lithium over decades with therapeutic lithium levels in the sense of a pseudo-dementia with a reversible course have been described [5]. Intoxications resembling Creutzfeldt-Jacob disease have also been reported [6]. There has been a controversial discussion about the so-called SILENT-syndrome [7], the syndrome of irreversible lithium-induced neurotoxicity. Newman and Saunders [8] postulated in 1979, according to their own case reports, that neurotoxicity related to lithium occurs more often in clinical practice than has been published. A few articles have reported cortical myoclonus even with therapeutic doses of lithium [9]. A hypersensitivity of the CNS towards lithium therapy has often been thought to be responsible for this phenomenon [10]. In addition, neuropsychiatric complications, and above all encephalopathic syndromes (clinical, electroencephalographical), occurred more often under the combination of lithium with high-potential neuroleptic drugs (typical ones, especially haloperidol).

In the following paper, we report on three patients who showed neurotoxic encephalopathy under combined treatment with lithium and antipsychotics or antidepressants.

Case reports

Case 1: lithium and risperidone

History

A female patient aged 60 with a schizoaffective disorder (ICD-10: F25) was transferred to the University of Zurich Psychiatric Hospital, because of a psychoorganic residual state under combined treatment with lithium and risperidone.

At the age of 35 she was diagnosed with a schizoaffective disorder and had suffered several episodes in the past which had been treated with various antidepressants and neuroleptics.

A prophylactic treatment with lithium had always been tolerated without complications for a period of more than

Correspondence:
Andrea Seidl, med. pract.
Psychiatrische Universitätsklinik Zürich
Lenggstrasse 31
Postfach 1931
CH-8032 Zürich
Switzerland
andrea.seidl@web.de

two decades. As far as we knew, she did not suffer from any somatic disorders.

Follow-up

Due to paranoid fears, various neuroleptics had been given. Severe side effects occurred such as akathisia under olanzapine and haloperidol. Finally, risperidone was introduced and increased to 6 mg/d in six days while she was still treated with lithium. There were no other co-mediations after haloperidol and olanzapine had been stopped. Lithium levels were not measured at this time of the treatment. Under this medication, hypomimia, hypersalivation and ataxia were observed. Within two weeks, rigor in all extremities became manifest and febrile temperatures were recorded. Blood samples showed an elevation of CK levels (953 U/l; normal range <145 U/l) and low sodium levels. Risperidone and lithium were stopped. The patient showed an acute neuropsychiatric state with severe cognitive deficits and a severe akinetic extrapyramidal syndrome.

The clinical state gradually began to improve after withdrawal of the psychopharmaceuticals. CK levels normalised within three weeks after stopping lithium and risperidone, but severe neuropsychological deficits (lack of attention, concentration, memory and especially logical-abstract thinking) persisted.

Neurophysiology

An EEG investigation in the acute state showed a severe change in basic activity which can usually be seen in the case of a diffuse encephalopathy. Follow-up EEGs showed a relatively frequent paroxysmal change of pattern with Frontal Intermittent Rhythmic Delta Activity (FIRDA), briefly preceded by fast activity with a fronto-precentral maximum and later on a change in the characteristics of the 1/s sharp-slow-waves. This pointed to severe disturbances of the vigilance-controlling thalamo-retikular structures.

Finally after stopping the medication (only a low dose lorazepam was given), the EEG showed a clear improvement with only slight changes in general activity.

Further course

After four weeks, neuropsychological functions improved. Psychomotoric unrest persisted, as did difficulties in everyday tasks due to an impairment of frontal lobe functions. Depressive symptoms could be improved under medication with citalopram and lamotrigine, and psychomotoric unrest ceased under therapy with quetiapine which was tolerated without side effects.

Case 2: lithium, trazodone and bupropion

History

A 72-year-old male patient with a recurrent depressive disorder (ICD-10: F33.2) was transferred to the University of Zurich Psychiatric Hospital after an attempted suicide. He had been diagnosed 15 years previously and had a history of three depressive episodes. In the past he had been treated with various antidepressants and antipsychotics. One year before the reported event, he had started treatment with

a combination of lithium, trazodone and quetiapine. Six months previously, the patient had started treatment with a combination of DOPA and benserazide because of a tremor. Idiopathic Parkinson's Syndrome was ruled out following a neurological examination. Due to side effects (e.g., weight gain), lithium and quetiapine were stopped six weeks before admission.

Follow-up

Due to a severe depressive state, the patient was initially treated with trazodone, and subsequently lithium was re-introduced. Blood samples showed normal lithium levels (0.9 mmol/l; normal range 0.5–1.3 mmol/l) and creatinine level (119 μmol/l; normal range 50–120 μmol/l). Because of persisting depressive symptoms the antidepressant bupropion was added. After an augmentation up to 300 mg of bupropion and 300 mg of trazodone, within two weeks the patient showed a delirant syndrome with fluctuating awareness, slow and muddled thinking, visual hallucinations and ataxia. All the prescribed drugs were discontinued.

Neurophysiology

In the acute state, the EEG showed slight pathological signs with normal basic activity and a diffuse slowing in the frontal region in the form of dysrhythmical delta-insertions with a few triphasic-like configurations. These findings were compatible with a slight metabolic encephalopathy.

A second EEG five days after discontinuation of any psychotropic medication showed normal results.

Further course

Four days after the manifestation of the acute encephalopathic syndrome and after reduction and subsequent withdrawal of the medication, the symptoms normalised under therapy with lorazepam and a low dose of haloperidol.

Finally the patient received treatment with lamotrigine and fluvoxamine which was tolerated without side effects.

Case 3: lithium and tranylcypromine

History

A 71-year-old female patient with a bipolar II disorder (ICD-10: F31.8) had been treated with lithium for 19 years. The patient also suffered from thyroid insufficiency which was compensated with Eltroxin (0.1 mg). Due to a therapy-resistant depression – after combined treatment with lithium, venlafaxine and escitalopram –, a combined treatment with lithium and tranylcypromine was introduced. Under this medication, encephalopathic symptoms occurred.

Follow-up

Under 50 mg/day tranylcypromine, lack of concentration, memory deficits and disorientation occurred as well as diffuse fears, illusionary confusion and misjudgement. Furthermore, the patient had a dysfunction of balance and ataxia. There also was an episode of hypertension and the patient collapsed once. Blood samples revealed elevated lithium levels (1.0 mmol/l) considering the age of the patient

and elevated creatinine levels (up to 150 $\mu\text{mol/l}$, GFR 28.9, reflecting an already existing renal insufficiency).

Neurophysiology

An EEG investigation in the acute state showed pathological signs with slight changes in basic activity and a bi-temporal, left-side accentuated, intermittent functional disturbance compatible with an encephalopathy (fig. 1). These findings disappeared in the further course, with the exception of a slight slowing of the basic activity to 7 Hz.

Further course

As a fluctuating state of delirium with disorientation, unrest, ataxia and illusionary confusion and misjudgement persisted, lithium was stopped and tranylcypromine was phased out. Only diazepam was given briefly. In the further course, the patient was still disorientated to time and place and showed apraxia and difficulties in short-term memory.

After a period of one month, the clinical state improved. The patient was orientated, the walking difficulties normalised and no more apraxia was observed.

Finally, the depressive symptoms also improved under a combination of lamotrigine, duloxetine and trazodone and the patient could be discharged in a stable state.

Discussion

Our series of cases shows three examples of neurotoxicity under a combination of lithium with antipsychotics and antidepressants.

In the first case, a 60-year-old female patient with a schizoaffective disorder developed a severe neurotoxic encephalopathy under the combination of lithium and risperidone. Based on the clinical symptoms (rapid development of the symptoms, extra-pyramidal symptoms, high temperature, increased CK levels), a malignant neuroleptic syndrome (MNS) should also be considered in the differential diagnosis [11, 12]. MNS has also been described

in the literature under lithium mono-therapy [13]. It has to be considered that the patient mentioned by Gill et al. took an intentional overdose of about 40 g lithium. Furthermore, it is surprising that Gill et al. called this MNS despite there being no neuroleptic drug involved.

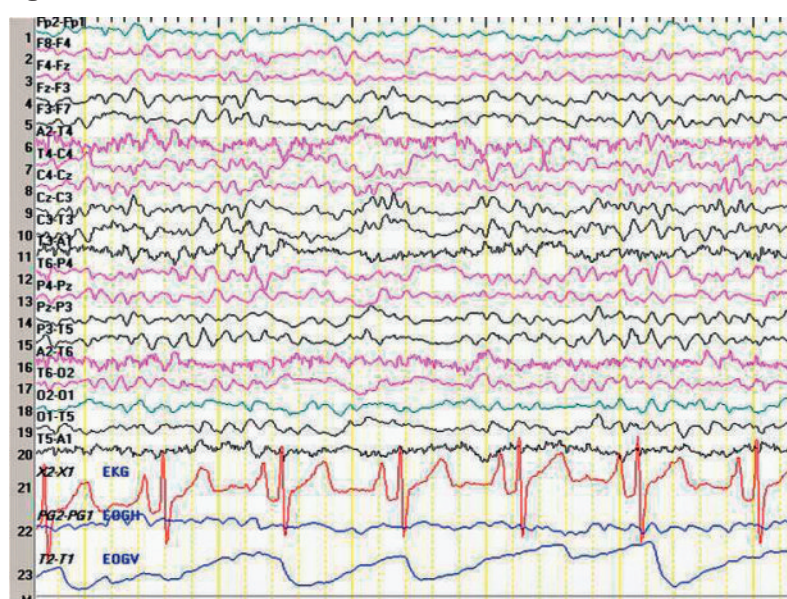
Concerning the interaction between the two drugs, lithium and risperidone, several case reports can be found in the literature [14, 15]. The male patient in Boora et al.'s paper was suffering from bipolar disorder and presented manic symptoms with psychotic features. The female patient in Boeker et al.'s report had been suffering from schizoaffective disorder for decades. All patients developed encephalopathy within a few days after starting the combination of lithium and risperidone. Similar EEG changes, specifically slow-wave EEG changes, could be seen in all cases. Whereas in Boora et al.'s paper the adverse effects were reversed upon discontinuation of lithium and risperidone, the female patient in Boeker et al. 2007 and in case 1 improved, but developed persisting neuropsychological deficits.

In regard to the interaction between the two drugs, the most important hypothesis put forward is that lithium-antipsychotic treatment causes neurotoxicity by increasing dopamine receptor blockade [14]. Both lithium and risperidone are known to modulate components of dopamine neurotransmission. Lithium inhibits pre-synaptic dopamine release. Risperidone, by blocking dopamine receptors, inhibits a different component of dopamine neurotransmission. In theory, this "two-pronged" effect causing inhibition of dopamine neurotransmission by the combination of lithium and risperidone would result in profound dopaminergic hypofunctionality, reflected for example by extrapyramidal symptoms [16]. Furthermore, it should be mentioned that risperidone is very similar to haloperidol pharmacologically and in higher dosages also clinically, and thus, compared to other atypical antipsychotics, the risk of developing neurotoxic symptoms under a combination with lithium is higher.

Concerning lithium antipsychotic combinations, in general it was found that neurotoxic syndromes may already occur with normal levels of lithium but significantly more often in combination with antipsychotics in particular [17–19]. Miller and Meninger presumed that a dose dependency of the neurotoxic symptoms exists for the antipsychotics but not for lithium levels [20].

Case 2 reported on a 72-year-old depressive male patient, who developed neurotoxic symptoms under a combination of lithium, trazodone and bupropion. Both trazodone and bupropion were given at maximal doses, and it should be noted that this has to be considered as an off-label situation, which already bears some risk *per se* without lithium. There is little experience concerning the combination of lithium and bupropion and so far not much is known about possible interaction mechanisms. Part of bupropion's action may be attributed to the inhibition of dopamine reuptake that may induce organic mental disorders in certain susceptible patients. Dose-related dopaminergic augmentation, accumulation of toxic metabolites and a predisposition to psychosis and drug interactions are suggested as possible mediating mechanisms for neurotoxic syndromes in patients with bupropion medication [21, 22].

Figure 1



In the current case, serotonergic side effects should also be considered. The combination of trazodone, inhibiting the serotonin re-uptake, with lithium, which is known to elevate the release of serotonin, might facilitate the development of a serotonin syndrome.

The resulting neurotoxic symptoms seen in case 2 could possibly be the result of an interaction between bupropion and trazodone. For example, trazodone is metabolised by cytochrome P450 to the active metabolite mCPP (m-chlorphenylpiperazine) which itself is a substrate of CYP 2D6. Bupropion is an inhibitor of CYP 2D6, which means that the level of mCPP is increased by co-medication [23]. mCPP is known to produce anxiety, derealisation and depersonalisation.

Finally, case 3 described a 71-year-old female patient with a bipolar-II disorder, who manifested neurotoxic symptoms after being given a combination of lithium and tranylcypromine. No reports on the combination and interaction between the two drugs can be found in the literature. Again dopaminergic effects could be the cause of neurotoxic symptoms as tranylcypromine influences dopamine levels which may block its breakdown.

Lithium probably also influences the dopaminergic system. On the basis of data from animal studies, it may be assumed that dopamine (DA) release in the nucleus accumbens is reduced in subjects treated chronically with lithium, and this effect is maintained for three days after withdrawal from lithium treatment [24]. Furthermore, there is some evidence that decreased dopamine release may mediate the mood-stabilising action of lithium [25]. Findings from other studies indicate that not all mood-stabilising agents, but only those which have anticonvulsant mood-stabilising properties, increase DA release in the cortex and that the effect is dependent upon 5-HT(1A) receptor stimulation [26]. Further studies suggest that lithium may exert some of its effects not by directly inhibiting enzymes, but by destabilising specific protein complexes involved in the regulation of enzyme activity [27]. Taken together, the complex molecular mechanisms of action involved in the interaction of lithium and DA are still unknown.

In general, the probability of developing signs of lithium intoxication in patients treated with lithium increases with advanced age, co-morbidity with pre-existing neurological or other general diseases, especially those associated with fever, and in combination with the use of antipsychotics, antidepressants or mood stabilisers. The serum lithium level is not necessarily a reliable indication for intoxication [4, 28]. In this paper, we also report on elderly patients (60–72 years of age) who had co-morbid somatic illnesses such as thyroid insufficiency, renal insufficiency and symptoms similar to those seen in Parkinson Disease, and took the appropriate medication. In all our three cases, lithium levels were constantly within the normal range. It must be conceded, however, that elderly patients, and particularly patients with impaired kidney function, can manifest toxic effects despite normal lithium levels.

The EEG has proven to be the most important diagnostic standard for the monitoring of neuropsychiatric effects. As the neuropsychiatric encephalopathic reactions to lithium or a combination of lithium and antipsychotics or antidepres-

sants are probably an overall cortical reaction to lithium, the EEG as a functional indicator of the whole cortical activity can offer valuable information [29]. In any case, there is a strong correlation between pathological EEG changes and neuropsychiatric encephalopathic reactions to therapy with lithium and antipsychotics or antidepressants.

The patients in all three cases showed pathological EEG patterns in the acute state which improved after stopping the medication. However, EEG examinations were only carried out after, and not before, medication was given. Typical EEG changes under lithium intoxication, which were also seen in our three cases, are slowed baseline activity, increased theta and delta waves and a tendency towards synchronisation, and sometimes even paroxysms.

Triphasic repetitive potentials may also occasionally be seen. However, it has to be stated that these changes are not specific for lithium intoxication. It should be mentioned that similar EEG changes can also be observed under intoxication with antipsychotics or antidepressants [30]. Frontal Intermittent Rhythmic Delta Activity (FIRDA), as observed in case 1, can also occur in patients with chronic, mostly ischemic structural brain lesions during acute metabolic derangement [31].

Several reports suggest a closer relationship between neurotoxic symptoms with EEG changes than with serum levels of lithium. This is of clinical interest with respect to encephalopathic reactions under therapeutic serum levels. The phenomenon of long-lasting EEG changes after discontinuation of lithium may be due to neuronal storing of lithium and persisting neurological disturbances [32].

In patients treated with lithium, EEG has the potential to differentiate between encephalopathy and non-convulsive status epilepticus, but more clearly can be used to follow up a patient's clinical course as lithium levels fall (after stopping lithium treatment) in the setting of a multifactorial encephalopathy [33].

Conclusion

Summing up, it can be concluded that while the therapeutic efficacy of lithium is invaluable, it can cause a variety of neurotoxicities, even at normal therapeutic doses or concentrations. The drug interaction effect is an important factor, especially in combination with antipsychotics, antidepressants and mood-stabilisers. Neurotoxic syndromes can occur both during an increase and reduction of antipsychotics or antidepressants under continuous lithium therapy and during additional application of lithium to an existing antipsychotic or antidepressant treatment. The mono-therapy with an atypical antipsychotic or an antidepressant represents a therapeutic alternative.

In patients developing neurotoxic symptoms under lithium therapy, further investigations should include serum levels and an EEG, which represents a simple and important investigational method. As soon as neurotoxic symptoms manifest, the psychopharmacotherapy should be stopped immediately. After the disappearance of the neurotoxic symptoms, further developments should be carefully monitored and documented and laboratory tests and

follow-up EEGs should be carried out. In addition, further neuropsychological examinations are recommended.

References

- 1 Schou M. Lithium treatment of mood disorders. Basel, Karger 2004, 6th edition.
- 2 Sheean GL. Lithium neurotoxicity. *Clin Expl Neurol.* 1991;28:112–27.
- 3 Fallgatter AJ, Strik WK. Reversible neuropsychiatrische Nebenwirkungen von Lithium bei normalen Serumspiegeln. *Nervenarzt.* 1997;68:586–90.
- 4 Bell AJ, Cole A, Eccleston D, Ferrier IN. Lithium neurotoxicity at normal therapeutic levels. *Br J Psychiat.* 1993;162:689–92.
- 5 Niethammer R, Keller A, Weisbrod M. Delirium syndrome as a side-effect of lithium in normal lithium levels. *Psychiatr Prax.* 2000;6:296–7.
- 6 Casanova B, de Entrambasaguas M, Perla C, Gomez-Siurana E, Veneto A, Burguera JA. Lithium-induced Creutzfeldt-Jakob syndrome. *Neuropharmacol.* 2000;19(4):356–9.
- 7 Adityanjee. The syndrome of irreversible lithium-effectuated neurotoxicity (SILENT). *Pharmacopsychiatry.* 1989;22(2):81–3.
- 8 Newman PK, Saunders M. Lithium neurotoxicity. *Postgrad Med J.* 1979;55:701–3.
- 9 Caviness JN, Evidente VG. Cortical myoclonus during lithium exposure. *Arch Neurol.* 2003;60(3):401–4.
- 10 Ghadirian AM, Lehmann HE. Acquired transient CNS hypersensitivity to lithium therapy. *Can J Psychiatry.* 1980;25(8):662–5.
- 11 Hasan S, Buckley P. Novel antipsychotics and the neuroleptic malignant syndrome: a review and critique. *Am J Psychiatry.* 1998;155(8):1113–6.
- 12 Bourgeois JA, Kahn DR. Neuroleptic malignant syndrome following administration of risperidone and lithium. *J Clin Psychopharmacol.* 2003;23(3):315–7.
- 13 Gill J, Singh H, Nugent K. Acute lithium intoxication and neuroleptic malignant syndrome. *Pharmacotherapy.* 2003;23(6):811–5.
- 14 Boora K, Xu J, Hyatt J. Encephalopathy with combined lithium – risperidone administration. *Acta Psychiatr Scand.* 2008;117:394–6.
- 15 Boeker H, Brandenberger M, Schopper C. Neurotoxicity related to lithium – risperidone combination treatment in a patient with schizoaffective disorder. *Psychiatr Prax.* 2007;34:38–41.
- 16 Young AH. Encephalopathy with combined lithium – risperidone administration. Invited comment. *Acta Psychiatr Scand.* 2008;117:394–6.
- 17 Emilien G, Maloteaux JM. Lithium neurotoxicity at low therapeutic doses: Hypotheses for mechanisms of action following a retrospective analysis of published reports. *Acta Neurol Belg.* 1996;96(4):281–93.
- 18 Lambrea E, Vecellio M, Wieser HG, Buddeberg C. Neurotoxische Enzephalopathie unter Neuroleptika und Lithium. *Nervenarzt.* 2005;76:756–9.
- 19 Bender S, Linka T, Wolstein J, Gehendges S, Paulus HJ, Schall U, Gastpar M. Safety and efficacy of combined clozapine-lithium pharmacotherapy. *Int J Neuropsychopharmacol.* 2004;7(1):59–63.
- 20 Miller F, Meninger J. Lithium-neuroleptic neural toxicity is dose-dependent. *J. Clin. Psychopharmacol.* 1987;7(2):89–91.
- 21 Ames D, Wirshing WC, Szuba MP. Organic mental disorders associated with bupropion in three patients. *J Clin Psychiatry.* 1992;53(2):53–5.
- 22 Dager SR, Heritch AJ. A case of bupropion – associated delirium. *J Clin Psychiatry.* 1990;51(7):307–8.
- 23 Rotzinger S, Fang J, Baker GB. Trazodone is metabolized to m-chlorophenylpiperazine by CYP3A4 from human sources. *Drug Metab Dispos.* 1998;16(6):572–5.
- 24 Ferrie LJ, Gartside SE, Martin KM, Young AH, McQuade R. Effect of chronic lithium treatment on D2/3 autoreceptor regulation of dopaminergic function in the rat. *Pharmacol Biochem Behav.* 2008;90(2):218–25.
- 25 Ferrie L, Young AH, McQuade R. Effect of lithium withdrawal on potassium-evoked dopamine release and tyrosine hydroxylase expression in the rat. *Int J Neuropsychopharmacol.* 2006;9(6):729–35.
- 26 Ichikawa J, Dai J, Meltzer HY. Lithium differs from anticonvulsant mood stabilizers in prefrontal cortical and accumbal dopamine release: role of 5-HT(1A) receptor agonism. *Brain Res.* 2005;1049(2):182–90.
- 27 Beaulieu JM, Caron MG. Looking at lithium: molecular moods and complex behaviour. *Mol Interv.* 2008;8(5):230–41.
- 28 Habermeyer B, Hess M, Kozomara-Hocke P, Mager R, Kawohl W. Lithium intoxications at normal serum levels. *Psychiatr Prax.* 2008;35(4):198–200.
- 29 Saran A, Addy O, Foliart RH, Schubert DS, Halaris A. Electroencephalographic changes and other indices of neurotoxicity with haloperidol-lithium therapy. *Neuropsychobiology.* 1989;20(3):152–7.
- 30 Koshino Y, Murata I, Murata T, Omori M, Hamada T, Miyagoshi M, Isaki K. Frontal intermittent delta activity in schizophrenic patients receiving antipsychotic drugs. *Clin Electroencephalogr.* 1993;24(1):13–8.
- 31 Korkmazalehan F, Waternberg N. Clinical and laboratory correlates of frontal intermittent rhythmic delta activity (FIRDA). *Turk J Med Sci.* 2002;32:155–8.
- 32 Gallinat J, Boetsch T, Padberg F, Hampel H, Herrmann WM, Hegerl U. Is the EEG helpful in diagnosing and monitoring lithium intoxication? A case report and review of the literature. *Pharmacopsychiatry.* 2000;33(5):169–73.
- 33 Kaplan PW, Birbeck G. Lithium – induced confusional states: non-convulsive status epilepticus or triphasic encephalopathy? *Epilepsia.* 2006;47(12):2071–4.