



**University of
Zurich**^{UZH}

**Zurich Open Repository and
Archive**

University of Zurich
University Library
Strickhofstrasse 39
CH-8057 Zurich
www.zora.uzh.ch

Year: 2011

Evidence for graft colonization with periodontal pathogens in lung transplant recipients

Irani, S ; Schmidlin, P R ; Bolivar, I ; Speich, R ; Boehler, A

Posted at the Zurich Open Repository and Archive, University of Zurich

ZORA URL: <https://doi.org/10.5167/uzh-54569>

Journal Article

Published Version

Originally published at:

Irani, S; Schmidlin, P R; Bolivar, I; Speich, R; Boehler, A (2011). Evidence for graft colonization with periodontal pathogens in lung transplant recipients. *Schweizer Monatsschrift für Zahnmedizin SMfZ*, 121(12):1144-1149.

Research · Science Forschung · Wissenschaft Recherche · Science

Publisher

Herausgeber
Editeur

Schweizerische Zahnärzte-
Gesellschaft SSO
Société Suisse
d'Odonto-Stomatologie
CH-3000 Bern 7

Editor-in-chief

Chefredaktor
Rédacteur en chef

Prof. Adrian Lussi
Klinik für Zahnerhaltung,
Präventiv- und
Kinderzahnmedizin
Freiburgstr. 7
3010 Bern

Editors

Redaktoren
Rédacteurs

Andreas Filippi, Basel
Susanne Scherrer, Genève
Patrick R. Schmidlin, Zürich

Assistant Editor

Redaktions-Assistent
Rédacteur assistant

Brigitte Zimmerli, Bern
Klaus Neuhaus, Bern

Jede im Teil «Forschung und Wissenschaft» der SMfZ eingereichte Arbeit wird von zwei bis drei zahnärztlichen Fachpersonen begutachtet. Diese genaue Begutachtung macht es möglich, dass die Publikationen einen hohen wissenschaftlichen Standard aufweisen.

Ich bedanke mich bei den unten aufgeführten Kolleginnen und Kollegen für ihre wertvolle Mitarbeit, die sie im vergangenen Jahr geleistet haben.

Adrian Lussi

N. Arweiler, Marburg (D)
T. Attin, Zürich
P. Baehni, Genève
U. Belser, Genève
M. M. Bornstein, Bern
D. Bosshardt, Bern
U. Brägger, Bern
W. Buchalla, Zürich
D. Buser, Bern
M. Chiquet, Bern
K. Dula, Bern
D. Ettl, Zürich
A. Filippi, Basel
R. Gmür, Zürich
T. Göhring, Zürich
K. W. Grätz, Zürich
B. Guggenheim, Zürich

C. Hämmerle, Zürich
N. Hardt, Luzern
E. Hedbom, Bern
E. Hellwig, Freiburg (D)
T. Imfeld, Zürich
K. Jäger, Aarburg
J.-P. Joho, Genève
C. Katsaros, Bern
I. Krejci, Genève
J. T. Lambrecht, Basel
T. Leisebach Minder, Winterthur
H. U. Luder, Zürich
C. Marinello, Basel
G. Menghini, Zürich
R. Mericske-Stern, Bern
J. Meyer, Basel
A. Mombelli, Genève

F. Müller, Genève
K. Neuhaus, Bern
S. Paul, Zürich
C. Ramseier, Bern
H. F. Sailer, Zürich
G. Salvi, Bern
U. Saxer, Forch
A. Sculean, Bern
R. Seemann, Bern
M. Schaffner, Bern
S. Scherrer, Genève
P. R. Schmidlin, Zürich
E. Schürch, Bern
M. Steiner, Zürich
J. Türp, Basel
H. van Waes, Zürich
T. von Arx, Bern

T. Waltimo, Basel
R. Weiger, Basel
M. Zehnder, Zürich
B. Zimmerli, Bern
N. U. Zitzmann, Basel

SAROSH IRANI^{1, 2}
PATRICK R. SCHMIDLIN³
IGNACIO BOLIVAR⁴
RUDOLF SPEICH²
ANNETTE BOEHLER²

¹ Clinic of Pulmonary Medicine,
Cantonal Hospital Aarau,
5000 Aarau, Switzerland

² Clinic of Pulmonary Medicine,
University Hospital,
8091 Zurich, Switzerland

³ Clinic for Preventive Dentistry,
Periodontology and Cariology,
Center for Dental Medicine,
University of Zurich,
8032 Zurich, Switzerland

⁴ Institute for Applied Immunology,
Eschenweg 6, CH-4528 Zuchwil

Correspondence

PD Dr. med. Sarosh Irani
Cantonal Hospital, Clinic of
Pulmonary Medicine
5000 Aarau
Switzerland
Tel. +41 62 838 41 41
Fax +41 62 838 44 69
E-mail: sarosh.irani@ksa.ch

Schweiz Monatsschr Zahnmed 121:
1144–1149 (2011)

Accepted for publication:
16 February 2011

Evidence for Graft Colonization with Periodontal Pathogens in Lung Transplant Recipients

A Pilot Study

Keywords: Periodontitis, allograft, bronchiolitis, DNA probes

Summary Bronchiolitis obliterans syndrome (BOS) is a major cause of late graft dysfunction in lung transplant recipients. There is increasing evidence that beside alloimmunologic injury also non-alloimmunologic inflammatory conditions may raise the risk of acute and chronic rejection. The oral cavity represents a possible reservoir for pathogenic bacteria due to its close anatomical proximity. In this pilot study, the presence of pathogenic periodontal bacteria in the oral cavity as well as in the lungs of lung transplant recipients was investigated for the first time.

Eight lung transplant recipients underwent broncho-alveolar lavage, transbronchial biopsies, and endobronchial biopsies. In addition to routinely performed examinations, pulmonary as well as plaque samples were assessed for *Aggregatibacter actinomycetemcomitans* (Aa), *Tannerella forsythia* (Tf), *Porphyromonas*

gingivalis (Pg), and *Treponema denticola* (Td) with the aid of a hybridization technique.

No or only one periodontal pathogen (solitarily Pg) was found in the gingival plaques of five of the eight patients (group A). In three patients, two or more periodontal pathogens were detectable in the gingival samples (group B). Whereas group A also had not more than one periodontal pathogen in the lungs, group B had more than one species in the lungs. In group B, all patients suffered from BOS, whereas in group A only one patient was affected.

This is the first evidence for the presence of periodontal pathogens in the lungs of lung transplant recipients. Further studies with larger cohorts are required to elucidate potential links between periodontal infection, pulmonary colonization, and rejection.

Introduction

Bronchiolitis obliterans (BO) and its clinical correlate bronchiolitis obliterans syndrome (BOS) is the major cause of late graft dysfunction in lung transplant recipients affecting up to 50–60% of patients who survive after surgery (GLANVILLE ET AL. 1987). Although BOS is thought to be mediated by an alloimmunologic injury, it is likely that non-alloimmunologic inflammatory conditions also play a role. Bacterial, viral and fungal infections may increase the risk of acute rejection (GIRGIS ET AL. 1996) and, in some centers, it has been shown that cy-

tomegalovirus infection was associated with chronic rejection (KROSHUS ET AL. 1997). However, despite high clinical suspicion, data dealing with the impact of infection as a risk factor for BOS is scarce.

Periodontitis, a local inflammation in the supporting tissues of the teeth, is thought to be the result of a disruption of the homeostatic balance between the host response and pathogenic microorganisms (HAFFAJEE ET AL. 1991). Prevalence and proportions of periodontal bacteria vary among patients with periodontitis and control subjects (VAN WINKELHOFF ET AL. 2002). *Aggregatibacter actinomycetemcomitans* (Aa), *Tannerella forsythia*

(Tf, former *Bacteroides forsythus*), *Porphyromonas gingivalis* (Pg), and *Treponema denticola* (Td) have been shown to be strongly associated with destructive periodontal infections.

The oral cavity has long been considered a potential reservoir for respiratory pathogens; both, colonization of dental plaques with respiratory pathogens (SCANNAPIECO ET AL. 1992) and lung infection by periodontal flora (MORRIS & SEWELL 1994, TAYLOR ET AL. 2000) are well known. Furthermore, chronic oral infections have been reported to be associated with systemic diseases including myocardial infarction and stroke. DNA from different periodontal pathogens has been found in atheromatous plaques of carotids (HARASZTHY ET AL. 2000). These disorders seem to be linked by the interaction between bacteria and their products and the intensity of the host inflammatory response.

To date, it is not known, whether periodontal pathogens can be found in transplanted human lungs and whether the severity of transmission is associated with clinical complications. In this pilot study we investigated the presence or absence of putative periodontopathogenic bacteria in the oral cavity as well as the lungs of 8 lung transplant recipients.

Materials and Methods

This pilot study was approved by the local ethics committee (EK 1164, 24.1.2005). All patients gave written informed consent.

In our program surveillance bronchoscopies are performed on a monthly basis during the first six months after transplantation. Indication bronchoscopies are performed whenever clinically indicated, usually due to deterioration of lung function. In the current study eight chronologically sequential lung transplant recipients who were off antibiotic treatment for at least two weeks and were scheduled for either routine surveillance bronchoscopy or clinically indicated bronchoscopy underwent broncho-alveolar lavage, transbronchial biopsies, and endobronchial biopsies. Samples were routinely sent for microbiology, differential cell counts and histology. Routine microbiological analyses for broncho-alveolar lavage samples were performed using blood agar and macconkey agar. Oral flora was defined as a typical mixed flora. Rejection of the lung was graded according to the International Society for Heart and Lung Transplantation (ISHLT) Working Formulation (YOUSEM ET AL. 1996). With this system perivascular as well as periobronchiolar lymphocyte infiltration (for acute rejection) and bronchiolar obliteration (for chronic rejection) are described in a standardized fashion. In all patients, lung function tests were performed prior to bronchoscopy. The term BOS was used in accordance with the new Working Formulation of the ISHLT (ESTENNE ET AL. 2002).

We wanted to circumvent any antibiotic treatment before the bronchoscopy was performed due to impaired bacteriological yield of the transplanted lung under antibiotic treatment. On the other hand, due to the immunosuppressive regimen immediate antibiotic prophylaxis before periodontal probing is standard care in our transplant program requiring subgingival manipulations. Hence, due to this severe status of immunosuppression of these patients, any generalized gingival manipulation was avoided as consequently as possible. Therefore, it was not possible to chart the periodontal probing pocket depths before the sampling procedures in order to choose appropriate sites. To meet these concerns, a standardized simplified and minimal-invasive sampling protocol was used and supra- and subgingival plaque was collected and only one site

was manipulated: A paper point was used to collect a combined supra- and subgingival plaque at the mesial surface of the first lower right molar (if not existing of the nearest available tooth mesially) for ten seconds and placed into a stabilizing guanidinium buffer two hours before bronchoscopy.

The endobronchial biopsy sample was obtained from the upper lobe carina, one transbronchial biopsy sample and 1 ml of broncho-alveolar lavage fluid were also transferred to guanidinium buffer. Then, hybridization was done. The probes that were used are synthetic DNA oligonucleotide probes directed against the small subunit ribosomal RNA (SSU rRNA) of four of the most pathogenic periodontic bacteria namely *Aggregatibacter actinomycetemcomitans*, *Tannerella forsythia*, *Porphyromonas gingivalis*, and *Treponema denticola* (IAI PadoTest4.5®). This test avoids amplification steps in order to facilitate exact quantification. Unlike polymerase chain reaction based approaches the hybridization technique used in this study allows a quantitative assessment of different bacterial species. Quantification is performed by using plasmid-cloned copies of the ribosomal RNA gene of each tested species. After hybridization with the probe, the samples are compared to the standard and the bacterial number is computed by assuming that 10,000 ribosomal RNA copies are equivalent to one bacterium. Furthermore, the total bacterial load of the sample was determined by a universal probe. The quantitative results of the DNA-rRNA hybridization are given as a proportion of the determined species compared to the total bacterial load.

From lung specimens, the sample with the highest number of pathogenic species detected was taken into consideration. Subjects were further evaluated depending on the number of these pathogens found in their gingival samples. Based on the latter findings, we arbitrarily defined a group A, where only one or none of the four marker bacteria was identified in the oral cavity, whereas patients were attributed to a group B, which was defined by the detection of two or more species in the oral sample.

Results

Eight bilaterally lung transplanted patients underwent fibre-optic bronchoscopy either for routine surveillance (5 patients, 63%) or for diagnostic work up (3 patients, 37%). The clinical characteristics of these patients and the results of the bacterial examination are shown in Table 1.

In five of the eight patients one or less of the four above mentioned periodontal pathogens was found in the gingival plaque (group A), the other patients had two or more of the periodontal pathogens (group B). In two of these three patients all bacteria were also detected in the transplanted lungs, whereas patients harboring only one of these periodontal bacteria in the gingival collecting area had also not more than one pathogen in the lungs.

Figure 1 shows the fraction of each of the four bacterial species (expressed as a percentage of the total bacterial load) of both groups in the gingiva and in the lungs, respectively.

In the pulmonary compartment of the three patients of group B the extent of bacterial colonization varied between broncho-alveolar lavage, endobronchial and transbronchial biopsies. In one patient, dental pathogen species were exclusively found in the transbronchial biopsy specimen. In the other two patients, the pathogens were found in three and two lung specimens, respectively.

The cytology of the broncho-alveolar lavage, the histology of the transbronchial biopsy and the sum of the dental patho-

Tab.I Clinical characteristics and periodontal pathogens

Patient number	Underlying disease	Age at TX m/f	Time since Tx (months)	Current Lung volume (FEV1% baseline)	Functional signs of chronic rejection	Bronchoscopy surveillance/ diagnostic	Rejection (biopsy grading according to ISHLT)	Microbiological findings (BAL)	Presence of periodontal pathogens at gingival sites	Presence of periodontal pathogens in allograft sites
1	PPH	51/f	7	93	no	s	A1B0	–	Pg	Tf
2	CF	34/f	46	58	no	d	A2Bx	Oral flora	–	Tf
3	Emphysema	43/m	15	75	no	d	AxBx	–	Pg	Pg
4	IPF	48/m	4	100	no	s	A0B0	–	Pg	Td
5	Emphysema	52/m	65	52	yes	d	Ax(2)Bx(0)	Staph. aureus	Pg	Td
6	Emphysema	55/m	35	81	yes	d	A0B0	–	Aa, Tf, Pg, Td	Aa, Tf, Pg (BAL, TBB, EBB)
7	Emphysema	44/m	54	74	yes	d	A2BxC	Oral flora	Aa, Tf, Pg, Td	Aa, Tf, Td (TBB)
8	Emphysema	48/f	4	85	yes	s	A1B0	Anaerobic flora	Aa, Pg, Td	Pg,Td (BAL, TBB)

PPH = primary pulmonary hypertension; CF = cystic fibrosis; IPF = idiopathic pulmonary fibrosis; FEV1 = forced expiratory lung volume in one second, ISHLT = International Society for Heart and Lung Transplantation; BAL = bronchoalveolar lavage; TBB = transbronchial biopsy; EBB = endobronchial biopsy; Aa = *Aggregatibacter actinomycetemcomitans*; Tf = *Tannerella forsythia*; Pg = *Porphyromonas gingivalis*; Td = *Treponema denticola*; x = less than five histological evaluable fragments. * persistent after treatment of acute rejection.

Tab.II Bronchoscopic and microbiological findings

	Group A (n = 5) (one or less periodontal pathogen gingival)	Group B (n = 3) (two or more periodontal pathogens gingival)
BAL		
– BAL total cell count (10 ³ /ul)	200 (200)	200 (200–300)
– BAL neutrophils (%)	2 (1–35)	12 (2–16)
– BAL lymphocytes (%)	8 (2–8)	4 (0–5)
– microbiological findings		
– oral flora	1 (20%)	1 (33%)
– others	1 (20%)	1 (33%)
TBB		
– ISHLT A0	1 (20%)	1 (33%)
– ISHLT other	4 (80%)	2 (66%)
In situ hybridization*		
– gingival	2.8 (0.6–3)	17.3 (4.3–38.5)
– pulmonary**	0.8 (0.5–1)	11.7 (5.8–22.6)

Values are number (%) for categoric items or median (lower and upper quartile) for numerical items. BAL = bronchoalveolar lavage; TBB = transbronchial biopsy; ISHLT = International Society for Heart Lung Transplantation.
* means the sum of the four determined pathogen species (Aa, Tf, Pg and Td, see text), expressed as the percentage of total bacterial load
** pulmonary sample with the highest number of pathogens was taken into consideration

gens of the two groups are shown in Table 2 (as medians with interquartile ranges,% for categoric items). By conventional culture techniques, representatives of an oral flora were found in the broncho-alveolar lavage in one patient of each group (Table 2).

One patient in group A fulfilled the clinical criteria for BOS, whereas every patient in group B at least suffered from BOS stage 0-p (Table 1).

Discussion

The risk of infection after lung transplantation is considerably higher as compared to other solid organ transplant recipients and more than 70% of infections involve the respiratory tract

(KRAMER ET AL. 1993). Whereas bacterial bronchopneumonia caused by Gram-negative species is a well described entity (SPEICH & VAN DER BIJ 2001) little is known about colonization or infection of the transplanted lung with the host's dental flora. Using DNA probes directed against SSU rRNA of selected dental pathogenic species (*Aggregatibacter actinomycetemcomitans*, *Tannerella forsythia*, *Porphyromonas gingivalis*, and *Treponema denticola*) we identified these bacteria not only in the supra- and subgingival biofilm of lung transplant recipients but also in their lungs. Since RNA's are quickly degraded once the bacteria are removed from their natural medium, these molecules are particularly suitable for detection of vital microorganisms. We have demonstrated that pathogenic gingival microflora can also be found in the transplanted lung. We feel

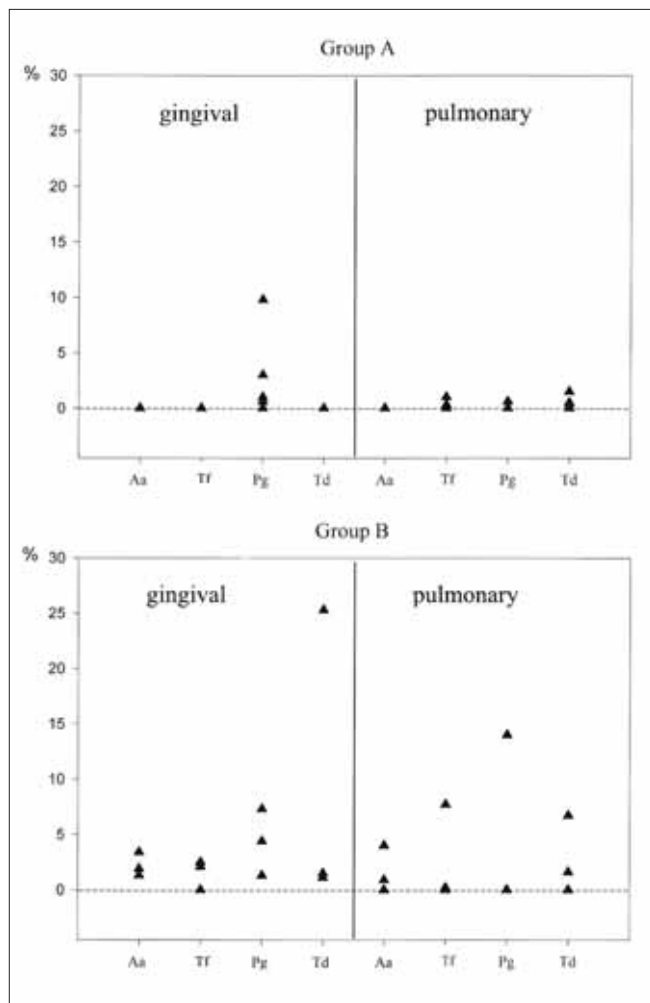


Fig. 1 Proportion of the four determined pathogen species (Aa, Tf, Pg and Td, see text) expressed as a percentage of total bacterial load from gingival (left column) and pulmonary (BAL, EBB or TBB, the specimen with the highest bacterial load was chosen; right column) specimens. Group A (defined as having one or less of the four species in the gingival biofilm) is shown in the upper panel, group B (two or more) in the lower panel.

that these findings are remarkable. With conventional culture techniques dental pathogens are often underestimated due to their anaerobic growth and not differentiated but only mentioned as “oral flora” and unappreciated as putative contaminants of bronchoalveolar lavage. In our study, only in one patient of each group were microbiological results reported as “oral flora”. In one of the three patients with lungs positive for more than one pathogen exclusively the transbronchial biopsy specimen was positive. This makes simple contamination unlikely and argues for colonization or infection. A further argument against contamination is the fact that in all but one case (Case No 2) endoscopy was performed through the nasal route. Most of all, the hybridization technique which we have used in the current study strongly argues against a simple contamination of the endoscope and other instruments.

All patients with ≥ 2 pathogens in the gingival plaque (arbitrarily referred to as group B) met the criteria for BOS (at least stage 0-p) whereas only one of five patients of group A did. Because of the small number of patients no statistical comparison could be made but an association between pulmonary colonization or infection with pathogenic gingival flora and BOS is conceivable. Primary infection with consecutive BO or

secondary colonization in a lung with preexistent BO are both possible scenarios. The latter is a well known phenomenon probably due to architectural damage and over-immunosuppression. Since periodontal disease and BO share some phenomenological aspects (i. e. inadequate inflammatory responses to different injuries and a specific individual genetic predisposition) the first hypothesis (pulmonary infection with dental pathogens leading to BO) needs further attention. Considering the significance of the clinical problem additional studies are highly warranted and as in many other fields an interdisciplinary approach seems ideal and promising.

One critical point of this study is the simplified oral detection method for bacteria. Under normal conditions, selection of the deepest pocket in each quadrant has been shown to be the most efficient method of sampling (MOMBELLI ET AL. 1991a). However, due to the severe status of immunosuppression of these patients, any additional gingival manipulation was avoided under stringent conditions as suggested by the internal clinical guidelines and the ethical protocol for safety reasons, despite a lack of evidence concerning lung transplant patients. Taking these concerns into consideration, only one site was scheduled for epi- and subgingival manipulation. In addition, given the potentially high number of samples needed to reliably detect the presence of *P. gingivalis* and other oral pathogens, the simple method of collecting supra- and subgingivally at only one specific site, presented an inferior, but adequate solution for screening the patient in a standardized manner. MOMBELLI and co-workers (1991a) found that in patients with moderate to advanced chronic periodontitis three distinct patterns of distribution and relative proportion of *P. gingivalis* were recognized. In one group of patients, the organism was not cultured. In a second group, few positive sites with low proportions of *P. gingivalis* were present. A third group of patients yielded high frequencies and proportions of *P. gingivalis*. Sampling of only one site could potentially lead to inadequate or underestimation of the bacteria found in the sample. However, it was shown that in the molar region, frequencies and mean proportions of *P. gingivalis* increased, which makes this area a potentially appropriate site (MOMBELLI ET AL. 1991b). Due to uneven and even cluster like distribution of positive samples in certain areas of the dentition, potential difficulties even remain when sampling more than one site. In this study, seven of the eight patients revealed *P. gingivalis* in the oral samples, which is a high frequency given the limitation of just one arbitrary sample site. On the other hand, one can speculate that a prevalence of ≥ 2 bacteria in a single site may argue for an increased contamination potential of the whole oral cavity and therefore a higher overall oral and gingival contamination, which may more easily spread in the body. Therefore that arbitrary allocation to a “high” (≥ 2 bacteria) and “low” colonization group may be justified and explain our preliminary, but clinically relevant findings in the lung parenchyma.

Despite this particular shortcoming of this pilot and feasibility study, the presented findings and results are the first to show that pathogenic oral bacteria can be detected in the lung parenchyma of lung transplant recipients, irrespective of the arbitrary colonization type pattern in the oral cavity.

Other limitations of this study lay in its cross sectional nature and in the small number of study patients included. Furthermore, the frequent use of antibiotics in this population hampers diagnostic approaches to a certain degree. Since antibiotic treatments are necessary so frequently in lung transplant recipients a maximum time period off antibiotics of only two weeks could be applied.

However, if these results are confirmed in larger studies they may well lead to new diagnostic and treatment strategies for better allograft survival.

Zusammenfassung

Die chronische Abstossungsreaktion, das Bronchiolitis-obliterans-Syndrom (BOS), ist ein häufiger Grund für eine späte Transplantat-Dysfunktion bei Lungen-Transplantat-Patienten. 50 bis 60% der Langzeitüberlebenden nach Lungentransplantation sind von dieser Komplikation betroffen. Das BOS stellt die hauptsächliche Todesursache dieser Patienten dar. Die Pathogenese des BOS ist noch weitgehend unverstanden. Neben alloimmunologischen Konditionen werden neuerdings in zunehmendem Masse auch nicht-alloimmunologische entzündliche Reaktionen wie bakterielle, virale oder fungale Infektionen als Risiko für eine akute oder chronische Abstossungsreaktion diskutiert. Die Mundhöhle stellt ein mögliches Reservoir für pathogene Keime wegen ihrer anatomischen Nähe zu den Atemwegen dar. Über die Anwesenheit von parodontal pathogenen Keimen in den Lungen ist wenig bekannt, insbesondere bei lungentransplantierten Patienten. Gerade in dieser Population könnten die inflammatorischen Eigenschaften dieser Keime aber potenziell grosse klinische Bedeutung haben. In dieser Pilotstudie wurde zum ersten Mal die Anwesenheit von parodontal pathogenen Keimen in Taschen sowie in den Lungen von Lungen-Transplantat-Patienten untersucht.

Acht lungentransplantierten Patienten, welche während mindestens zweier Wochen keine Antibiotika erhielten, wurden einer broncho-alveolären Lavage sowie einer trans- und endobronchialen Biopsie unterzogen. Diese Untersuchungen wurden unter leichter Sedation mittels flexibler Bronchoskopie durchgeführt. Zusätzlich zu den Routineuntersuchungen (Mikrobiologie, Differenzialzytologie beziehungsweise Histologie) wurden Lungen- und subgingivale Plaqueproben auf die Anwesenheit von *Aggregatibacter actinomycetemcomitans* (Aa), *Tannerella forsythia* (Tf), *Porphyromonas gingivalis* (Pg) und *Treponema denticola* (Td) mit einer DNA-Hybridisierungstechnik untersucht. Die subgingivalen Plaqueproben wurden mittels Papierstreifen von der mesialen Oberfläche des ersten unteren Molars maximal zwei Stunden vor der Bronchoskopie entnommen.

Keine oder ein parodontaler Markerkeim (ausschliesslich Pg) wurden im subgingivalen Sample von fünf der acht Patienten gefunden (Gruppe A). Bei den übrigen drei Patienten wurden zwei oder mehr Keime festgestellt (Gruppe B). Während bei Gruppe A in den Lungen nie mehr als einer der Keime festgestellt wurde, zeigten die Patienten in Gruppe B alle mehr als eine Spezies. Bei zwei der drei Patienten dieser Gruppe fanden sich alle der nachgewiesenen Keime der subgingivalen Probe auch in der Lunge. Mittels konventioneller Kultur konnte in der bronchoalveolären Lavage von einem Patienten jeder Gruppe orale Flora nachgewiesen werden. In Gruppe B litten alle Patienten an einem BOS. In der Gruppe A war lediglich ein Patient davon betroffen.

Diese Pilotstudie liefert zum ersten Mal Evidenz, dass parodontal pathogene Keime in den Lungen von Lungentransplantierten Patienten gefunden werden können. Weitere Studien mit grösseren Kohorten sind allerdings von Nöten, um die möglichen Zusammenhänge zwischen Parodontalerkrankungen, pulmonaler Infektion und Abstossung aufzuzeigen. Sollten sich die vorliegenden Daten in grösseren Kollektiven von lungentransplantierten Patienten bestätigen, wären die pathogenetischen Zusammenhänge zwischen der Anwesenheit den-

tal pathogener Keime und lokal pulmonaler Inflammation von grösstem Interesse. Potenziell würden sich hieraus neue, unmittelbare diagnostische und therapeutische Strategien ergeben im Kampf gegen das BOS.

Résumé

Le syndrome de la bronchiolite oblitérante (BOS) est une cause fréquente d'une dysfonction retard de la greffe chez les transplantés pulmonaires. 50 à 60% de survivants long terme après une transplantation pulmonaire sont touchés par cette complication. Le BOS est la principale cause de décès de ces patients. La pathogénie du BOS est encore mal comprise. Outre les conditions alloimmunologiques, la réaction inflammatoire non-alloimmunologique provenant d'une infection bactérienne, virale ou fongique a été récemment discutée comme facteur de risque d'une réaction de rejet aigu ou chronique. La cavité buccale représente un réservoir potentiel de bactéries pathogènes à cause de sa proximité anatomique. Peu d'informations existent sur la présence des pathogènes parodontaux dans les poumons, en particulier chez les patients greffés des poumons. C'est surtout dans cette population que les propriétés inflammatoires des ces bactéries peuvent potentiellement avoir une grande importance clinique. Cette étude-pilote analyse pour la première fois la présence de germes pathogènes parodontaux dans les poches parodontales et les poumons de patients greffés des poumons.

Huit patients transplantés des poumons, qui n'avaient pas reçu d'antibiotiques depuis au moins deux semaines, ont subi un lavage broncho-alvéolaire ainsi qu'une biopsie trans- et endobronchique. Ces examens ont été réalisés au moyen d'une bronchoscopie flexible et sous légère sédation. En plus des examens de routine (microbiologie, histologie et cytologie différentielle), des prélèvements des poumons et de plaque sous-gingivale ont été analysés pour détecter la présence des bactéries *Aggregatibacter actinomycetemcomitans* (Aa), *Tannerella forsythia* (Tf), *Porphyromonas gingivalis* (Pg), *Treponema denticola* (Td) en utilisant une technique d'hybridation de l'ADN. Les prélèvements de plaque sous-gingivale ont été pris avec des pointes de papier sur la surface mésiale de la première molaire inférieure deux heures au maximum avant la bronchoscopie.

Aucun ou seulement un marqueur de germe parodontal (exclusivement Pg) a été trouvé dans les prélèvements sous-gingivaux chez cinq des huit patients (groupe A). Pour les trois autres patients, deux ou plusieurs bactéries ont été identifiées (groupe B). Dans les prélèvements pulmonaires, jamais plus d'une espèce bactérienne n'a été trouvée pour le groupe A, tandis que pour le groupe B au moins deux espèces bactériennes étaient identifiées. Dans ce dernier groupe, toutes les bactéries sous-gingivales étaient également détectées au niveau des prélèvements pulmonaires chez deux patients sur trois. Au moyen d'une culture bactérienne conventionnelle, la flore buccale était détectée dans le lavage broncho-alvéolaire d'un patient de chaque groupe. En outre, tous les patients du groupe B souffraient d'un BOS, alors que dans le groupe A seul un patient en était atteint.

Cette étude-pilote montre pour la première fois l'évidence que des bactéries parodontales peuvent être trouvées dans les poumons des patients greffés des poumons. Des études supplémentaires avec des cohortes plus grandes sont néanmoins nécessaires pour démontrer les possibles relations entre maladies parodontales, infections pulmonaires et la réaction de rejet de la greffe pulmonaire. Si les données présentes sont confirmées au niveau d'une population plus grande de patients

transplantés des poumons alors la relation pathogénique entre la présence de germes pathogènes dentaires et l'inflammation locale pulmonaire serait du plus grand intérêt. Des nouvelles et importantes stratégies à valeur diagnostique et thérapeutique pourraient potentiellement en résulter dans la lutte contre le BOS.

References

- ESTENNE M, MAURER J R, BOEHLER A, EGAN J J, FROST A, HERTZ M, MALLORY G B, SNELL G I, YOUSEM S: Bronchiolitis obliterans syndrome 2001: an update of the diagnostic criteria. *J Heart Lung Transplant* 21: 297–310 (2002)
- GLANVILLE A R, BALDWIN J C, BURKE C M, THEODORE J, ROBIN E D: Obliterative bronchiolitis after heart-lung transplantation: apparent arrest by augmented immunosuppression. *Ann Intern Med* 107: 300–304 (1987)
- GIRGIS R E, TU I, BERRY G J, REICHENSPURNER H, VALENTINE V G, CONTE J V, TING A, JOHNSTONE I, MILLER J, ROBBINS R C, REITZ B A, THEODORE J: Risk factors for the development of obliterative bronchiolitis after lung transplantation. *J Heart Lung Transplant* 15: 1200–1208 (1996)
- HAFFAJEE A D, SOCRANSKY S S, SMITH C, DIBART S: Microbial risk indicators for periodontal attachment loss. *J Periodontol* 26: 293–296 (1991)
- HARASZTHY V I, ZAMBON J J, TREVISAN M, ZEID M, GENCO R J: Identification of periodontal pathogens in atheromatous plaques. *J Periodontol* 71: 1554–1560 (2000)
- KRAMER M R, MARSHALL S E, STARNES VA, GAMBERG P, AMITAI Z, THEODORE J: Infectious complications in heart-lung transplantation. Analysis of 200 episodes. *Arch Intern Med* 153: 2010–2016 (1993)
- KROSHUS T J, KSHETRY V R, SAVIK K, JOHN R, HERTZ M I, BOLMAN R M R: Risk factors for the development of bronchiolitis obliterans syndrome after lung transplantation. *J Thorac Cardiovasc Surg* 114: 195–202 (1997)
- MOMBELLI A, McNABB H, LANG N P: Black-pigmenting gram-negative bacteria in periodontal disease. II. Screening strategies for detection of *P. gingivalis*. *J Periodontol* 26: 308–313 (1991a).
- MOMBELLI A, McNABB H, LANG N P: Black-pigmenting gram-negative bacteria in periodontal disease. I. Topographic distribution in the human dentition. *J Periodontol* 26:301–307 (1991b)
- MORRIS J F, SEWELL D L: Necrotizing pneumonia caused by mixed infection with *Aggregatibacter actinomycetemcomitans* and *Actinomyces israelii*: case report and review. *Clin Infect Dis* 18: 450–452 (1994)
- SCANNAPIECO F A, STEWART E M, MYLOTTE J M: Colonization of dental plaque by respiratory pathogens in medical intensive care patients. *Crit Care Med* 20: 740–745 (1992)
- SPEICH R, VAN DER BIJ W: Epidemiology and management of infections after lung transplantation. *Clin Infect Dis* 33 Suppl 1: S58–65 (2001)
- TAYLOR G W, LOESCHE W J, TERPENNING M S: Impact of oral diseases on systemic health in the elderly: diabetes mellitus and aspiration pneumonia. *J Public Health Dent* 60: 313–320 (2000)
- VAN WINKELHOFF A J, LOOS B G, VAN DER REIJDEN W A, VAN DER VELDEN U: *Porphyromonas gingivalis*, *Bacteroides forsythus* and other putative periodontal pathogens in subjects with and without periodontal destruction. *J Clin Periodontol* 29: 1023–1028 (2002)
- YOUSEM S A, BERRY G J, CAGLE P T, CHAMBERLAIN D, HUSAIN A N, HRUBAN R H, MARCHEVSKY A, OHORI N P, RITTER J, STEWART S, TAZELAAR H D: Revision of the 1990 working formulation for the classification of pulmonary allograft rejection: Lung Rejection Study Group. *J Heart Lung Transplant* 15: 1–15 (1996)