



**University of  
Zurich**<sup>UZH</sup>

**Zurich Open Repository and  
Archive**

University of Zurich  
University Library  
Strickhofstrasse 39  
CH-8057 Zurich  
[www.zora.uzh.ch](http://www.zora.uzh.ch)

---

Year: 2011

---

## **Congenital glaucoma in siblings**

Cont, M ; Fontijn, J ; Michels, R ; Arlettaz, R

**Abstract:** We report on a full term female neonate delivered by cesarean section at 37 2/7 weeks of gestation. The mother, a 28-year-old G2/P2, had a history of autoimmune thrombocytopenia and diabetes mellitus type I. She also has astigmatism and the father is myopic. There is no history of consanguinity. The first child, a son, was born at term and discharged home considered to be healthy. However, the parents noticed corneal clouding, and brought their baby to the pediatrician who confirmed corneal opacities and buphthalmus. The child was referred to the ophthalmologist who diagnosed congenital glaucoma at the age of four weeks. After numerous surgical procedures and treatment with antihypertensive agents, his visual outcome at three and a half years is presently 0.25 cardiff charts in the right eye and 0.158 cardiff charts in the left eye. Because of the possibility of an inherited condition as an autosomal recessive trait, genetic analysis was recommended but declined by the parents.

Posted at the Zurich Open Repository and Archive, University of Zurich

ZORA URL: <https://doi.org/10.5167/uzh-59723>

Scientific Publication in Electronic Form

Published Version

Originally published at:

Cont, M; Fontijn, J; Michels, R; Arlettaz, R (2011). Congenital glaucoma in siblings. Luzern, CH: Swiss Society of Neonatology.

SWISS SOCIETY OF NEONATOLOGY

Congenital glaucoma  
in siblings

DECEMBER 2011



Cont M, Fontijn J, Michels R, Arlettaz-Mieth R, Clinic for Neonatology (CM, FJ, AMR), Department of Ophthalmology (MR), University Hospital Zurich

We report on a full term female neonate delivered by cesarean section at 37 2/7 weeks of gestation. The mother, a 28-year-old G2/P2, had a history of autoimmune thrombocytopenia and diabetes mellitus type I. She also has astigmatism and the father is myopic. There is no history of consanguinity. The first child, a son, was born at term and discharged home considered to be healthy. However, the parents noticed corneal clouding, and brought their baby to the pediatrician who confirmed corneal opacities and buphthalmus. The child was referred to the ophthalmologist who diagnosed congenital glaucoma at the age of four weeks. After numerous surgical procedures and treatment with antihypertensive agents, his visual outcome at three and a half years is presently 0.25 cardiff charts in the right eye and 0.158 cardiff charts in the left eye. Because of the possibility of an inherited condition as an autosomal recessive trait, genetic analysis was recommended but declined by the parents.

The current pregnancy had been uneventful. The mother had normal blood glucose levels under insulin treatment. The baby was delivered by cesarean section in general anesthesia because of maternal autoimmune thrombocytopenia. At the time of birth, the maternal platelets were 73'000/ $\mu$ l. The baby girl had a birth weight of 3560 g (P90-95), length of 50.5 cm (P50-75), and head circumference of 34.5 cm (P50-75). The Apgar scores were 3, 8, and 8 at 1, 5, and 10

minutes, respectively. Bag and mask ventilation was required during the first minute of life but otherwise the adaptation was uneventful. The baby was transferred with the mother to the postnatal ward.

Physical examination on the 1st day of life revealed bilateral corneal opacities in an otherwise healthy baby with a normal platelet count. The ophthalmologic examination the same day confirmed the diagnosis of congenital glaucoma. The intraocular pressure was elevated at 36 mmHg (normal values 8-15 mmHg). A topical beta-blocker (timolol) was started. Bilateral trabeculotomy was performed on the 4th day of life, followed by cyclophotocoagulation with destruction of the ciliary body on the 11th day and 5th week of life. As a result there was a stop in the production of aqueous fluid.

The girl is now 2 years old and has normal intraocular pressures (right eye 11 mmHg, left eye 12 mmHg). A lensectomy had been performed on the right eye because of secondary cataract. There is major myopia in the left eye (-8 diopters). Both optic nerves are minimally excavated (cup to disc ratio 0.1). The visual acuity is 0.158 in the right eye and 0.25 in the left eye (cardiff charts).

Congenital glaucoma is a very rare condition with an incidence of one in 10'000 live births (1) in western countries, with some geographic variability (2). It still remains one of the major causes of preventable blindness in childhood. Congenital glaucoma presents at birth or during early infancy. It is bilateral in 70% of cases (3).

Congenital glaucoma may occur as a primary condition or it can be associated with ocular or systemic disease (aphakia, malformations of the anterior segment of the eye such as neural crest dysgenesis, Lowe's syndrome, congenital rubella, neurofibromatosis, homocystinuria). Primary glaucoma is sporadic in most cases, 10% are familial and usually autosomal recessive. Chromosomal loci correlated with congenital glaucoma are GLC3A with the causal gene CYP1B1 and GLC3B (2) having been identified. Diminished or absent metabolism of key endogenous CYP1B1 substrates adversely affects the development of the trabecular meshwork (4).

Polygenic or multifactorial etiologies have been suggested, particularly in boys, who are affected twice as often as girls (3, 5). As in our case, the need for genetic examination is debatable, because children with congenital glaucoma can easily be diagnosed after birth by recognition of corneal signs and symptoms of glaucoma.

Primary congenital glaucoma seems to be related to dysgenesis of the trabeculum or its surrounding structures, resulting in impaired aqueous outflow and increased intraocular pressure (6). Elevated intraocular pressure in an immature eye causes corneal oedema which manifests as corneal clouding (Fig. 1) and progressive enlargement of the cornea and sclera (Fig. 2, 3), known as buphthalmos (from the Greek βούς bous (ox or cow), referring to the bulging eyes common to bovines).

Without treatment, optic disc cupping will develop, leading to progressive loss of visual fields and visual acuity (5). The most severe cases usually present in the neonatal period. Early recognition and treatment are essential, as the resulting optic disc cupping is reversible and visual prognosis good when the condition is treated early.

Corneal opacities as a sign of severe congenital glaucoma may be detected as early as on the first day of life, as in our case, but can also be difficult to detect by unexperienced physicians. Other signs of congenital glaucoma include photophobia, excessive tearing and blepharospasm (6). These signs and symptoms should lead to prompt referral to an ophthalmologist. Ophthalmologic examination reveals an elevated intraocular pressure confirming the diagnosis. Further examinations, particularly ultrasound (7) to measure the axial length of the eye, slit lamp exam, gonioscopy

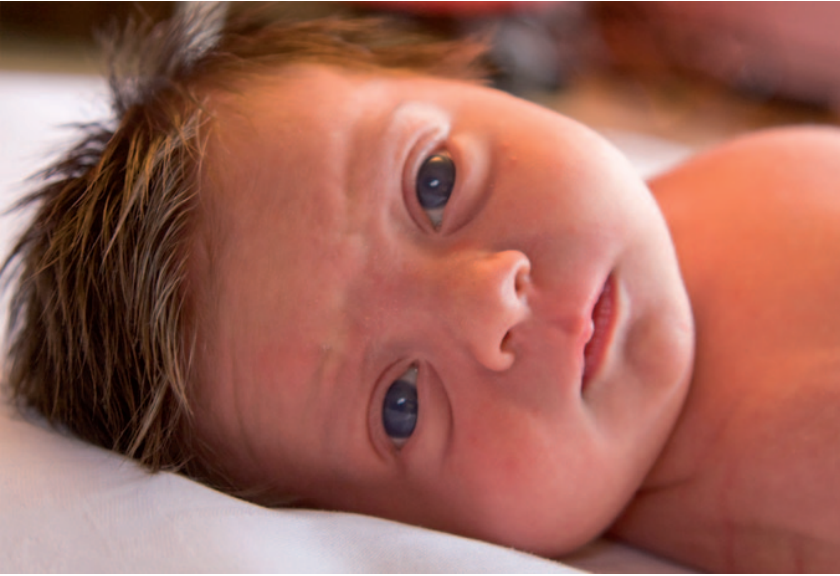

Fig. 1

*Infant with cloudy corneae.*



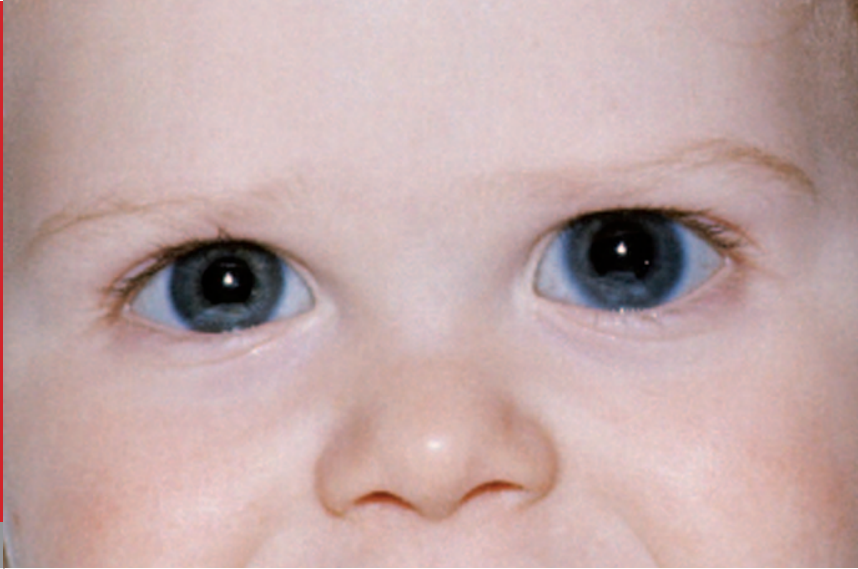

Fig. 2

*Infant with bilateral buphthalmos.*



Fig. 3

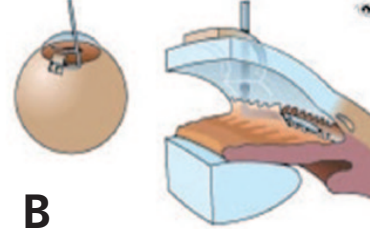
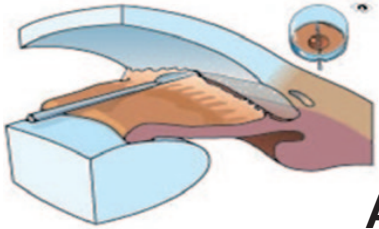
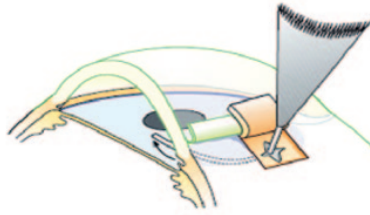
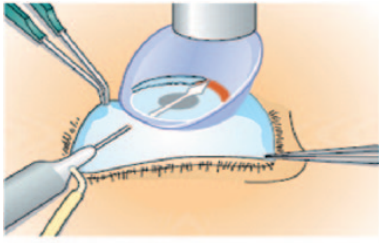
*Toddler with unilateral buphthalmos of the left eye.*

and, if possible, fundoscopy and retinoscopy, are usually performed.

The initial triad of symptoms (photophobia, excessive tearing and blepharospasm) should not be confused with the more common and benign congenital nasolacrimal duct obstruction. These infants also have excessive tearing, but in contrast to congenital glaucoma, there is no photosensitivity or corneal enlargement (5). Differential diagnoses include megalocornea (a rare, non-progressive, usually bilateral corneal enlargement), severe myopia (3) and cloudy cornea that may be caused by birth trauma (forceps injury), corneal dystrophy, interstitial keratitis, anterior chamber malformations or metabolic disease (cystinosis, mucopolysaccharidoses, acromesomelic dysplasia) (8).

Surgery is the first-line treatment for primary congenital glaucoma. The two most common procedures are goniotomy and trabeculotomy. Both of them involve microsurgical dissection of the trabecular meshwork in order to facilitate aqueous outflow. Ocular antihypertensive agents are an important adjuvant treatment, and are often used as a temporary measure (6).

The visual outcome of a child with congenital glaucoma is closely related to the time of diagnosis. Assessment of visual function in children with congenital glaucoma must be initiated at the time of diagnosis. Visual loss secondary to congenital glaucoma may occur as



**A**

**B**

Fig. 4

*Endogoniotomy (A) and trabeculotomy (B).*

a consequence of optic nerve damage, corneal opacities, cataracts and amblyopia. With early treatment only 35% of all patients will have a visual acuity better than 20/50 (9). If untreated, this condition carries an exceedingly poor visual prognosis (6).

## CONCLUSION

Clinical diagnosis of congenital glaucoma in a newborn infant can be difficult. It should be suspected in every newborn with corneal clouding. Early recognition and treatment of congenital glaucoma are of utmost importance. If the family history is positive for congenital glaucoma, an ophthalmologic examination should be performed by a specialist within the first days of life. Genetic counselling can be considered but is not mandatory, because the treatment is the same in genetically acquired and sporadic or multifactorial forms. A multidisciplinary team approach should be initiated as early as possible for monitoring and treatment of a child with congenital glaucoma. Lifelong follow-up is mandatory.

1. Teplin SU. Visual impairment in infants and young children. *Inf Young Child* 1995;8:18-51
2. Ray K, Mukhopadhyay A, Acharya M. Recent advances in molecular genetics of glaucoma. *Mol Cell Biochem* 2003; 253:223-231
3. Girgis NM, Frantz KA. A case of primary congenital glaucoma: A diagnostic dilemma. *Optometry* 2007;78:167-175
4. Vasiliou V, Gonzalez FJ. Role of CYP1B1 in glaucoma. *Annu Rev Pharmacol Toxicol* 2008;48:333-358
5. Robertson's Textbook of Neonatology, 4th edition (2005): 839-840, Elsevier Churchill Livingstone
6. Rudkin AK, Khong JJ, Casey TM. Recognising congenital glaucoma. *Med J Aust* 2009;191:466-467
7. Dureau P. Congenital glaucoma and trabeculodysgenesis. Clinical and genetic aspects. *J Fr Ophtalmol* 2006;29:198-215
8. Taylor D, Hoyt CS. *Pediatric Ophthalmology and Strabismus*. 3rd Edition (2005):275-276, Elseviers Saunders
9. Haddad MA, Sampaio MW, Oltrogge EW, et al. Visual impairment secondary to congenital glaucoma in children: visual responses, optical correction and use of low vision aids. *Clinics Sao Paulo* 2009;64:725-730

SUPPORTED BY



CONTACT

Swiss Society of Neonatology

[www.neonet.ch](http://www.neonet.ch)

[webmaster@neonet.ch](mailto:webmaster@neonet.ch)