



University of Zurich  
Zurich Open Repository and Archive

Winterthurerstr. 190  
CH-8057 Zurich  
<http://www.zora.uzh.ch>

---

*Year: 2008*

---

## Hyperthyroidism in connection with suspected diabetes mellitus in a chinchilla (*Chinchilla laniger*)

Fritsche, R; Simova-Curd, S; Clauss, M; Hatt, J M

Fritsche, R; Simova-Curd, S; Clauss, M; Hatt, J M (2008). Hyperthyroidism in connection with suspected diabetes mellitus in a chinchilla (*Chinchilla laniger*). *Veterinary Record*, 163(15):454-456.

Postprint available at:  
<http://www.zora.uzh.ch>

Posted at the Zurich Open Repository and Archive, University of Zurich.  
<http://www.zora.uzh.ch>

Originally published at:  
*Veterinary Record* 2008, 163(15):454-456.

# Hyperthyroidism in connection with suspected diabetes mellitus in a chinchilla (*Chinchilla laniger*)

## Abstract

A six year-old female chinchilla was presented because of progressive weight loss. At the clinic, a yeast-stomatitis, a severely elevated glucose level and glucosuria were found. However, 10 days of diabetes mellitus therapy with glipizide did not halt weight loss. Evaluation of T4 level indicated the presence of hyperthyroidism. Treatment of the hyperthyroid state with locally applied thiamazole ointment was successful in that the animal gained weight. This case illustrates that hyperthyroidism can also occur in chinchillas and should be included in the differential diagnoses for a diabetic state in this species, especially in the absence of ketonuria and presence of low fructosamine blood levels

1 **Case report**

2

3 **Hyperthyroidism in connection with a suspected diabetes mellitus**  
4 **in a chinchilla (*Chinchilla laniger*)**

5

6 R. Fritsche, S. Simova-Curd, M. Clauss, J.M. Hatt \*

7

8 Clinic of Zoo Animals, Exotic Pets and Wildlife, Vetsuisse Faculty, University of Zurich,

9 Winterthurerstr. 260, 8057 Zurich, Switzerland, Tel ++41 44 635 8111 Fax ++41 44 635 8901

10 Email: [jmhatt@vetclinics.uzh.ch](mailto:jmhatt@vetclinics.uzh.ch)

11

12

13 \* To whom correspondence should be addressed

---

**1 Summary**

2 A six year-old female chinchilla was presented because of progressive weight loss. At the  
3 clinic, a yeast-stomatitis, a severely elevated glucose level and glucosuria were found.  
4 However, 10 days of diabetes mellitus therapy with glipizide did not halt weight loss.  
5 Evaluation of T4 level indicated the presence of hyperthyroidism. Treatment of the  
6 hyperthyroid state with locally applied thiamazole ointment was successful in that the animal  
7 gained weight. This case illustrates that hyperthyroidism can also occur in chinchillas and  
8 should be included in the differential diagnoses for a diabetic state in this species, especially  
9 in the absence of ketonuria and presence of low fructosamine blood levels.

10

11 Key words: Chinchilla, diabetes mellitus, hyperthyroidism

12

---

## 1 **Introduction**

2 Diabetes mellitus in chinchilla's (*Chinchilla laniger*) is not a common disease. Although  
3 diabetes is a common disease in rodents (for example in guinea pigs and degus) only two  
4 cases have been reported in chinchillas (Marlow 1995, Ewringmann and Göbel 1998). In this  
5 case, diabetes mellitus was suspected and initially treated. It could not be satisfactorily  
6 managed though, and further diagnostic work revealed hyperthyroidism. Hyperthyroidism has  
7 to our knowledge never been reported in a chinchilla. This report intends to show that  
8 hyperthyroidism can appear in chinchillas, and to suggest concepts of treatment for both  
9 diseases, hyperthyroidism and diabetes mellitus.

10

## 11 **Case Report**

12 A six year-old female chinchilla, kept in a group of five animals, was referred to the clinic of  
13 Zoo Animals, Exotic Pets and Wildlife, Vetsuisse Faculty, University of Zurich, Switzerland  
14 because of fast progressive weight loss. The patient had given birth to three young six months  
15 ago. No other animals in the population were affected. According to the owner, diet of the  
16 animal consisted of grass hay and commercial chinchilla pellets (brand unknown). First  
17 examination revealed no obvious external abnormalities, the animal was alert and responsive.  
18 Upon palpation a reduced body condition (ribs and spinal processes of thoracic and lumbar  
19 vertebrates prominent), reduced body weight (364 g healthy adult females weigh 400-600 g,  
20 Quesenberry and others 1997) and a little gas in the abdomen were noted. Furthermore, focal,  
21 scaly alopecia medial on the left front leg was observed, but was not further investigated. No  
22 abnormalities were detected during heart and lung auscultation. The faeces were soft and not  
23 well formed. The mouth was full of slime and halitosis was noted. In thhe left eye seromucous  
24 lacrimation was observed.

1 As a first diagnostic step a blood sample was obtained from the jugular vein during isoflurane  
2 anaesthesia and submitted for hematology and serum biochemistry. A swab from the mouth  
3 was taken and examined by microscopy, which revealed abnormal amount of yeasts  
4 indicating a yeast-stomatitis. Due to the overall poor condition and in agreement with the  
5 owner, the chinchilla was hospitalised for further diagnostic work.

6 Initial treatment of the chinchilla included fluid therapy (40 ml of Ringer Lactate s.c.),  
7 meloxicam ( 0.6 mg/kg s.c. Metacam®, Boehringer Ingelheim, Basel, Switzerland) and  
8 nystatine (15'000 mg/kg p.o. Mycostatin®, Sanofi-Synthelabo, Geneva, Switzerland). Blood  
9 analysis (Table 1) revealed a mild leucopenia as well as decreased creatinine and potassium  
10 and potassium levels. Aspartate aminotransferase (AST) and glucose were more than twice  
11 the upper limit of the respective reference ranges. The first differential diagnosis at that point  
12 was diabetes mellitus.

13 Spontaneous urine tested with the semi-quantitative Combur 9-test® (Roche, Basel,  
14 Switzerland) yielded a very high glucose reading (glucosuria), which supported the suspicion  
15 of diabetes mellitus, however, the test did not indicate ketonuria. Abdominal sonography was  
16 performed. Pancreas, liver and kidneys were examined thoroughly and no abnormalities could  
17 be detected. The bladder and uterus were also inconspicuous. As diabetes was now considered  
18 the most likely diagnosis, treatment was accordingly altered. The owner disliked the idea of  
19 giving regular insulin injections. As an alternative, glipizide has been suggested in the  
20 literature (Besselmann and Hatt 2004). Therefore, a prescription was given to the owner for  
21 glipizide (Glibenese®, Pfizer, Zurich, Switzerland), with a suggested dose of 2.5 mg glipizide  
22 BID for 10 days. Before the chinchilla was to go home the next day, another blood sample  
23 was taken to establish a pre-treatment baseline for fructosamine and thyroxine (T4). The  
24 owner agreed for a recheck to perform a serial blood glucose testing in ten days time. The  
25 fructosamine result was obtained the following day and was not elevated (126 µmol/l,  
26 reference range is 215-296 µmol/l in the free-ranging plains viscacha, *Lagostomus maximus*, a

---

1 close relative of the chinchilla, Wenker and others 2007). The results for T4 were not  
2 available for several days and diabetes mellitus treatment was continued.

3 At the recheck after ten days, general condition had improved, and the owner said it seemed  
4 to be livelier and was eating. It had lost 4 g and weighed 362 g. Inspection of the mouth did  
5 not show any abnormality. The feet were showing mild pododermatitis on both sides. The T4  
6 level was 7.0 µg/dl (reference range is 3.4 – 6.4 µg/dl, Martin and others 2005). Blood  
7 samples for hematology, glucose, fructosamine, and T4 were sent for revaluation (Table 1).  
8 Repeat T4 level was 7.6 µg/dl. This increased T4 level was considered to indicate the  
9 presence of hyperthyroidism. Since glucose was only mildly elevated and fructosamine was  
10 still not elevated, diabetes mellitus was considered unlikely and glipizide treatment was  
11 discontinued. The chinchilla was again hospitalized for nine days and a thyroid ultrasound  
12 examination was performed.

13 Treatment of the hyperthyroidism was started 16 days after the first presentation with 0.15 ml  
14 thiamazole ointment BID applied locally on the inner side of the ear (50mg/ml, no brand  
15 name, Christoffel Apotheke, Bern, Switzerland). On ultrasound examination, the thyroid  
16 could not be localized. As treatment with thiamazole was continued over the next nine days,  
17 the chinchilla gained weight. It ate well and continuously put on 30 g within nine days, which  
18 encouraged continuation of the treatment. During the hospitalisation bilateral hairloss was  
19 noted at the medial canthus of the eyes, which was considered to be a result of scratching.

20 Ophthalmologic examination was performed, and a Fluorescein-Test® (Haag-Streit AG,  
21 Bern, Switzerland) was negative. Another hairless site was noted medially on both hind legs.  
22 T4 level was repeated and found to have decreased to 6.7 µg/dl. The owner wanted to take the  
23 chinchilla home and continue the treatment himself. He was given the instructions and  
24 advised to wear gloves when putting the ointment on. He was also advised to measure weight  
25 every day and to notify the clinic, if the chinchilla lost more than 20 g.

1 Thereafter, the chinchilla was presented again in the clinic three times over a period of four  
2 months. First the owner called and said that the chinchilla was showing severe pthyalism.  
3 Assuming that it was another yeast-stomatitis, it was again treated with nystatine (15'000  
4 mg/kg p.o. SID, for two weeks). The next time it was presented it weighed 408 g. The  
5 discharge from the left eye was now serous. Fluorescin-test was repeated and was negative.  
6 The alopecia in the inguinal area persisted. An additional T4 level recheck revealed a further  
7 decrease to 4.2 µg/dl. The eye secretion seemed to be due to hyperplasia of the membrana  
8 nicitans and the owner was advised to wash the eye with lukewarm water as needed.  
9 Nystatine therapy was reinstigated for 10 days. He was also told to reduce thiamazole  
10 administration, starting with 0.10 ml thiamazole for two weeks, to cease thiamazole treatment  
11 afterwards and come for a recheck after another two weeks. The owner did not return after  
12 four weeks as suggested, but after two months with the animal weighing only 390 g. This  
13 weight loss was considered to be the result of malposition of the incisors. The general  
14 examination showed a thin chinchilla that was otherwise in a good condition with a good  
15 appetite. Heart and lungs were considered normal during routine auscultation and the fur, with  
16 the exception of the medial aspects of the tibiae, had regrown. A teeth correction under  
17 isoflurane anaesthesia was performed, as the mandibular incisors were too long and slanting.  
18 Both blood glucose and T4 levels were mildly elevated. The animal came back two times  
19 more during the next month for a dental correction. Body weight was 412 g, fur loss had  
20 improved, ocular discharge and pododermatitis were not noted anymore. Topical thiamazole  
21 was continued , however the exact dosage could not be elucidated from the owner.

22

## 23 **Discussion**

24 Diabetes mellitus has been reported in chinchillas only twice (Marlow 1995, Ewringmann  
25 and Göbel 1998). In both cases animals showed blood glucose levels elevated at least four  
26 times above the upper limit of the reference range, heavy glucosuria and ketonuria. The



---

1 animals were treated with insuline. After initial improvement, both animals died. Post mortem  
2 examination showed an atrophy of the pancreas and vacuolation of the islets of Langerhans in  
3 one case and a pancreas adenoma in the other. Ewringmann and Göbel (1998) suspected a  
4 hereditary component for diabetes mellitus in chinchillas.

5 In this case diabetes was at first suspected due to high blood glucose levels and  
6 glucosuria, although typical findings such as ketonuria, polyuria and polydipsia, obesity and  
7 cataracts were not present. In addition, fructosamine levels did not appear to be elevated.  
8 Although interpretation is guarded, since the only reference values available were for a  
9 closely related rodent, the plains viscacha. One single measurement of glucose level is not  
10 sufficient for the diagnosis in rodents; several measurements are required because stress, pain,  
11 hyperthermia, and shock can cause hyperglycemia (Besselmann and Hatt 2004). Other  
12 possible differential diagnoses for hyperglycemia are hyperthyroidism, Cushing's disease,  
13 iatrogen, postprandial and pancreatitis (Kraft and Dürr 1995). In order to support a diagnosis  
14 of diabetes and exclude a possible hyperthyroidism, serum fructosamine and T4 levels were  
15 determined. The increased T4 level, however, suggested the presence of hyperthyroidism. The  
16 low serum fructosamine level was inconsistent with a suspected diabetes mellitus, and led to  
17 the conclusion that hyperglycemia and glucosuria were most probably stress induced.  
18 Secondary diabetes mellitus, though unlikely, cannot be excluded, Considering, that in  
19 hyperthyroid cats, low serum fructosamine may be due to accelerated protein turnover,  
20 independent of blood glucose concentration (Reusch and Tomsa 1999). A second T4  
21 measurement ten days later with persistently elevated T4 confirmed the diagnosis of  
22 hyperthyroidism. Hyperthyroidism also explains weight loss, whereas diabetes mellitus has  
23 been linked to obesity in the chinchilla (Besselmann and Hatt 2004). The differential  
24 diagnoses for increased T4 levels are: growth, hyperestrogenism, estrus and gravidity (Kraft  
25 and Dürr 1995). In search for an explanation of increased T4 levels, thyroid ultrasound  
26 examination was performed. No apparent change in thyroid glands could be found (they were

---

1 not seen in sonography, palpation did not reveal any swelling or pain), thus the cause of  
2 hyperthyroidism in this case is a matter of speculation. In cats, the diagnosis of  
3 hyperthyroidism is confirmed with the thyroid-stimulation hormone response test (TRH  
4 response test) or T3 suppression test, if T4 levels are unclear. A further diagnostic step would  
5 have been thyroid scintigraphy with technetium. However, due to financial constraints this  
6 test could not be performed.

7 The suspected diabetes mellitus was at first treated with glipizide (Glibenese®), which is  
8 an alternative to insuline in type 2 diabetes. Glipizide stimulates endogenous insulin synthesis  
9 and release. An imminent effect of glipizide in this case is possible, as the glucose level was  
10 decreased at the second measuring, after ten days of therapy (Table 1). It remains  
11 questionable whether this is due to glipizide therapy or simply different occurrences of stress  
12 or pain induced hyperglycemia and glucosuria (influencing factors being: adaptation to  
13 handling, treatment with nystatine). It is nevertheless interesting to note that glipizide did not  
14 appear to have a negative effect. Further research in the use of glipizide in chinchilla with  
15 diabetes is certainly warranted.

16 Hyperthyroidism therapy was performed with thiamazole (or methimazole), which is an  
17 imidazole derivate. It interferes with the synthesis of thyroid hormones T3 and T4 as it  
18 inhibits the binding of iodine to the enzyme thyroidperoxidase. In cats, it is used either as  
19 preoperative preparation for thyroidectomy or as sole treatment for the hyperthyroid state (  
20 Mooney 2005;). In our case an immediate effect can be suspected, as T4 was clearly  
21 decreased after seven and more so after 47 days of therapy (Table 1). More important,  
22 however, is the effect it had on body weight. Initially the chinchilla continuously gained  
23 weight with therapy, and a clear correlation between the T4 level and the body weight  
24 measured at the same day can be demonstrated (Fig. 1). It must be stated, though, that the  
25 animal never reached a body weight significantly over 400 g, and lost weight again after three

---

1 months, which could possibly be explained in all cases with either yeast stomatitis or dental  
2 malposition.

3       The ideal therapy for hyperthyroidism in the chinchilla can only be empirical based on  
4 knowledge in other domestic animals. Thyroidectomy is challenging in chinchillas, as the  
5 parathyroid is difficult to separate from the thyroid and would therefore require lifelong  
6 supplementation of calcium gluconate. Further, rapid regrowth of thyroid tissue has been  
7 reported after thyroparathyroidectomy in chinchillas (Martin and others 2005). Therefore,  
8 radioactive iodine would be needed to obliterate tissue remnants after surgical excision. Sole  
9 treatment with radioactive iodine is considered to be the safest, simplest and most effective  
10 therapy for feline hyperthyroidism (Mooney 2005). No reports on the safety and effect in  
11 rodents are described, though, and no dosage recommendation exists. Longterm medical  
12 management with antithyroid drugs is a practical treatment option for hyperthyroidism that  
13 requires no special facilities, is readily available, easy to implement, and at a reasonable price.  
14 Anaesthesia is avoided, as are the peri- and postoperative complications associated with  
15 surgical thyroidectomy. Unlike in radioactive iodine therapy, hospitalization is unnecessary. It  
16 is noncurative and thus needs to be administered long-term (relapse of hyperthyroidism  
17 invariably occurs in cats rapidly). Methimazole treatment in cats has been described in  
18 detail (Mooney 2005). Because of easier application, thiamazole ointment was used in the case  
19 of this chinchilla instead of a tablet formulation used in cats (oral application of Felimazole®,  
20 Veterinaria, Zurich, Switzerland).

21       Antithyroid drugs require regular assessment of T4 concentration. In cats, adverse  
22 reactions include anorexia, vomiting, depression, self induced excoriation of the face and  
23 neck (pruritus), bleeding diathesis and jaundice caused by hepatopathy (Peterson and others  
24 1988). As hyperthyroidism can mask underlying renal disease that only becomes apparent  
25 upon induction of euthyroidism it is advisable to monitor kidney function (Mooney 2005).

---

1 This intense and continuous monitoring was limited in our case because of the financial  
2 constraints.

3 Further breeding with this chinchilla should be avoided. First because of a possible  
4 hereditary component, and second because thiamazole can be excreted in milk and may cause  
5 disturbances in suckling offspring (Johansen and others 1982). Whether any side effects  
6 actually did occur because of thiamazole treatment in our case can only be guessed. Anorexia  
7 is possible and could be the cause for the clinically reoccurring yeast stomatitis (Gabrisch and  
8 others 2004). Another possible side effect could be pruritus that manifested itself in our case  
9 as bilateral hair loss at the medial canthus of the eyes.

10 A connection between hyperthyroidism and diabetes mellitus is possible, though unlikely.  
11 In cats hyperthyroidism can lead to impairment of glucose tolerance possibly due to  
12 peripheral insulin resistance (Hoenig and Ferguson 1989). Hyperthyroidism in cats may result  
13 in long-lasting alterations of glucose tolerance and insuline secretion which may not be  
14 reversed by treatment of hyperthyroidism (Hoenig and others 1992).

15 Another possible connection can be drawn between hyperthyroidism and fur chewing in  
16 chinchillas. Vanjonack and Johnson (1973) investigated the thyroxin levels in two groups of  
17 chinchillas, and found increased T4 levels in the group that practised fur-chewing as  
18 compared to the non-fur-chewing control group. The fur-chewers also had higher cortisone  
19 levels and lower body temperatures, and a general, increased, non-specific stress was  
20 suspected as one potential trigger. In our case, the chinchilla showed a focal alopecia on the  
21 left front leg and initially developed alopecia in the inguinal area after therapy but was never  
22 actually observed chewing its fur, and no particular stress situation for this animal as  
23 compared to the others was evident. Allopecia and pododermatitis in the present case more  
24 likely was a sequela of the chronic systemic disease.

25 In conclusion we suggest that the present case emphasizes that also in the chinchilla, a  
26 primary diagnosis of diabetes mellitus should not be considered final based on hyperglycemia

1 and glucosuria alone, but that potential differential diagnoses leading to this state should be  
2 investigated and hyperthyroidism should be a differential diagnosis in cases of weight loss.

3

#### 4 **Acknowledgement**

5 The authors would like to acknowledge Claudia Reusch for the helpful comments on the  
6 manuscript.

7

#### 8 **References**

- 9 BESSELMANN, D. & HATT, J. M. (2004) Diabetes mellitus bei Kaninchen und Nagern.  
10 *Tierärztliche Praxis* **32 K**, 370-376
- 11 EWRINGMANN, A. & GÖBEL, T. (1998) Diabetes mellitus bei Kaninchen,  
12 Meerschweinchen und Chinchilla. *Kleintierpraxis* **43**, 337-348
- 13 GABRISCH, P., ZWART, K., FEHR, M. & L, S. (2004) Krankheiten der Heimtiere.  
14 Schlütersche, Hannover
- 15 HOENIG, M. & FERGUSON, D. C. (1989) Impairment of glucose tolerance in hyperthyroid  
16 cats. *Journal of Endocrinology* **121**, 249-251
- 17 HOENIG, M., PETERSON, M. E. & FERGUSON, D. C. (1992) Glucose tolerance and  
18 insulin secretion in spontaneously hyperthyroid cats. *Research in Veterinary Science*  
19 **53**, 338-341
- 20 JOHANSEN, K., ANDERSEN, A. N., KAMPMANN, J. P., MOLHOLM HANSEN, J. M. &  
21 MORTENSEN, H. B. (1982) Excretion of methimazole in human milk. *European*  
22 *Journal of Clinical Pharmacology* **23**, 339-341
- 23 KRAFT, W. & DÜRR, U. (1995) Klinische Labordiagnostik in der Tiermedizin. Schattauer,  
24 Stuttgart
- 25 MARLOW, C. (1995) Diabetes in a chinchilla. *Veterinary Record* **136**, 595-596
- 26 MARTIN, L. B., CHIDAMBARAM, R. M., SCHROEDER, K. E. & MCFADDEN, S. L.  
27 (2005) Thyroparathyroidectomy procedures and thyroxine levels in the chinchilla.  
28 *Contemporary Topics in Laboratory Animal Science* **44**, 31-36
- 29 MOONEY, C. T. (2005) Hyperthyroidism. In: Ettinger SJ, Feldman EC (eds) Textbook of  
30 veterinary internal medicine, 6th ed. Saunders, St. Louis, pp 1544-1558
- 31 PETERSON, M. E., KINTHER, P. P. & HURVITZ, A. I. (1988) Methimazole treatment of  
32 262 cats with hyperthyroidism. *Veterinary Internal Medicine* **2**, 150-157
- 33 QUESENBERRY, K. E., DONNELLY, T. M. & HILLYER, E. V. (1997) Biology,  
34 husbandry, and clinical techniques of guinea pigs and chinchillas. In: Quesenberry  
35 KE, Carpenter JW (eds) Ferrets, rabbits and rodents. Clinical medicine and surgery.  
36 Saunders, St. Louis, pp 232-244
- 37 REUSCH, C. E. & TOMSA, K. (1999) Serum fructosamine concentrations in cats with overt  
38 hyperthyroidism. *Journal of the American Veterinary Medical Association* **215**, 1297-  
39 1300
- 40 VANJONACK, W. J. & JOHNSON, H. D. (1973) Relationship of thyroid and adrenal  
41 function to 'fur-chewing' in the chinchilla. *Comparative Biochemistry and Physiology*  
42 *A* **45**, 115-120

---

1 WENKER, C. J., HUNZIKER, D., LOPEZ, J., OPPLINGER, H., FORRER, R. & LUTZ, H.  
2 (2007) Hematology, blood chemistry, and urine parameters of free-ranging plains  
3 viscachas (*Lagostomus maximus*) in Argentina determined by use of a portable blood  
4 analyzer (i-STAT) and conventional laboratory methods. *Journal of Veterinary*  
5 *Medicine A* **54**, 260-264  
6  
7

1 TABLE 1: Hematology and serum biochemistry findings in a Chinchilla (*Chinchilla laniger*)

2 diagnosed with hyperthyroidism and suspected secondary diabetes mellitus, as compared to

3 reference values

4

	unit	day 1	day 3	day 12	day 24	day 59	day 132	reference range
leukocytes	10 <sup>3</sup> /μl	5.3		4.4				5.5 - 17.5 *
neutrophiles	%	83						22 - 48 *
lymphocytes	%	10						39 - 72 *
glucose	mmol/l	14.1		9.0			7.1	3.3 - 6.87 *
urea	mmol/l	10.9						3.21 - 11.24 *
creatinine	μmol/l	40						53.4 - 194.48 *
total protein	g/l	54						42 - 68 *
albumin	g/l	33						21 - 39 *
globulin	g/l	21						17 - 26 *
AST	U/l	186						26 - 68 *
potassium	mmol/l	2.9						3.8 - 7.9 *
calcium	mmol/l	2.62						2.05 - 3.00 *
phosphorus	mmol/l	1.44						0.96 - 2.45 *
fructosamine	μmol/l		126	145				215 - 296 °
T4	μg/dl		7	7.6	6.7	4.2	6.6	3.4 - 6.4 ^

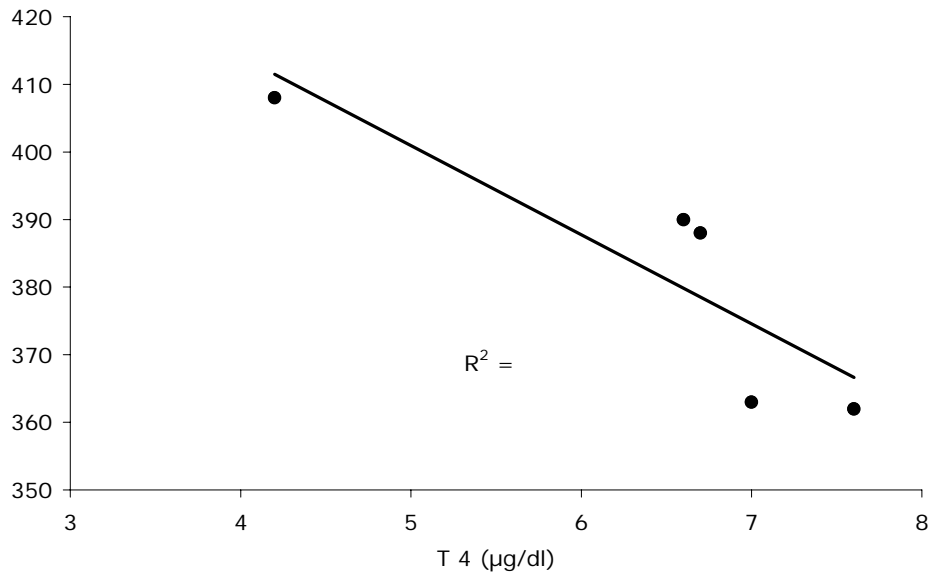
5

6 \* according to Quesenberry and others (1997)

7 ° according to Wenker and others (2007)

8 ^ according to Martin and others (2005)

- 
- 1 FIG 1: Correlation of T4 levels with body weight of a chinchilla (*Chinchilla laniger*)
  - 2 diagnosed with hyperthyroidism and suspected secondary diabetes mellitus



- 3
- 4
- 5
- 6
- 7
- 8
- 9
- 10