



**University of
Zurich**^{UZH}

**Zurich Open Repository and
Archive**

University of Zurich
University Library
Strickhofstrasse 39
CH-8057 Zurich
www.zora.uzh.ch

Year: 2012

Rare human skin infection with *Corynebacterium ulcerans*: transmission by a domestic cat

Corti, M A M ; Bloemberg, G V ; Borelli, S ; Kutzner, H ; Eich, G ; Hoelzle, L ; Lautenschlager, S

DOI: <https://doi.org/10.1007/s15010-012-0254-5>

Posted at the Zurich Open Repository and Archive, University of Zurich

ZORA URL: <https://doi.org/10.5167/uzh-71116>

Journal Article

Published Version

Originally published at:

Corti, M A M ; Bloemberg, G V ; Borelli, S ; Kutzner, H ; Eich, G ; Hoelzle, L ; Lautenschlager, S (2012). Rare human skin infection with *Corynebacterium ulcerans*: transmission by a domestic cat. *Infection*, 40(5):575-578.

DOI: <https://doi.org/10.1007/s15010-012-0254-5>

Rare human skin infection with *Corynebacterium ulcerans*: transmission by a domestic cat

M. A. M. Corti · G. V. Bloemberg ·
S. Borelli · H. Kutzner · G. Eich · L. Hoelzle ·
S. Lautenschlager

Received: 5 December 2011 / Accepted: 1 March 2012 / Published online: 9 March 2012
© Springer-Verlag 2012

Abstract *Corynebacterium ulcerans* is mainly known for its ability to cause animal infections. Some strains of *C. ulcerans* produce diphtheria toxin, which can cause life-threatening cardiopathies and neuropathies in humans. Human cutaneous *C. ulcerans* infection is a very rare disease that mimics classical cutaneous diphtheria. We present a very rare case of a *C. ulcerans* skin infection caused by a non-diphtheria toxin-producing strain of *C. ulcerans* that resolved after 3 weeks of therapy with amoxicillin–clavulanate. A pet cat was the probable source of infection. The presence of *C. ulcerans* in the mouth of the cat was confirmed by 16S rRNA gene analysis and the API Coryne system. In cases of human infection with potentially toxigenic corynebacteria, it is important to determine the species and examine the isolate for diphtheria toxin production. If toxigenicity is present, diphtheria antitoxin should be administered immediately. Carriers and potential infectious

sources of *C. ulcerans* include not only domestic livestock but also pet animals. For the primary prevention of disease caused by diphtheria toxin-producing corynebacteria, vaccination with diphtheria toxoid is recommended.

Keywords *Corynebacterium ulcerans* · Infection · Bacteria · Zoonotic transmission

Introduction

Corynebacterium ulcerans is primarily known as an animal pathogen and is a commensal in horses and cattle [1]. In veterinary medicine, it is a recognized cause of mastitis in cows and has been isolated from raw cow's milk. Zoonotic human infections have been reported, usually among rural populations with direct contact to domestic livestock [1]. The global epidemiology of human infections caused by *C. ulcerans* is not well understood [2]. Many strains of *C. ulcerans* produce the diphtheria toxin [3] and cause exudative pharyngitis in humans indistinguishable from diphtheria [4], with local pseudomembrane production and potential systemic cardiac or neurologic manifestations as life-threatening complications. Independently of diphtheria toxin production, some strains produce a dermonecrotic toxin [5]. Skin infections caused by *C. ulcerans* have very rarely been reported so far (Table 1). As in this reported case, the clinical manifestation is indistinguishable from classical cutaneous diphtheria [1, 6].

Case report

A 29-year-old otherwise healthy male developed a cutaneous ulcer on the right hand measuring about 1 cm in

M. A. M. Corti · S. Borelli · S. Lautenschlager (✉)
Outpatient Clinic of Dermatology, Triemli Hospital,
Herman Greulich Strasse 70, 8004 Zurich, Switzerland
e-mail: stephan.lautenschlager@triemli.stzh.ch

G. V. Bloemberg
Institute of Medical Microbiology,
University of Zurich, Zurich, Switzerland

H. Kutzner
Dermatohistopathologische Gemeinschaftspraxis,
Friedrichshafen, Germany

G. Eich
Department of Internal Medicine, Triemli Hospital,
Zurich, Switzerland

L. Hoelzle
Institute of Veterinary Bacteriology,
University of Zurich, Zurich, Switzerland

diameter with undermined elevated edges, covered with a gray–brown membrane (Fig. 1). In addition, on the back of his hand and over the fourth and fifth fingers, there was a clearly outlined area of erythema (Fig. 1). No signs of lymphangitis or lymphadenopathy were detected and the patient did not report any other symptoms. The laboratory findings, including the inflammatory markers (C-reactive protein [CRP] 1.5 mg/l and leukocytes $9.40 \times 10^9/l$) and the antistreptolysin titer, were normal. We took a swab from the lesion and started oral therapy with amoxicillin–clavulanate (625 mg, three times a day). Culture of the swab on 5 % sheep blood agar produced a growth of normal skin flora and, as major pathogens, *Enterococcus* species and dry waxy colonies of Gram-positive rods were subsequently identified as *C. ulcerans* by the API Coryne system (bioMérieux, Genève, Switzerland) and by a positive fermentation test for glycogen and trehalose. Real-time polymerase chain reaction (PCR) analysis for the presence of the diphtheria toxin gene [7] using chromosomal DNA extracted from the *C. ulcerans* isolate was negative, indicating the lack of diphtheria toxin production. The patient had been vaccinated with diphtheria toxoid 10 years earlier during military service. The general condition of the patient remained good for the duration of the treatment and, as he showed no signs of cardiopathy or neuropathy,

diphtheria antitoxin titration or administration was thought not to be necessary.

The course of the patient's disease was favorable and, after 3 weeks of unchanged systemic antibiotic therapy and local antiseptics with aqueous chlorhexidine 0.1 % lotion, we noticed a remarkable improvement of the lesion on the hand, resulting in defect healing with a scar.

On further inquiry, the patient remembered an episode of sore throat and fever 3 weeks before the appearance of the cutaneous lesion. Swabs taken from the throat of the patient 2 weeks after the end of antibiotic therapy produced only the growth of normal flora. The patient denied any contacts with horses or cows but the pet cat of the patient had lesions similar to the patient in its mouth and on a paw 1 week earlier. The cat's veterinarian clinically suspected a neoplasm or a bullous skin disease and, therefore, performed two skin biopsies that revealed a suppurative skin infection with edema of the dermis and an infiltration of neutrophils (Fig. 2). Broad-range bacterial 16S rRNA gene PCR [8] using an extract of the paraffin-embedded tissue did not detect bacterial DNA. However, this could be due to reduced sensitivity of the PCR in formalin-fixed, paraffin-embedded tissue [9]. The cat received systemic therapy with clindamycin (5.5 mg/kg body weight every 12 h orally for 32 days), which resulted in complete regression of all lesions.

Subsequently, about 2 weeks after the end of clindamycin therapy, we took a swab from the mouth of the cat; Gram-positive rods identified as *C. ulcerans* or *C. pseudotuberculosis* were isolated on a 5 % sheep blood agar-based selective medium containing fosfomycin. Coryneform colonies were examined by 16S rRNA gene analysis and the API Coryne system. The sequence was submitted to GenBank under accession number

Table 1 Reported cases of *Corynebacterium ulcerans* skin infections

Reference	Year	Number of patients	Country	Toxicogenic strain
Wagner et al. [6]	2001	1	Germany	Uncertain
DeWinter et al. [22]	2005	3	Canada	Yes
Werchniak et al. [23]	2007	1	USA	Yes

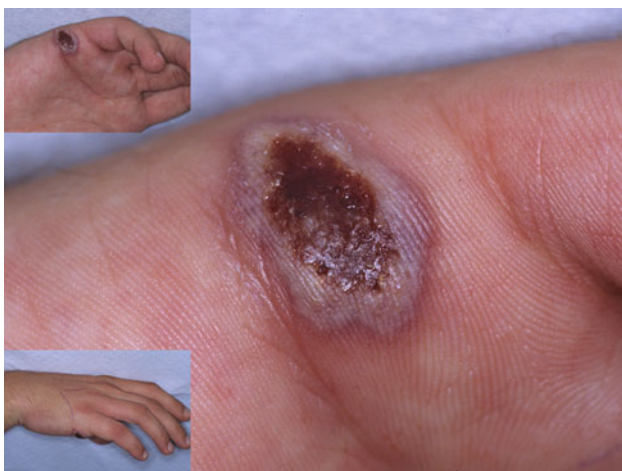

Fig. 1 Ulcer of 1 cm in diameter with undermined edges, covered with a gray–brown membrane. Erythema on the back of the right hand and over the fourth and fifth fingers (lower inset photograph)

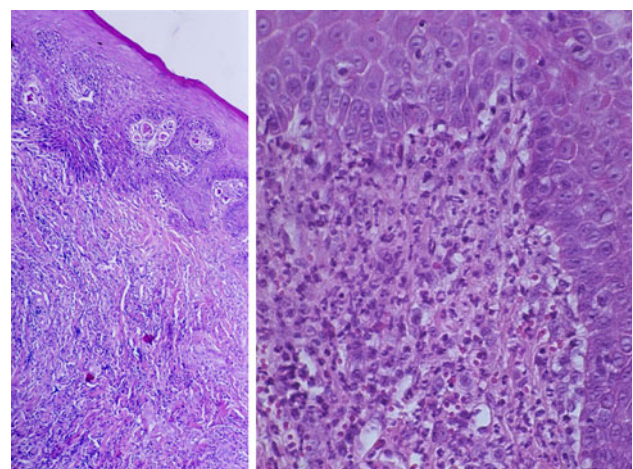


Fig. 2 Biopsy specimen of the cat's lips revealing a suppurative mucosal infection with edema of the dermis and an infiltration of neutrophils. HE $\times 10$ and $\times 40$

HM136582. The 16S rRNA gene sequence showed 100 % homology with *C. ulcerans*. There was also a high homology (99.7 %) to *C. pseudotuberculosis*, requiring a further analysis for species assignment. Using the API Coryne system, the isolate was identified as *C. ulcerans* with a percentage identification value of 99.7 % and *T*-index value of 1. Both the analysis for the production of diphtheria toxin and PCR for *Parapoxvirus*, *Orthopoxvirus*, and *Orf virus* resulted negative.

Discussion

There is no evidence of human-to-human transmission of *C. ulcerans* [1, 6], but rare cases of familial infection have been detected [10]. In addition to domestic livestock, pet cats and dogs were recently suggested as possible carriers and transmission sources of this pathogen [11, 12]. Our case supports this conjecture. In the reported case, the domestic cat had suffered a cutaneous infection resembling the patient's lesion. After antibiotic therapy, the cat was found to be carrying *C. ulcerans* in the mouth, suggesting that it may have been the source of the patient's infection. As cultures were no longer available, molecular typing and comparison of the human and feline isolates was not possible. Nevertheless, the time course and the close contact suggest possible zoonotic transmission. Probably, the normal flora of the cat's mouth will overcome *C. ulcerans* as a normal pathophysiological process [13]. Similarly to the prevention of pasteurellosis [14], hygienic precautions, such as the avoidance of contact of skin lesions with cat saliva and the use of appropriate antiseptics and disinfection procedures, are to be observed for a minimal transmission risk.

The microbiological diagnosis of *C. ulcerans* can be performed by culture from a swab of the infection site using the procedures fully described in the World Health Organization (WHO) "Manual for the laboratory diagnosis of diphtheria" [15]. The microorganism can be distinguished from *C. diphtheriae* and *C. pseudotuberculosis* with a conventional biochemical kit test (e.g., API Coryne system) [16]. After the identification of the correct species, an evaluation of diphtheria toxin production is recommended for all organisms that have the potential to produce this toxin. It is known that the ability to produce diphtheria toxin is carried in the structural gene, *tox*, mediated by infection of the bacterium by a corynebacteriophage [17]. Rapid methods such as PCR have improved the identification of the diphtheria toxin gene [15]. Not all PCR-positive strains of *C. diphtheriae* have a biologically active *tox* gene and express phenotypically the toxin [18]. Nevertheless, *tox* gene-positive but non-toxigenic strains of *C. ulcerans* have, so far, not been documented [6]. In our case, we used a real-time PCR for the detection of

toxigenicity; however, a recent study has suggested that false-negative results may be obtained by this method [19]. For this reason, an additional test to check for diphtheria toxin production (e.g., Elek test [15]) should be performed or the patient should be closely clinically observed for symptoms manifestation. In our case, we opted for the latter. If the patient presents any symptoms of toxemia, even without the confirmation of phenotypic active toxin production, diphtheria antitoxin should be administered as soon as possible. Serum sickness should be ruled out by scratch testing [20]. The antibiotic management should be similar to the treatment for diphtheria [10]. Although the organism is sensitive to most antibacterial agents in vitro, erythromycin is regarded as the antibiotic of choice [1]. Since the clinical course of our patient under amoxicillin-clavulanate treatment was favorable, we did not change the therapy and the skin lesion healed completely. The value of diphtheria toxoid vaccination in preventing disease caused by toxigenic *C. ulcerans* has been the subject of debate [2, 21]. Previous vaccination with diphtheria toxoid did not modify the local disease process of our patient affected with non-toxigenic *C. ulcerans*. This could be explained by the fact that the local disease may be caused by other toxins such as the dermonecrotic toxin [1].

In conclusion, we present a very rare case of cutaneous infection with *C. ulcerans*, which has potential clinical complications similar to classic cutaneous diphtheria. All corynebacteria isolated from wounds (if growing as predominant organisms or in pure culture) should be identified to the species level. In case of toxigenic species such as *C. diphtheriae*, *C. ulcerans*, and *C. pseudotuberculosis*, they should be analyzed for diphtheria toxin production. If the isolate is found to produce toxin or the patient presents with related symptoms, the need for antitoxin administration should be evaluated immediately (in Switzerland, antitoxin is available from the Swiss Toxicological Information Centre, <http://www.toxi.ch>). Not only domestic livestock but also pets may be responsible for the transmission of this pathogen. Immunization with diphtheria toxoid will minimize the risk of diphtheria-like disease complications arising from infections due to toxigenic corynebacteria [10], but it seems not to be able to avoid non-toxigenic *C. ulcerans* local infections.

Acknowledgment We thank the laboratory team of Triemli Hospital for their expert technical support.

Conflict of interest None.

References

1. Meyer DK, Reboli AC. Other coryneform bacteria and rhodococcus. In: Mandell GL, Bennett JE, Dolin R, editors. Principles

- and practice of infectious diseases. New York: Elsevier; 2005. p. 2465–78.
2. Tiwari TS, Golaz A, Yu DT, Ehresmann KR, Jones TF, Hill HE, et al. Investigations of 2 cases of diphtheria-like illness due to toxigenic *Corynebacterium ulcerans*. *Clin Infect Dis*. 2008;46:395–401.
 3. Wong TP, Groman N. Production of diphtheria toxin by selected isolates of *Corynebacterium ulcerans* and *Corynebacterium pseudotuberculosis*. *Infect Immun*. 1984;43:1114–6.
 4. Lipsky BA, Goldberger AC, Tompkins LS, Plorde JJ. Infections caused by nondiphtheria corynebacteria. *Rev Infect Dis*. 1982;4:1220–35.
 5. Carne HR, Onon EO. The exotoxins of *Corynebacterium ulcerans*. *J Hyg (Lond)*. 1982;88:173–91.
 6. Wagner J, Ignatius R, Voss S, Höpfner V, Ehlers S, Funke G, et al. Infection of the skin caused by *Corynebacterium ulcerans* and mimicking classical cutaneous diphtheria. *Clin Infect Dis*. 2001;33:1598–600.
 7. Bosshard PP, Abels S, Altwegg M, Böttger EC, Zbinden R. Comparison of conventional and molecular methods for identification of aerobic catalase-negative gram-positive cocci in the clinical laboratory. *J Clin Microbiol*. 2004;42:2065–73.
 8. Bosshard PP, Kronenberg A, Zbinden R, Ruef C, Böttger EC, Altwegg M. Etiologic diagnosis of infective endocarditis by broad-range polymerase chain reaction: a 3-year experience. *Clin Infect Dis*. 2003;37:167–72.
 9. Shi SR, Cote RJ, Wu L, Liu C, Datar R, Shi Y, et al. DNA extraction from archival formalin-fixed, paraffin-embedded tissue sections based on the antigen retrieval principle: heating under the influence of pH. *J Histochem Cytochem*. 2002;50:1005–11.
 10. Bonnet JM, Begg NT. Control of diphtheria: guidance for consultants in communicable disease control. *World Health Organization. Commun Dis Public Health*. 1999;2:242–9.
 11. Hogg RA, Wessels J, Hart J, Efstratiou A, De Zoysa A, Mann G, et al. Possible zoonotic transmission of toxigenic *Corynebacterium ulcerans* from companion animals in a human case of fatal diphtheria. *Vet Rec*. 2009;165:691–2.
 12. De Zoysa A, Hawkey PM, Engler K, George R, Mann G, Reilly W, et al. Characterization of toxigenic *Corynebacterium ulcerans* strains isolated from humans and domestic cats in the United Kingdom. *J Clin Microbiol*. 2005;43:4377–81.
 13. Bär W. Physiologische Bakterienflora: Kolonisationsresistenz, endogene Opportunisteninfektionen; Probiotika. In: Hahn H, Falke D, Kaufmann SHE, Ullmann U, editors. *Medizinische Mikrobiologie und Infektiologie*. 5th ed. Heidelberg: Springer Medizin; 2005. p. 35–44.
 14. Oehler RL, Velez AP, Mizrahi M, Lamarche J, Gompf S. Bite-related and septic syndromes caused by cats and dogs. *Lancet Infect Dis*. 2009;9:439–47.
 15. Efstratiou A, Maple PAC. Manual for the laboratory diagnosis of diphtheria. The Expanded Programme on Immunization in the European Region of WHO. ICP/EPI038(C). Copenhagen: WHO; 1994.
 16. Soto A, Zapardiel J, Soriano F. Evaluation of API Coryne system for identifying coryneform bacteria. *J Clin Pathol*. 1994;47:756–9.
 17. Clarridge J, Popovic T, Inzana T. Diphtheria and other corynebacterial and coryneform infections. In: Collier L, Balows A, Sussman M, editors. *Topley and Wilson's microbiology and microbial infections*. London: Arnold; 1998. p. 348–52.
 18. Efstratiou A, Engler KH, Dawes CS, Sesardic D. Comparison of phenotypic and genotypic methods for detection of diphtheria toxin among isolates of pathogenic corynebacteria. *J Clin Microbiol*. 1998;36:3173–7.
 19. Cassidy PK, Pawloski LC, Tiwari T, Sanden GN, Wilkins PP. Analysis of toxigenic *Corynebacterium ulcerans* strains revealing potential for false-negative real-time PCR results. *J Clin Microbiol*. 2008;46:331–3.
 20. MacGregor RR. *Corynebacterium diphtheriae*. In: Mandell GL, Bennett JE, Dolin R, editors. *Principles and practice of infectious diseases*. New York: Elsevier; 2005. p. 2457–65.
 21. Schuhegger R, Kugler R, Sing A. Pitfalls with diphtheria-like illness due to toxigenic *Corynebacterium ulcerans*. *Clin Infect Dis*. 2008;47:288.
 22. DeWinter LM, Bernard KA, Romney MG. Human clinical isolates of *Corynebacterium diphtheriae* and *Corynebacterium ulcerans* collected in Canada from 1999 to 2003 but not fitting reporting criteria for cases of diphtheria. *J Clin Microbiol*. 2005;43:3447–9.
 23. Werchniak AE, Devlin RK, Klaus SN. Case report of a persistent skin and soft tissue infection caused by *Corynebacterium ulcerans*. *Infect Dis Clin Pract*. 2007;15:217–9.