



Neural correlates of laughter and humour

Wild, Barbara ; Rodden, Frank A ; Grodd, Wolfgang ; Ruch, Willibald

Abstract: Although laughter and humour have been constituents of humanity for thousands if not millions of years, their systematic study has begun only recently. Investigations into their neurological correlates remain fragmentary and the following review is a first attempt to collate and evaluate these studies, most of which have been published over the last two decades. By employing the classical methods of neurology, brain regions associated with symptomatic (pathological) laughter have been determined and catalogued under other diagnostic signs and symptoms of such conditions as epilepsy, strokes and circumspect brain lesions. These observations have been complemented by newer studies using modern non-invasive imaging methods. To summarize the results of many studies, the expression of laughter seems to depend on two partially independent neuronal pathways. The first of these, an 'involuntary' or 'emotionally driven' system, involves the amygdala, thalamic/hypo- and subthalamic areas and the dorsal/tegmental brainstem. The second, 'voluntary' system originates in the premotor/frontal opercular areas and leads through the motor cortex and pyramidal tract to the ventral brainstem. These systems and the laughter response appear to be coordinated by a laughter-coordinating centre in the dorsal upper pons. Analyses of the cerebral correlates of humour have been impeded by a lack of consensus among psychologists on exactly what humour is, and of what essential components it consists. Within the past two decades, however, sufficient agreement has been reached that theory-based hypotheses could be formulated and tested with various non-invasive methods. For the perception of humour (and depending on the type of humour involved, its mode of transmission, etc.) the right frontal cortex, the medial ventral prefrontal cortex, the right and left posterior (middle and inferior) temporal regions and possibly the cerebellum seem to be involved to varying degrees. An attempt has been made to be as thorough as possible in documenting the foundations upon which these burgeoning areas of research have been based up to the present time.

DOI: <https://doi.org/10.1093/brain/awg226>

Posted at the Zurich Open Repository and Archive, University of Zurich

ZORA URL: <https://doi.org/10.5167/uzh-77671>

Journal Article

Published Version

Originally published at:

Wild, Barbara; Rodden, Frank A; Grodd, Wolfgang; Ruch, Willibald (2003). Neural correlates of laughter and humour. *Brain*, 126(Pt 10):2121-38.

DOI: <https://doi.org/10.1093/brain/awg226>

REVIEW ARTICLE

Neural correlates of laughter and humour

Barbara Wild,^{1,2,*} Frank A. Rodden,² Wolfgang Grodd² and Willibald Ruch³

¹Department of Psychiatry, ²Section of Experimental Magnetic Resonance of the CNS, Department of Neuroradiology, University of Tübingen, Germany and ³Department of Psychology, University of Zürich, Switzerland

Correspondence to: Dr Barbara Wild, Psychiatrische Universitätsklinik, Oslanderstrasse 24, 72076 Tübingen, Germany
E-mail: bawild@med.uni-tuebingen.de

Summary

Although laughter and humour have been constituents of humanity for thousands if not millions of years, their systematic study has begun only recently. Investigations into their neurological correlates remain fragmentary and the following review is a first attempt to collate and evaluate these studies, most of which have been published over the last two decades. By employing the classical methods of neurology, brain regions associated with symptomatic (pathological) laughter have been determined and catalogued under other diagnostic signs and symptoms of such conditions as epilepsy, strokes and circumspect brain lesions. These observations have been complemented by newer studies using modern non-invasive imaging methods. To summarize the results of many studies, the expression of laughter seems to depend on two partially independent neuronal pathways. The first of these, an ‘involuntary’ or ‘emotionally driven’ system, involves the amygdala, thalamic/hypo- and subthalamic areas and the dorsal/tegmental brainstem. The second, ‘voluntary’ system originates in the premotor/frontal opercular areas and

leads through the motor cortex and pyramidal tract to the ventral brainstem. These systems and the laughter response appear to be coordinated by a laughter-coordinating centre in the dorsal upper pons. Analyses of the cerebral correlates of humour have been impeded by a lack of consensus among psychologists on exactly what humour is, and of what essential components it consists. Within the past two decades, however, sufficient agreement has been reached that theory-based hypotheses could be formulated and tested with various non-invasive methods. For the perception of humour (and depending on the type of humour involved, its mode of transmission, etc.) the right frontal cortex, the medial ventral prefrontal cortex, the right and left posterior (middle and inferior) temporal regions and possibly the cerebellum seem to be involved to varying degrees. An attempt has been made to be as thorough as possible in documenting the foundations upon which these burgeoning areas of research have been based up to the present time.

Keywords: emotion; facial expression; brain physiology; exhilaration; functional anatomy

Abbreviations: ERP = event related potential; PAG = periaqueductal grey; rCBF = regional cerebral blood flow; RF = reticular formation; SMA = supplementary motor area

Introduction

Abraham called the name of his son who was born to him, whom Sarah bore him: Isaac (i.e. ‘he laughs’) ... and Sarah said, ‘God has made laughter for me; everyone who hears will laugh over me’.

Genesis 21:3 and 6

Analysing humour is like dissecting a frog. Few people are interested and the frog dies of it.

E. B. White

That laughter and humour are integral components of humanity hardly needs to be documented; they have been analysed and discussed for over two millennia, traditionally within the contexts of philosophy, anthropology, psychology, theology and philology (Martin, 1998; Fry, 2002). Ever since the 19th century, particularly the pathological variants of laughter have enjoyed the interest of neurologists (Nothnagel, 1889; Brissaud, 1895). More than 20 years have passed,

however, since the last major review of this field was published (Poeck, 1985) and most of the present article is a summary and evaluation of studies on symptomatic laughter carried out since 1985.

Very recently, however, ‘normal’ laughter has also come under the purview of neurology (Ozawa *et al.*, 2000; Goel *et al.*, 2001, Iwase *et al.*, 2002), and with it has come—somewhat in the role of an uninvited guest at a family reunion, its awkward companion—humour. Normal laughter can, of course, be caused by elements other than humour: tickling, social cues and laughing gas come to mind (McGhee, 1979; Ramachandran, 1998; Provine, 2000). At present, however, humour is the only element that has been used to elicit normal laughter in neurological studies. Far from being a simple stimulus, humour is a phenomenon of such controversial complexity (particularly with respect to its cognitive components) that a brief discourse on its nature is prerequisite for understanding the laughter that it evokes. Under what conditions can laughter and humour be separated from one another? Under what conditions can they be dissected into sensory, cognitive, emotional and expressive components? When and how are these factors related? Recent studies addressing these questions, based on ‘normal laughter’, are discussed and a framework for the neural correlates of laughter and humour is formulated on the basis of the studies on laboratory animals, neurological patients and normal subjects that are reviewed here.

Laughter and the brain

Laughter: origins

It would be remarkable if such a loud, ubiquitous, relatively uniform but somewhat incapacitating behaviour such as laughter had no survival value. In his book *The Expression of the Emotions in Man and Animals*, Charles Darwin (1872) speculated that the evolutionary basis of laughter was its function as a social expression of happiness, and that this rendered a cohesive survival advantage to the group. Smiling and laughter are not unique to humans. The cerebral organization of laughter has likewise been studied in squirrel monkeys (Jürgens, 1986, 1998); furthermore, among juvenile chimpanzees a ‘play face’ with associated vocalization has been noted to accompany actions such as play, tickling or play biting (van Hoof, 1972; Preuschoft, 1995).

In humans, responsive smiling generally develops within the first 5 weeks of extrauterine life (Kraemer *et al.*, 1999). Laughter emerges later, around the fourth month (Ruch and Ekman, 2001). Although more than 16 different types of smiles have been distinguished at the morphological level (Ekman, 1997), it is interesting that the various types of laughter (at humorous situations, but also scornful, mocking, social, faked, etc.) remain relatively undesignated (Ruch and Ekman, 2001). The smile occurring in response to humour is the facial configuration designated (Ekman *et al.*, 1990) the ‘Duchenne display’ (in honour of the neurologist, G. B.

Duchenne, who first described how this pattern distinguished smiles of enjoyment from other kinds of smiling). The Duchenne display refers to the simultaneous contraction of the zygomatic major and orbicularis oculi muscles (which pull the corners of the lips backwards and upwards and narrow the eyes, causing wrinkles). During laughter, additional facial, respiratory and laryngeal muscles are activated (Bachorowski and Smoski, 2001; Ruch and Ekman, 2001). Smiling and laughing may occur spontaneously (in response to humour or to appropriate emotional or sociological stimuli), and can also be elicited upon command (voluntary, contrived or ‘faked’ smiling/laughter). The neural pathways involved in these different displays have been partially elucidated on the basis of information derived from studies of subjects with brain lesions (see below).

Pathological laughter

As mentioned above, the study of symptomatic laughter antedates that of normal laughter by decades. The following sections describe various forms of symptomatic laughter in patients with brain lesions. Most (but not all) of the studies cited here date from the past 18 years, i.e. since Poeck’s (1969) widely quoted review.

At the outset of this discussion, it must be noted that at present there is neither a uniform nomenclature nor a consistent nosology with regard to neurological disturbances involving laughter. What follows must be considered a summary of the state of the art. Inasmuch as laughter is such a ubiquitous component of human behaviour, the notion of ‘pathological’ laughter can refer to anything from laughter at politically incorrect jokes to laughter as a manifestation of chromosomal aberrations in the Angelman syndrome. In those conditions in which pathological laughter is part of a global behaviour pattern (i.e. in which the laughter is congruent with a feeling of exhilaration), issues of causality are, at present, simply too complex for analysis and will not be further discussed in this review. Such conditions include mania, schizophrenia, mood disorders, Alzheimer’s syndrome and the genetic disorder of Angelman syndrome (Askenasy, 1987; Laan *et al.*, 1996).

Despite certain shortcomings (see below), the most widely acknowledged classification scheme for symptomatic laughter is that of Poeck (1969, 1985). With respect to neuropathology, he differentiated among symptomatic laughter deriving from: (i) motor neuron disease, vascular pseudobulbar paralysis and extrapyramidal motor disorders; (ii) *fou rire prodromique*; and (iii) epileptic seizures. In the following sections, we use Poeck’s classification but have added sections on voluntary/emotional dissociation, laughter, mirth and brain stimulation, functional imaging in healthy subjects and studies of non-human laughter-like vocalizations. For heuristic reasons, the various forms of pathological laughter are described in an order different from Poeck’s. A summary of pathological findings (included here only if they

were determined either by neuroradiology or post-mortem) associated with symptomatic laughter is presented in Table 1.

Gelastic epilepsy

Laughter can occur within the framework of any epileptic seizure. The term 'gelastic epilepsy' (from the Greek *gelos*, laughter) refers exclusively to those relatively rare seizures in which laughter is the cardinal symptom. These seizures can consist exclusively of laughing but often occur in association with general autonomic arousal and automatisms of movement and/or disturbed states of consciousness (Wilson, 1924; Berkovic *et al.*, 1988; Cascino *et al.*, 1993; Valdeuza *et al.*, 1994; Cerullo *et al.*, 1998; Striano *et al.*, 1999). Other symptoms accompanying this ictal laughter, such as perambulation (Jandolo *et al.*, 1977) and micturition (Tasch *et al.*, 1998), have been reported occasionally and are less frequent. Despite its stereotypic nature, the laughter produced by patients during gelastic seizures can appear normal and even be contagious; one such patient even won a 'happy baby' contest (Berkovic *et al.*, 1988). More typically, however, ictal laughter appears mechanical and unnatural (Berkovic *et al.*, 1988; Tasch *et al.*, 1998).

During gelastic seizures, some patients report pleasant feelings which include exhilaration or mirth (Jacome *et al.*, 1980; Arroyo *et al.*, 1993; Sturm *et al.*, 2000). Other patients experience the attacks of laughter as inappropriate and feel no positive emotions during their laughter (Assal *et al.*, 1993; Munari *et al.*, 1995; Berkovic *et al.*, 1997; Iannetti *et al.*, 1997; Kuzniecky *et al.*, 1997; Cerullo *et al.*, 1998; Georgakoulias *et al.*, 1998; Tasch *et al.*, 1998; Striano *et al.*, 1999). It has been claimed that gelastic seizures originating in the temporal regions involve mirth but that those originating in the hypothalamus do not. This claim has been called into question, however, by investigators who have documented feelings of mirth in some patients during seizures arising from hamartomas of the hypothalamus (Arroyo *et al.*, 1993; Sturm *et al.*, 2000).

Older studies of gelastic epilepsy were based exclusively on findings using surface EEG electrodes; such arrays do not allow the exact intracranial localization of epileptogenic foci. The only studies discussed below are those based on data confirmed by CT/MRI localization of abnormalities or by intracranial recordings of epileptic activity.

The brain areas most frequently found to have been harbouring pathological findings in patients suffering from gelastic epilepsy are: (i) the hypothalamus, most commonly in the form of hypothalamic hamartomas, which are non-neoplastic malformations composed of hyperplastic neuronal tissue resembling grey matter (Cascino *et al.*, 1993; Valdeuza *et al.*, 1994; Munari *et al.*, 1995; Kuzniecky *et al.*, 1997; Georgakoulias *et al.*, 1998; Unger *et al.*, 2000); (ii) the frontal poles (Arroyo *et al.*, 1993; Iannetti *et al.*, 1997; Unger *et al.*, 2000); and (iii) the temporal poles (Coria *et al.*, 2000). Ictal smiling (without laughter) has been observed in patients with epileptic foci in the parieto-occipital, hippocampal and,

again, the temporal regions (Molinuevo and Arroyo, 1998). Epileptic laughter has also been reported in patients with generalized tuberous sclerosis (Striano *et al.*, 1999).

Of all these lesions, it is the hypothalamic hamartomas that have been studied most extensively. Their intra-ictal epileptic activity has been characterized not only by surface electrodes but also with intracerebral recordings (Munari *et al.*, 1995). A study employing single photon emission computed tomography has demonstrated a condition of hyperperfusion (Arroyo *et al.*, 1997) in these tumours during gelastic seizures. Hypothalamic and pituitary hormones have been found to be secreted during the seizures (Arroyo *et al.*, 1997; Tinuper *et al.*, 1997; Cerullo *et al.*, 1998). The supposition that the hypothalamus *per se* is responsible for the production of these seizures (as opposed to the hypothesis that the pathological activity observed in the hypothalamus is the result of temporal or frontal processes essential for seizure generation) has been strengthened by three observations. First, electrical stimulation of the hamartomas themselves produces typical seizures (Kuzniecky *et al.*, 1997). Secondly, with respect to the biochemistry of hypothalamic hamartomas, magnetic resonance spectroscopy has shown a reduction in the *N*-acetyl aspartic acid/creatine ratio in the area of the tumour itself but not in adjoining brain areas (Tasch *et al.*, 1998; Martin *et al.*, 2003). Although a decreased peak of *N*-acetyl aspartic acid is regarded as a sign of neuronal degeneration, it does not necessarily indicate pathological changes. It may merely reflect the variability of the spectral pattern between different anatomical formations due to the heterogeneity of their histomorphology. Thirdly, surgical removal of the tumour can reduce the incidence of seizures (Nishio *et al.*, 1994; Valdeuza *et al.*, 1994; Kuzniecky *et al.*, 1997; Parrent, 1999; Unger *et al.*, 2000).

It seems plausible that these tumours have excitatory effects, with abnormal electrical activity spreading rostrally and dorsally to areas in the neighbouring limbic system and caudally to the brainstem to produce the physiological and psychophysiological manifestations of the 'laugh attacks' (Kuzniecky *et al.*, 1997).

Fou rire prodromique

The *fou rire prodromique* (Féré, 1903) is a very rare condition in which unmotivated, inappropriate laughter occurs as the first symptom of cerebral ischaemia. This laughter, which seems to be utterly uncontrollable, may be followed by giggling (Wali, 1993) or crying (Badt, 1927), and is then replaced by more typical symptoms of a stroke: hemiparesis or aphasia, for example (Poeck, 1969). The laughter of *fou rire prodromique* has been described as 'loud and hearty' (Badt, 1927) or as of a 'chuckling' nature (Poeck, 1969). It can last up to 30 min (Wali, 1993). Lesions associated with *fou rire prodromique* have been found (i) at the base of the pons, bilaterally with no involvement of the tegmentum (Wali, 1993); (ii) in the left parahippocampal gyrus, the left posterolateral thalamus and adjacent parts of the internal

Table 1 Lesion localization in laughter due to neurological disease

	Voluntary facial paretic without pathological laughter	<i>Fou rire prodromique</i>	Gelastic epilepsy	Pathological laughter With voluntary paretic	Without voluntary paretic	Voluntary paretic unknown	Emotional paretic/aminia
Ventral brainstem	Trepel (1996) (<i>n</i> = 1)	Wali (1993) (<i>n</i> = 1)	Many cases, e.g. Valdueza (1994) Unger (2000) Munari (1995) Kuzniecky (1997) Georgakoulas (1998) Cascino (1993)	Bhatjiwale (2000) (<i>n</i> = 3) Cantu (1966) (<i>n</i> = 1) Lal (1992) (<i>n</i> = 1) Mouton (1994) (<i>n</i> = 1) Tei (1997) (<i>n</i> = 1)	Bhatjiwale (2000) (<i>n</i> = 1) Matsuoka (1993) (<i>n</i> = 1) Shafiqat (1998) (<i>n</i> = 1)	Kataoka (1997) (<i>n</i> = 3)	
Tegmental brainstem							Karmosh (1945) (<i>n</i> = 12)
Hypothalamus							
Frontal cortex	Bilateral opercular lesions, e.g. Foix (1926) Mateos (1995)	Garg (2000) (<i>n</i> = 1)	Arroyo (1993) (<i>n</i> = 1) Iannetti (1997) <i>n</i> = 1		Mendez (1999) (<i>n</i> = 1)		Hopf (1992) (<i>n</i> = 1)
Temporal cortex			Coria (2000) (<i>n</i> = 1)				
Striatocapsular	Husain (1997) (<i>n</i> = 1)				Ceccaldi (1994) (<i>n</i> = 3)		Hopf (1992) (<i>n</i> = 1)
Basal ganglia							e.g. Katsikitis (1991); Parkinson's disease (<i>n</i> = 21)
Corticobulbar motor tract				Nishimura (1990): chronic progressive spinobulbar spasticity (<i>n</i> = 1) Weller (1990): progressive supranuclear motor system degeneration (<i>n</i> = 1)	McCullagh (2000): ALS (<i>n</i> = 2)		

Table 1 Continued

	Voluntary facial paresis without pathological laughter	<i>Fou rire prodromique</i>	Gelastic epilepsy	Pathological laughter With voluntary paresis	Without voluntary paresis	Voluntary paresis unknown	Emotional paresis/amimia
Multiple regions	Gschwend (1978): occlusion L MCA with intact thalamostriatal arteries in angiography (<i>n</i> = 1) Hopf (1992): R MCA infarction/partial infarct corona radiate/large space occupying lesion lower frontoparietal white matter/MS with large R frontocentral white matter lesion (<i>n</i> = 4) Billeth (2000): L frontotemporoparietal incl. Wernicke's area + R anterior cerebral artery, in particular precentral gyrus (<i>n</i> = 1) Bingham (1998): bilateral perisylvian microgyria (<i>n</i> = 16)	Ceccaldi (1994): L parahippocampal gyrus + posterolateral thalamus + adjacent parts of the internal capsule, not hypothalamus, hippocampus, amygdala. (<i>n</i> = 1) Carel (1997): L lenticular and caudate nuclei + ant. insula. (<i>n</i> = 1) Lago (1998) L MCA territory (<i>n</i> = 1)		With voluntary paresis	Parvizi (2001): pontomesencephalic junction affecting L cerebral peduncle + midline basis pontis in middle to upper pons + R middle cerebellar peduncle + R middle cerebellar peduncle (<i>n</i> = 1)	unknown	Hopf (1992): Ant. + lat. thalamus, operculum/posterior or thalamic defect + opercular atrophy/Substantia nigra + insular atrophy + mesial temporal lobe defect (<i>n</i> = 3)
Other			Molinuevo (1998): smiling not laughter (<i>n</i> = 20 Parieto-occipital temporal (<i>n</i> = 3)				Hopf (1992): posterior thalamus (<i>n</i> = 2)

Only reports based on autopsy, angiography, CT or MRI scanning are included. L = left; R = right; MCA = middle cerebral artery; *n* = number of patients described; MS = multiple sclerosis; ALS = amyotrophic lateral sclerosis.

capsule, with no involvement of the hypothalamus, the hippocampus or the amygdala (Ceccaldi and Milandre, 1994); (iii) in the left lenticular and the caudate nuclei, with involvement of the anterior insula (Carel *et al.*, 1997); and (iv) in the area supplied by the right middle cerebral artery (Lago, 1998). It seems possible that laughter in these cases is caused by lesions of inhibitory neurons; these lesions would result in a releasing effect on brainstem areas generating laughter. A short excitatory effect of ischaemia, however, cannot be completely excluded (Nardone and Tezzon, 2002).

Although most reported *fou rire prodromique* phenomena herald vascular insults, there is also the report of a patient who, after three involuntary, uncontrollable laugh attacks, was diagnosed as having a glioblastoma multiforme in the area of the right prerolandic area (Arroyo *et al.*, 1997). From the data presented in this report, however, it is possible that the patient's symptoms were due to an epileptic seizure.

Pathological laughter due to other neurological disorders

Most publications on laughter in neurological disorders are concerned not with epileptic laughter or *fou rire prodromique* but with syndromes of inappropriate and uncontrollable smiling or laughter which occur chronically. Although other definitions of pathological laughter exist (Dark *et al.*, 1996; Shafqat *et al.*, 1998), the definition cited most often is that of Poeck (1969). According to his criteria, pathological laughter is laughter that arises: (i) in response to non-specific stimuli; (ii) in the absence of a corresponding change in affect; (iii) in the absence of voluntary control of the extent or duration of the episode; and (iv) in the absence of a corresponding change in mood lasting beyond the actual laughing.

Over the years, other terms for conditions in which pathological laughter occur have included 'involuntary laughter', 'pseudobulbar affect' (Allman, 1989; Mendez *et al.*, 1999), 'dysprosopia' (Eames and Papakostopoulos, 1990), 'sham mirth' (Martin, 1950), 'inappropriate', 'uncontrollable' and 'non-epileptic' laughter and 'emotional incontinence' (Kim and Choi-Kwon, 2000).

Wilson (1924), in a classical report, described several cases of pathological laughter, e.g. in a patient who, after two strokes, 'whatever the emotional stimulus, and however slight, ... at once began to laugh, and laugh loudly. Thus, on reading the war news he used at once to begin to smile, and the more serious and anxious the news, the more he laughed'. In another patient with 'disseminated sclerosis', Wilson reported that 'bursts of long, uncontrollable, but almost noiseless laughter took place at the veriest trifles'.

Pathological laughter is (usually; Dark *et al.*, 1996) inappropriate to the situation in which it arises. The patient can be aware of this inappropriateness but, nonetheless, powerless to control the laughter (Tanaka and Sumitsuji, 1991; Sloan *et al.*, 1992; Zeilig *et al.*, 1996). Such inappropriate laughter is often triggered by trivial stimuli (Shafqat

et al., 1998). In some cases, the stimulus may even have an emotional valence contrary to the emotional expression: patients can laugh in response to sad news or cry in response to a moving hand. Furthermore, the laughter can abruptly change to crying (Poeck, 1969). Pathological laughter is not, however, (usually) considered to be a component of 'emotional lability' (but see above and Seliger *et al.*, 1992; Dark *et al.*, 1996; Shafqat *et al.*, 1998; Mendez *et al.*, 1999) or 'emotional incontinence' (Kim and Choi-Kwon, 2000), but is generally understood to be a disorder of the motor concomitants of affective expression, which include respiratory, vasomotor, secretory and vocal components. Unfortunately, most case reports of pathological laughter are less exact than Wilson's in the descriptions of vocalizations and facial movements. The only neurophysiological study of pathological and normal laughter observed in the same subjects was one by Tanaka and Sumitsuji (1991), in six patients. They found that, in pathological laughter, there were additional contractions of the frontalis and supercillii muscles; i.e. the patients frowned at the same time as they were laughing, thus giving their faces 'strained' rather than 'released' appearances. It was not clear whether the forehead contractions were an attempt to control facial movements voluntarily or were due to a transition from smiling to laughter, which, in normal subjects, also often includes forehead contractions (Ruch and Ekman, 2001). Pathological laughter involves rhythmic clonic movements of the diaphragm that do not develop in a crescendo manner as normal laughter does, but abruptly.

Although pathological laughter can occur alone, it is also often observed as part of the more general syndrome of 'pathological laughter and crying' (Wilson, 1924; Poeck, 1969). There exist all grades of pathological laughter, from simple exaggerated emotional facial expressions (e.g. on the side of a volitional facial paresis due to stroke) to the loud laughter occurring in cases such as those described above. These differences are reflected in intensity scales developed by Sloan and colleagues and by Robinson and colleagues (Sloan *et al.*, 1992; Robinson *et al.*, 1993).

There is evidence that pathological laughter is influenced by serotonergic and dopaminergic transmission inasmuch as favourable treatment results have been reported in patients given selective serotonin reuptake blockers (Seliger *et al.*, 1992; Sloan *et al.*, 1992; McCullagh and Feinstein, 2000; Parvizi *et al.*, 2001) and levodopa (Udaka *et al.*, 1984). For theoretical reasons, it seems likely that the dopaminergic reward system and/or the cannabinoid system might be involved in the generation of positive emotional expressions.

Pathological laughter has been associated with brain lesions found in areas ranging from the frontal cortex and the pyramidal tracts to the ventral mesencephalon and the pons. The neurophysiological action of most of these lesions seems likely to be due to chronic disinhibition of the laughter-generating circuitry. In the following sections, studies of pathological laughter are collated on the basis of their anatomical locations.

Mesencephalon, pons, brainstem and cerebellum

In one of the older studies of pathological laughter (and crying), Wilson (1924) described patients with tumours in the tegmentum and upper pons. More recently, several reports of patients with predominantly ventrally located brainstem lesions producing mirthless laughter were published. Bhatjiwale and colleagues reported four patients with compression of the pons and medial medulla (from a ventral direction due to trigeminal neuromas) (Bhatjiwale *et al.*, 1996) and Mouton and colleagues and Tei and Sakamoto reported two patients with vascular insults, one located in the right cerebral peduncle, pons and caudal mesencephalon and the other in the ventromedial pons (Mouton *et al.*, 1994; Tei and Sakamoto, 1997). Similar symptoms were exhibited by a patient with a meningioma located ventromedial to the nuclei of the facial and acoustic nerves (associated with cranial nerve pareses) (Cantu, 1966), a patient with a pontomedullary glioma (Lal and Chandy, 1992), a patient with a clival chordoma (which put pressure on pontomesencephalic structures from a ventral direction) (Matsuoka *et al.*, 1993), and a patient with a petroclival meningioma (and a resulting distortion of the upper brainstem) (Shafiqat *et al.*, 1998).

In a study of 49 patients with paramedial pontine infarcts, on the basis of MRI and magnetic resonance angiography, Kataoka and colleagues differentiated among patients with infarcts in the (i) paramedial basal, (ii) paramedial basal tegmental and (iii) paramedial tegmental regions (Kataoka *et al.*, 1997). Only patients in the first group (three in number) exhibited pathological laughter. All of these patients also suffered from dysarthria and two of them from facial pareses.

Parvizi and colleagues described a patient with several lesions in the brainstem and cerebellum and suggested, as had Brown (1967), a modulating and coordinating role of the cerebellum in the production of laughter (Parvizi *et al.*, 2001). They argued that the cerebellum receives input from the 'limbic cortex' (ventromedial prefrontal, anterior cingulum, extended amygdala, ventral striatum), has efferent connections with the premotor and motor cortex, the hypothalamus, the periaqueductal grey (PAG) and the nuclei of the facial and vagus nerves, and thus is in an appropriate position to perform these functions. The lesions described in the case report by Parvizi and colleagues, however, were not located exclusively in the cerebellum (Parvizi *et al.*, 2001).

Striatocapsular regions

Despite the high incidence of striatocapsular infarcts, reports of pathological laughter in these patients have been relatively rare. Three patients with such infarcts (two large in area, one small) exhibited mirthless laugh attacks during speech, exertion or frustration that began and ended abruptly (Ceccaldi and Melandre, 1994). Other reports of pathological laughter in patients with infarcts in these areas include those of Kim and Choi-Kwon (2000), Poeck (1969) and Arlazaroff *et al.* (1998).

Frontal lesions

Mendez and colleagues described a patient suffering from more or less continual pathological laughter, apparently due to bifrontal medial encephalomalacia (after a ruptured aneurysm) with bifrontal hypometabolism in a PET examination (Mendez *et al.*, 1999). Another patient exhibiting pathological laughter due to a frontal brain lesion was described by Zeilig and colleagues (Zeilig *et al.*, 1996).

By using the Wisconsin card sorting test (a measure of prefrontal function), McCullagh and Feinstein (2000) compared the frontal lobe function of patients with amyotrophic lateral sclerosis who did or did not exhibit 'pathological laughter and crying' according to the criteria of Poeck (1969). With respect to the corticobulbar involvement of the disease, the patient groups were similar. Patients exhibiting pathological laughter and crying earned lower scores on the test, possibly indicating the presence of more pronounced prefrontal dysfunction in this group than in those without these symptoms.

Mixed patient groups

In the older report already mentioned, Wilson (1924) also described a varied collection of brain lesions associated with the syndrome of pathological laughter or crying; they included pseudobulbar palsy, single and double hemiplegia with 'thalamic syndrome', and tumours in the right internal capsule, the right subthalamic region, the tegmentum and the upper pons. In a study of 148 consecutive patients with 'single, unilateral strokes', Kim and Choi-Kwon (2000) found that 34% of the patients exhibited 'post stroke emotional incontinence – excessive or inappropriate laughing, crying or both'. From their descriptions it is unclear whether this laughter was accompanied by appropriate emotions. In this subgroup of 34%, insults to the lenticulocapsular area, the basal pons, the medial medulla and the cerebellum were found more often than in the remainder of the patients. It should be mentioned that this group of patients also had more severe motor disabilities than the remaining 66% and contained more females than males.

Pathological laughter has been reported to be a symptom in 10% of patients with multiple sclerosis, with an increase in incidence occurring parallel with disease progression (Feinstein *et al.*, 1997). As mentioned above, pathological laughter has also been observed in patients with amyotrophic lateral sclerosis (Gallagher, 1989; McCullagh and Feinstein, 2000), in patients suffering from chronic progressive spinobulbar spasticity (Nishimura *et al.*, 1990) and in patients with progressive supranuclear motor system degeneration (Weller *et al.*, 1990).

Sackeim and colleagues, in a review of 119 published cases, found a predominance of right-sided lesions associated with pathological laughter (Sackeim *et al.*, 1982). Other studies, however, have not confirmed this laterality (e.g. Kim and Choi-Kwa 2000).

In summary, mesencephalic or pontine lesions associated with pathological laughter were in the ventral areas of these structures. Pathological laughter as a result of frontal lesions or lesions in the striatocapsular area have been reported only rarely.

Dissociation of voluntary from emotionally driven laughter and smiling

Pareses of voluntary facial expressions can occur while emotionally driven facial expressions remain undisturbed. This condition has been named the 'Foix–Chavany–Marie syndrome', 'anterior opercular syndrome' or 'volitional facial paresis' (Hopf *et al.*, 1992). The reverse of this situation is also possible: a paresis of emotionally triggered facial muscles can occur while voluntarily controlled facial expressions remain intact, as in emotional facial paresis (Hopf *et al.*, 1992) and amimia (Karnosh, 1945).

Typical lesions producing volitional facial paresis lie bilaterally in the opercula and can occur either congenitally or, in the adult, as a result of vascular insults or tumours (Bingham *et al.*, 1998). In the Foix–Chavany–Marie syndrome, severe dysarthria and pareses of the distal cranial nerves are also present (Weller, 1993). Volitional facial pareses have also been observed in patients suffering from infarcts of the left middle cerebral artery (with sparing of the thalamostriatal branches) (Gschwend, 1978) or of the motor cortex (Hopf *et al.*, 1992), and from partial infarcts of the corona radiata (Hopf *et al.*, 1992). The condition has also been associated with lesions of the capsula interna (Husain, 1997), lesions of the paramedial pontine area without involvement of the tegmentum (Trepel *et al.*, 1996) and large space-occupying lesions in the frontoparietal white matter (Hopf *et al.*, 1992), and has been reported in a patient suffering from multiple sclerosis with large ventrocentral white matter lesions (Hopf *et al.*, 1992).

To summarize, all these lesions were located in premotor areas (eg. the frontal operculum) or along the course of the corticobulbar motor tracts. Not only volitional facial paresis but also pathological laughter can occur as a consequence of most of these lesions. When pathological laughter accompanied volitional facial paresis, the lesions responsible were generally multiple, subcortical and located in either the ventral mesencephalon or the pons. Obviously, however, not all patients with lesions of the corticobulbar motor tracts suffer from pathological laughter.

These later data suggest that there may be a gradual transition between volitional facial paresis and pathological laughter. Some patients with volitional facial paresis have been observed to produce stronger emotional expressions on the paretic side of their face than on the non-paretic side (Monrad-Krohn, 1924; Gschwend, 1978; Eblen *et al.*, 1992). Such exaggerated expressions might be included in the first stages of pathological laughter according to the rating of Sloan and colleagues (Sloan *et al.*, 1992).

Classic examples of emotional paresis are seen in patients with Parkinson's disease, some of whom, despite normal subjective emotionality, display faces that appear emotionless, although facial movements can be produced voluntarily (Monrad-Krohn, 1924). According to autopsies of several patients with reduced facial expressiveness (amimia), Karnosh (1945) reported lesions 'in the reticular portion of the pons, just above the facial nucleus'. He postulated, on the basis of other studies, that patients with emotional paresis (some of whom also exhibited voluntary facial paresis) had lesions 'more deeply seated and ... generally located in the thalamus and striatal structures'. Limitation of the syndrome to patients with lesions to the thalamus has, however, been contested by Hopf and colleagues on the basis of seven patients with emotional paresis due to a variety of lesions, only some of which involved the thalamus (Hopf *et al.*, 1992).

Laughter, mirth and brain stimulation

Over the past 20 years it has become a common practice to stimulate the surgically exposed surface of the brain electrically in an attempt to locate epileptogenic foci. In the course of these stimulations, laughter has sometimes been induced with or without concomitant feelings of exhilaration. The first report of such an occurrence was by Fish and colleagues (Fish *et al.*, 1993). Smiling was induced in two of 75 patients whose brains were stimulated. During these episodes of smiling, the brain was being stimulated either in the amygdala (in one patient) or in the frontal cortex (in the other). Unfortunately, apart from the locations of the regions being stimulated, no details regarding the nature of the elicited smiles were given. Similar incidents of elicited smiling were reported by Gordon and colleagues (Gordon *et al.*, 1996); two of their 106 consecutive patients exhibited laughter or smiling as their brains were being stimulated. These same patients were described more extensively by Arroyo and colleagues, who reported the production of mirth-associated laughter when the fusiform gyrus or the parahippocampal gyrus was being stimulated (Arroyo *et al.*, 1993). These patients reported that, during stimulation, 'the significance of things had been altered' and that everything was 'funny'. They also reported feelings of happiness and dizziness.

In two letters to scientific journals (Bejjani *et al.*, 1999; Kumar *et al.*, 1999) and in one article (Krack *et al.*, 2001), anecdotal reports of 'feelings of well-being' (some with laughter and hilarity) have been described during the stimulation of the subthalamic nucleus in six patients with Parkinson's disease. In one patient (with a hamartoma), stimulation of the hypothalamus produced laughter (Kuzniecky *et al.*, 1997). According to somewhat older sources, the induction of laughter has also been reported in association with electrical stimulation in the anterior cingulate cortex (Sem-Jacobsen, 1968) and in the globus pallidus (Hassler and Riechert, 1961). In the oldest report of intraoperatively induced laughter, the laughter was not

produced by electrical stimulation at all but rather by lightly touching the floor of the third ventricle during a brain operation (Foerster and Gagel, 1934).

Most recently, Fried and colleagues described the behaviour and subjective feelings of a young patient who, upon having her brain stimulated in the left superior frontal gyrus, began to laugh (Fried *et al.*, 1998). Stimulation of other brain areas in the immediate vicinity produced an arrest of speech and hand movements. The authors reported that the patient's laughter was associated with mirth. In a published BBC video of this stimulation, however, the patient herself said that she found the situation of having to laugh a strange one. 'It was not funny', she reported, 'but it was funny because I was laughing'. This comment of hers raises the question of whether the mirth that she reported was a direct result of the brain stimulation or of her observing herself laughing. It must remain an open question whether the stimulation had a direct excitatory effect on a hypothetical prefrontal laughter/mirth area or a local inhibitory effect that caused disinhibition of caudally located laughter-generating regions. Such an inhibition would be comparable to that which resulted in the cessation of the speech and hand movements which occurred during the stimulation of nearby areas.

To summarize these findings, although over half a century has passed since Penfield first stimulated the cortex during a brain operation, and although the technique of transcranial cortical magnetic stimulation has been widely applied as an alternative method of focal cortical stimulation, there have been few reports of induced laughter during these procedures. One possible reason for this is that laughter may be so complex a phenomenon that it cannot normally be stimulated from any single brain area but depends on the temporal coordination of several areas of activity and/or areas of inhibition, and the incidents reported above are merely artefacts of unnatural stimulations. Alternatively, it is possible that such laughter-initiating areas do exist, but that they have only rarely been stimulated, possibly due to their subcortical locations. It is also conceivable that high-frequency electrical stimulations, as they are performed in the search for epileptic foci, induce depolarization blocks that inhibit rather than induce normal functions.

Studies of non-human laughter-like vocalizations

Although humour-associated laughter seems to be a phenomenon unique to humans, there are behavioural patterns of emotionally evoked vocalizations in other primates and even in rats that bear similarities to social laughter. These patterns have also been induced by various forms of brain stimulation. Weinstein (1943) stimulated 22 macaques (*Macaca mulatta*) in areas of the diencephalon, midbrain, pons and medulla. While stimulating an area 0.5–2 mm from the mid-sagittal plane, dorsomesial to the inferior olive, he observed a 'facial-respiratory complex simulating laughter and consisting of retraction and elevation of the corners of the mouth, depression of the lower jaw, lowering of the base of the

tongue and uvula and cessation of respiration in the expiratory phase'. From these data he postulated a rubro-reticulo-olivary system as the final integrator of facial movement patterns. Jürgens (1998) suggested a more complex model based on emotional utterances in the squirrel monkey. These vocalizations had patterns of intonation similar to those of human laughter and were produced in situations similar to those in which humans laugh; e.g. while the monkeys were 'rejoicing'. This system consisted of four levels of control. (i) The anterior cingulum was seen as responsible for the voluntary production of the vocalizations. (ii) The hypothalamus, amygdala and medial thalamus were responsible for the animal's emotional states and thus for the effects of these states on the vocalizations (relatively long latency between stimulation and effect). (iii) The PAG was postulated to be a relay station with a relatively short latency between stimulation and vocalization. This region was seen to be responsible for coupling the call and the emotional state. (iv) The lateral pontine reticular formation (RF) and the medulla were thought to be primarily involved in the motor coordination of the vocalizations.

The degree to which the recently reported 'chirping' of rats (Panksepp, 2000) elicited by tickling is behaviourally homologous to laughter (a possibility the author suggests) will have to await further ethological evaluation.

The neuroanatomy of laughter

Taken together, these reports suggest that in the area of the mesencephalon and pons there is a functional division between those structures necessary for the formation of emotionally driven expressions on the one hand and of volitional, emotionally neutral, expressions on the other. Ventral lesions in these areas lead to pareses of volitionally created facial expression with either no damage to or exaggerated expression of emotionally driven expressions. Lesions in the area of the dorsal, tegmental structures lead to a muting of emotional expression.

For anatomical areas rostral to the mesencephalon, this division is not as clear: lesions of the basal ganglia or of the internal capsule, for example, can be associated with pathological laughter or pareses of volitional muscles or emotional pareses. With respect to lesions in the thalamus, only emotional pareses have been reported: there are no reports of pareses of volitional muscles and no reports of pathological laughter or crying. Pathological laughter, on the other hand (but not emotional pareses), has been associated with extensive frontal brain lesions, with lesions in the cerebellum and with degenerative diseases of the tracts running from the motor and premotor cortex to the brainstem.

Theories on the neuroanatomical basis of laughter must, of course, be consistent with results of the studies reviewed above. Although not the first to formulate a model for the functional anatomy of laughter, Wilson (1924) has greatly influenced the development of this field over the past decades. He pointed out that, in laughing (as well as in crying),

muscles involved in facial expression (as well as those involved in respiratory and vocal control) are implicated. He postulated a 'facio-respiratory co-ordination centre', probably located in the upper pons, and emphasized that the thalamus was not necessarily involved in the control of laughter, in contrast to the general consensus that had existed since the work of Nothnagel (1889).

On the basis of data obtained from studies with patients, Davison and Kelman (1939) suggested that the hypothalamus and other diencephalic nuclei, thalamic centres, the striatum and the globus pallidum were involved in the production of affective reactions. Martin (1950) was the first to emphasize the significance of the hypothalamus in these processes and postulated a centre for laughter in or near the hypothalamus (based on four patients, among whom one was investigated at autopsy). He coined the phrase 'sham mirth' (in analogy to sham rage) for emotional expressions manifested during, for example, gelastic epilepsy. Ironside (1956) spoke of 'bulbar automatisms of laughter'. Under normal conditions, such automatisms would have been under the control of orbito-frontal and temporal cortical areas via connections through the hypothalamus to the bulbar RF. He assumed that the hypothalamus was not a 'laugh centre' but rather that the laughter associated with lesions in this area was induced by lesions in connections to limbic and bulbar structures. Thus, 'abnormal laughter responses' could be initiated by lesions at three levels: (i) the level of the faciorespiratory bulbar nuclei and the suprasegmental motor tracts; (ii) the 'posterior diencephalic and limbic' level; and (iii) the 'anterior hypothalamic, frontal, temporal' level, where psychiatric disturbances, including those of mood and cognitive functions, presumably had their seat.

Poeck (1969) postulated (as Wilson had) a pontine 'coordination centre' for laughter. According to Poeck, however, pathological laughter would occur not simply as a result of pure pyramidal tract lesions, but would occur only when such lesions coexisted with subcortical disturbances in the corticoreticular tracts. Poeck contested the Wilsonian model with its voluntary and involuntary innervation and posited instead a brainstem centre that was under phasic and tonic control. Pathological laughter, then, could arise from any of four levels: (i) lesions of the internal capsule with involvement of the basal ganglia; (ii) lesions of the substantia nigra in connection with other extrapyramidal lesions; (iii) lesions of the caudal hypothalamus; and (iv) double-sided lesions of the pyramidal tract.

Brown (1967), with his primary interest in the physiology of emotional expression, focused on the brainstem, in particular the PAG and its connections with the RF. He suggested a synchronizing mechanism in the rostral midbrain responsible for coordinating expressions such as laughter, crying and manifestations of rage. He postulated, on the basis of data from patients and from animal experiments, that (i) the mesencephalic central grey matter played a central role as a relay station between descending limbic-diencephalic tracts and bulbar effector organs, integrating input from diverse

regions (hippocampus, entorhinal cortex, dorsomedial thalamus, lateral hypothalamus via the medial anterior bundle, ascending reticular and spinothalamic connections) and the ventral and paramedial RF by excitatory connections (connections that had been well documented in animal studies); (ii) in the RF, the appropriate pattern responsible for laughter (or crying, involving breathing, facial expression and vocalization) would be activated; and (iii) the mesencephalic central grey matter, via the annulo-olivary tract to the cerebellum, would exercise a modulating effect on all these expressions.

To summarize, nearly all authors agree that there must exist in the brainstem a final common pathway for laughter, integrating facial expression, respiration and autonomic reactions. There is good evidence that only dorsal mesencephalic lesions cause a diminution of facial emotional expressions, whereas ventral lesions lead to pathological laughter. The data cited from animal experiments, as well as the newer case reports summarized above, lend support to the notion that such a laughter-coordinating centre must lie in the dorsal area of the upper pontine mesencephalon and is connected to the PAG and the RF.

In the light of the multiple anatomical connections from the PAG and the RF to the most diverse cerebral regions, as demonstrated in animal experiments (Veazey *et al.*, 1982; Ter Horst *et al.*, 1991; Cowie and Holstege, 1992; Bandler and Keay, 1996) and in the patient data presented above, the postulation of rostral, hierarchically assembled pathways or centres above the PAG does not seem justified. On the contrary, it seems more likely that input from disparate regions of the brain (hypothalamus, frontal cortex, basal temporal cortex, basal ganglia, thalamus) may be sufficient to elicit the reaction pattern constituting laughter. A special role for either the hypothalamus or the frontomesencephalic tract/medial forebrain bundle is, however, likely in view of the data from patients with gelastic epilepsy due to hypothalamic hamartomas and from the animal experiments (Veazey *et al.*, 1982; Abrahamson and Moore, 2001). The possibility that the cerebellum has a role in the modulation and coordination of these processes must remain tentative. It seems possible, however, that, on the basis of its rich synaptic connections in normal humans, the cerebellum may well be involved in emotional expression.

We postulate that, during healthy emotional reactions (laughter, crying, frowning, etc.), the PAG and the upper RF receive excitatory input, in particular from the prefrontal or basal temporal cortex as well as from the basal ganglia and the hypothalamus. Figure 1 illustrates our notion of the network involved in the generation of laughter. We suggest that these reactions are influenced voluntarily by means of (probably primarily inhibitory) tracts running from the premotor and motor cortex, via the cerebral peduncles, to the ventral side of the brainstem. At present, however, it is utterly unclear how, at this level of the brain, these neuronal activities vary when they are associated with emotions (mirth, grief, surprise, etc.). Naturally, many facial expressions can

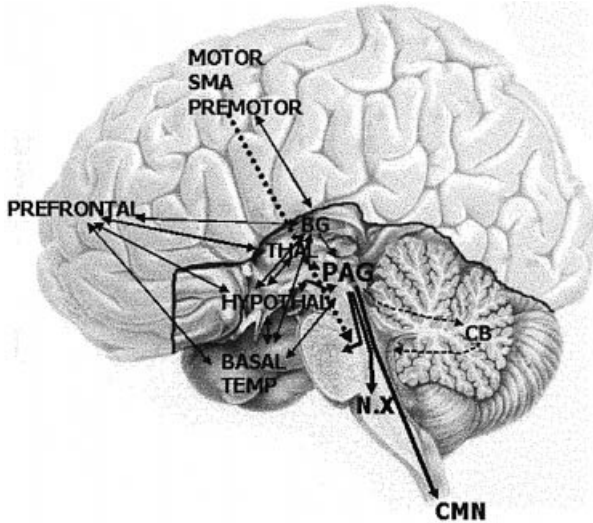


Fig. 1 The laughter network: regions involved in the generation of normal and pathological laughter. Note that in the mesencephalic and pontine regions the fibres from the PAG, which probably transmit the signal to laugh, are located dorsally/tegmentally, whereas the fibres from the frontal motor areas run ventrally, probably inhibiting facial emotional expressions. BASAL TEMP = basal temporal lobe including amygdala; CB = cerebellum; CMN = cervical motor neurons; BG = basal ganglia; HYPOTHAL = hypothalamus; MOTOR = motor area; N.X = vagal nerve nucleus; PREFRONTAL = medial and dorsolateral prefrontal cortex; PREMOTOR = premotor area; THAL = thalamus.

be formed voluntarily; it is, however, not possible for most people to imitate convincingly the genuine facial expressions of felt emotion. This is particularly difficult with laughter, or as Gowers (1887, cf. Ironside, 1956) formulated it, 'The will is needed not to effect it, but to restrain it'.

We thus propose that genuine, emotionally driven laughter is not normally initiated in the motor cortex but rather that, during such laughter, cortical frontal inhibition ceases. In this context, it is interesting that laughing gas, an *N*-methyl-D-aspartate antagonist, probably exerts its influence by inhibition of neurons in the premotor and motor cortex (Franks and Lieb, 1998). We consider the occurrence of pathological laughter to be the result of damage to this inhibitory system. Pathological laughter, then, would have a neural substrate of subcortical disinhibition similar to the disinhibition observed in patients with spasticity of the extremities or of the bladder, in which the micturition reflex can be triggered by normally inadequate stimuli. It further seems possible that, in patients with ventrally lying tumours of the brainstem, pressure-induced disruption of inhibitory tracts results in forced facial expressions.

Humour and the brain

Humour: overview

Reasons for the complexity of research on humour are legion. What was funny 20 years ago may not be funny today and the

meanings of such terms as 'humour', 'funny', 'mirth' and 'hilarity' vary not only with time but also among languages and cultures (Davies, 1998; Ruch, 1998). Stimuli which produce laughter are as protean as dress codes. Are tickling (Ramachandran, 1998) and contagious laughter (Carrell, 1997) manifestations of particular kinds of humour? Is humour a kind of perception or is humour 'something' that is produced? Or is it both? The reluctance of neuroscientists to enter such inchoate fields is understandable.

These fields have been entered, however, and it is encouraging to consider that the notions of laughter and humour are no more intractable now than crying and pain once were. Indeed, the latter pair of phenomena share important characteristics with humour and laughter. Crying and pain are also mixtures of subjectivity, neurology and poetry. Despite these confounds, however, so much has been learned about pain and its expressions over the past 100 years that a review of their neural correlates would occupy a small encyclopaedia.

Although operational definitions of 'laughter,' 'humour' and 'funny' have been formulated for individual studies, a broad consensus on their exact meanings has yet to be reached. This is not a trivial handicap: it is obvious that what one means by humour and laughter will influence what kinds of experiments one designs for their analysis. The relationships between the subjective feelings of an emotion (in this case, exhilaration) and its motor expressions (in this case, smiling and laughter) have been discussed for over a century (James, 1950) and continue to be the subject of lively discourse (Damasio, 2003).

There is a goodly number of theories on why things are funny. Inasmuch as all the experiments described below are based on only one of these theories, however—the incongruity theory of Kant (1972)—other theories, such as the superiority theory of Plato (1941) and Aristotle (1941) and the psychoanalytic theory of Sigmund Freud (1976), will not be discussed.

According to the incongruity theory, humour involves the perception of incongruity or paradox in a playful context (Forabosco, 1992). For something to be funny, two stages can be distinguished in the processing of humorous material (Suls, 1972). In the first stage, '... the perceiver finds his expectation about the text disconfirmed by the ending of the joke. ... In other words, the recipient encounters an incongruity—the punch-line. In the second stage, the perceiver engages in a form of problem-solving to find a cognitive rule which makes the punch-line follow from the main part of the joke and reconciles the incongruous parts'. Other researchers have called these stages 'surprise' and 'coherence' (Brownell *et al.*, 1983).

To some psychologists, however, these two stages are insufficient to account for differences between the perception of humour and a similar situation, the perception that a problem has been solved. It has been suggested that the two-step model should be expanded to include a third stage (Ruch and Hehl, 1998): that of detecting that what actually makes

sense (given the ability to perceive humour) is pleasant nonsense. If the processing of humour merely ended with the resolution of the incongruity, one would not know whether one had solved a problem (as in a riddle) or had experienced humour.

In the following, an attempt is made to dissect what happens when the elements of humour are presented to an observer. First of all, the perception of elements of humour can (or cannot) result in the feeling that something is funny. If they do not result in that feeling, then humour is not present in that situation. The responses to humour are by no means tied to jokes or joke-like constructions but rather can be induced by a variety of means (Ruch and Ekman, 2001). If the feeling of something's having been funny is generated, that transitory feeling, or McGhee's 'humour response' (McGhee, 1979), can then feed into an emotion (such as exhilaration, but alternatively into anger, fear, etc. depending on what the object of the humour was). The emotion with which the humour response is most often associated is labelled inconsistently as 'amusement', 'mirth', 'hilarity' or 'exhilaration' (the last of these designations corresponds to the Latin root of the term as a transient uplift into a cheerful state). The emotion then may influence a mood. The humour response can elicit a smile or laugh, but does not have to; it can even elicit a frown. These distinctions are important to bear in mind inasmuch as not everything that (i) contains the potential elements of humour is (ii) perceived as humorous and leads to (iii) exhilaration, (iv) the motor expression of laughter and (v) to an elevated mood. Each of these elements may have its own cerebral substrate.

It is, however, clear that, regardless of how these specific tasks are apportioned, the perception of humour is dependent on certain faculties of the brain, such as attention, working memory, mental flexibility, emotional evaluation, verbal abstraction and the feeling of positive emotions. Given these involvements, theory dictates that (at least) those regions of the brain associated with these processes should be active in the perception of humour.

Lesion studies

In the first reported attempt to associate what the authors called 'the perception of humour' with specific brain regions, 13 patients suffering from temporal lobe epilepsy (not of a gelastic nature) were tested psychologically (Ferguson *et al.*, 1969) with a battery of funny cartoons. It was found that in these patients, the ability to 'perceive humour' was disturbed, due to such relatively subtle psychological symptoms as 'inappropriate focus on irrelevant detail', 'integration difficulty', 'concreteness', 'egocentricity' and a 'paranoid attitude'. This was the first of several studies to point to the temporal lobes as structures essential for the appreciation of humour.

The first study framed within a hypothesis-based theory (comparing patients with right- and left-sided brain injuries and normal control subjects) was published in this journal in

1975 (Gardner *et al.*, 1975). Until then, scattered references to an alteration of the sense of humour among brain-injured patients could be found (Head, 1926; Isserlin, 1936; Weinstein, 1955; Luria, 1970; Critchley, 1970) but no experiments had been designed specifically to test whether damage to discrete areas of the brain might result in a disturbance of the patient's sense of humour. As predicted by their hypothesis, the group of patients with brain injuries in the study of Gardner and colleagues performed more poorly than did normal controls in distinguishing the funny from the non-funny cartoons (Gardner *et al.*, 1975). There were, however, no significant differences between results in patients with lesions in the left and right hemisphere in their global ability to perceive humour. Patients with right-hemisphere lesions, however, performed slightly better when there was a caption, indicating that they were probably helped by linguistic information.

Six years after the above study, Wapner and colleagues reported that patients with lesions of the non-dominant hemisphere exhibited abnormalities in their responses to humour (Wapner *et al.*, 1981). These deficits were interpreted as being based on the patients' impaired abilities to process the non-canonical and pragmatic dimensions of language. Two years later, Brownell and colleagues found that patients with defects in the right hemisphere were able to detect the necessary surprise element of a verbal joke's punch-line but were unable to discern which of several surprising endings of an 'experimental joke' were funny due to the ending's essential coherence with the body of the joke (Brownell *et al.*, 1983). These results showed that these patients either suffered from an inability to integrate content across parts of a narrative unit or were unable to deal with affectively laden materials. This either-or ambiguity was addressed in a study by Dagge and Hartje (1985) of patients with damage to the right hemisphere. Their impairments in understanding cartoons were more related to deficits in their visuoperceptive and cognitive capability than to their inability to identify the affective components of cartoons. In a study published the following year, Bihrlé and colleagues reported similar results with cartoons and verbal jokes, thus adding support to the hypothesis that the right hemisphere plays a special role in the processes required for the comprehension of humour regardless of the perceptual mode by which the humorous material is presented (Bihrlé *et al.*, 1986).

In 1999, Shammi and Stuss (1999) investigated 21 right-handed patients with single, focal brain lesions restricted to the frontal (right, left or bilateral) or non-frontal (right or left) regions. Patients with right frontal lesions showed the greatest deficits in the ability to distinguish humorous from non-humorous cartoons and were also reported to react with less physical or emotional responsiveness (laughter, smiling). The article concluded with the following statement: 'At the highest level, the integration of cognitive with affective information in the right frontal lobe is critical to the highest and most evolved human cognitive functions, such as self awareness and humour'.

Not only patients with localized lesions, but also patients with Parkinson's syndrome have been studied with respect to the perception of humour. Although impaired with respect to their spontaneous emotional expressions, they were able to detect the surprise element in humorous sketches as long as there was no additional cognitive deterioration (Benke *et al.*, 1998).

Surprise is an important element of many, if not all, forms of humour. Brazzelli and colleagues reported a patient with extensive prefrontal postherpetic lesions who showed, among other deficits, an inability to experience surprise (Brazzelli *et al.*, 1994). Neuroimaging studies (of normal subjects) also indicate a role of the prefrontal cortex (particularly on the right) and the anterior cingulate in the detection of surprising events during learning (Fletcher *et al.*, 1995), the perception of objects with unnatural colours (Zeki and Marini, 1998), and during discrepancy between visual and tactile perception (Fink *et al.*, 1999). So far, there has been no published study on surprise as such, i.e. surprise evoked by stimuli in which the emotional component of surprise was the main common characteristic.

Studies of humour in normal subjects

In a study of cortical electrical activity associated with humour information processing, Derks and colleagues reported a peak of activity in event-related potentials (ERPs) ~300 ms after hearing the punch-line of a joke (Derks *et al.*, 1997). This was followed by a general depolarization ~100 ms later. These two waves were suggested to parallel the two-stage cognitive model of humour processing (Suls, 1972; Forabosco, 1992). The results of this study also suggested that mood could influence humour processing: positive mood, compared with negative mood, was accompanied by greater differences in ERPs between jokes producing laughter and those producing no laughter. In a more recent study using ERPs, however, Coulson and Kutas (2001) were unable to differentiate between the elements of surprise and the subsequent coherence stage in healthy subjects as they read sentences, the last word of which made them either jokes or not. Although these two elements could not be shown to differ between the jokes and the non-jokes, the ERPs did differ in several respects depending on whether the subjects were good or poor comprehenders of jokes.

In two recent studies, functional MRI was used to demonstrate areas of blood oxygen level-dependent cerebral activity in normal subjects as they listened to jokes. In the first of these (Ozawa *et al.*, 2000), 10 subjects listened to a tape recording of three different genres of texts from within a functional MRI apparatus: jokes, a simple newspaper article, and a complicated philosophical text. Later, the subjects ranked the individual texts with respect to how funny each text was and how difficult each had been to understand. Consistent with the linguistic nature of the tasks, Wernicke's area and the transverse temporal gyri (bilaterally) were

activated in all subjects by all conditions. Sentences that the subjects rated as funny also induced activation in Broca's area and the middle frontal gyrus (possibly corresponding to syntactic processing and auditory working memory); those that were rated as difficult to understand were associated with activity in the left inferior parietal lobule (possibly corresponding to semantic processing) and the posterior part of the left superior temporal gyrus.

In the second study (Goel and Dolan, 2001), 14 subjects were presented with two types of jokes: phonological jokes (puns) and semantic jokes (which relied for their humour on factors other than simple language play). While they were in the functional MRI scanner, the subjects made judgements (recorded by a key-press) as to whether or not they found each story amusing; after scanning, the subjects reviewed the jokes and rated them on a funniness scale. Cortical activation associated with listening to the puns was found in the left posterior middle temporal gyrus and the left inferior frontal gyrus, whereas activity associated with listening to the semantic jokes was found in the left posterior middle temporal gyrus, the left posterior inferior temporal gyrus, the right posterior middle temporal gyrus and the cerebellum. Cerebral activity in the medial ventral prefrontal cortex covaried with the subject's post-scan ratings of joke funniness and, thus, may have been associated with the affective appreciation of humour.

In both of these studies, the perception of (joke-induced) humour was associated with blood oxygen level-dependent activity in the temporal regions and in the left frontal areas, but the areas in the two studies did not exactly match and areas of activity were described in the second study that were not described in the first. Neither study included controls for such confounding variables as attention or emotional facial reactions; thus, the presumption that humour was a cause of the observed activations may be premature.

Using PET, Iwase and colleagues studied subjects' facial reactions to humorous film clips (Iwase *et al.*, 2002). During humour-induced smiling or laughter (measured by EMG of facial muscles), a selective increase in regional cerebral blood flow (rCBF), compared with baseline, was found bilaterally in the subjects' supplementary motor areas (SMAs) and the left putamen. Humour-associated laughter/smiling, as opposed to voluntary smiling, was associated with increased rCBF in the visual association areas, left anterior temporal cortex, left uncus and orbitofrontal and medial prefrontal cortices, whereas voluntary smiling was associated with increased rCBF in the face area of the left primary motor cortex and bilateral SMA when compared with humorous smiling. In this paradigm, however, it was impossible to distinguish between rCBF related to the presence of humour and that related to the behavioural reactions.

In a study of facial reactions to pictures of faces expressing emotions (Wild *et al.*, 2003), activation of both basal temporal cortices, including the amygdalae, was observed when subjects generated smiles in response to pictures of smiling faces.

To summarize the results on humour and the brain, there is convincing evidence from studies of patients with brain lesions that the non-dominant hemisphere is necessary for the perception of humour and that its frontal areas are particularly critical (Gardner, 1975; Shammi and Stuss, 1999). When humour was being perceived in normal subjects, however, these areas were not shown to be particularly active (Ozawa *et al.*, 2000; Goel and Dolan, 2001; Iwase *et al.*, 2002). When laughter or mirth were induced electrophysiologically in patients with epilepsy (who were otherwise normal), the prefrontal cortex (Fried *et al.*, 1998) and the basal temporal lobes (Arroyo *et al.*, 1993) were involved. With respect to the latest imaging studies in normal subjects, cerebral areas associated with the processing of humour have included the middle frontal gyrus and Broca's area (Ozawa *et al.*, 2000); the medial ventral prefrontal cortex, the left inferior frontal gyrus, the left posterior middle and inferior temporal gyri, the right posterior middle temporal gyrus and the cerebellum (Goel and Dolan, 2001); and the orbitofrontal and medial prefrontal cortices bilaterally, SMA bilaterally, the visual association areas bilaterally, the left anterior temporal cortex, the left uncus and the left putamen (Iwase *et al.*, 2002).

Conclusion

The studies reviewed here describe particular facets of the brain's involvement in the production of laughter and in the perception of humour. As in the well-known story of the blind person surveying an elephant, each study describes a bit of truth about laughter, humour and the brain. However, it must be stated frankly that at the present time the description of the neural correlates of laughter and humour remains fragmentary.

Consistent with the studies described above would be a neural network in which frontal and temporal regions were involved in the perception of humour. These, in turn, would induce facial reactions and laughter mediated by dorsal brainstem regions. These reactions would be inhibited by the ventral brainstem, probably via frontal motor/premotor areas. Confirmation of the validity of such a network will, of course, have to await the results of further experiments.

Despite over 100 years of interest in the neurology of laughter, many questions remain. What similarities and what differences are there between normal laughter and the laughter of patients suffering from gelastic epilepsy, *fou rire prodromique*, etc.? Is the nature of pathological laughter dependent on the topography of lesions in the brainstem? What role does the cerebellum play in these expressions? What are the functional anatomical differences between laughter and crying? Are smiling and laughing the results of different degrees of activation in common structures or do they rely on basically different mechanisms?

With respect to humour, is there or is there not a 'final common pathway' at the end of the various kinds of things that are 'funny': verbal jokes, non-verbal cartoons, contagious laughter, tickling, laughing gas? Do the various forms

of humour (slapstick, ironic, aggressive, self effacing, etc.) have common neural networks? Do the stages of appreciating a joke involve discrete brain regions?

Hard neurological evidence can be collected only on the basis of increasingly refined theories regarding humour and laughter. Confounding variables, such as attention, emotional state and surprise, must be considered. The degree to which observed changes in the brain are due to laughter (mirthful or not) *per se* must be determined, as must the degree to which such changes are dependent upon the basic emotional trait characteristics of the experimental subject, and the influence of the subject's emotional state at the time of the experiment. Add to these factors other obvious confounds, such as the subject's age, sex, phase of the menstrual cycle, handedness, educational status and linguistic, national and ethnic affiliations, and it is clear that we are exploring the edge of a large and fascinating territory.

Acknowledgement

This work was supported by a grant from the Fortune programme of the medical faculty of the University of Tübingen to B.W. and F.A.R.

References

- Abrahamson EE, Moore RY. The posterior hypothalamic area: chemoarchitecture and afferent connections. *Brain Res* 2001; 889: 1–22.
- Allman P. Crying and laughing after brain damage: a confused nomenclature. *J Neurol Neurosurg Psychiatry* 1989; 52: 1439–40.
- Aristotle A. *Nicomachean ethics*. In: McKeon R, editor. *The basic works of Aristotle*. New York: Random House; 1941.
- Arlazaroff A, Mester R, Spivak B, Klein C, Toren P. Pathological laughter: common vs. unusual aetiology and presentation. *Isr J Psychiatry Relat Sci* 1998; 35: 184–9.
- Arroyo S, Lesser RP, Gordon B, Uematsu S, Hart J, Schwerdt P, et al. Mirth, laughter and gelastic seizures. *Brain* 1993; 116: 757–80.
- Arroyo S, Santamaria J, Sanmarti F, Lomena F, Catafau A, Casamitjana R, et al. Ictal laughter associated with paroxysmal hypothalamopituitary dysfunction. *Epilepsia* 1997; 38: 114–7.
- Askenasy J. The functions and dysfunctions of laughter. *J Gen Psychol* 1987; 114: 317–34.
- Assal G, Majdalani A, Gautier JC. Gelastic epilepsy. Probable diencephalic hamartoma. [French]. *Rev Neurol Paris* 1993; 149: 291–3.
- Bachorowski JA, Smoski MJ, Owen MJ. The acoustic features of human laughter. *J Acoust Soc Am* 2001; 110: 1581–97.
- Badt B. Lachen als erstes Symptom eines apoplektischen Insultes. *Z ges Neurol Psychiat* 1927; 110: 297–300.
- Bandler R, Keay KA. Columnar organization in the midbrain periaqueductal gray and the integration of emotional expression. *Prog Brain Res* 1996; 107: 285–300.

- BBC. Available from: <http://www.bbc.co.uk/science/horizon/beyondtrans.shtml>. Page 9: '... it was not so funny, but it was funny because I was laughing'.
- Bejjani BP, Damier P, Agid Y. Transient acute depression induced by high-frequency deep-brain stimulation. *New Engl J Med* 1999; 341: 1004.
- Benke T, Bosch S, Andree B. A study of emotional processing in Parkinson's disease. *Brain Cogn* 1998; 38: 36–52.
- Berkovic SF, Andermann F, Melanson D, Ethier R, Feindel W, Gloor P. Hypothalamic hamartomas and ictal laughter: evolution of a characteristic epileptic syndrome and diagnostic value of magnetic resonance imaging. *Ann Neurol* 1988; 23: 429–39.
- Berkovic SF, Kuzniecky RI, Andermann F. Human epileptogenesis and hypothalamic hamartomas: new lessons from an experiment of nature. *Epilepsia* 1997; 38: 1–3.
- Bhatjiwale MG, Goel A, Desai K. Pathological laughter as a presenting symptom of trigeminal neurinoma—case report. *Neurol Med Chir Tokyo* 1996; 36: 644–6.
- Bihrlé AM, Brownell HH, Powelson JA, Gardner H. Comprehension of humorous and nonhumorous materials by left and right brain-damaged patients. *Brain Cogn* 1986; 5: 399–411.
- Billeth R, Jorgler E, Baumhackl U. Bilateral anterior operculum syndrome. [German]. *Nervenarzt* 2000; 71: 651–4.
- Bingham PM, Parrish B, Chen SC, Canto-Moreira N, Zimmerman RA. Spectrum of disorders associated with enlarged sylvian fissures in infancy. *Neurology* 1998; 51: 1732–5.
- Brazzelli M, Colombo N, Della Sala S, Spinnler H. Sparing and impaired cognitive abilities after bilateral frontal damage. *Cortex* 1994; 30: 27–51.
- Brissaud E. *Leçons sur les maladies nerveuses*. Paris: Masson; 1895. p. 446–68.
- Brown JW. Physiology and phylogenesis of emotional expression. *Brain Res* 1967; 5: 1–14.
- Brownell HH, Michel D, Powelson J, Gardner H. Surprise but not coherence: sensitivity to verbal humor in right-hemisphere patients. *Brain Lang* 1983; 18: 20–7.
- Cantu RC. Importance of pathological laughing and/or crying as a sign of occurrence or recurrence of a tumor lying beneath the brainstem. *J Nerv Ment Dis* 1966; 143: 508–12.
- Carel C, Albucher JF, Manelfe C, Guiraud-Chaumeil B, Chollet F. Fou rire prodromique heralding a left internal carotid artery occlusion. *Stroke* 1997; 28: 2081–3.
- Carrell AT. Humor communities. *Humor* 1997; 10: 11–24.
- Cascino GD, Andermann F, Berkovic SF, Kuzniecky RI, Sharbrough FW, Keene DL, et al. Gelastic seizures and hypothalamic hamartomas: evaluation of patients undergoing chronic intracranial EEG monitoring and outcome of surgical treatment. *Neurology* 1993; 43: 747–50.
- Ceccaldi M, Milandre L. A transient fit of laughter as the inaugural symptom of capsular-thalamic infarction. *Neurology* 1994; 44: 1762.
- Cerullo A, Tinuper P, Provini F, Contin M, Rosati A, Marini C, et al. Autonomic and hormonal ictal changes in gelastic seizures from hypothalamic hamartomas. *Electroencephalogr Clin Neurophysiol* 1998; 107: 317–22.
- Coria F, Bahillo Marcos E, Moral Blanco M, Garcia Gutierrez P, Oritz Saenz de Santa Maria R. Late onset isolated gelastic epilepsy secondary to entrapment of the right temporal horn. *Neurologia* 2000; 15: 204–7.
- Coulson S, Kutas M. Getting it: human event-related brain response to jokes in good and poor comprehenders. *Neurosci Lett* 2001; 316: 71–4.
- Cowie RJ, Holstege G. Dorsal mesencephalic projections to pons, medulla, and spinal cord in the cat: limbic and non-limbic components. *J Comp Neurol* 1992; 319: 536–59.
- Critchley M. *Aphasiology and other aspects of language*. London: Edward Arnold; 1970. p. 159–73.
- Dagge M, Hartje W. Influence of contextual complexity on the processing of cartoons by patients with unilateral lesions. *Cortex* 1985; 21: 607–16.
- Damasio A. *Looking for Spinoza: joy, sorrow, and the human brain*. New York: Harcourt; 2003. p. 27–80.
- Dark FL, McGrath JJ, Ron MA. Pathological laughing and crying. *Aust N Z J Psychiatry* 1996; 30: 472–9.
- Darwin C. *The expression of the emotions in man and animals*. London: John Murray; 1872.
- Davies C. The dog that didn't bark in the night: a new sociological approach to the cross-cultural study of humor. In: Ruch W, editor. *The sense of humor*. Berlin: Mouton de Gruyter; 1998. p. 293–306.
- Davison C, Kelman H. Pathological laughter and crying. *Arch Neurol Psychiat* 1939; 42: 595–643.
- Derks P, Gillikon L, Bartolome DS, Bogart EH. Laughter and electroencephalographic activity. *Humor* 1997; 10: 283–98.
- Eames P, Papakostopoulos D. Crying and laughing after brain damage. *J Neurol Neurosurg Psychiatry* 1990; 53: 1111.
- Eblen F, Weller M, Dichgans J. Automatic–voluntary dissociation: an unusual facial paresis in a patient with probable multiple sclerosis. *Eur Arch Psychiatry Clin Neurosci* 1992; 242: 93–5.
- Ekman P. What we have learned by measuring facial behavior. In: Ekman P, Rosenberg EL, editors. *What the face reveals*. New York: Oxford University Press; 1997. p. 469–85.
- Ekman P, Davidson RJ, Friesen WV. The Duchenne smile: emotional expression and brain physiology: II. *J Pers Soc Psychol* 1990; 58: 342–53.
- Feinstein A, Feinstein K, Gray T, O'Connor P. Prevalence and neurobehavioral correlates of pathological laughing and crying in multiple sclerosis. *Arch Neurol* 1997; 54: 1116–21.
- Féré MC. Le fou rire prodromique. *Rev Neurol (Paris)* 1903; 11: 353–8.
- Ferguson SM, Schwartz ML, Rayport M. Perception of humor in patients with temporal lobe epilepsy: a cartoon test as an indicator of neuropsychological deficit. *Arch Gen Psychiatry* 1969; 21: 363–7.

- Fink GR, Marshall JC, Halligan PW, Frith CD, Driver J, Frackowiak RS, et al. The neural consequences of conflict between intention and the senses. *Brain* 1999; 122: 497–512.
- Fish DR, Gloor P, Quesney FL, Olivier A. Clinical responses to electrical brain stimulation of the temporal and frontal lobes in patients with epilepsy. Pathophysiological implications. *Brain* 1993; 116: 397–414.
- Fletcher PC, Frith CD, Grasby PM, Shallice T, Frackowiak RS, Dolan RJ. Brain systems for encoding and retrieval of auditory-verbal memory. An in vivo study in humans. *Brain* 1995; 118: 401–16.
- Foerster O, Gagel O. Ein Fall von Ependymcyste des III. Ventrikels: ein Beitrag zur Frage der Beziehungen psychischer Störungen zum Hirnstamm. *Z ges Neurol Psychiat* 1934; 149: 312–44.
- Foix C, Chavany JA, Marie J. Diplégie facio-linguo-masticatrice d'origine cortico-sous corticale sans paralysie des membres. *Rev Neurol (Paris)* 1926; 33: 214–9.
- Forabosco G. Cognitive aspects of the humor process: the concept of incongruity. *Humor* 1992; 5: 45–68.
- Franks NP, Lieb WR. A serious target for laughing gas. *Nat Med* 1998; 4: 383–4.
- Freud S. Jokes and their relation to the unconscious. Translated by J. Strachey. Harmondsworth: UK: Penguin; 1976.
- Fried I, Wilson CL, MacDonald KA, Behnke EJ. Electric current stimulates laughter. *Nature* 1998; 391: 650.
- Fry W. Humor and the brain: a selective review. *Humor* 2002; 15: 305–33.
- Gallagher JP. Pathologic laughter and crying in ALS: a search for their origin. *Acta Neurol Scand* 1989; 80: 114–7.
- Gardner H, Ling PK, Flamm L, Silverman J. Comprehension and appreciation of humorous material following brain damage. *Brain* 1975; 98: 399–412.
- Garg RK, Misra S, Verma R. Pathological laughter as heralding manifestation of left middle cerebral artery territory infarct: case report and review of literature. *Neurol India* 2000; 48: 388–90.
- Georgakoulis N, Vize C, Jenkins A, Singounas E. Hypothalamic hamartomas causing gelastic epilepsy: two cases and a review of the literature. *Seizure* 1998; 7: 167–71.
- Goel V, Dolan RJ. The functional anatomy of humor: segregating cognitive and affective components. *Nat Neurosci* 2001; 4: 237–8.
- Gordon B, Hart J Jr, Lesser RP, Arroyo S. Mapping cerebral sites for emotion and emotional expression with direct cortical electrical stimulation and seizure discharges. *Prog Brain Res* 1996; 107: 617–22.
- Gschwend J. The dissociated laughing and weeping in apoplectic insult. [German]. *Fortschr Neurol Psychiatr Grenzgeb* 1978; 46: 29–32.
- Hassler R, Riechert T. Wirkungen der Reizungen und Koagulationen in den Stammganglien bei stereotaktischen Hirnoperationen. *Nervenarzt* 1961; 32: 97–109.
- Head H. Aphasia and kindred disorders of speech, Vol. 2. New York: Macmillan; 1926. p. 375.
- Hopf HC, Muller-Forell W, Hopf NJ. Localization of emotional and volitional facial paresis. *Neurology* 1992; 42: 1918–23.
- Husain AM. Neurological picture. Mimetic smile. *J Neurol Neurosurg Psychiatry* 1997; 63: 144.
- Iannetti P, Spalice A, Raucci U, Atzei G, Cipriani C. Gelastic epilepsy: video-EEG, MRI and SPECT characteristics. *Brain Dev* 1997; 19: 418–21.
- Ironside R. Disorders of laughter due to brain lesions. *Brain* 1956; 79: 589–609.
- Isserlin M. Aphasie. In: Bumke O, Förster O, editors. *Handbuch der Neurologie*, Vol. 6. Berlin: Springer; 1936. p. 627–806
- Iwase M, Ouchi Y, Okada H, Yokoyama C, Nobezawa S, Yoshikawa E, et al. Neural substrates of human facial expression of pleasant emotion induced by comic films: a PET study. *Neuroimage* 2002; 17: 758–68.
- Jacome DE, McLain LW Jr, FitzGerald R. Postural reflex gelastic seizures. *Arch Neurol* 1980; 37: 249–51.
- James W. The principles of psychology. 3rd ed. New York: Dover; 1950.
- Jandolo B, Gessini L, Occhipinti E, Pompili A. Laughing and running fits as manifestation of early traumatic epilepsy. *Eur Neurol* 1977; 15: 177–82.
- Jürgens U. The squirrel monkey as an experimental model in the study of cerebral organization of emotional vocal utterances. *Eur Arch Psychiatry Neurol Sci* 1986; 236: 40–3.
- Jürgens U. Neuronal control of mammalian vocalization, with special reference to the squirrel monkey. *Naturwissenschaften* 1998; 85: 376–88.
- Kant I. Kant's Critique of judgement. Translated by J. H. Bernard. New York: Hafner; 1972.
- Karnosh LJ. Amimia or emotional paralysis of the face. *Dis Nerv Syst* 1945; 6: 106–8.
- Kataoka S, Hori A, Shirakawa T, Hirose G. Paramedian pontine infarction. Neurological/topographical correlation. *Stroke* 1997; 28: 809–15.
- Katsikitis M, Pilowsky I. A controlled quantitative study of facial expression in Parkinson's disease and depression. *J Nerv Ment Dis* 1991; 179: 683–8.
- Kim JS, Choi-Kwon KS. Poststroke depression and emotional incontinence: correlation with lesion location. *Neurology* 2000; 54: 1805–10.
- Krack P, Kumar R, Ardouin C, Dowsey PL, McVicker JM, Benabid AL, et al. Mirthful laughter induced by subthalamic nucleus stimulation. *Mov Disord* 2001; 16: 867–75.
- Kraemer M, Abrahamsson M, Sjöström A. The neonatal development of the light flash visual evoked potential. *Doc Ophthalmol* 1999; 99: 21–39.
- Kumar R, Krack P, Pollak P. Transient acute depression induced by

- high-frequency deep-brain stimulation. *New Engl J Med* 1999; 341: 1003–4.
- Kuzniecky R, Guthrie B, Mountz J, Bebin M, Faught E, Gilliam F, et al. Intrinsic epileptogenesis of hypothalamic hamartomas in gelastic epilepsy. *Ann Neurol* 1997; 42: 60–7.
- Laan L, den Boer AT, Hennekam R, Renier WO, Brouwer OF. Angelman syndrome in adulthood. *Am J Med Genet* 1996; 66: 356–60.
- Lago A. Fou rire prodromique and ischemic stroke. *Stroke* 1998; 29: 1067–8.
- Lal AP, Chandy MJ. Pathological laughter and brain stem glioma. *J Neurol Neurosurg Psychiatry* 1992; 55: 628–9.
- Luria AR. Traumatic aphasia. The Hague: Mouton; 1970. p. 223–5.
- Martin JP. Fits of laughter (sham mirth) in organic cerebral disease. *Brain* 1950; 70: 453–64.
- Martin R. Approaches to the sense of humor: a historical review. In: Ruch W, editor. *The sense of humor*. Berlin: Mouton de Gruyter; 1998. p. 16–60.
- Martin DD, Seeger U, Ranke MB, Grodd W. MR imaging and spectroscopy of a tuber cinereum hamartoma: a patient with growth hormone deficiency and hypogonadotropic hypogonadism. *AJNR Am J Neuroradiol*; 24: 1177–80.
- Mateos V, Salas-Puig J, Campos DM, Carrero V, Andermann F. Acquired bilateral opercular lesions or Foix–Chavany–Marie syndrome and eating epilepsy. *J Neurol Neurosurg Psychiatry* 1995; 59: 559–60.
- Matsuoka S, Yokota A, Yasukouchi H, Harada A, Kadoya C, Wada S, et al. Clival chordoma associated with pathological laughter. Case report. *J Neurosurg* 1993; 79: 428–33.
- McCullagh S, Feinstein A. Treatment of pathological affect: variability of response for laughter and crying. *J Neuropsychiatry Clin Neurosci* 2000; 12: 100–2.
- McGhee PE. *Humor: its origin and development*. San Francisco: W.H. Freeman; 1979.
- Mendez MF, Nakawatase TV, Brown CV. Involuntary laughter and inappropriate hilarity. *J Neuropsychiatry Clin Neurosci* 1999; 11: 253–8.
- Molinuevo JL, Arroyo S. Ictal smile. *Epilepsia* 1998; 39: 1357–60.
- Monrad-Krohn GH. On the dissociation of voluntary and emotional innervation in facial paresis of central origin. *Brain* 1924; 47: 22–35.
- Mouton P, Remy A, Cambion H. Spasmodic laughter caused by unilateral involvement of the brain stem. [French]. *Rev Neurol (Paris)* 1994; 150: 302–3.
- Munari C, Kahane P, Francione S, Hoffmann D, Tassi L, Cusmai R, et al. Role of the hypothalamic hamartoma in the genesis of gelastic fits (a video-stereo-EEG study). *Electroencephalogr Clin Neurophysiol* 1995; 95: 154–60.
- Nardone R, Tezzon F. Inhibitory and excitatory circuits of cerebral cortex after ischaemic stroke: prognostic value of the transcranial magnetic stimulation. *Electromyogr Clin Neurophysiol* 2002; 42: 131–6.
- Nishimura M, Tojima M, Suga M, Hirose K, Tanabe H. Chronic progressive spinobulbar spasticity with disturbance of voluntary eyelid closure. Report of a case with special reference to MRI and electrophysiological findings. *J Neurol Sci* 1990; 96: 183–90.
- Nishio S, Morioka T, Fukui M, Goto Y. Surgical treatment of intractable seizures due to hypothalamic hamartoma. *Epilepsia* 1994; 35: 514–9.
- Nothnagel H. Zur Diagnose der Sehhügelerkrankungen. *Z Klin Med* 1889; 16: 424–30.
- Ozawa F, Matsuo K, Kato C, Nakai T, Isoda H, Takehara Y, et al. The effects of listening comprehension of various genres of literature on response in the linguistic area: an fMRI study. *Neuroreport* 2000; 11: 1141–3.
- Panksepp J, Burgdorf J. 50-kHz chirping (laughter ?) in response to conditioned and unconditioned tickle-induced reward in rats: effects of social housing and genetic variables. *Behav Brain Res* 2000; 115: 25–38.
- Parent AG. Stereotactic radiofrequency ablation for the treatment of gelastic seizures associated with hypothalamic hamartoma. Case report. *J Neurosurg* 1999; 91: 881–4.
- Parvizi J, Anderson SW, Martin CO, Damasio H, Damasio AR. Pathological laughter and crying. A link to the cerebellum. *Brain* 2001; 124: 1708–19.
- Plato P. *Philebus*. Translated by J. C. B. Gosling. Oxford: Clarendon Press; 1941. p. 45–51.
- Poeck K. Pathophysiology of emotional disorders associated with brain damage. In: Vinken PJ, Bruyn GW, editors. *Handbook of clinical neurology*, Vol. 3. Amsterdam: Elsevier; 1969. p. 343–67.
- Poeck K. Pathological laughter and crying. In: Frederik S, editor. *Handbook of clinical neurology*, Vol 1. Amsterdam: Elsevier 1985. p. 219–225.
- Preuschhoff S. ‘Laughter’ and ‘smiling’ in macaques—an evolutionary perspective. Utrecht: University of Utrecht Press; 1995.
- Provine RR. *Laughter: a scientific investigation*. New York: Viking; 2000. p. 23–53, 158–62.
- Ramachandran VS, Blakeslee S. *Phantoms in the brain*. New York: William Morrow; 1998. p. 208.
- Robinson RG, Parikh RM, Lipsey JR, Starkstein SE, Price TR. Pathological laughing and crying following stroke: validation of a measurement scale and a double-blind treatment study. *Am J Psychiatry* 1993; 150: 286–93.
- Ruch W. Sense of humor: a new look at an old concept. In: Ruch W, editor. *The sense of humor*. Berlin: Mouton de Gruyter; 1998. p. 3–14.
- Ruch W and Hehl F-J. A two-mode model of humor appreciation: its relation to aesthetic appreciation and simplicity-complexity of personality. In: Ruch W (ed.), *The sense of humor: explorations of a personality characteristic*. Berlin: Mouton de Gruyter, 109–142.
- Ruch W, Ekman P. The expressive pattern of laughter. In: Kaszniak A, editor. *Emotion, qualia and consciousness*. Tokyo: World Scientific; 2001. p. 426–43.

- Sackeim HA, Greenberg MS, Weiman AL, Gur RC, Hungerbuhler JP, Geschwind N. Hemispheric asymmetry in the expression of positive and negative emotions. Neurologic evidence. *Arch Neurol* 1982; 39: 210–8.
- Seliger GM, Hornstein A, Flax J, Herbert J, Schroeder K. Fluoxetine improves emotional incontinence. *Brain Inj* 1992; 6: 267–70.
- Sem-Jacobsen CW. Depth-electrographic stimulation of the human brain and behavior: from fourteen years of studies and treatment of Parkinson's disease and mental disorders with implanted electrodes. American lecture series, publication No. 710. Springfield (IL): Charles C. Thomas; 1968.
- Shafqat S, Elkind MS, Chiocca EA, Takeoka M, Koroshetz WJ. Petroclival meningioma presenting with pathological laughter. *Neurology* 1998; 50: 1918–9.
- Shammi P, Stuss DT. Humour appreciation: a role of the right frontal lobe. *Brain* 1999; 122: 657–66.
- Sloan RL, Brown KW, Pentland B. Fluoxetine as a treatment for emotional lability after brain injury. *Brain Inj* 1992; 6: 315–9.
- Striano S, Meo R, Bilò L, Cirillo S, Nocerino C, Ruosi P, et al. Gelastic epilepsy: symptomatic and cryptogenic cases. *Epilepsia* 1999; 40: 294–302.
- Sturm JW, Andermann F, Berkovic SF. 'Pressure to laugh': an unusual epileptic symptom associated with small hypothalamic hamartomas. *Neurology* 2000; 54: 971–3.
- Suls JA. A two-stage model for the appreciation of jokes and cartoons. In: Goldstein JH, McGhee P, editors. *The psychology of humor: theoretical perspectives and empirical issues*. New York: Academic Press; 1972. p. 81–100.
- Tanaka M, Sumitsuji N. Electromyographic study of facial expressions during pathological laughing and crying. *Electromyogr Clin Neurophysiol* 1991; 31: 399–406.
- Tasch E, Cendes F, Li LM, Dubeau F, Montes J, Rosenblatt B, et al. Hypothalamic hamartomas and gelastic epilepsy: a spectroscopic study. *Neurology* 1998; 51: 1046–50.
- Tei H, Sakamoto Y. Pontine infarction due to basilar artery stenosis presenting as pathological laughter. *Neuroradiology* 1997; 39: 190–1.
- Ter Horst GJ, Copray JC, Liem RS, Van Willigen JD. Projections from the rostral parvocellular reticular formation to pontine and medullary nuclei in the rat: involvement in autonomic regulation and orofacial motor control. *Neuroscience* 1991; 40: 735–58.
- Tinuper P, Cerullo A, Rosati A, Cortelli P. Case of a child with gelastic seizures and hypothalamic hamartoma. *Epilepsia* 1997; 38: 1363–4.
- Trepel M, Weller M, Dichgans J, Petersen D. 1996. Voluntary facial palsy with a pontine lesion. *J Neurol Neurosurg Psychiatry* 1996; 61: 531–3.
- Udaka F, Yamao S, Nagata H, Nakamura S, Kameyama M. Pathologic laughing and crying treated with levodopa. *Arch Neurol* 1984; 41: 1095–6.
- Unger F, Schrottner O, Haselsberger K, Korner E, Ploier R, Pendl G. Gamma knife radiosurgery for hypothalamic hamartomas in patients with medically intractable epilepsy and precocious puberty. Report of two cases. *J Neurosurg* 2000; 92: 726–31.
- Valdueza JM, Cristante L, Dammann O, Bentele K, Vortmeyer A, Saeger W, et al. Hypothalamic hamartomas: with special reference to gelastic epilepsy and surgery. *Neurosurgery* 1994; 34: 949–58.
- Van Hoof JA. A comparative approach to the phylogeny of laughter and smiling. In: Hinde RA, editor. *Non-verbal communication*. London: Cambridge University Press; 1972. p. 209–41.
- Veazey RB, Amaral DG, Cowan WM. The morphology and connections of the posterior hypothalamus in the cynomolgus monkey (*Macaca fascicularis*). II. Efferent connections. *J Comp Neurol* 1982; 207: 135–56.
- Wali GM. 'Fou rire prodromique' heralding a brainstem stroke. *J Neurol Neurosurg Psychiatry* 1993; 56: 209–10.
- Wapner W, Hamby S, Gardner H. The role of the right hemisphere in the apprehension of complex linguistic materials. *Brain Lang* 1981; 14: 15–33.
- Weinstein EA, Gender MB. Integrated facial patterns elicited by stimulation of the brain stem. *Arch Neurol Psychiatr* 1943; 50: 34–42.
- Weinstein EA, Kahn RL. *Denial of illness*. Springfield (IL): Thomas; 1955.
- Weller M. Anterior opercular cortex lesions cause dissociated lower cranial nerve palsies and anarthria but no aphasia: Foix–Chavany–Marie syndrome and 'automatic voluntary dissociation' revisited. *J Neurol* 1993; 240: 199–208.
- Weller M, Poremba M, Dichgans J. Opercular syndrome without opercular lesions: Foix–Chavany–Marie syndrome in progressive supranuclear motor system degeneration. *Eur Arch Psychiatry Neurol Sci* 1990; 239: 370–2.
- Wild B, Erb M, Eyb M, Bartels M, Grodd W. Why are smiles contagious? An fMRI study of the interaction between perception of facial affect and facial movements. *Psychiatry Res* 2003; 123: 17–36.
- Wilson SAK. Some problems in neurology, No. II. Pathological laughing and crying. *J Neurol Psychopath* 1924; 4: 299–333.
- Zeilig G, Drubach DA, Katz-Zeilig M, Karatinos J. Pathological laughter and crying in patients with closed traumatic brain injury. *Brain Inj* 1996; 10: 591–7.
- Zeki S, Marini L. Three cortical stages of colour processing in the human brain. *Brain* 1998; 121: 1669–85.

*Received September 28, 2002. Revised February 17, 2003.
Second revision April 25, 2003. Accepted April 28, 2003*