



Year: 2008

Repeated and preemptive palliative radiotherapy of symptomatic hepatomegaly in a patient with advanced myelofibrosis

Riesterer, O ; Gmür, J ; Lütolf, U

Abstract: **BACKGROUND:** Patients with advanced myelofibrosis often suffer from symptomatic extramedullary hematopoiesis in spleen and/or liver. In case of drug-refractory disease splenomegaly is treated surgically, whereas hepatomegaly is palliated by radiotherapy (RT). **CASE REPORT:** A 56-year-old man with advanced and drug-refractory myelofibrosis suffered from extensive hepatomegaly with severe upper abdominal pain, satiety, weight loss, and fatigue 1.5 years after splenectomy. The patient was treated periodically with fractionated RT to the liver in order to obtain symptom control and to prevent severe symptom recurrence. **RESULTS:** After 2 Gy fractionated RT to a treatment field encompassing nearly the whole liver, symptoms improved and liver size decreased without severe side effects. This treatment regimen was successfully conducted 3 times in trimonthly intervals. Because symptoms recurred periodically, we then continued RT on a preemptive basis in monthly intervals and with single-dose irradiation. The patient responded well to 1 Gy preemptive single-dose RT to the liver, but not to 0.5 Gy single-dose partial liver irradiation. **CONCLUSION:** RT is effective in palliation of hepatomegaly in advanced myelofibrosis. Even preemptive RT can benefit selected patients with advanced disease and periodical recurrence of symptoms.

DOI: <https://doi.org/10.1159/000127399>

Posted at the Zurich Open Repository and Archive, University of Zurich

ZORA URL: <https://doi.org/10.5167/uzh-8636>

Journal Article

Published Version

Originally published at:

Riesterer, O; Gmür, J; Lütolf, U (2008). Repeated and preemptive palliative radiotherapy of symptomatic hepatomegaly in a patient with advanced myelofibrosis. *Onkologie*, 31(6):325-327.

DOI: <https://doi.org/10.1159/000127399>

Repeated and Preemptive Palliative Radiotherapy of Symptomatic Hepatomegaly in a Patient with Advanced Myelofibrosis

Oliver Riesterer^a Jürg Gmür^b Urs Lütolf^a

^a Department of Radiation Oncology, University Hospital Zurich,

^b Onkozentrum, Hirslanden, Klinik im Park, Zurich, Switzerland

Key Words

Myelofibrosis · Hepatomegaly · Radiotherapy

Summary

Background: Patients with advanced myelofibrosis often suffer from symptomatic extramedullary hematopoiesis in spleen and/or liver. In case of drug-refractory disease splenomegaly is treated surgically, whereas hepatomegaly is palliated by radiotherapy (RT). **Case Report:** A 56-year-old man with advanced and drug-refractory myelofibrosis suffered from extensive hepatomegaly with severe upper abdominal pain, satiety, weight loss, and fatigue 1.5 years after splenectomy. The patient was treated periodically with fractionated RT to the liver in order to obtain symptom control and to prevent severe symptom recurrence. **Results:** After 2 Gy fractionated RT to a treatment field encompassing nearly the whole liver, symptoms improved and liver size decreased without severe side effects. This treatment regimen was successfully conducted 3 times in trimonthly intervals. Because symptoms recurred periodically, we then continued RT on a preemptive basis in monthly intervals and with single-dose irradiation. The patient responded well to 1 Gy preemptive single-dose RT to the liver, but not to 0.5 Gy single-dose partial liver irradiation. **Conclusion:** RT is effective in palliation of hepatomegaly in advanced myelofibrosis. Even preemptive RT can benefit selected patients with advanced disease and periodical recurrence of symptoms.

Schlüsselwörter

Osteomyelofibrose · Hepatomegalie · Radiotherapie

Zusammenfassung

Hintergrund: Patienten mit fortgeschrittener Osteomyelofibrose leiden oft unter symptomatischer extramedullärer Blutbildung in Milz und/oder Leber. Bei medikamentenresistenter Erkrankung wird die Splenomegalie chirurgisch behandelt, während Patienten mit Hepatomegalie palliativ bestrahlt werden. **Fallbericht:** Ein 56 Jahre alter Mann mit fortgeschrittener und medikamentenresistenter Osteomyelofibrose litt 1,5 Jahre nach Splenektomie unter ausgeprägter Hepatomegalie mit Oberbauschmerzen, Sättigungsgefühl, Gewichtsverlust und Abgeschlagenheit. Der Patient erhielt eine periodische fraktionierte Leberbestrahlung zur Symptomkontrolle und um einem Rezidiv schwerer Symptome vorzubeugen. **Ergebnisse:** Nach 2 Gy fraktionierter Radiotherapie der Leber besserten sich die Symptome, und die Leber wurde kleiner. Es traten keine schweren Nebenwirkungen auf. Dieses Therapieschema wurde dreimal in dreimonatlichen Abständen erfolgreich durchgeführt. Da die Symptome periodisch wiederkehrten, führten wir die Radiotherapie (RT) im Folgenden auf präemptiver Basis fort, mit 1 Gy und 0,5 Gy Einzeldosen in einmonatlichen Abständen. Der Patient sprach gut auf 1 Gy präemptive RT der Leber an, nicht aber auf 0,5 Gy Teilleberbestrahlung. **Schlussfolgerung:** Die RT ist wirksam in der Palliation der Hepatomegalie bei fortgeschrittener Osteomyelofibrose. Sogar eine präemptive RT kann einzelnen Patienten mit fortgeschrittener Erkrankung und periodischem Auftreten von Symptomen nützen.

Introduction

Myelofibrosis with myeloid metaplasia (MMM) is a myeloproliferative disorder in which an as yet unidentified stem cell defect leads to cytopenia, bone marrow fibrosis, and extramedullary hematopoiesis (EMH) [1]. Allogenic stem cell transplantation is the only therapy that has been shown to cause remissions in MMM, however, depends on the availability of a human leukocyte antigen matching donor. In many patients management of MMM is palliative and focuses on optimizing cytopenia and symptoms through medication, splenectomy, and palliative radiotherapy (RT) [2, 3]. Radiation is used in patients with drug-refractory MMM to treat symptomatic EMH, which can induce organomegaly of spleen or liver, spinal cord compression, ascites, and/or pleural effusion. Organomegaly of the spleen and/or the liver causes pain, satiety, weight loss, portal hypertension, and profound fatigue. Removal of the enlarged spleen in patients with drug-refractory MMM was shown to decrease plasma volume and improve anemia [2]. Since the publication of this report many patients with drug-refractory MMM receive splenectomy. In contrast, hepatomegaly is still the domain of palliative RT. In a recent report 14 patients with drug-refractory MMM received palliative RT to the liver with symptomatic relief after 86% of treatments [4]. Here we report a patient with drug-refractory MMM and hepatomegaly, who received not only 3 palliative courses of RT within 6 months, but in addition 4 preemptive courses of RT in monthly intervals with different fractionated and single doses of RT and different field sizes.

Case Report

The 57-year-old patient first presented in 2000 when he suffered from weight loss, fatigue, and cytopenia. Examination of bone marrow aspirate suggested a myeloproliferative syndrome, most likely myeloid metaplasia with myelofibrosis. Allogenic stem cell transplantation could not be performed because of lack of an appropriate donor. For 2 years the disease was controlled by palliative medication with hydroxyurea without need of blood transfusions. Thereafter the patient suffered from rapidly increasing left upper abdominal pain, weight loss, and exacerbated cytopenias with repetitive epistaxis. Clinical examination revealed extensive splenomegaly. Thereupon a giant spleen was removed with a weight of 2,935 g (6.47 lb). In the following months the patient's general condition, body weight, and cytopenia improved. The disease remained stable for 1.5 years until the next deterioration with upper abdominal pain, breathlessness in supine position, satiety, reduced meal quantities with subsequent nausea and vomitus, diarrhea, and again progressive weight loss. The patient now needed periodical blood transfusions to compensate for anemia. Clinically a giant liver was palpated with liver size extending from the diaphragm to the right iliac crest; the most likely explanation for this was EMH relocation to the liver. The patient was referred to our radiation oncology department for palliative RT of the liver. The first treatment course of RT was delivered with opposed anterior and posterior fields, a beam energy of 6 MV and a total dose of 2 Gy in 4 fractions. Irradiation was delivered twice a week in order to be able to stop RT ahead of schedule in case of extensive hematological toxicity. The treatment field was determined clinically as area of intense abdominal distension and comprised nearly

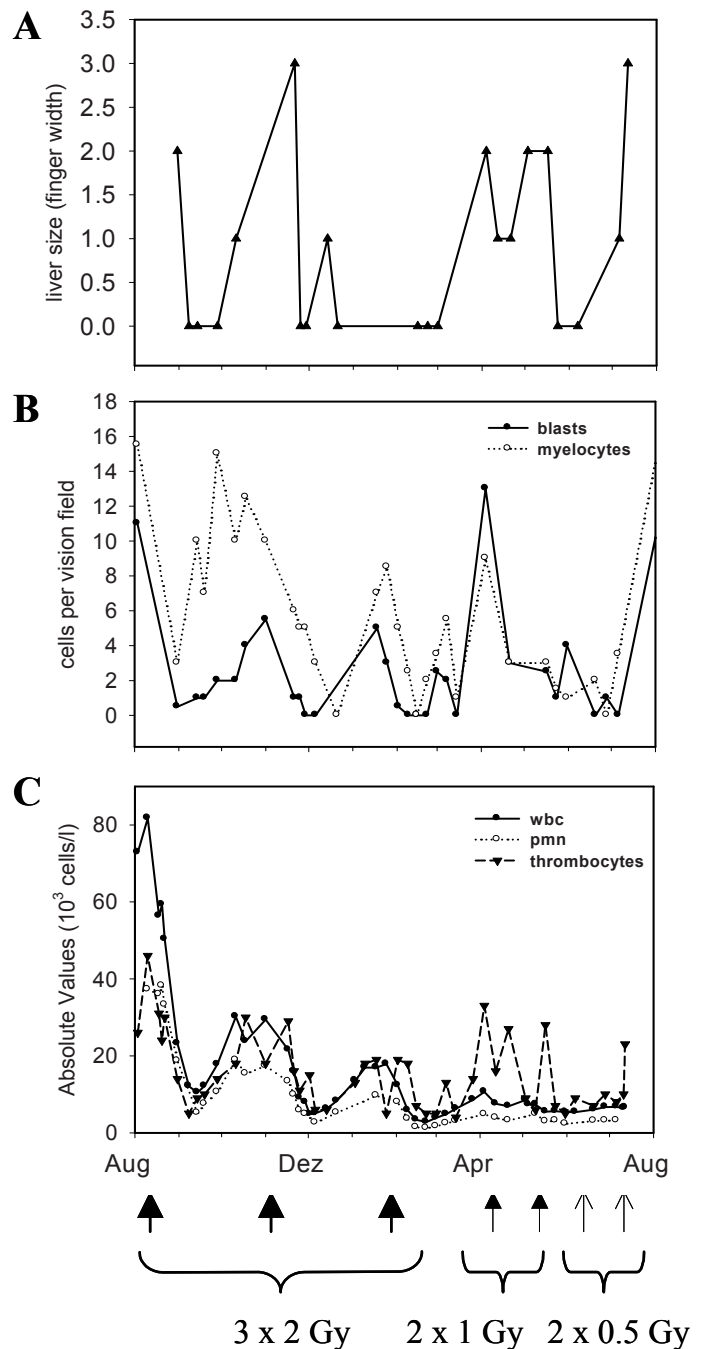


Fig. 1. Correlation of morphological and hematological response. **A** Liver size was determined as finger width below umbilicus. No initial liver size was recorded before third fractionated treatment course with 2 Gy. **B** Absolute values of blasts and myelocytes per visual field as counted by light microscopy. **C** Absolute values (10^3 cells/l) of white blood cells (wbc), thrombocytes, and premature neutrophils (pmn) as determined by automated blood cell count.

the whole liver from the diaphragm to the iliac crest. Abdominal pain and tension already improved during RT, and improvement lasted for 4 to 5 weeks. Liver size clearly diminished as measured by the same experienced investigator in finger width below umbilicus (fig. 1 A). Treatment was well tolerated. No additional red blood cell transfusion was necessary during or shortly after treatment beyond the biweekly blood transfusions that

the patient needed for symptomatic treatment of anemia at that time. Expected hematological side effects of RT were a short-term decrease of white blood cells, immature blood cells, and thrombocytes (fig. 1 C). Of note, apart of the short-term radiation-induced effects, the mature blood cell count gradually decreased during the observation period, reflecting increasing bone marrow depletion in the course of the disease. Because of weak epistaxis platelets were substituted 11 days after the last fraction. Differentiation of immature blood cells revealed a drop of blastocytes and myelocytes indicative for response of EMH in the liver to RT (fig. 1 B), whereas myelomonocytes responded less (data not shown). We repeated fractionated RT with 2 Gy in 4 fractions after 3 and 6 months because of recurrent abdominal symptoms that clinically correlated with increased liver size. Again the patient experienced good symptomatic and morphologic treatment responses with objective reduction of liver size (fig. 1 A). Because symptoms recurred periodically, aggravated rapidly and even seemed to accelerate, we then decided to continue RT on a preemptive basis. RT was continued with 0.5–1 Gy single doses in monthly intervals when symptoms were still modest. The first preemptive single dose of 1 Gy was given to the same treatment field, whereas the second 1 Gy single dose one month later was focused on the upper part of the liver close to the diaphragm where the patient had the discomfort. Both preemptive treatments were tolerated well and induced satisfactory subjective and morphological responses. We then reduced the radiation single dose to 0.5 Gy for the subsequent 2 treatments and again only performed partial liver irradiation with focus on areas of discomfort. After the first 0.5 Gy single dose the patient experienced only a minimal and short-lasting improvement, whereas the second 0.5 Gy single dose did not have any palliative effect at all and did not reduce liver size (fig. 1 A). However, because in the latter situation we reduced dose and treatment field together we can not determine which of the two factors had more impact on treatment response. A few weeks after the last liver irradiation, the patient developed leg palsy and urinary dysfunction due to an infiltrative process in the cervical spine. He recovered after palliative RT to the brain and cervical spine with 5×3 Gy. Shortly thereafter, he became refractory to thrombocyte substitution and died from cerebral hemorrhage.

Discussion

RT is effective for palliation of symptomatic EMH in MMM. In small series of patients palliative doses of RT (15–30 Gy) divided into multiple fractions successfully reversed spinal cord compression [5], while comparatively low doses are adequate in the treatment of EMH-associated pleural (1–2 Gy) [6] or peritoneal (10–12 Gy) [7] effusion. Abdominal pain and discomfort due to hepatomegaly may occur in advanced MMM after splenectomy because EMH relocates from the

spleen into the liver. Tefferi et al. [4] reported a symptomatic response rate of 86% after palliative RT to the liver in a group of 14 patients. Because some of these patients had splenomegaly and/or ascites in addition to hepatomegaly, they were treated with a broad range of radiation doses (0.5–10 Gy) and treatment fields. Of note, the doses given by us (0.5–2 Gy) compare to the medium dose given by Tefferi et al. (1.5 Gy). In our case we did not intend to cover the whole liver volume, presuming that a partial volume reduction would be clinically sufficient. In fact, the treatment field employed by us (diaphragm to iliac crest) compares to the upper abdominal field described by Tefferi et al. for patients without ascites. The total dose of 9 Gy given to our patient is far below the tolerance of liver tissue (TD 5/5 approx. 30 Gy) and/or adjacent organs within the treatment field. Nevertheless, for preemptive treatments we first reduced dose and then field size because we did not want to completely eradicate hematopoiesis in liver and lumbar spine in the situation of advanced bone marrow depletion. We report for the first time consecutive preemptive liver irradiation in a patient with advanced MMM in order to prevent recurrence of severe symptoms. In addition, in contrast to Tefferi et al. [4] who treated a heterogeneous group of patients with a wide range of treatment schedules and treatment fields, we observed a correlation between dose and treatment field on the one hand and clinical, morphological, and hematological response on the other hand in a single patient. The patient treated by us benefited from total doses of 1–2 Gy to the liver in contrast to 0.5 Gy partial liver irradiation. RT induced a decrease of immature blood cells indicating that it was indeed EMH that was targeted by RT in the liver. Mature and immature blood cell counts correlated with clinical and morphological response indicating a potential role of these markers as response marker.

The optimal time point to start palliative treatment is crucial in the management of palliative patients. The decision for treatment, among other factors, depends on the severity of symptoms and the expected side effects. With this report we demonstrate that repeated palliative RT of the liver is a simple and effective treatment option for palliation of hepatomegaly in advanced myelodysplasia. Further, in case of good response, even early preemptive liver irradiation may be beneficial in selected patients.

References

- 1 Tefferi A: Pathogenesis of myelofibrosis with myeloid metaplasia. *J Clin Oncol* 2005;23:8520–8530.
- 2 Tefferi A, Mesa RA, Nagorney DM, Schroeder G, Silverstein MN: Splenectomy in myelofibrosis with myeloid metaplasia: a single-institution experience with 223 patients. *Blood* 2000;95:2226–2233.
- 3 Mesa RA, Barosi G, Cervantes F, Reilly JT, Tefferi A: Myelofibrosis with myeloid metaplasia: disease overview and non-transplant treatment options. *Best Pract Res Clin Haematol* 2006;19:495–517.
- 4 Tefferi A, Jiménez T, Gray LA, Mesa RA, Chen MG: Radiation therapy for symptomatic hepatomegaly in myelofibrosis with myeloid metaplasia. *Eur J Haematol* 2001;66:37–42.
- 5 De Klippel N, Dehou MF, Bourgain C, Schots R, De Keyser J, Ebinger G: Progressive paraparesis due to thoracic extramedullary hematopoiesis in myelofibrosis. *J Neurosurg* 1993;79:125–127.
- 6 Bartlett RP, Greipp PR, Tefferi A, Cupps RE, Mullan BP, Trastek VF: Extramedullary hematopoiesis manifesting as a symptomatic pleural effusion. *Mayo Clin Proc* 1995;70:1161–1164.
- 7 Liote F, Yeni P, Teillet-Thiebaud F, Barge J, Devars Du Mayne JF, Flamant Y, Molas G, Carbon C: Ascites revealing peritoneal and hepatic extramedullary hematopoiesis with peliosis in agnogenic myeloid metaplasia: case report and review of the literature. *Am J Med* 1991;90:111–117.