



**University of  
Zurich**<sup>UZH</sup>

**Zurich Open Repository and  
Archive**

University of Zurich  
University Library  
Strickhofstrasse 39  
CH-8057 Zurich  
[www.zora.uzh.ch](http://www.zora.uzh.ch)

---

Year: 2013

---

## **A well-preserved culprit**

Maurer, Florian P ; Maggio, Ewerton M ; Roth, Thomas N ; Kuster, Stefan P ; Bloemberg, Guido V

DOI: <https://doi.org/10.1093/cid/cis914>

Posted at the Zurich Open Repository and Archive, University of Zurich

ZORA URL: <https://doi.org/10.5167/uzh-93011>

Journal Article

Published Version

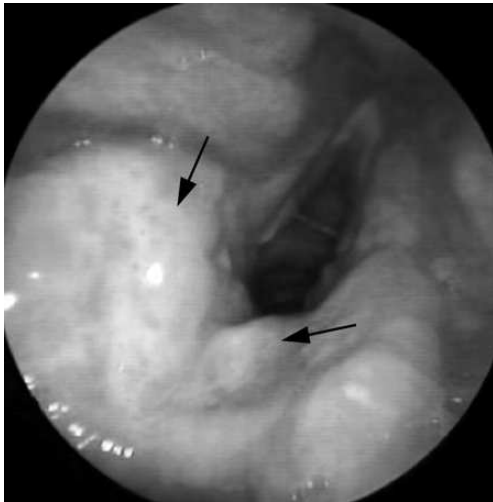
Originally published at:

Maurer, Florian P; Maggio, Ewerton M; Roth, Thomas N; Kuster, Stefan P; Bloemberg, Guido V (2013). A well-preserved culprit. *Clinical Infectious Diseases*, 56(5):747-748.

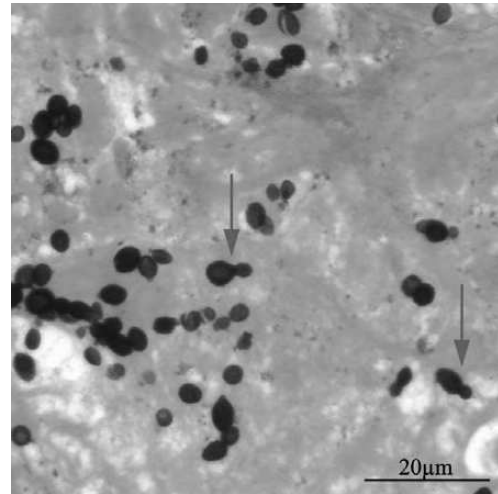
DOI: <https://doi.org/10.1093/cid/cis914>

## A Well-Preserved Culprit

(See page 704 for the Photo Quiz.)



**Figure 1.** Yellowish, edematous mucosal changes in the interarytenoid region involving the posterior part of the vocal cords (arrows). Along with Addison's disease, mucous membrane lesions are a characteristic manifestation of *H. capsulatum* infection.



**Figure 2.** Grocott–Gomori methenamine silver stain (magnification ×400) showing blastoconidia of *H. capsulatum* and the typical narrow-necked budding (arrows).

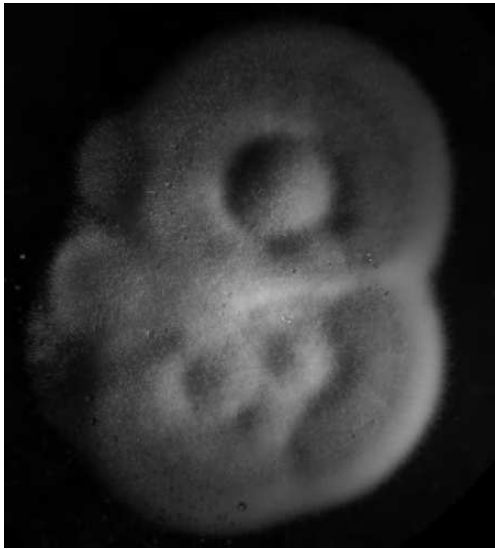Diagnosis: reactivated, disseminated histoplasmosis.

Histological examination of laryngeal biopsy specimens showed the presence of budding yeast cells (Figures 1 and 2). Based on this observation, laryngeal histoplasmosis with underlying iatrogenic hypercortisolism, steroid-induced hypertension, and diabetes mellitus was suspected. Histopathological reexamination of the adrenal glands, which had been removed in 1996, also raised suspicion of adrenal histoplasmosis instead of the previously suspected culture-negative tuberculosis. The presence of *Histoplasma capsulatum* in both the laryngeal and adrenal gland tissues was demonstrated by broad-spectrum polymerase chain reaction (PCR) targeting the fungal internal transcribed spacer (ITS) region, followed by sequence homology analysis of the PCR product [1]. *H. capsulatum* genotyping using 4 targets of sufficient intraspecies variability (*arf*, *h-anti*, *ole*, and *tub1*) [2, 3] provided proof that reactivation, not reinfection, took place. Interestingly, tests for specific antibodies remained negative twice, but *H. capsulatum* antigen detection from a urine sample obtained

after 2 weeks of antifungal therapy was positive. After 6 weeks of incubation, *H. capsulatum* was also cultivated from the patient's urine (Figure 3).

Treatment with itraconazole was initiated according to the current Infectious Diseases Society of America guidelines [4]. The hoarseness disappeared almost completely, but hospitalization became necessary due to progressive asthenia. Cranial computed tomography (CT) scan was not indicative of cerebral histoplasmosis, but CT scans of the chest and abdomen suggested bilateral pulmonary involvement. The patient, who always had sufficient capacity of discernment, chose to discontinue any treatment, including hydrocortisone substitution, and died from hypocortisolism 2 months after the diagnosis of disseminated histoplasmosis was made. The development of diabetes mellitus and immunological changes as a result of advancing age may have contributed to the reemergence of the pathogen 15 years after the initial manifestation.

Only <1% of individuals infected with *H. capsulatum* develop symptomatic disease. The severity of symptoms depends on the degree of exposure and the immune status of



**Figure 3.** White to buff-brown mould form of *H. capsulatum* grown at 25°C on Sabouraud's dextrose agar. Large numbers of infectious conidia may be released by the mere lifting of the culture plate lid.

the host, and can range anywhere from mild pulmonary affection to severe disseminated disease. Disseminated disease mostly occurs in patients with impaired cell-mediated immunity [5]. In this context, it is remarkable that invasive fungal infections are not consistently recognized in patients treated with immunosuppressants like corticosteroids and tumor necrosis factor- $\alpha$  blockers [6, 7].

Disseminated histoplasmosis can affect every organ system. Involvement of mucous membrane tissue in combination with Addison's disease due to the destruction of both adrenal glands are particularly indicative of histoplasmosis compared to other systemic mycoses. Reactivation of a silent focus can occur decades after the initial exposure [6, 8].

*H. capsulatum* is highly prevalent in the central and southeastern parts of the United States as well as in Central and South America and parts of Africa. However, our case shows that, due to increasing international travel activity, infection needs to be ruled out in a wide variety of clinical scenarios, not only within endemic regions. In addition to traditional diagnostic techniques (histopathology, serology, and culture), broad-spectrum PCR targeting the fungal ITS region is a valuable tool for the detection of this potentially fatal pathogen, not least in settings where reliable histopathological identification may be difficult to obtain.

## Notes

**Acknowledgments.** We thank the technicians at the Institute of Medical Microbiology for their technical support.

**Financial support.** This work was supported in part by the University of Zürich.

**Potential conflicts of interest.** All authors: No reported conflicts.

All authors have submitted the ICMJE Form for Disclosure of Potential Conflicts of Interest. Conflicts that the editors consider relevant to the content of the manuscript have been disclosed.

**Florian P. Maurer,<sup>1</sup> Ewerton Marques Maggio,<sup>2</sup> Thomas N. Roth,<sup>3</sup> Stefan P. Kuster,<sup>4</sup> and Guido V. Bloemberg<sup>1</sup>**

Institutes of <sup>1</sup>Medical Microbiology and <sup>2</sup>Surgical Pathology, Divisions of <sup>3</sup>Otorhinolaryngology, and <sup>4</sup>Infectious Diseases and Hospital Epidemiology, University Hospital Zürich, Switzerland

## References

1. Ciardo DE, Schar G, Altwegg M, Bottger EC, Bosshard PP. Identification of moulds in the diagnostic laboratory—an algorithm implementing molecular and phenotypic methods. *Diagn Microbiol Infect Dis* 2007; 59:49–60.
2. Kasuga T, Taylor JW, White TJ. Phylogenetic relationships of varieties and geographical groups of the human pathogenic fungus *Histoplasma capsulatum* Darling. *J Clin Microbiol* 1999; 37:653–63.
3. Kasuga T, White TJ, Koenig G, et al. Phylogeography of the fungal pathogen *Histoplasma capsulatum*. *Mol Ecol* 2003; 12:3383–401.
4. Wheat LJ, Freifeld AG, Kleiman MB, et al. Clinical practice guidelines for the management of patients with histoplasmosis: 2007 update by the Infectious Diseases Society of America. *Clin Infect Dis* 2007; 45:807–25.
5. Schnizlein-Bick C, Durkin M, Kohler S, et al. Effects of CD4 and CD8 T lymphocyte depletion on the course of histoplasmosis following pulmonary challenge. *Med Mycol* 2003; 41:189–97.
6. Kauffman CA. Histoplasmosis: a clinical and laboratory update. *Clin Microbiol Rev* 2007; 20:115–32.
7. Administration USFaD. Information for healthcare professionals: Cimzia (certolizumab pegol), Enbrel (etanercept), Humira (adalimumab) and Remicade (infliximab). Available at: <http://www.fda.gov/Drugs/DrugSafety/PostmarketDrugSafetyInformationforPatientsandProviders/ucm124185.htm>. Accessed 22 June.
8. Brandt ME, Warnock DW. Histoplasma, Blastomyces, Coccidioides, and other dimorphic fungi causing systemic mycoses. In: Mandell G, Bennett J, Dolin R, eds. *Mandell, Douglas, and Bennett's principles and practice of infectious diseases*. 9 ed. Vol. 2. Elsevier Science, 2007: 1857–73.

Correspondence: Florian P. Maurer, MD, Institute of Medical Microbiology, University of Zürich, Gloriastr. 30/32, 8006 Zürich, Switzerland (florian.maurer@imm.uzh.ch).

**Clinical Infectious Diseases** 2013;56(5):747–8

© The Author 2013. Published by Oxford University Press on behalf of the Infectious Diseases Society of America. All rights reserved. For Permissions, please e-mail: journals.permissions@oup.com.

DOI: 10.1093/cid/cis914