



**University of
Zurich**^{UZH}

**Zurich Open Repository and
Archive**

University of Zurich
University Library
Strickhofstrasse 39
CH-8057 Zurich
www.zora.uzh.ch

Year: 2023

Soft tissue augmentation with a volume-stable collagen matrix or an autogenous connective tissue graft at implant sites: Five-year results of a randomized controlled trial post implant loading

Thoma, Daniel S ; Gasser, Thomas J W ; Hämmerle, Christoph H F ; Strauss, Franz J ; Jung, Ronald E

DOI: <https://doi.org/10.1002/JPER.22-0226>

Posted at the Zurich Open Repository and Archive, University of Zurich

ZORA URL: <https://doi.org/10.5167/uzh-228488>

Journal Article

Published Version



The following work is licensed under a Creative Commons: Attribution 4.0 International (CC BY 4.0) License.

Originally published at:

Thoma, Daniel S; Gasser, Thomas J W; Hämmerle, Christoph H F; Strauss, Franz J; Jung, Ronald E (2023). Soft tissue augmentation with a volume-stable collagen matrix or an autogenous connective tissue graft at implant sites: Five-year results of a randomized controlled trial post implant loading. *Journal of Periodontology*, 94(2):230-243.

DOI: <https://doi.org/10.1002/JPER.22-0226>



HUMAN RANDOMIZED CONTROLLED TRIAL

Soft tissue augmentation with a volume-stable collagen matrix or an autogenous connective tissue graft at implant sites: Five-year results of a randomized controlled trial post implant loading

Daniel S. Thoma | Thomas J. W. Gasser | Christoph H. F. Hämmerle |
Franz J. Strauss | Ronald E. Jung

Clinic of Reconstructive Dentistry, Center of Dental Medicine, University of Zurich, Zurich, Switzerland

Correspondence

Daniel S. Thoma, Clinic of Reconstructive Dentistry, Center of Dental Medicine, University of Zurich, Plattenstrasse 11, CH-8032 Zurich, Switzerland.
Email: daniel.thoma@zzm.uzh.ch

German Clinical Trials
Register: DRKS00017484

Funding information

Geistlich Pharma AG, Wolhusen, Switzerland; Clinic of Reconstructive Dentistry, Center of Dental Medicine; University of Zurich, Switzerland

Abstract

Background: Interventions to augment the mucosal thickness around dental implants are indicated to optimize esthetics and maintain peri-implant health. However, there is a lack of clinical data on the long-term performance of soft tissue substitutes, such as volume-stable collagen matrix (VCMX), compared to autogenous grafts, such as subepithelial connective tissue grafts (SCTGs). This randomized controlled trial aimed to assess 5-year data on clinical and radiographic outcomes at implant sites previously augmented with VCMX or SCTG.

Methods: Twenty patients were randomly assigned for soft tissue augmentation with VCMX or SCTG at single implant sites. Following abutment connection, final restorations were inserted (baseline; BL) and patients were reexamined up to 5 years (FU-5). Measurements included clinical data, marginal bone levels, mucosal thickness, and ridge contour changes. Nonparametric tests and estimates were applied for the statistical analysis.

Results: The median buccal mucosal thickness increased by 0.3 mm (Q1: -0.8; Q3: 1.0) in the VCMX group ($P = 0.656$) and 0.3 mm (Q1: 0.0; Q3: 1.0) in the SCTG group ($P = 0.188$) between BL and FU-5 (intergroup $P = 0.752$), while the ridge contour decreased by a median of -0.3 mm (-0.9; -0.1) ($P = 0.078$) for VCMX and -0.3 mm (-0.4; -0.2) ($P = 0.039$) for SCTG (intergroup $P = 0.817$). Peri-implant health was maintained in both groups with stable clinical and radiographic outcomes and without significant differences between the treatments.

Conclusion: Despite the limited power and considerable dropout rate in the present study, soft tissue augmentation at implant sites with either VCMX or

This is an open access article under the terms of the [Creative Commons Attribution](https://creativecommons.org/licenses/by/4.0/) License, which permits use, distribution and reproduction in any medium, provided the original work is properly cited.

© 2022 The Authors. *Journal of Periodontology* published by Wiley Periodicals LLC on behalf of American Academy of Periodontology.



SCTG resulted in similar stable peri-implant tissues, favorable esthetics, and clinically negligible contour changes at 5 years post loading.

KEYWORDS

collagen matrix, dental implants, esthetic, oral surgical procedures, tissue transplantation

1 | INTRODUCTION

Interventions to augment the mucosal thickness at implant sites are routinely performed to maintain peri-implant health and to enhance the esthetic outcomes.¹⁻³ Various time points have been suggested to perform the soft tissue grafting procedures including prior to or concomitant with implant placement, during the healing phase of the implant, and even post insertion of the final restorations.⁴

Mucosal thickness augmentation has several benefits: (i) over the short-term (early healing phase), reestablishment of the convex ridge contour, as soft tissue grafting may be responsible for up to 40% of the final volume⁵; and (ii) in the long-run, the maintenance of peri-implant health indicated by reduced probing depths, plaque levels, and bleeding scores, as well as stable marginal bone levels or minimal marginal bone changes.⁶⁻⁸ Furthermore, mucosal thickness augmentation can mask the tissue discoloration caused by metallic abutments when the peri-implant mucosal thickness is thin (<2 mm),^{9,10} thereby improving the esthetic outcome.¹¹ In addition, soft tissue augmentation appears to favor the stability of the mucosal margin.^{12,13}

Current scientific data recommends the use of autogenous subepithelial connective tissue grafts (SCTGs) as the grafting material of choice for mucosal thickness augmentation.^{14,15} SCTGs have demonstrated favorable outcomes, primarily by improving soft tissue esthetics at implant sites.^{16,17} It should be noted that the use of an SCTG is inevitably accompanied by increased morbidity, as it requires an additional harvesting procedure¹⁸ and the tissue availability is limited. Arguably, the best treatment may not necessarily be the one that shows the highest efficacy in randomized clinical trials, but the one that fits with the patients' values and preferences.^{19,20} Consequently, greater reliance is placed on patients' preferences—the so-called patient reported-outcome measures (PROMS), which are becoming crucial for the selection of the intervention.²¹⁻²³ Therefore, soft tissue substitutes of various origins have been introduced and evaluated in a plethora of pre-clinical and clinical studies.²²⁻²⁵ Short-term data on these soft tissue substitutes appear promising as patient morbidity decreases compared to autogenous soft tissue grafts.^{22,24,26} However, and despite these promising findings, there is a

lack of long-term data using this type of substitute for soft tissue augmentation at implant sites. This is clinically relevant, as reliance on long-term data is a decisive factor for decision-making in daily practice.

The aim of the present study was, therefore, to assess the mucosal thickness, esthetics, peri-implant health, as well as ridge contour changes and patient evaluations (i.e., PROMs) of implant sites previously subjected to soft tissue augmentation with either a tissue substitute (a volume-stable collagen matrix, VCMX) or an SCTG 5 years after insertion of final restorations.

2 | MATERIALS AND METHODS

2.1 | Study design

The present study was designed as a non-interventional follow-up of patients previously enrolled in a randomized controlled clinical trial (RCT) performed according to ISO Standard 14155:2011 (“Clinical Investigation of medical devices for human patients”), along with appendices VIII and X of the Medical Device Directive 93/42/EFC and the Declaration of Helsinki, 2004.²⁷ Following approval by the local ethics committee (KEK_ZH-Nr 2012-0226), patients were recalled at the Clinic of Reconstructive Dentistry in Zürich, Switzerland, between November 2012 and May 2020. The reporting of the present trial follows the guidelines of the CONSORT statement²⁸ and was registered in the German Clinical Trials Register: DRKS00017484.

2.2 | Inclusion criteria

The specific inclusion criteria were as follows:

1. Patients with a volume deficiency at single-tooth implant sites enrolled in the previous RCT²⁷ and reexamined annually up to 5 years post insertion of final restorations
2. Final restoration inserted at the implant site
3. Ability to fully understand the nature of the proposed non-interventional long-term follow-up study and the ability to sign the informed consent form



2.3 | Exclusion criteria

Any of the following constituted grounds for exclusion from the study:

1. Newly developed disease interfering with soft tissue regeneration (e.g., diabetes)
2. Second soft tissue augmentation since completion of the previous study²⁷
3. Severe trauma to the implant site
4. Patients not willing to participate in the 5-year follow-up examination

2.4 | Clinical procedures

Twenty implants were placed in 20 patients with single-tooth gaps. During the healing phase (submerged healing), patients were treated with a soft tissue grafting procedure to augment the mucosal thickness. Using a sealed envelope with the assignment contained for either of two treatment modalities, patients were randomized to the VCMX¹ and SCTG groups.

Sulcular incisions were made around the neighboring teeth, followed by a straight incision connecting the palatal line angles of the two neighboring teeth, and the elevation of a full thickness flap on top of the ridge crest. A split thickness flap was then prepared by a sharp dissection using a blade, leaving the periosteum intact on the buccal aspect. Subsequently, the split-thickness flap on the buccal side was extended resulting in a pouch larger than the expected size of the VCMX or SCTG. Additional periosteal releasing incisions were made to allow a tension-free wound closure.

In the VCMX group, the matrix with an initial dimension of 15 mm × 20 mm × 6 mm was trimmed according to the needs at the recipient site (desired volume).

In the SCTG group, following a single incision technique, an autogenous connective tissue graft was harvested from the palate.

For both groups, the grafts were positioned into the pouch and sutured to the palatal flap. Primary tension-free wound closure was obtained with a horizontal mattress and single interrupted sutures.² Sutures were removed 7–10 days later, following abutment connection.

Three months later, impressions were taken, and subsequently, final restorations were inserted. All patients were then enrolled in individual maintenance programs at the Clinic of Reconstructive Dentistry with regular dental check-ups and dental hygienist appointments.

2.5 | Baseline and follow-up examinations

Follow-up examinations were scheduled at 2 weeks after insertion of the final restorations (baseline; BL), again at 6 months, and then yearly up to 5 years (FU-5). All examinations were performed by a blinded examiner not involved in the previous RCT and unaware of the therapy the patients had received. The maintenance recalls were tailored according to each patient, ranging from 3 to 6 months.

2.6 | Outcome measures

2.6.1 | Primary outcome measure: mucosal thickness

The mucosal thickness was assessed using an endodontic file (K-File 31/15)³ inserted 1 mm apical of the mucosal margin on the buccal side of the implant restorations with the help of an individualized stent. Changes in mucosal thickness over time (BL to FU-5) were considered as the primary outcome. Ridge contour stability was considered with changes <0.5 mm.²⁹

2.6.2 | Secondary outcome measures

Ridge contour changes

At all follow-up examinations, dental impressions of the implant sites and the two neighboring teeth were taken using an A-silicone impression material,⁴ and casts were poured and scanned with a lab scanner to obtain a stereolithography (STL) file. The respective STL files were processed with a digital imaging software program.⁵ A region of interest (ROI) was defined with a trapezoid shape: the coronal border was 1 mm apical of the mucosal margin; the apical border was located at the mucogingival junction; the mesial and distal borders were at a distance of 1 mm from the neighboring teeth (Figures 1 and 2). Due to inter-individual anatomical differences between the sites, the ROI varied between patients, but was kept consistent for all follow-up time points. STL files of the various time points (BL, 6 months, 1 year, 3 years, 5 years) were superimposed applying a best-fit algorithm on the surfaces of the surrounding structures (neighboring teeth). The software then calculated the mean distance between the surfaces within the ROI in mm.

¹ Geistlich Fibro-Gide, Geistlich Pharma AG, Wolhusen, Switzerland.

² Gore Tex 5-0, W.L. Gore & Associates, Inc., Flagstaff, Arizona, USA.

³ Dentsply Maillefer, Tulsa, Oklahoma, USA.

⁴ President, Coltene/Whaledent, Altstätten, Switzerland.

⁵ SMOP, Swissmeda AG, Zurich, Switzerland.

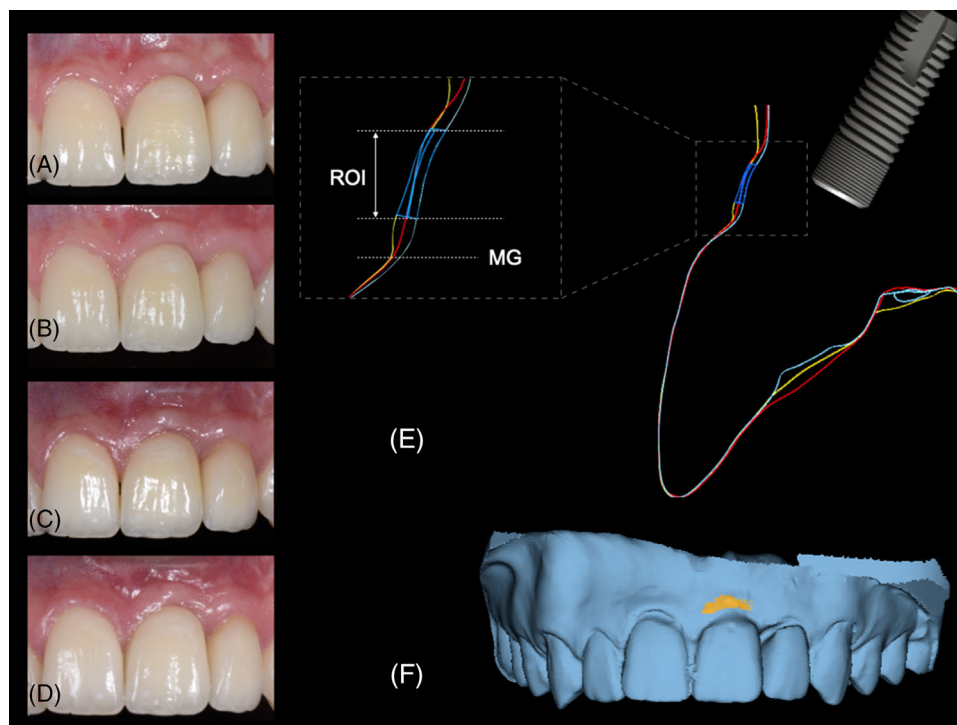


FIGURE 1 Representative case of the volume-stable collagen matrix group. (A) Clinical situation at baseline after the delivery of an implant-supported restoration in position 21. (B) Clinical situation at 1-year follow-up. (C) Clinical situation at 3 years of follow-up. (D) Clinical situation at 5 years of follow-up. (E) Cross-section view through superimposed stereolithography (STL) files, with the yellow line representing the baseline STL, the red line as the STL at 3 years and the light blue line at 5 years of follow-up. (F) Three-dimensional view at 5 years of follow-up with the corresponding region of interest (ROI) delineated in orange. MG = margo mucosae

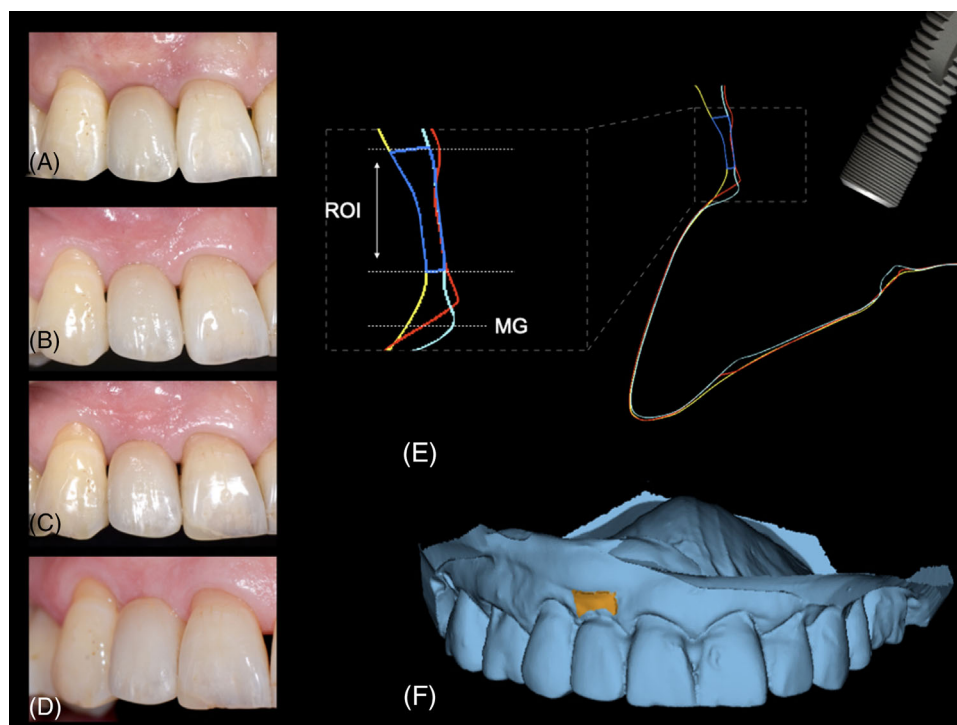


FIGURE 2 Representative case of the subepithelial connective tissue graft group. (A) Clinical situation at baseline after the delivery of an implant-supported restoration in position 12. (B) Clinical situation at the 1-year follow-up. (C) Clinical situation at 3 years of follow-up. (D) Clinical situation at 5 years of follow-up. (E) Cross-section view through superimposed stereolithography (STL) files, with the yellow line representing the baseline STL, the red line as the STL at 3 years and the light blue line at 5 years of follow-up. (F) Three-dimensional view at 5 years of follow-up with the corresponding region of interest (ROI) delineated in orange. MG = margo mucosae



2.7 | Clinical and periodontal measurements

Probing depth (PD), plaque control record (PCR), and bleeding on probing (BOP) were assessed at six sites for all implants and the respective two neighboring teeth. The width of the keratinized tissue (KT) was measured on the buccal side of the implants and the two adjacent teeth. The presence of peri-implant health or disease was assessed according to the report of the 2017 World Workshop on the Classification of Periodontal and Peri-Implant Diseases and Conditions.

The definition used for peri-implant mucositis cases was as follows³⁰:

- Presence of profuse (line or drop) bleeding and/or suppuration on probing
 - An increase in probing depths compared to baseline
 - Absence of bone loss beyond crestal bone level changes resulting from the initial remodeling

Peri-implantitis cases were defined by the following criteria^{7,30}:

- Presence of bleeding and/or suppuration on gentle probing
 - Increased probing depth compared to previous examinations
 - Presence of bone loss beyond crestal bone level changes (≥ 2 mm) from baseline
 - Probing depths of ≥ 6 mm

2.8 | Radiologic examination and assessment of bone loss

Radiographs were taken using a paralleling technique with digital sensor holders.⁶ Marginal bone levels were calculated at different time points by measuring the distance between the implant shoulder and the first bone-to-implant contact. The inter-thread pitch distance was used for the calibration of the apical-coronal measurements in each radiograph by using open-source software.⁷ The marginal bone level assessments were performed by one independent examiner who was not involved in the surgical or prosthetic treatment. The examiner performed the measurements on two different occasions at least 1 month apart. For the second occasion, radiographs of 10 patients were randomly selected using a computer-generated list (www.randomizer.org) and the intra-examiner reliability was calculated with the intra-class correlation coefficient (ICC). The ICC amounted to 0.97 (confidence interval [CI]: 0.87–0.99), revealing excellent intra-examiner reliability.

⁶ XCP dental film/PSP holder, Dentsply, Charlotte, North Carolina, USA.

⁷ ImageJ 1.50i, National Institutes of Health, Bethesda, Maryland, USA.

2.9 | Esthetics

Esthetics of the peri-implant tissues (mesial and distal papilla) was assessed by measuring the papilla fill (papilla index),³¹ the crown height (distance between the incisal edge and the mucosal margin on the buccal side), and the Pink Esthetic Score (PES). A blinded and calibrated clinician who was not involved in the surgical or prosthetic treatment performed all measurements. The PES scores were determined on two different occasions at least 1 month apart. For the second occasion, 10 cases were randomly selected using a computer-generated list (www.randomizer.org). For the PES scores, the ICC amounted to 0.95 (CI: 0.80–0.98), indicating excellent intra-examiner reliability.

2.10 | Patient-reported outcome measures (PROMs)

All patients filled out a standardized questionnaire (oral health impact profile-G14; OHIP-G14) to record PROMs.

2.11 | Randomization procedure, concealment of allocation, and outcome assessments

A block randomization was used to ensure a balance in patients allocated to either of the two groups. A study monitor performed the allocation concealment by preparing the assigned treatment in opaque, sealed envelopes. During surgery, these envelopes were opened following the preparation of the recipient site, thereby revealing the allocation. Blinding of the surgeon was not possible due to the nature of the SCTG group (harvesting). The examiner performing the follow-ups was blinded to the treatment as he did not participate in the initial surgical phase of the study.

2.12 | Statistical analysis

Means, medians, standard deviations, minimums, maximums, and the Q1 and Q3 quartiles were used to describe continuously scaled variables and counts and percentages for categorically scaled variables. Nonparametric statistical methods were applied. Differences in the distribution functions between treatment groups were evaluated with the Mann–Whitney *U*-test, and within treatment groups with the Wilcoxon signed-rank test. The treatment-related differences of medians were expressed as Hodges-Lehmann-estimates, including 95% CIs. The data were analyzed as intention-to-treat. As this was a



TABLE 1 Patient demographics at baseline

		VCMX group	SCTG group	P-value*
Sex	n (female)	7	6	1.000
	n (male)	3	4	
Age	Mean ± SD	44.1 ± 12.8	43.4 ± 18.7	1.000
	Median	46.0	47.5	
	Q1; Q3	39.0; 48.0	23.0; 60.0	
Cigarettes per day	Mean ± SD	0.0 ± 0.0	1.0 ± 2.5	0.184
	Median	0.0	0.0	
	Q1; Q3	0.0; 0.0	0.0; 0.0	

Abbreviations: Q1, first quartile; Q3, third quartile; SCTG, subepithelial connective tissue graft; SD, standard deviation; VCMX, volume-stable collagen matrix.

*Mann-Whitney *U*-test, *P*-values are given.

follow-up investigation of a previously performed randomized controlled clinical trial, the sample size resulted from the corresponding published study.²⁷ The original sample size was calculated to assess the non-inferiority of VCMX to SCTG for the changes in soft tissue thickness. Considering a non-inferiority margin of 1 mm, a SD of 0.5 mm, and a dropout rate of 30%, 10 patients per group were required to have 95% power with an alpha set at 0.05 to be consistent with the 95% CI of the non-inferiority trial.²⁷

3 | RESULTS

An overview with baseline demographics of the 20 patients, with 10 being treated with a VCMX and 10 with an SCTG, is displayed in Table 1. Follow-up examinations were performed between November 2012 and April 2015 (baseline; 20 patients) and January 2018 and June 2020 (FU-5; 15 patients). Due to the COVID-19 situation, two patients were unwilling to participate within the desired time frame for the 5-year follow-up. Moreover, two patients (one in each group) died between the 1- and 3-year follow-ups, whereas one patient had moved abroad shortly after the baseline examination. Therefore, 15 patients provided data for the 5-year analysis (Figure 3). None of the 15 patients received a second soft tissue augmentation surgery during the follow-up of 5 years.

3.1 | Mucosal thickness

The median mucosal thickness at baseline amounted to 3.0 mm in the VCMX and 3.0 mm in the SCTG groups (intergroup comparison: $P = 0.128$) (Table 2). At 5 years, the median mucosal thickness was 3.0 mm in the VCMX and 3.3 mm in the SCTG groups, with no significant differences between both groups ($P = 0.771$). The respective changes in median mucosal thickness between BL and 5 years amounted to 0.3 mm in both groups ($P = 0.752$) (Table 2).

3.2 | Contour changes of the peri-implant tissues

The dimensions of the ROI serving as a reference for the contour changes varied from patient to patient depending on the site (range 11–38 mm²; mean 24 mm²). The ridge contour changes between baseline and 5 years demonstrated a median decrease of –0.3 mm in both treatment groups (intergroup comparison: $P = 0.817$) (Table 3).

3.3 | Clinical and periodontal measurements

Peri-implant health was maintained in both groups over 5 years. This was reflected by median PD values ≤ 3 mm in both groups at all time points (see Table S1 in the Supporting Information, available in the online *Journal of Periodontology*) as well as by insignificant changes of BOP from baseline to 5 years in both groups (see Table S2 in the online *Journal of Periodontology*) ($P > 0.05$). Regarding PCR (see Table S3 in the online *Journal of Periodontology*) and KT (see Table S4 in the online *Journal of Periodontology*), there were no significant differences between the groups at any time point ($P > 0.05$), except at FU-1 where a higher median of KT in the SCTG group was observed (VCMX: 2.0 vs. SCTG: 3.0, $P = 0.037$). Healthy peri-implant status, peri-implant mucositis, and peri-implantitis were observed for VCMX in 71%, 29%, and 0% of the patients/sites, respectively, and in 50%, 50%, and 0%, respectively, for SCTG.

3.4 | Radiographic data

Median marginal bone levels measured 0.3 mm (VCMX) and –0.2 mm (SCTG) at baseline, and –0.2 mm (VCMX) and –0.5 mm (SCTG) at 5 years, with no significant differences between the groups ($P = 0.093$) (Table 4). Changes between baseline and FU-5 were insignificant in both

**TABLE 2** Soft tissue thickness at the different time points in both treatment groups and changes over time

	Soft tissue thickness (mm)		Intergroup P-value*
	VCMX group	SCTG group	
BL			0.128
	Mean ± SD	3.2 ± 0.8	2.7 ± 0.4
	Median	3.0	3.0
	Q1; Q3	3.0; 4.0	2.5; 3.0
6 M			1.000
	Mean ± SD	2.9 ± 0.9	3.0 ± 0.9
	Median	3.0	3.0
	Q1; Q3	2.0; 3.8	2.0; 3.5
FU-1			0.900
	Mean ± SD	2.8 ± 0.7	3.1 ± 1.3
	Median	3.0	2.8
	Q1; Q3	2.0; 3.0	2.0; 4.0
FU-3			0.901
	Mean ± SD	3.6 ± 1.5	3.8 ± 1.5
	Median	3.5	3.3
	Q1; Q3	3.0; 4.0	3.0; 5.5
	Diff. [95% CI]***	0.0 [−1.5; 1.0]	
FU-5			0.771
	Mean ± SD	3.4 ± 1.2	3.2 ± 1.1
	Median	3.0	3.25
	Q1; Q3	3.0; 4.0	3.0; 3.5
	Diff. [95% CI]***	0.0 [−1.0; 1.5]	
BL to 6M			0.318
	Mean ± SD	−0.3 ± 0.9	0.3 ± 1.0
	Median	0.0	0.0
	Q1; Q3	−0.5; 0.0	0.0; 1.0
	P-value**	0.750	0.500
BL to FU-1			0.243
	Mean ± SD	−0.4 ± 0.9	0.4 ± 1.4
	Median	−0.5	0.0
	Q1; Q3	−1.0; 0.3	−0.5; 1.0
	P-value**	0.231	0.563
BL to FU-3			0.303
	Mean ± SD	0.4 ± 1.1	1.1 ± 1.5
	Median	0.5	0.75
	Q1; Q3	−0.5; 1.25	0.0; 2.5
	P-value**	0.281	0.047
	Diff. [95% CI]***	−1.0 [−2.0; 1.0]	
BL to FU-5			0.752
	Mean ± SD	0.3 ± 1.1	0.5 ± 1.0
	Median	0.3	0.3
	Q1; Q3	−0.8; 1.0	0.0; 1.0
	P-value**	0.656	0.188
	Diff. [95% CI]***	0.0 [−1.0; 1.0]	

Abbreviations: 6M, follow-up at 6 months; BL, baseline; CI, confidence interval; FU-1, follow-up at 1 year; FU-3, follow-up at 3 years; FU-5, follow-up at 5 years; Q1, first quartile; Q3, third quartile; SCTG, subepithelial connective tissue graft; SD, standard deviation; VCMX, volume-stable collagen matrix.

*Mann-Whitney *U*-test.

**Non-parametric Wilcoxon signed-test (intragroup differences).

***Hodges-Lehmann estimate of the treatment-related difference including 95% confidence interval (CI). *P*-values are given.

**TABLE 3** Profilometric changes by 3D volumetric analysis at the different time points in both treatment groups and changes over time

	Profilometric changes (mm)		Intergroup P-value*
	VCMX group	SCTG group	
BL to 6M			0.462
	Mean ± SD	-0.1 ± 0.4	-0.2 ± 0.3
	Median	0.0	-0.1
	Q1; Q3	-0.2; 0.1	-0.3; 0.0
	P-value**	0.574	0.049
BL to FU-1			0.369
	Mean ± SD	-0.2 ± 0.5	-0.2 ± 0.2
	Median	-0.1	-0.2
	Q1; Q3	-0.2; 0.0	-0.4; -0.1
	P-value**	0.301	0.002
BL to FU-3			0.596
	Mean ± SD	-0.3 ± 0.4	-0.2 ± 0.3
	Median	-0.2	-0.1
	Q1; Q3	-0.5; -0.1	-0.3; -0.1
	P-value**	0.039	0.020
	Diff. [95% CI]***	-0.05 [-0.49; 0.2]	
BL to FU-5			0.817
	Mean ± SD	-0.4 ± 0.5	-0.3 ± 0.3
	Median	-0.3	-0.3
	Q1; Q3	-0.9; -0.1	-0.4; -0.2
	P-value**	0.078	0.039
	Diff. [95% CI]***	-0.025 [-0.64; 0.29]	

Abbreviations: 6M, follow-up at 6 months; BL, baseline; CI, confidence interval; FU-1, follow-up at 1 year; FU-3, follow-up at 3 years; FU-5, follow-up at 5 years; Q1, first quartile; Q3, third quartile; SCTG, subepithelial connective tissue graft; SD, standard deviation; VCMX, volume-stable collagen matrix.

*Mann-Whitney *U*-test.

**Non-parametric Wilcoxon signed-test (intragroup differences).

***Hodges-Lehmann estimate of the treatment-related difference including 95% confidence interval (CI). *P*-values are given.

TABLE 4 Marginal bone levels at the different time points in both treatment groups and changes over time

	Marginal bone levels (mm)		Intergroup P-value*
	VCMX group	SCTG group	
BL			0.039
	Mean ± SD	0.2 ± 0.7	-0.3 ± 0.5
	Median	0.3	-0.2
	Q1; Q3	0.0; 0.6	-0.4; 0.2
FU-5			0.093
	Mean ± SD	-0.4 ± 1.1	-0.7 ± 0.6
	Median	-0.2	-0.5
	Q1; Q3	-0.6; 0.3	-0.6; -0.4
BL to FU-5			0.772
	Mean ± SD	-0.5 ± 0.7	-0.4 ± 0.4
	Median	-0.7	-0.4
	Q1; Q3	-1.0; 0.2	-0.6; 0.0
	P-value**	0.219	0.055

Abbreviations: BL, baseline; FU-5, follow-up at 5 years; Q1, first quartile; Q3, third quartile; SD, standard deviation; SCTG, subepithelial connective tissue graft; VCMX, volume-stable collagen matrix.

*Mann-Whitney *U*-test.

**Non-parametric Wilcoxon signed-test (intragroup differences). *P*-values are given.

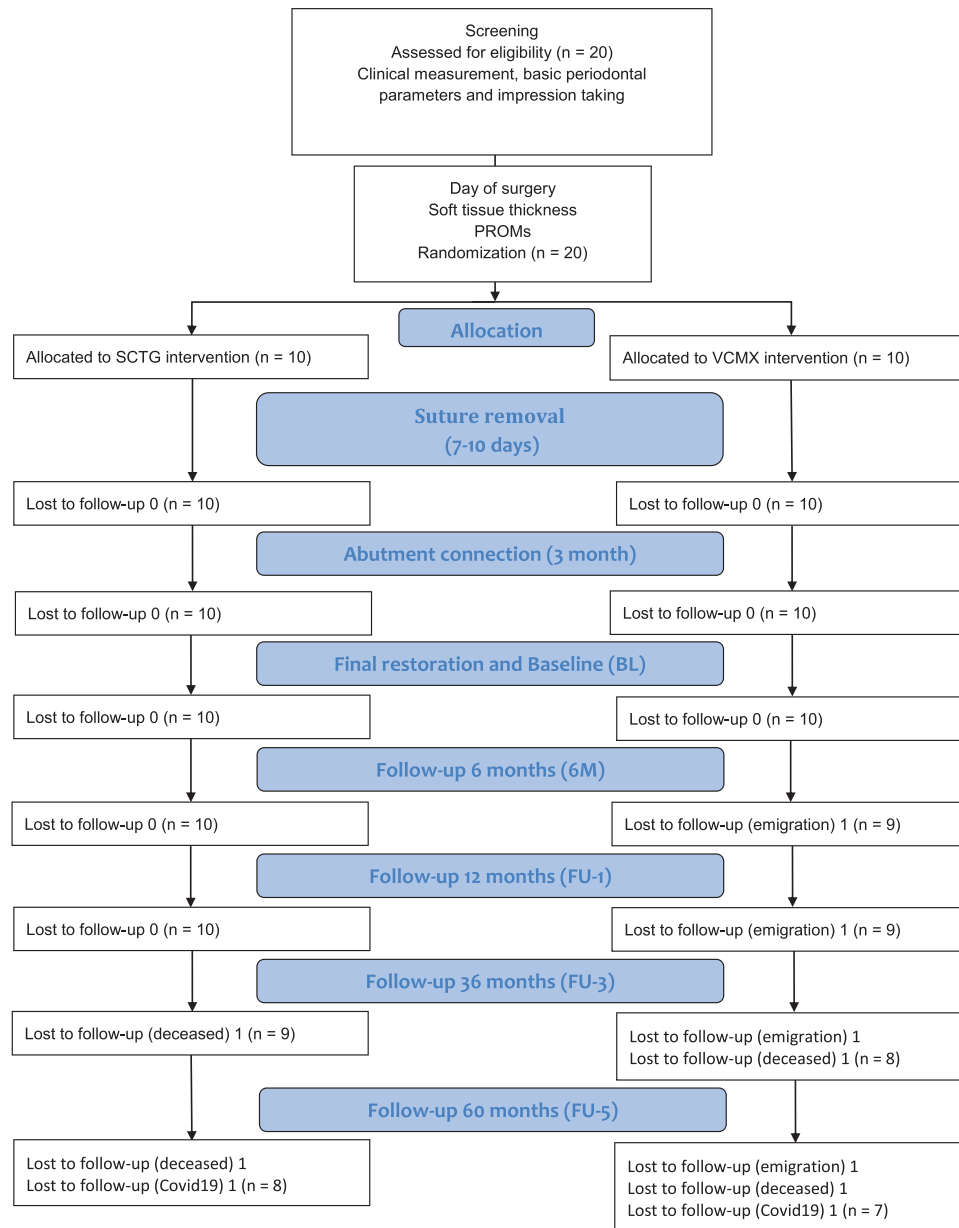


FIGURE 3 CONSORT flow diagram. VCMX, volume-stable collagen matrix; SCTG, subepithelial connective tissue graft; PROMs, patient-reported outcome measures

groups, with -0.7 mm ($P = 0.219$) in the VCMX group and -0.4 mm ($P = 0.055$) in the SCTG group (intergroup $P = 0.772$) (Table 4).

3.5 | Esthetics

All esthetic outcome measures are presented in Table S5 (see the online *Journal of Periodontology*). At BL median PES scores amounted to 9.0 (9.0; 11.0) for VCMX and 8.5 (6.0; 11.0) for SCTG (intergroup $P = 0.444$). At 5 years of follow-up, the median PES amounted to 11.0 in both groups, with no significant differences between the groups

(VCMX: 11.0 [8.0; 13.0] vs. SCTG: 11.0 [8.5; 12.0], $P = 1.000$). The median mid-facial recession amounted to 0 mm in both groups (VCMX: 0.0 [0.0; 1.0] vs. SCTG: 0.0 [0.0; 0.5]) at 5 years, indicating a stability of the mucosal margin (see Table S6 in the online *Journal of Periodontology*).

3.6 | Patient-reported outcome measures

The median overall OHIP-G14 scores were close to or at 0 at all follow-up time points without significant differences between the groups ($P > 0.05$) (see Table S7 in the online *Journal of Periodontology*).



4 | DISCUSSION

The present long-term follow-up of an RCT comparing a collagen-based soft tissue substitute to an autogenous connective tissue graft for mucosal thickness augmentation at single implant sites predominantly revealed the following, from crown insertion to 5 years: (i) similar mucosal thickness between the groups; (ii) a comparable and slight decrease of the buccal peri-implant tissue contour; (iii) stable and healthy peri-implant tissues in a majority of the sites; and (iv) favorable and similar esthetic outcomes in both treatment groups.

Mucogingival procedures to augment the mucosal thickness at implant sites are increasingly performed at various time points during implant therapy.^{4,33–35} This is based on scientific data indicating that a sufficient thickness of the peri-implant tissues results in more favorable biological, prosthetic, and esthetic outcomes.^{11,36,37} Nevertheless, the majority of data derive from studies with a short- to mid-term time frame. This is of clinical importance, as reliance on long-term data is a decisive factor for decision-making in daily practice. Hence, prospective clinical studies assessing the effect of soft tissue grafting procedures in the long run were needed.³⁸

Traditional methods for assessing peri-implant tissue changes are based on linear measurements using an endodontic file inserted at the buccal aspect (close to the mucosal margin) of the implant site.^{16,39–41} The present study revealed a median thickness of 3 mm in both groups at 5 years. Unfortunately, an unbiased comparison between the present values with other clinical datasets is not feasible, as there are no long-term clinical data available with VCMX. Notwithstanding, the present values are in line with previous clinical investigations on implants in the esthetic zone with final mucosal thickness values ranging from 2.4 mm³⁵ to 3.4 mm.⁴² Apart from traditional measurements, the superimposition of impressions taken at various time points during the follow-up examinations adds a further parameter for assessing the stability of the peri-implant tissues. This technique was introduced in the late 2000s⁴³ and has been applied in a plethora of both preclinical and clinical studies.^{29,44–48} In the present study, contour changes of the peri-implant tissues demonstrated a clinically negligible decrease of 0.3 mm in both treatment groups. Clinically, such contour changes might still be considered as stable and are in line with previous clinical follow-up studies reporting similar change.^{45,48}

Interestingly, when the contour changes were compared to the linear measurements using the endodontic file (mucosal thickness), the two methods showed an opposite trend. Whereas the contour slightly decreased, the soft tissue thickness increased with a median difference

of ≈ 0.5 mm. This difference might be related to a resorption of the buccal bone compensated by an increase in soft tissue thickness, as recently shown in a clinical study.⁵¹ Without cone-beam computed tomographies available this hypothesis nevertheless cannot be confirmed. Another possible explanation for this opposite trend is the methodology applied. The measurements with endodontic files could be prone to some errors, including the instability of the rubber stop with its potential to move up and down the instrument shaft⁵² and the inherent rounding errors.

Regarding the increase of soft tissue thickness over time, the present study revealed a similar median increase of 0.3 mm in both groups between baseline and 5 years of follow-up. This comparable increase between VCMX and SCTG is in contrast to systematic reviews, which have indicated a significantly higher increase of about 0.5 mm for SCTG over soft tissue substitutes.^{37,49} Similarly, a recent multi-center RCT, comparing VCMX to SCTG for soft tissue augmentation at implant sites, revealed 0.4 mm more increase ($p < 0.05$) with SCTG at 1 year follow-up. The lack of difference between both treatment modalities in the present study is most likely explained by methodological differences. Whilst the study by Cosyn and coworkers³⁸ was designed as a superiority trial with 60 patients, the present trial was originally designed as a non-inferiority trial with 20 patients. Apart from the inherent limited power of the present study, non-inferiority trials are primarily designed to find therapies that are not substantially worse than the standard of care, but have other advantages, such as lower morbidity.⁵⁰

As mentioned above, autogenous soft tissue grafts are still considered the gold standard to augment the mucosal thickness, with gains of about 0.5 mm over soft tissue substitutes.^{37,38,49} Soft tissue substitutes, however, can significantly reduce pain perception, amounts of painkillers, and surgery time, while achieving similar levels of patient satisfaction as autogenous grafts.⁵³ Arguably, the best treatment may not necessarily be the one that shows the highest efficacy in RCTs but the one that fits with the patient's values and preferences.^{19,20} While from a clinical standpoint a millimeter of difference might be important, this difference is probably irrelevant for the patient. In fact, statistically significant differences do not necessarily equate to clinically important differences.²⁰ Nevertheless, the minimal clinically important differences^{54,55} in implant-related outcomes have not been established, complicating the decision-making.²⁰ Therefore, for the purpose of decision-making it seems reasonable that clinicians ask themselves how much they are willing to give up in terms of clinical efficacy relative to the standard of care (SCTG), in return for the benefits in terms of morbidity with soft tissue substitutes.⁵³



The maintenance of peri-implant health over time is, apart from the pleasing esthetics, one of the goals in implant therapy. Systematic reviews and clinical studies have demonstrated that soft tissue grafting at implant sites is one of the important parameters with a considerable influence on marginal bone levels and the respective changes over time.^{2,33,56–58} Peri-implant health was maintained in both treatment groups as reflected by PD values ≤ 3 mm, an insignificant increase in BOP, as well as marginal bone levels located close to the implant shoulder. Final marginal bone levels were 0.2 and 0.5 mm below the implant shoulder. Those values are within the range that is commonly reported for two-piece dental implants with a horizontal off-set at 5 years.^{59–61}

The present study demonstrated that the augmented peri-implant tissues remained stable over 5 years. PROMs further underlined the positive clinical experience in the short term. PROMs were assessed at all follow-up examinations using a standardized and validated questionnaire (OHIP-14). The scores obtained were all close to 0 at all follow-up time points, reflecting success for the overall treatment from the patient's point of view. The observation that PROM scores return to 0, once the active treatment phase is over, has been shown in several clinical studies.^{16,62,63}

The outcomes of the present non-interventional follow-up are limited by a number of factors: (i) a low sample size and a considerable drop-out rate, limiting the power of the study to detect significant differences; (ii) the COVID-19 situation that prevented two additional patients from attending the scheduled 5-year examination; (iii) the learning curve being associated with a new device reflected in some of the early outcomes; (iv) the gap between the time point of abutment connection and the insertion of the final restoration that is not reflected in any outcome measure; (v) the hybrid workflow (indirect technique) to obtain the STL files, being prone to some inherent errors due to the additional steps and which may have affected the volumetric analyses; and (vii) possible inaccuracies in the radiograph evaluation between the follow-ups, despite the calibration of the examiner and the use of digital sensor holders and bite blocks, since individualized bite blocks for each patient were not fabricated.

Despite the limitations mentioned above, this is the first RCT that provides long-term data with a cross-linked VCMX showing long-term performance and safety. Assuming that patients tend to prefer less painful procedures and clinicians simplified procedures, the use of a soft-tissue substitute appears to be an acceptable alternative to SCTG for mucosal thickness augmentation at implant sites, particularly in pain-sensitive patients.^{37,38,53} Collectively, the present findings can assist clinicians in the decision-making process in clinical practice.

5 | CONCLUSIONS

Despite the limited power and the considerable dropout rate of the present study, implant sites that underwent a procedure to augment the mucosal thickness using either a VCMX or the gold standard (SCTG) resulted in stable peri-implant tissues from a biological (peri-implant health in a majority of the cases), clinical (ridge contour), as well as esthetic (PES scores) point of view, in addition to favorable PROMs, during an observation period of 5 years.

AUTHOR CONTRIBUTIONS

All authors have made substantial contributions to the conception and design of the study. Daniel S. Thoma, Thomas J. W. Gasser, Christoph H. F. Hämmerle, Ronald E. Jung, and Franz J. Strauss were involved in data collection and data analysis. Franz J. Strauss and Daniel S. Thoma interpreted the data and drafted the manuscript. All authors critically revised the draft and approved the final version.

ACKNOWLEDGMENTS


The authors would like to thank Gisela Müller and Christa Fritschi of the Clinic of Reconstructive Dentistry, University of Zurich, for monitoring the study.

CONFLICT OF INTEREST

Drs. Thoma, Hämmerle, and Jung have provided lectures sponsored by Geistlich Pharma AG. Drs. Strauss and Gasser report no conflicts of interest related to this study.

ORCID

Daniel S. Thoma  <https://orcid.org/0000-0002-1764-7447>

Thomas J. W. Gasser  <https://orcid.org/0000-0002-3161-6065>

Christoph H. F. Hämmerle  <https://orcid.org/0000-0002-8280-7347>

Franz J. Strauss  <https://orcid.org/0000-0002-5832-7327>

Ronald E. Jung  <https://orcid.org/0000-0003-2055-1320>

REFERENCES

1. Raghoobar GM, Meijer HJA, van Minnen B, Vissink A. Immediate reconstruction of failed implants in the esthetic zone using a flapless technique and autogenous composite tuberosity graft. *J Oral Maxillofac Surg*. 2018;76:528-533.
2. Thoma DS, Naenni N, Figuero E, et al. Effects of soft tissue augmentation procedures on peri-implant health or disease: a systematic review and meta-analysis. *Clin Oral Implants Res*. 2018;29(15):32-49. Suppl.
3. Cosyn J, De Bruyn H, Cleymaet R. Soft tissue preservation and pink aesthetics around single immediate implant restorations: a 1-year prospective study. *Clin Implant Dent Relat Res*. 2013;15:847-857.



4. Thoma DS, Muhlemann S, Jung RE. Critical soft-tissue dimensions with dental implants and treatment concepts. *Periodontol* 2000. 2014;66:106-118.
5. Schneider D, Grunder U, Ender A, Hämmerle CHF, Jung RE. Volume gain and stability of peri-implant tissue following bone and soft tissue augmentation: 1-year results from a prospective cohort study. *Clin Oral Implants Res*. 2011;22:28-37.
6. Tomasi C, Derks J. Clinical research of peri-implant diseases—quality of reporting, case definitions and methods to study incidence, prevalence and risk factors of peri-implant diseases. *J Clin Periodontol*. 2012;39(Suppl 12):207-223.
7. Berglundh T, Armitage G, Araujo MG, et al. Peri-implant diseases and conditions: consensus report of workgroup 4 of the 2017 World Workshop on the classification of periodontal and peri-implant diseases and conditions. *J Periodontol*. 2018;89(Suppl 1):S313-S318.
8. Romandini M, Berglundh J, Derks J, Sanz M, Berglundh T. Diagnosis of peri-implantitis in the absence of baseline data: a diagnostic accuracy study. *Clin Oral Implants Res*. 2021;32:297-313.
9. Avila-Ortiz G, Gonzalez-Martin O, Couso-Queiruga E, Wang HL. The peri-implant phenotype. *J Periodontol*. 2020;91:283-288.
10. Jung RE, Sailer I, Hammerle CH, Attin T, Schmidlin P. In vitro color changes of soft tissues caused by restorative materials. *Int J Periodontics Restorative Dent*. 2007;27:251-257.
11. Bienz SP, Pirc M, Papageorgiou SN, Jung RE, Thoma DS. The influence of thin as compared to thick peri-implant soft tissues on aesthetic outcomes: a systematic review and meta-analysis. *Clin Oral Implants Res*. 2022;33(Suppl 23):56-71.
12. Raghoobar GM, Korfage A, Meijer HJA, Gareb B, Vissink A, Delli K. Linear and profilometric changes of the mucosa following soft tissue augmentation in the zone of aesthetic priority: a systematic review and meta-analysis. *Clin Oral Implants Res*. 2021;32(Suppl 21):138-156.
13. Thoma DS, Cosyn J, Fickl S, et al. Soft tissue management at implants: summary and consensus statements of group 2. The 6th EAO Consensus Conference 2021. *Clin Oral Implants Res*. 2021;32(Suppl 21):174-180.
14. Cairo F, Barbato L, Selvaggi F, Baielli MG, Piattelli A, Chambrone L. Surgical procedures for soft tissue augmentation at implant sites. A systematic review and meta-analysis of randomized controlled trials. *Clin Implant Dent Relat Res*. 2019;21:1262-1270.
15. Zucchelli G, Tavelli L, McGuire MK, et al. Autogenous soft tissue grafting for periodontal and peri-implant plastic surgical reconstruction. *J Periodontol*. 2020;91:9-16.
16. De Bruyckere T, Cosyn J, Younes F, et al. A randomized controlled study comparing guided bone regeneration with connective tissue graft to re-establish buccal convexity: one-year aesthetic and patient-reported outcomes. *Clin Oral Implants Res*. 2020;31:507-516.
17. Zuiderveld EG, Meijer HJA, den Hartog L, Vissink A, Raghoobar GM. Effect of connective tissue grafting on peri-implant tissue in single immediate implant sites: a RCT. *J Clin Periodontol*. 2018;45:253-264.
18. Soileau KM, Brannon RB. A histologic evaluation of various stages of palatal healing following subepithelial connective tissue grafting procedures: a comparison of eight cases. *J Periodontol*. 2006;77:1267-1273.
19. Chow A, Purkayastha S, Dosanjh D, Sarvanandan R, Ahmed I, Paraskeva P. Patient reported outcomes and their importance in the development of novel surgical techniques. *Surg Innov*. 2012;19:327-334.
20. Thoma DS, Strauss FJ. On the discrepancy between professionally assessed and patient-reported outcome measures. *J Periodontal Implant Sci*. 2022;52:89-90.
21. De Bruyn H, Raes S, Matthys C, Cosyn J. The current use of patient-centered/reported outcomes in implant dentistry: a systematic review. *Clin Oral Implants Res*. 2015;26(Suppl 11):45-56.
22. McGuire MK, Janakievski J, Scheyer ET, et al. Efficacy of a harvest graft substitute for recession coverage and soft tissue volume augmentation: a randomized controlled trial. *J Periodontol*. 2021;93(3):333-342.
23. McGuire MK, Scheyer ET, Lipton DI, Gunsolley JC. Randomized, controlled, clinical trial to evaluate a xenogeneic collagen matrix as an alternative to free gingival grafting for oral soft tissue augmentation: a 6- to 8-year follow-up. *J Periodontol*. 2021;92:1088-1095.
24. Sanz M, Lorenzo R, Aranda JJ, Martin C, Orsini M. Clinical evaluation of a new collagen matrix (Mucograft prototype) to enhance the width of keratinized tissue in patients with fixed prosthetic restorations: a randomized prospective clinical trial. *J Clin Periodontol*. 2009;36:868-876.
25. Schmitt CM, Moest T, Lutz R, Wehrhan F, Neukam FW, Schlegel KA. Long-term outcomes after vestibuloplasty with a porcine collagen matrix (Mucograft((R))) versus the free gingival graft: a comparative prospective clinical trial. *Clin Oral Implants Res*. 2016;27:e125-e133.
26. Zeltner M, Jung RE, Hammerle CH, Husler J, Thoma DS. Randomized controlled clinical study comparing a volume-stable collagen matrix to autogenous connective tissue grafts for soft tissue augmentation at implant sites: linear volumetric soft tissue changes up to 3 months. *J Clin Periodontol*. 2017;44:446-453.
27. Thoma DSZ, Zeltner M, Hilbe M, Hämmerle CH, Hüsler J, Jung RE. Randomized controlled clinical study evaluating effectiveness and safety of a volume-stable collagen matrix compared to autogenous connective tissue grafts for soft tissue augmentation at implant sites. *J Clin Periodontol*. 2016;43:874-885.
28. Schulz KF, Altman DG, Moher D. CONSORT 2010 statement: updated guidelines for reporting parallel group randomised trials. *BMJ*. 2010;340:c332.
29. Sapata VM, Sanz-Martin I, Hammerle CHF, Cesar Neto JB, Jung RE, Thoma DS. Profilometric changes of peri-implant tissues over 5 years: a randomized controlled trial comparing a one- and two-piece implant system. *Clin Oral Implants Res*. 2018;29:864-872.
30. Renvert S, Persson GR, Piri FQ, Camargo PM. Peri-implant health, peri-implant mucositis, and peri-implantitis: case definitions and diagnostic considerations. *J Periodontol*. 2018;89(Suppl 1):S304-S312.
31. Jemt T. Regeneration of gingival papillae after single-implant treatment. *Int J Periodontics Restorative Dent*. 1997;17:326-333.
32. Tavelli L, Barootchi S, Avila-Ortiz G, Urban IA, Giannobile WV, Wang HL. Peri-implant soft tissue phenotype modification and its impact on peri-implant health: a systematic review and network meta-analysis. *J Periodontol*. 2021;92:21-44.



33. Thoma DS, Benic GI, Zwahlen M, Hammerle CH, Jung RE. A systematic review assessing soft tissue augmentation techniques. *Clin Oral Implants Res.* 2009;20(Suppl 4):146-165.
34. Poli PP, Maridati PC, Stoffella E, Beretta M, Maiorana C. Influence of timing on the horizontal stability of connective tissue grafts for buccal soft tissue augmentation at single implants: a prospective controlled pilot study. *J Oral Maxillofac Surg.* 2019;77:1170-1179.
35. Jung RE, Holderegger C, Sailer I, Khraisat A, Suter A, Hammerle CH. The effect of all-ceramic and porcelain-fused-to-metal restorations on marginal peri-implant soft tissue color: a randomized controlled clinical trial. *Int J Periodontics Restorative Dent.* 2008;28:357-365.
36. Jung RE, Becker K, Bienz SP, et al. Effect of peri-implant mucosal thickness on esthetic outcomes and the efficacy of soft tissue augmentation procedures: consensus report of group 2 of the SEPA/DGI/OF workshop. *Clin Oral Implants Res.* 2022;33(Suppl 23):100-108.
37. Cosyn J, Eeckhout C, De Bruyckere T, et al. A multi-centre randomized controlled trial comparing connective tissue graft with collagen matrix to increase soft tissue thickness at the buccal aspect of single implants: 1-year results. *J Clin Periodontol.* 2022. <https://doi.org/10.1111/jcpe.13691>. Online ahead of print. PMID: 35781692.
38. Schallhorn RA, McClain PK, Charles A, Clem D, Newman MG. Evaluation of a porcine collagen matrix used to augment keratinized tissue and increase soft tissue thickness around existing dental implants. *Int J Periodontics Restorative Dent.* 2015;35:99-103.
39. Cevallos CAR, de Resende DRB, Damante CA, et al. Free gingival graft and acellular dermal matrix for gingival augmentation: a 15-year clinical study. *Clin Oral Investig.* 2020;24:1197-1203.
40. Hutton CG, Johnson GK, Barwacz CA, Allareddy V, Avila-Ortiz G. Comparison of two different surgical approaches to increase peri-implant mucosal thickness: a randomized controlled clinical trial. *J Periodontol.* 2018;89:807-814.
41. Cairo F, Barbato L, Tonelli P, Batalocco G, Pagavino G, Nieri M. Xenogeneic collagen matrix versus connective tissue graft for buccal soft tissue augmentation at implant site. A randomized, controlled clinical trial. *J Clin Periodontol.* 2017;44:769-776.
42. Windisch SI, Jung RE, Sailer I, Studer SP, Ender A, Hammerle CH. A new optical method to evaluate three-dimensional volume changes of alveolar contours: a methodological in vitro study. *Clin Oral Implants Res.* 2007;18:545-551.
43. Bienz SP, Sailer I, Sanz-Martin I, Jung RE, Hammerle CH, Thoma DS. Volumetric changes at pontic sites with or without soft tissue grafting: a controlled clinical study with a 10-year follow-up. *J Clin Periodontol.* 2017;44:178-184.
44. Bienz SP, Jung RE, Sapata VM, Hammerle CHF, Husler J, Thoma DS. Volumetric changes and peri-implant health at implant sites with or without soft tissue grafting in the esthetic zone, a retrospective case-control study with a 5-year follow-up. *Clin Oral Implants Res.* 2017;28:1459-1465.
45. Eeckhout C, Bouckaert E, Verleyen D, De Bruyckere T, Cosyn J. A 3-year prospective study on a porcine-derived acellular collagen matrix to re-establish convexity at the buccal aspect of single implants in the molar area: a volumetric analysis. *J Clin Med.* 2020;9(5):1568.
46. Noh K, Thoma DS, Park JC, Lee DW, Shin SY, Lim HC. A case series of profilometric changes in two implant placement protocols at periodontally compromised non-molar sites. *Sci Rep.* 2021;11:1714.
47. Papi P, Penna D, Di Murro B, Pompa G. Clinical and volumetric analysis of peri-implant soft tissue augmentation using an acellular dermal matrix: a prospective cohort study. *J Periodontol.* 2021;92:803-813.
48. Naenni N, Stucki L, Husler J, et al. Implants sites with concomitant bone regeneration using a resorbable or non-resorbable membrane result in stable marginal bone levels and similar profilometric outcomes over 5 years. *Clin Oral Implants Res.* 2021;32:893-904.
49. Hardy LB, Cox FL. Precision measurement control in endodontics. *Oral Surg Oral Med Oral Pathol.* 1980;49:538-540.
50. Valles C, Vilarrasa J, Barallat L, Pascual A, Nart J. Efficacy of soft tissue augmentation procedures on tissue thickening around dental implants: a systematic review and meta-analysis. *Clin Oral Implants Res.* 2022;33(Suppl 23):72-99.
51. Kaji AH, Lewis RJ. Noninferiority trials: is a new treatment almost as effective as another? *JAMA.* 2015;313:2371-2372.
52. Thoma DS, Strauss FJ, Mancini L, Gasser TJ, Jung RE. Minimal invasiveness in soft tissue augmentation at dental implants: a systematic review and meta-analysis of patient-reported outcome measures. *Periodontology 2000.* 2022. <https://doi.org/10.1111/prd.12465>
53. Jaeschke R, Singer J, Guyatt GH. Measurement of health status. Ascertaining the minimal clinically important difference. *Control Clin Trial.* 1989;10:407-415.
54. McGlothlin AE, Lewis RJ. Minimal clinically important difference: defining what really matters to patients. *JAMA.* 2014;312:1342-1343.
55. van Eekeren P, van Elsas P, Tahmaseb A, Wismeijer D. The influence of initial mucosal thickness on crestal bone change in similar macrogeometrical implants: a prospective randomized clinical trial. *Clin Oral Implants Res.* 2017;28:214-218.
56. Giannobile WV, Jung RE, Schwarz F, Groups of the 2nd Osteology Foundation Consensus M. Evidence-based knowledge on the aesthetics and maintenance of peri-implant soft tissues: osteology Foundation Consensus Report Part 1-Effects of soft tissue augmentation procedures on the maintenance of peri-implant soft tissue health. *Clin Oral Implants Res.* 2018;29(Suppl 15):7-10.
57. Puisys A, Zukauskas S, Kubilius R, et al. Clinical and histologic evaluations of porcine-derived collagen matrix membrane used for vertical soft tissue augmentation: a case series. *Int J Periodontics Restorative Dent.* 2019;39:341-347.
58. Strauss FJ, Hammerle CHF, Thoma DS. Short communication: cemented implant reconstructions are associated with less marginal bone loss than screw-retained reconstructions at 3 and 5 years of loading. *Clin Oral Implants Res.* 2021;32:651-656.
59. Wennstrom JL, Ekstubbe A, Grondahl K, Karlsson S, Lindhe J. Implant-supported single-tooth restorations: a 5-year prospective study. *J Clin Periodontol.* 2005;32:567-574.
60. Wessels R, Vervaeke S, Seyssens L, Eghbali A, Cosyn J. A 5-year cohort study on early implant placement with guided bone regeneration or alveolar ridge preservation with connective tissue graft. *Clin Implant Dent Relat Res.* 2020;22:697-705.



61. Fonteyne E, Burms E, Matthys C, Van Lierde K, De Bruyn H. Four-implant-supported overdenture treatment in the maxilla. Part II: speech- and oral health-related quality of life in patients with implant-supported overdentures in the maxilla-A prospective 3-year follow-up. *Clin Implant Dent Relat Res*. 2021;23(5):680-691.
62. de Carvalho EBS, Ferreira R, Azuaga BO, et al. Impact of subepithelial connective tissue for root coverage on brazilian patients' quality of life: a longitudinal clinical study. *J Int Acad Periodontol*. 2021;23:99-105.

SUPPORTING INFORMATION

Additional supporting information can be found online in the Supporting Information section at the end of this article.

How to cite this article: Thoma DS, Gasser TJW, Hämmerle CHF, Strauss FJ, Jung RE. Soft tissue augmentation with a volume-stable collagen matrix or an autogenous connective tissue graft at implant sites: Five-year results of a randomized controlled trial post implant loading. *J Periodontol*. 2022;1-14. <https://doi.org/10.1002/JPER.22-0226>